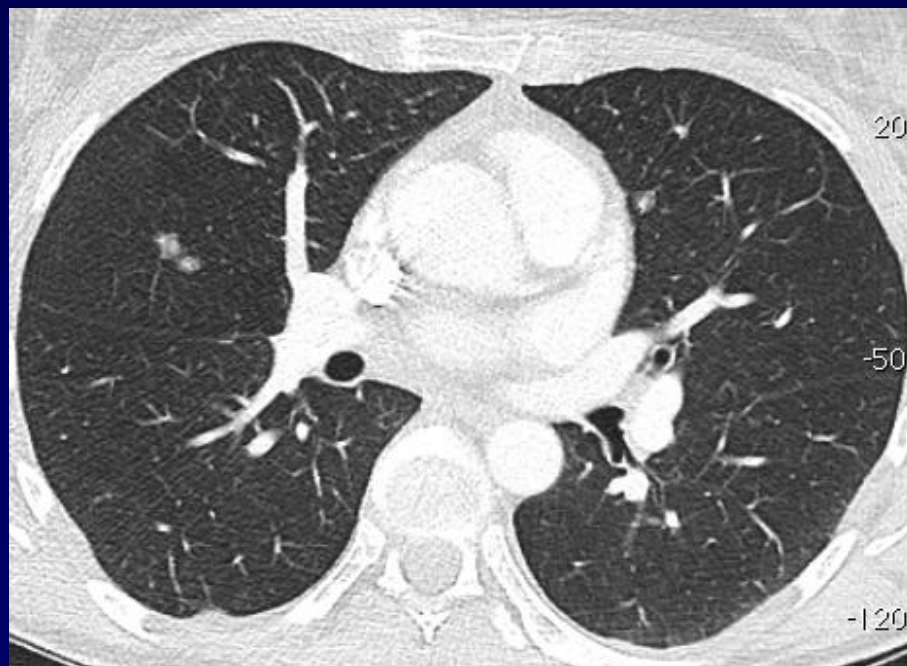
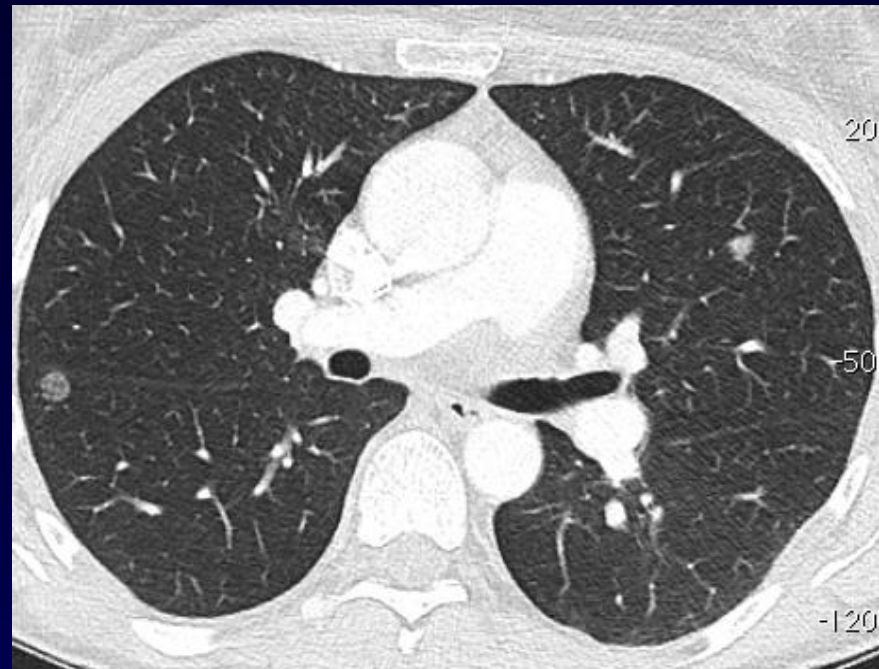
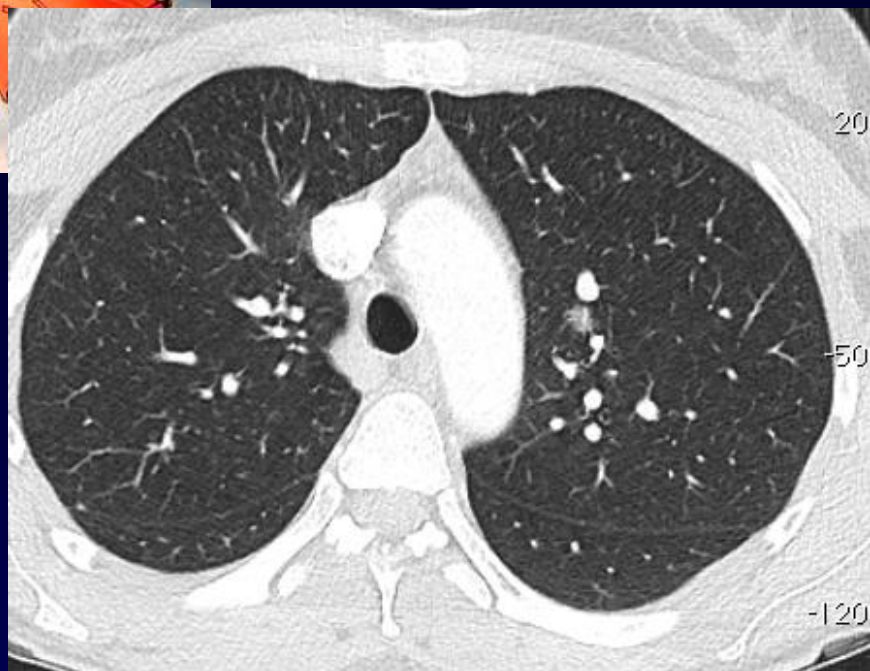




Quiz 3

- Femme de 38 ans
- Douleurs abdominales isolées
- Etat général conservé
- Pas de SF respiratoire
- Bilan gynéco: kyste ovarien banal
- Biologie normale
- Endoscopie non contributive



Diagnostic ?

PET Scan - SUV = 3.6

