

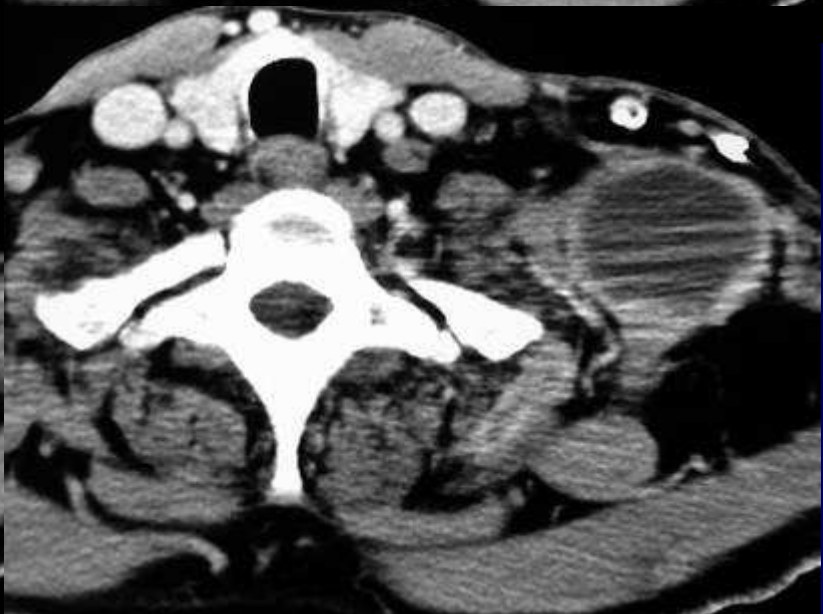
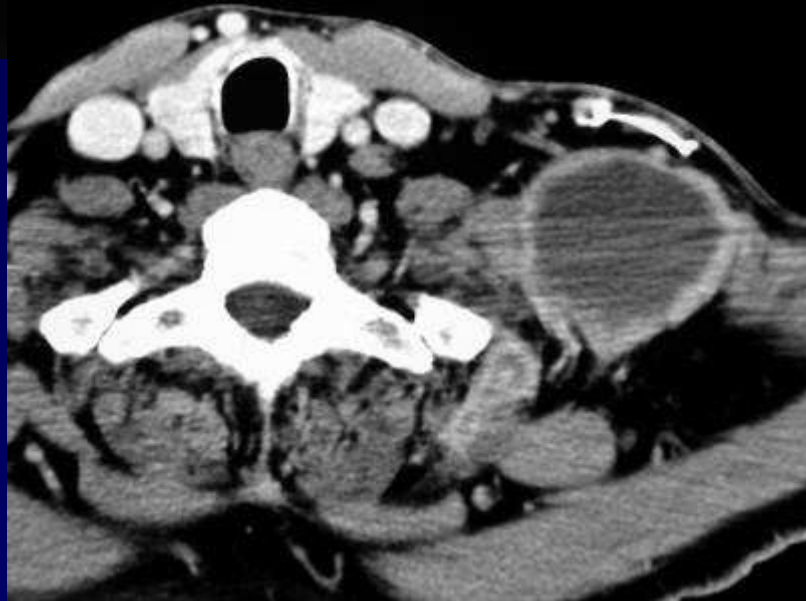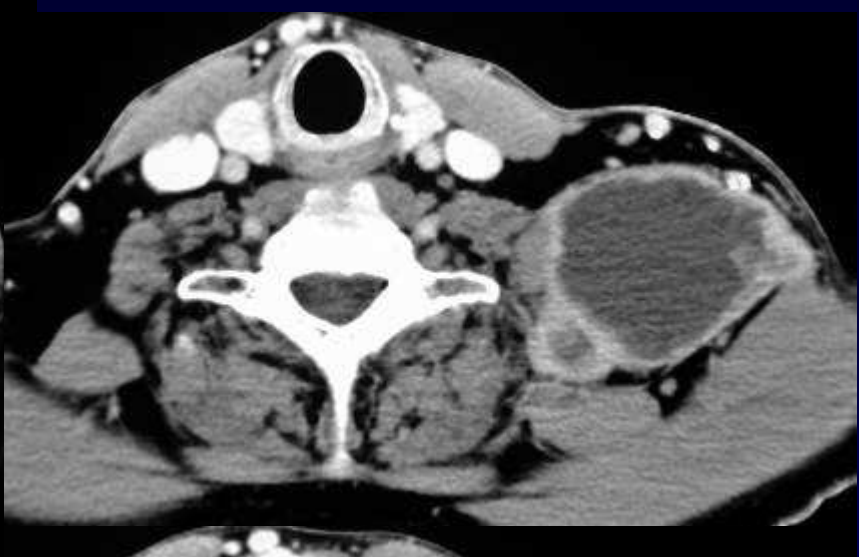

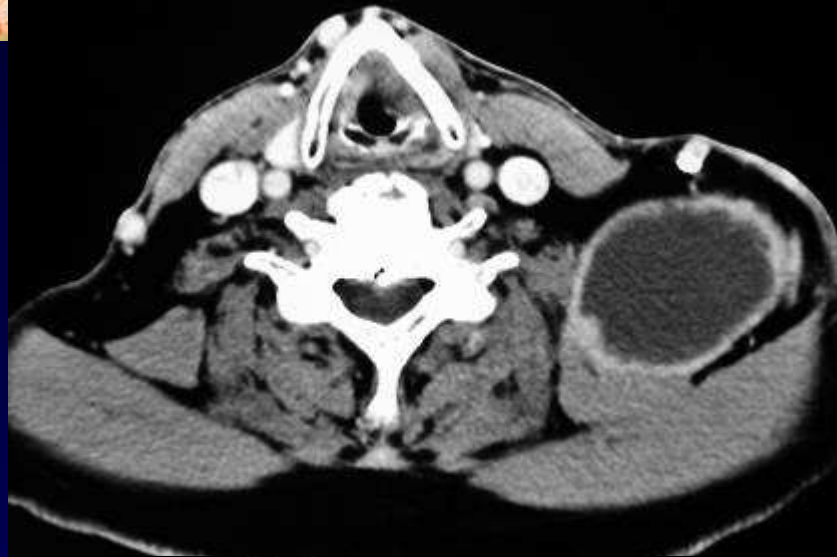
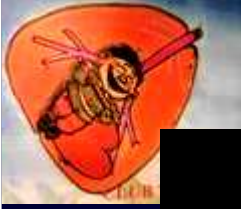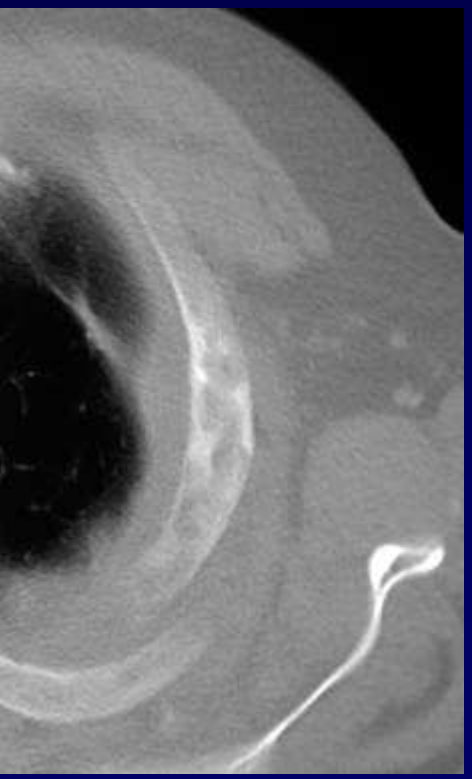
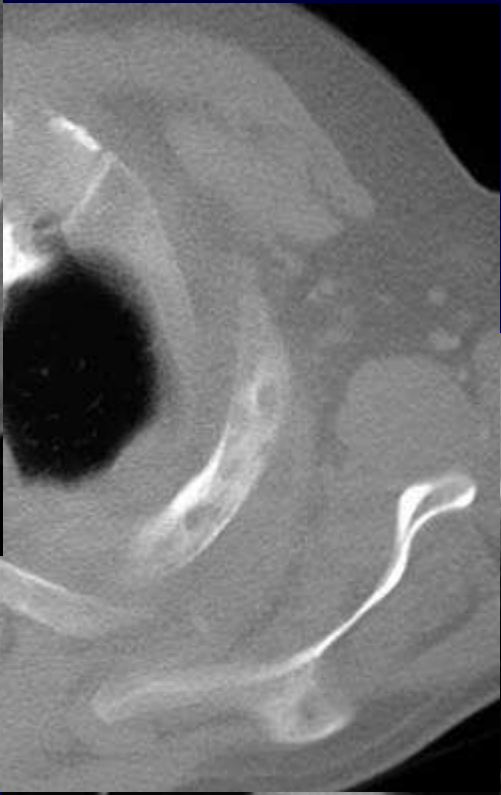
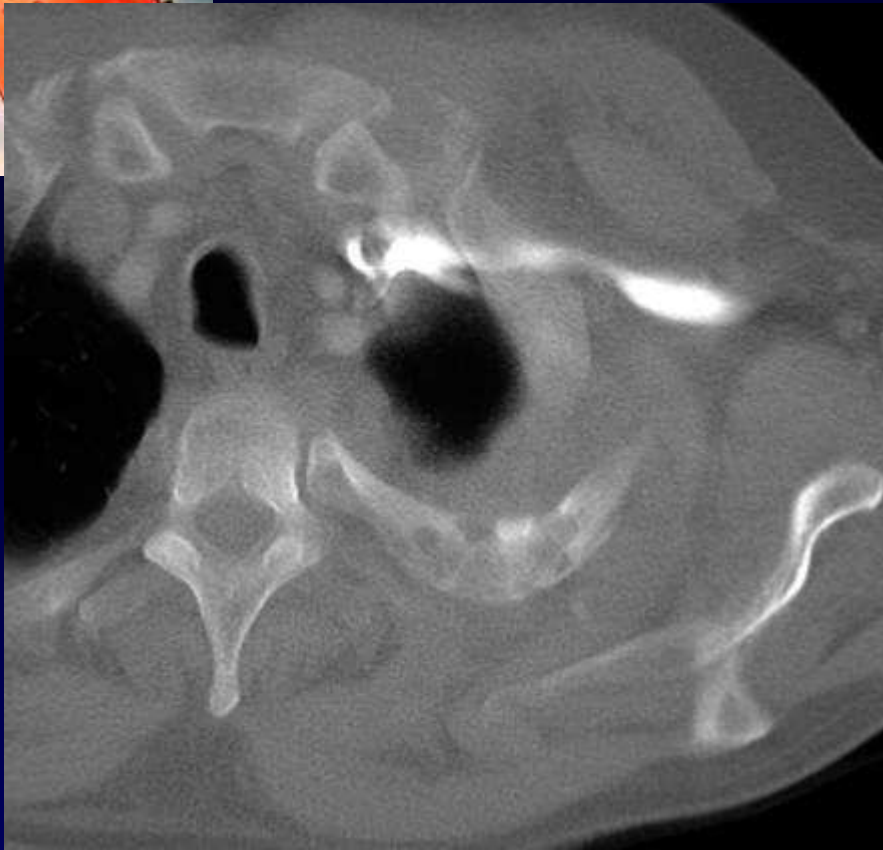
## Dossier 11

L METGE

Homme de 54 ans

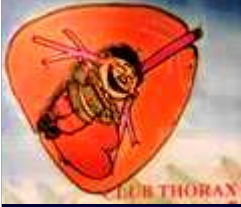Douleur et masse cervicale



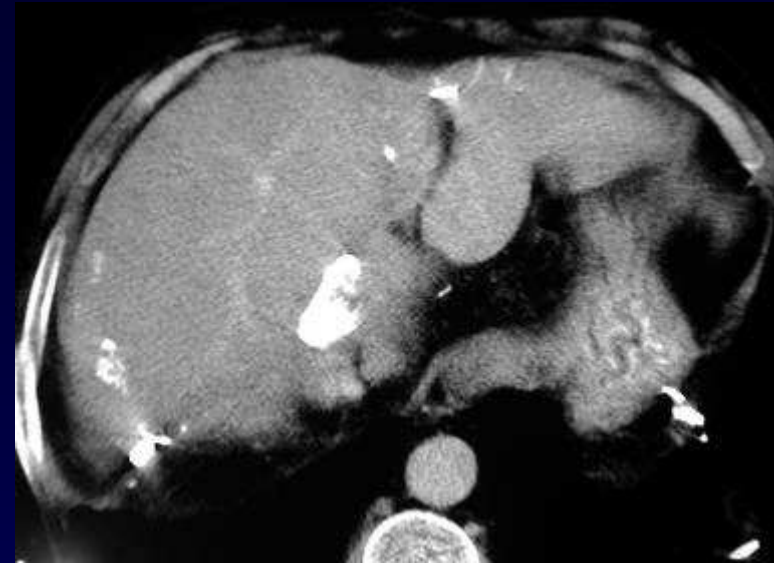




**Diagnostic ?**



## Diagnostic



**Hydatidose pariétale, des parties molles  
et costale chez un patient aux antécédents  
de kystes hydatiques hépatiques**

**Codage :paroi- infectieux**