

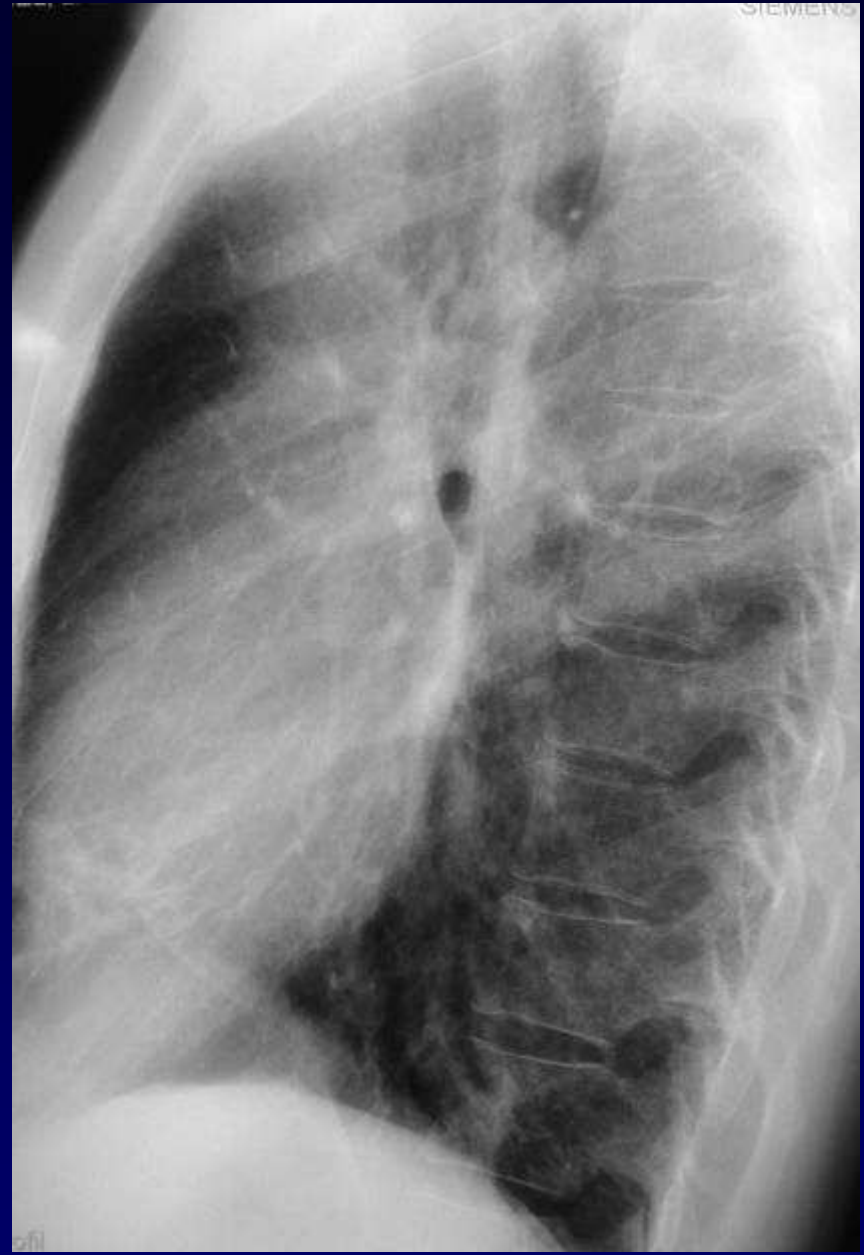
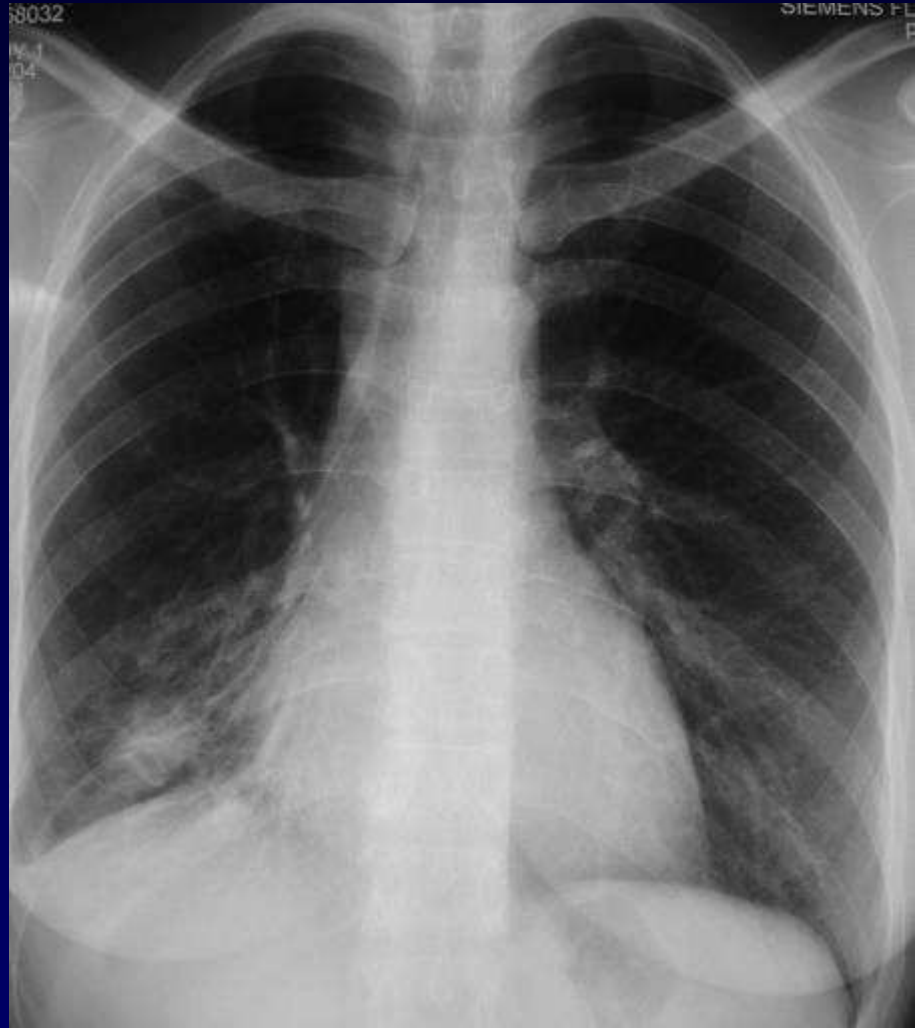
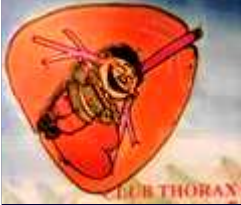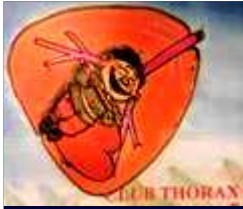DOSSIER 5

A KHALIL

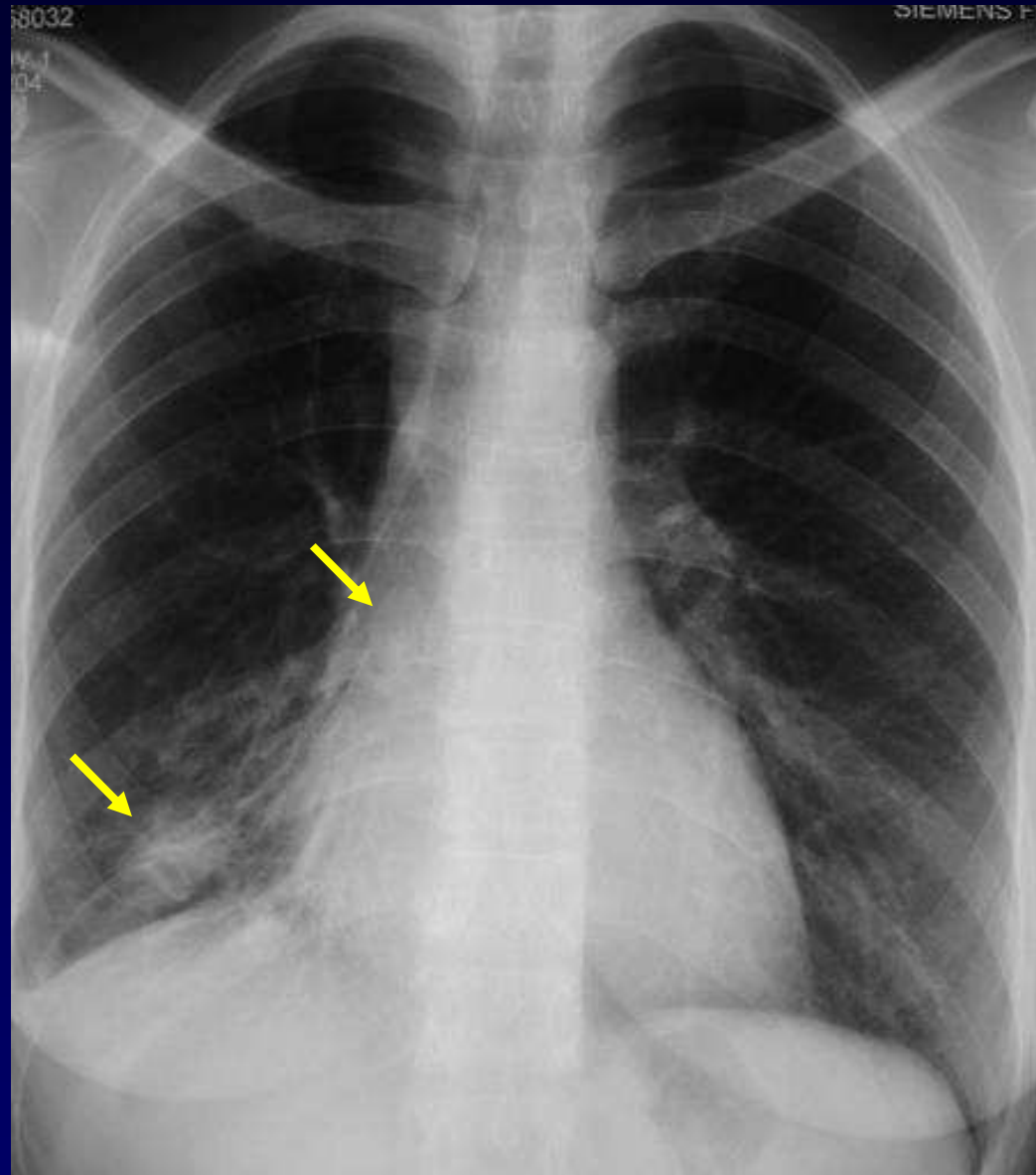
Femme de 41 ans

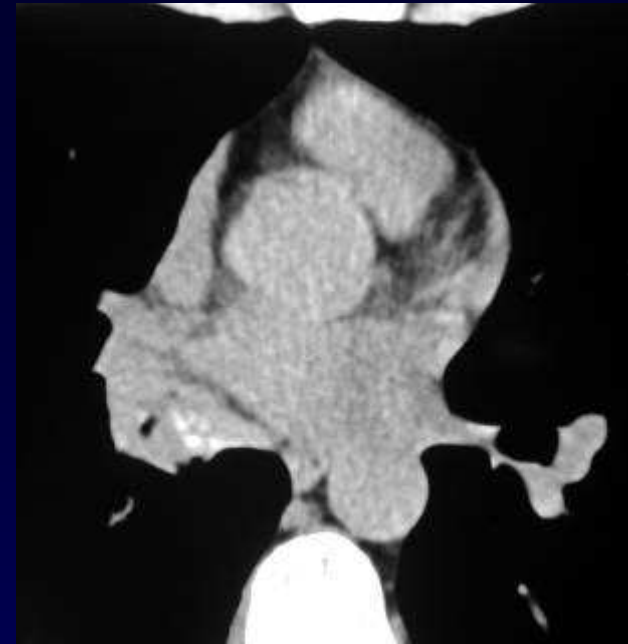
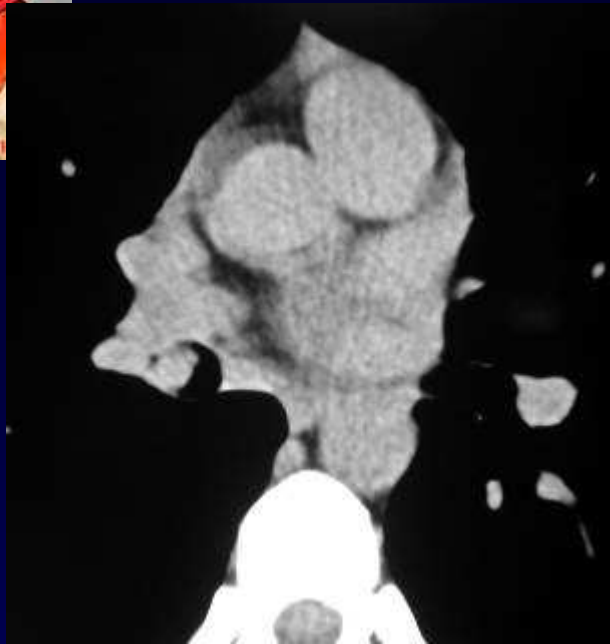
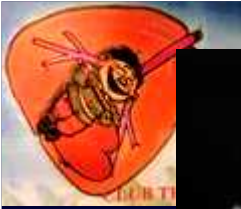**Bilan de surinfections broncho-pulmonaires
à répétition**



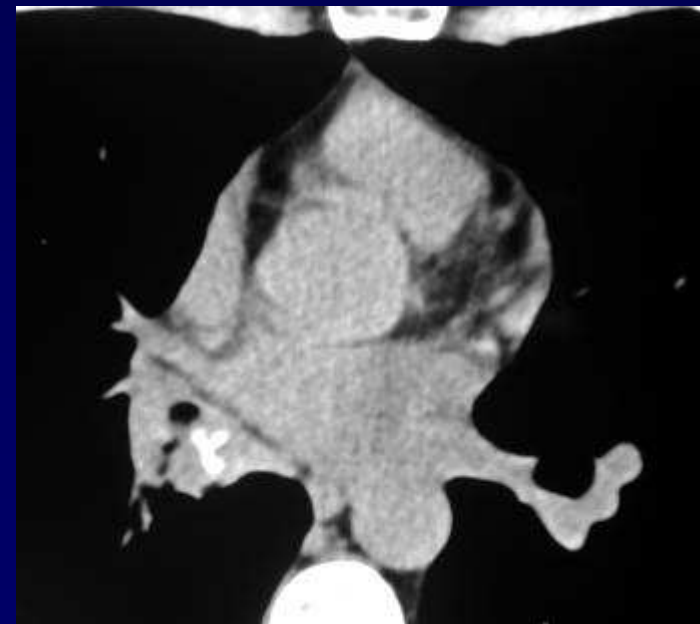
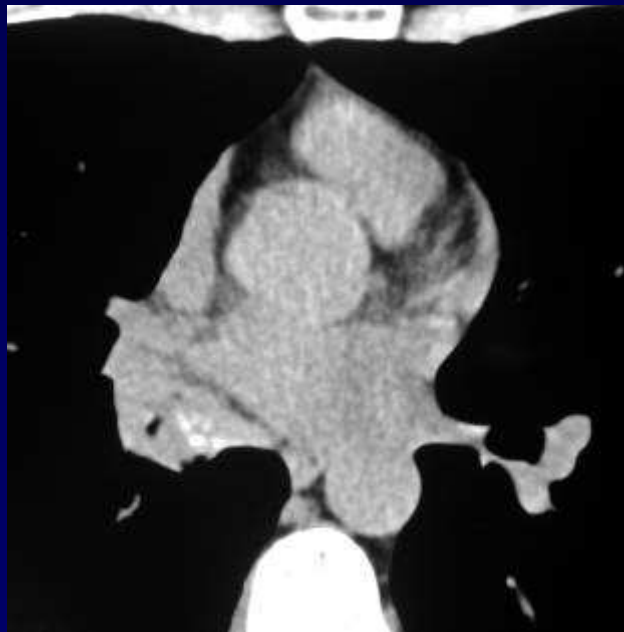


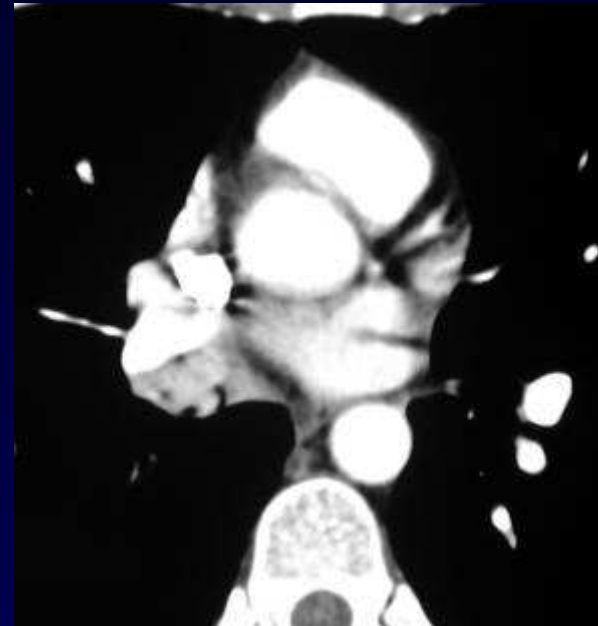
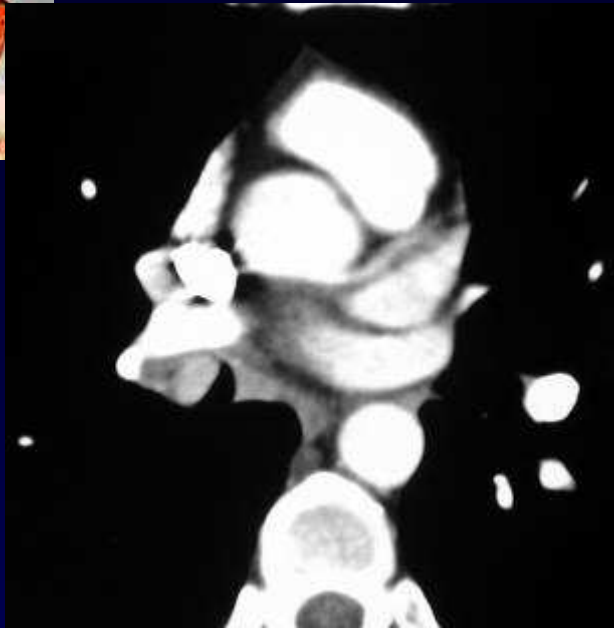
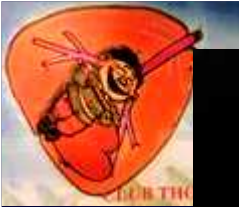Une petite aide ?



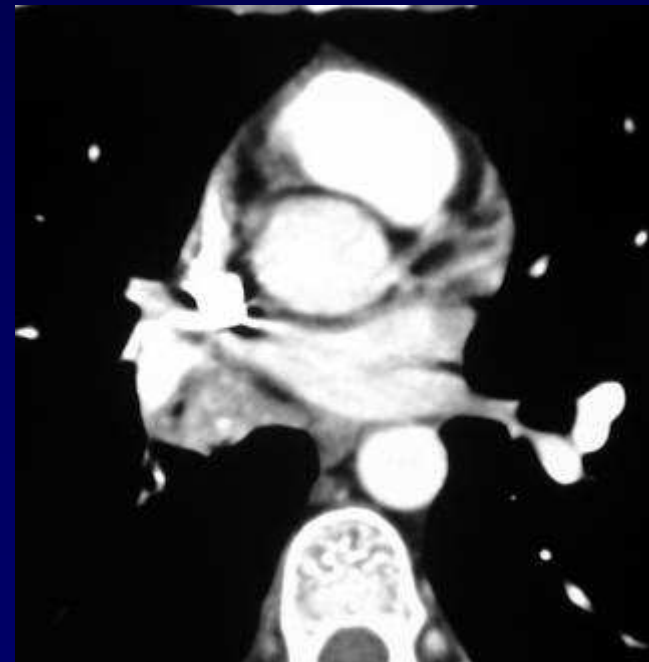


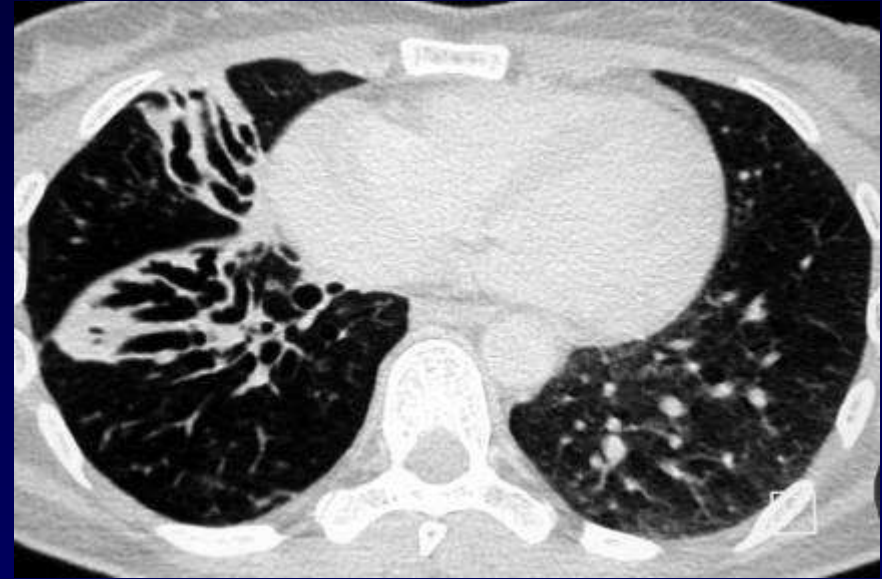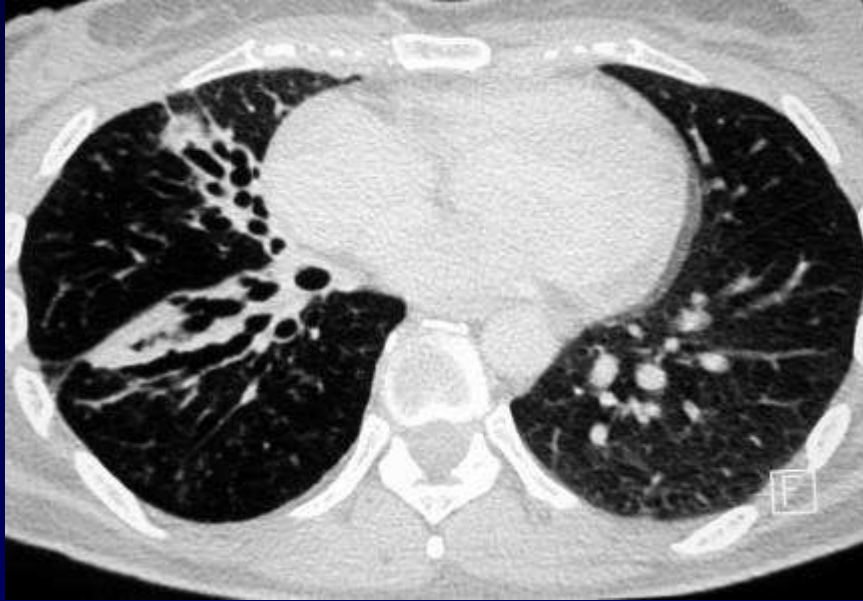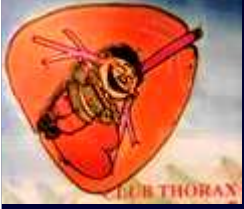TDM sans injection de produit de contraste

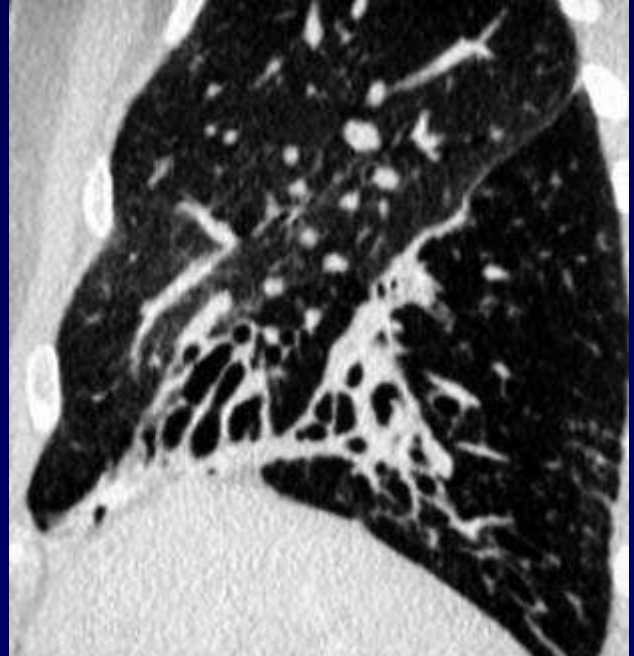
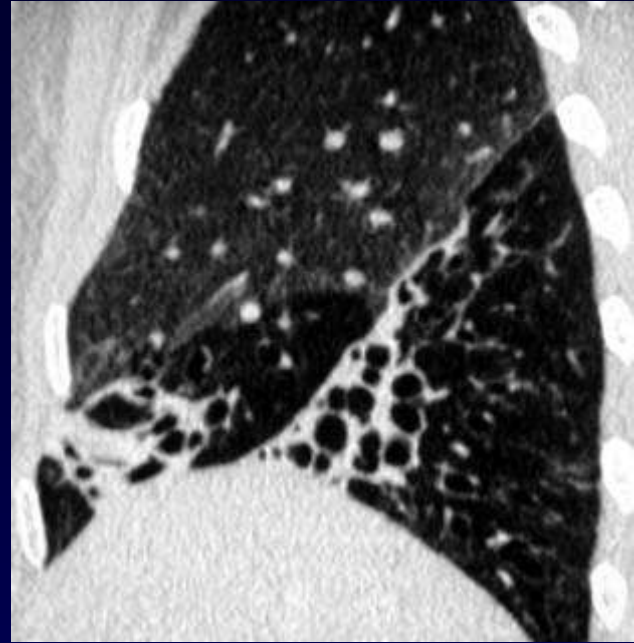
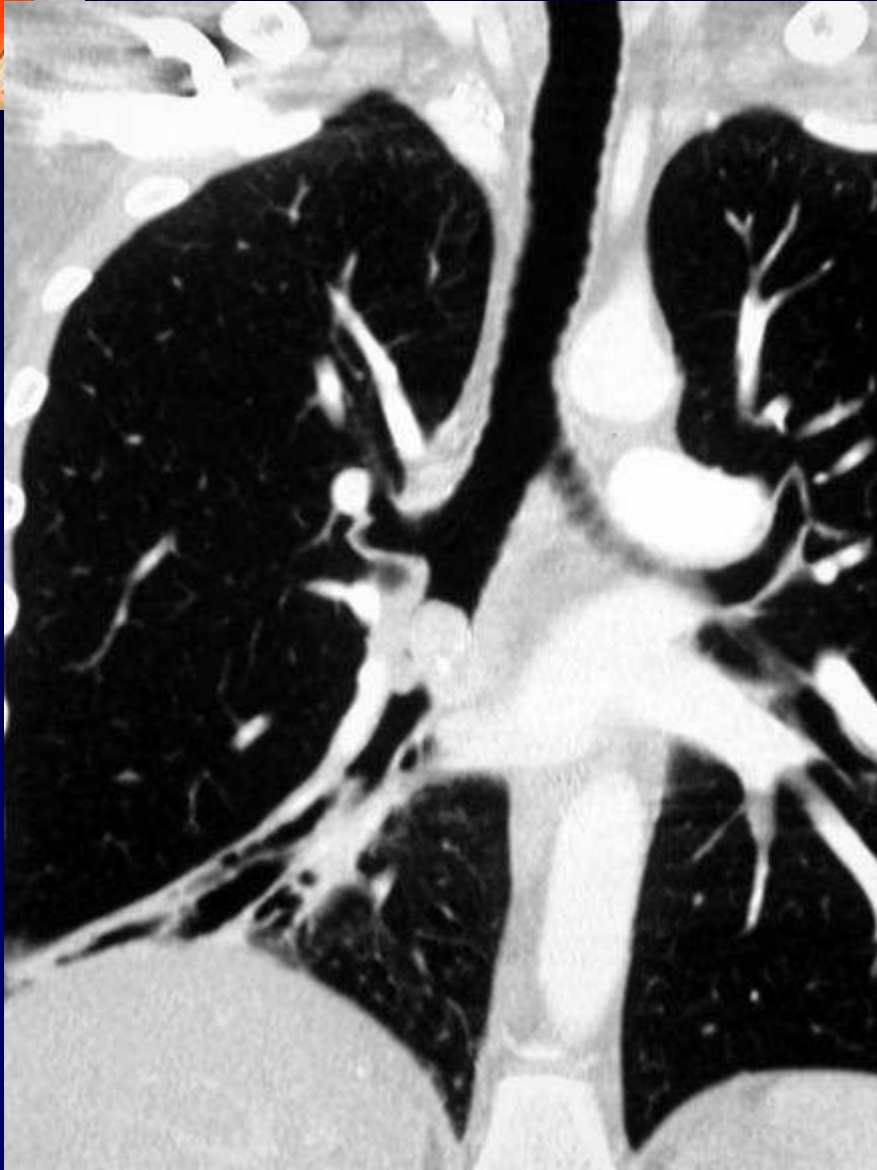



**TDM avec injection de produit de
contraste**

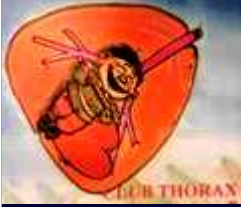







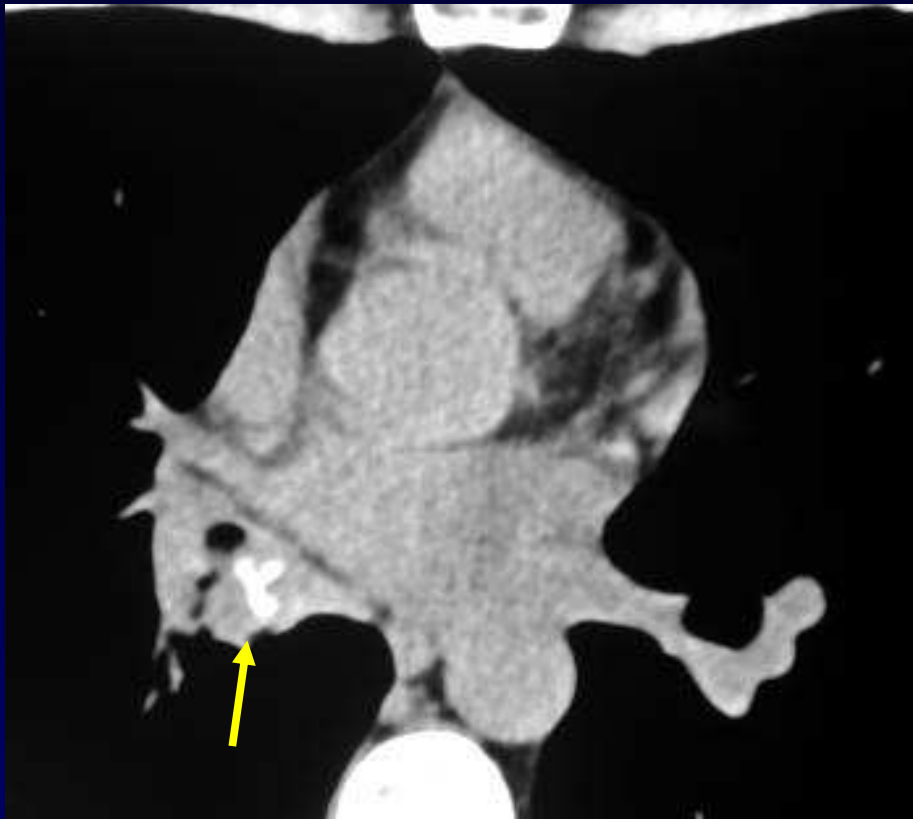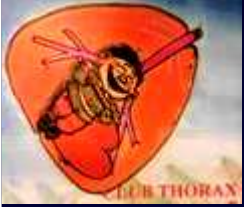Diagnostic ?



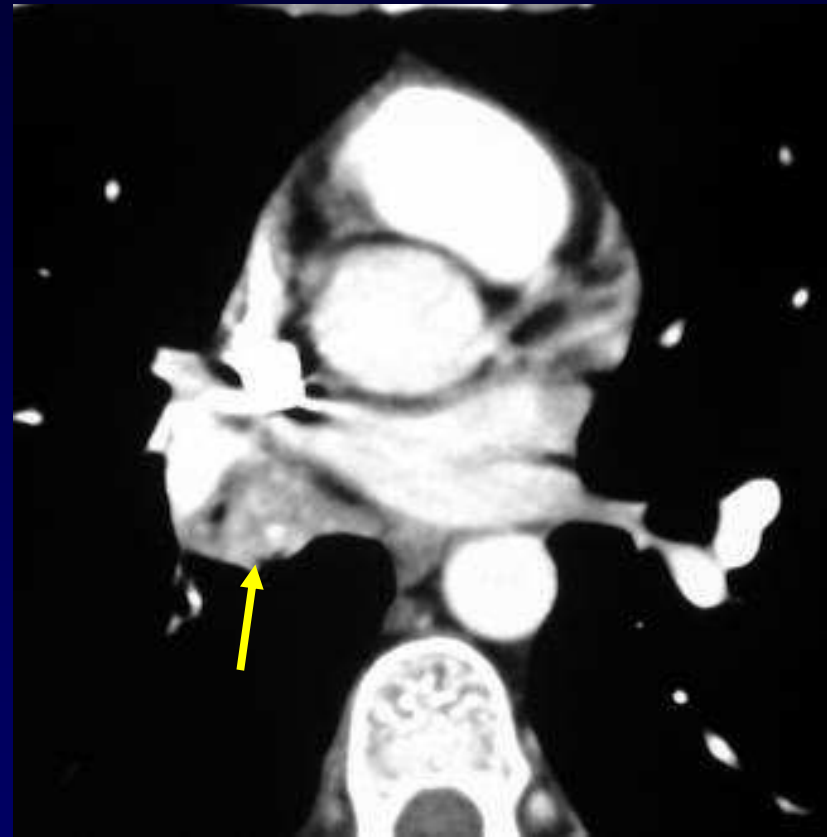
Diagnostic

**Tumeur endo-luminale du tronc
intermédiaire, partiellement calcifiée
et rehaussée après injection de
produit de contraste**

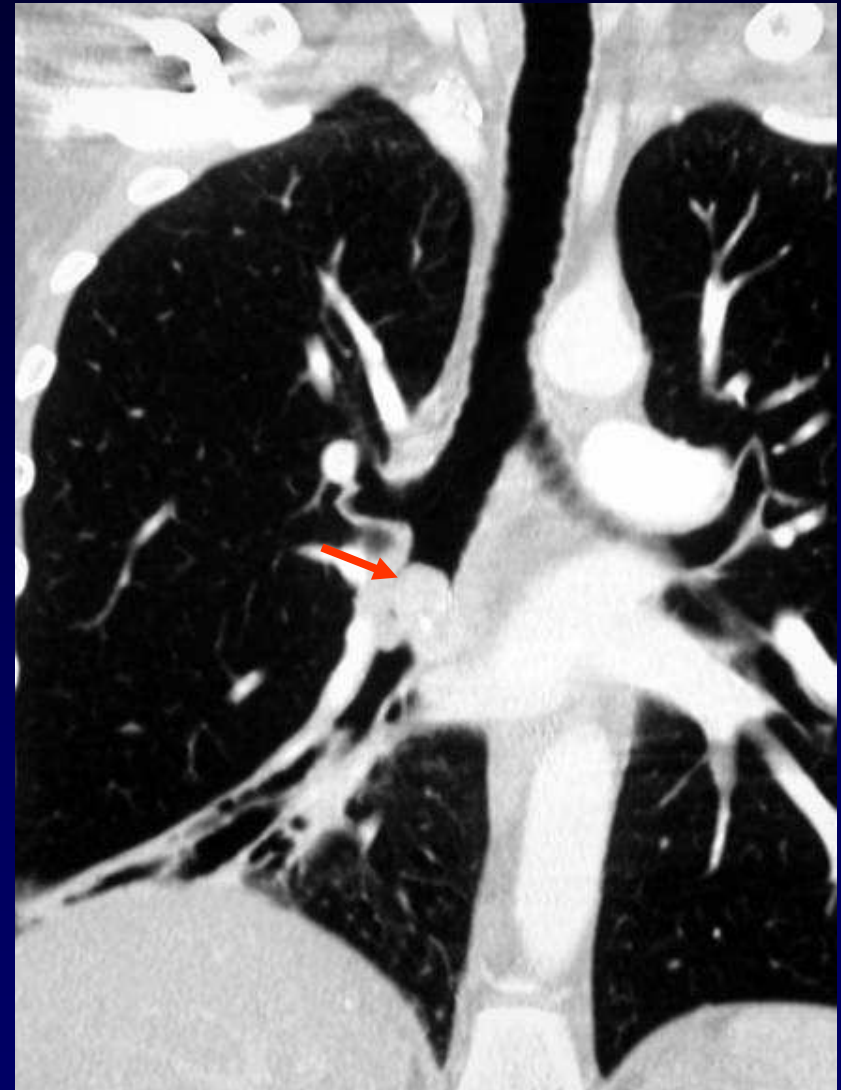
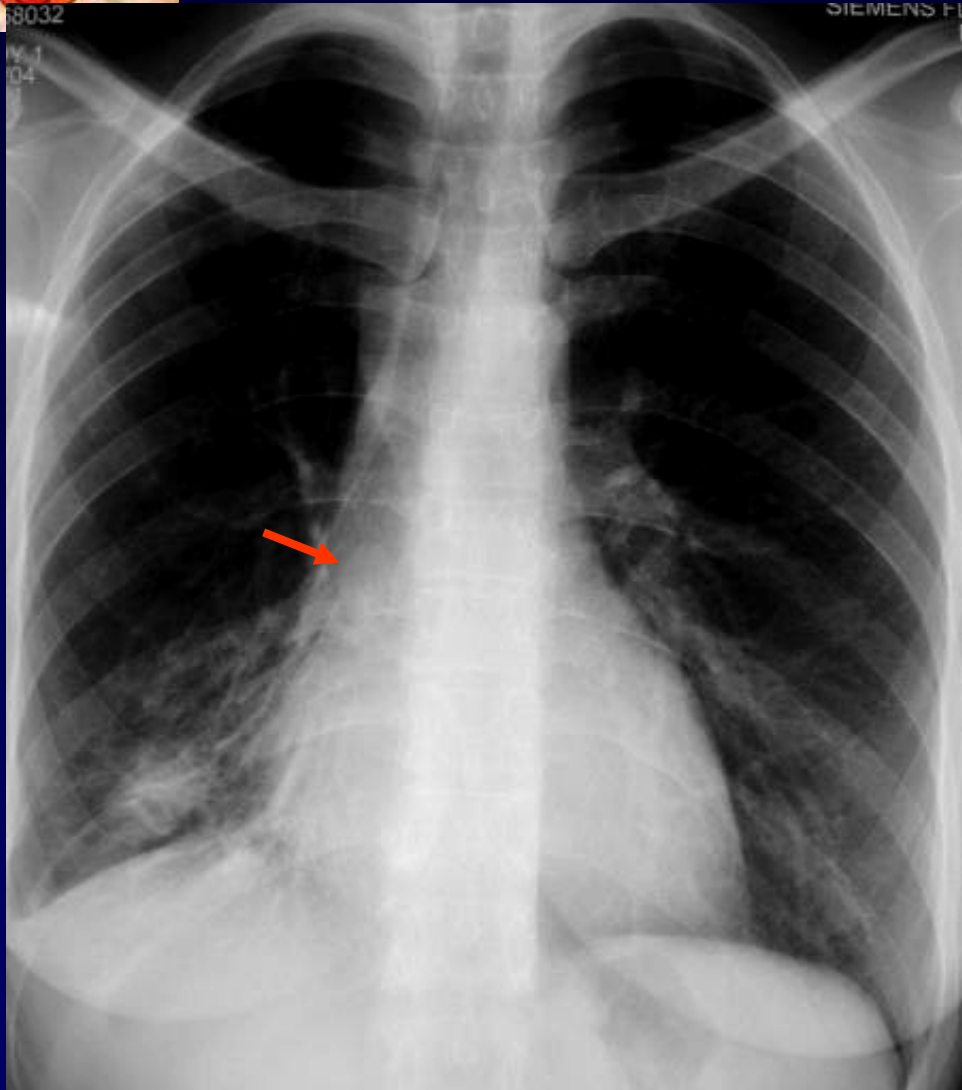
TUMEUR CARCINOÏDE



TDM sans injection



TDM après injection



Il faut avoir un œil de lynx pour voir ça sur la radio !!!