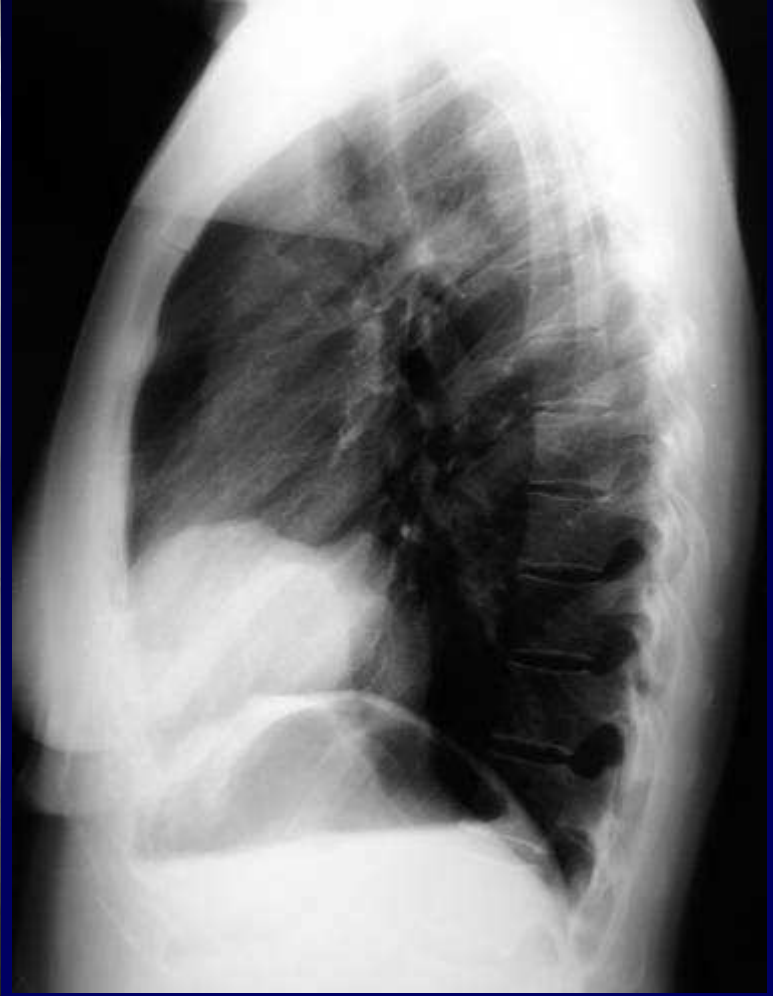
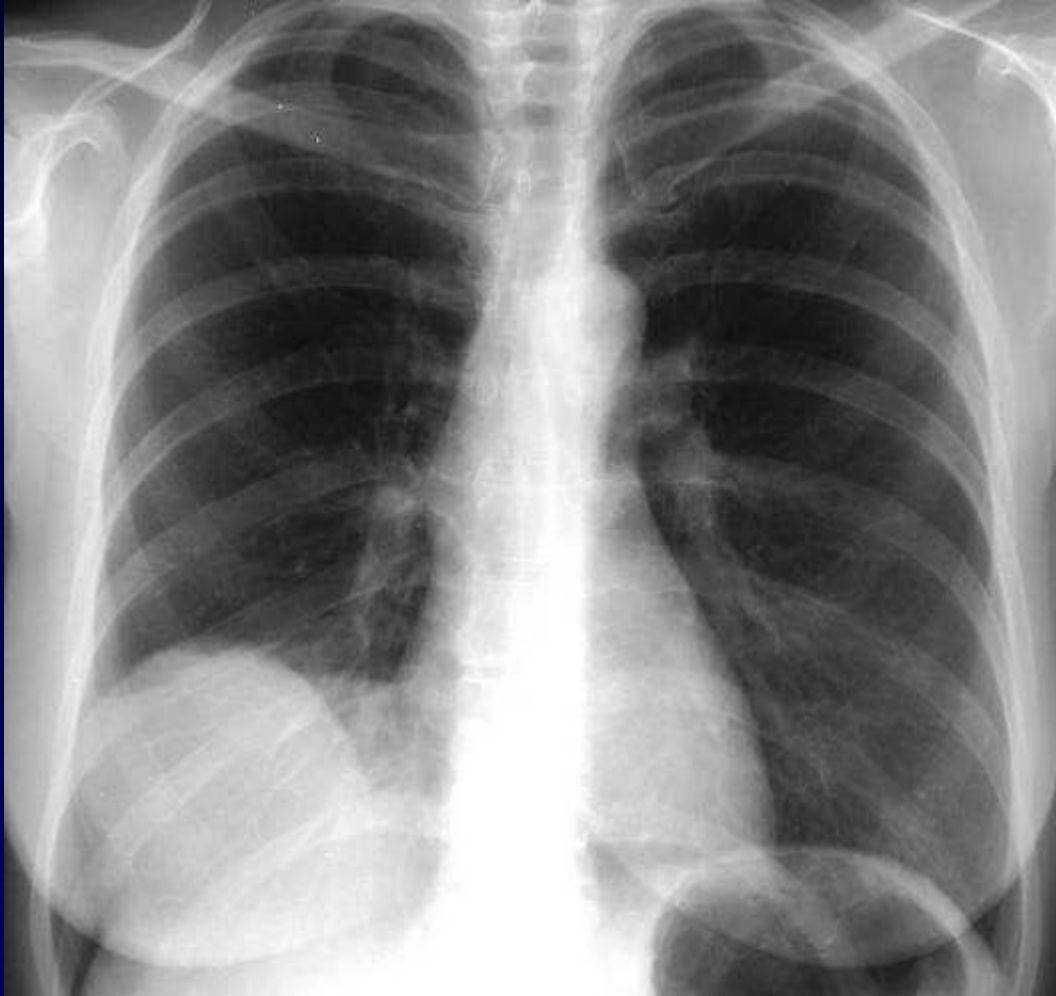



Dossier 9

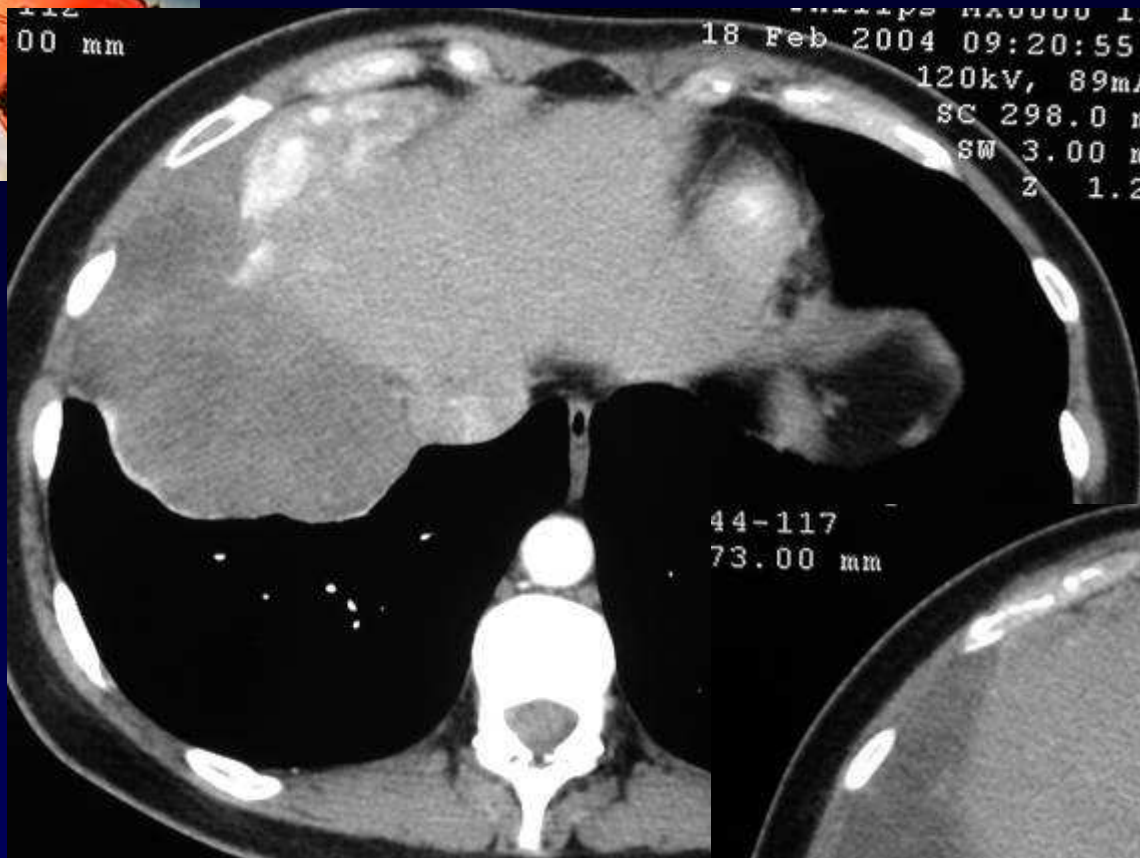P FAJADET

Femme de 54 ans,
Oppression thoracique



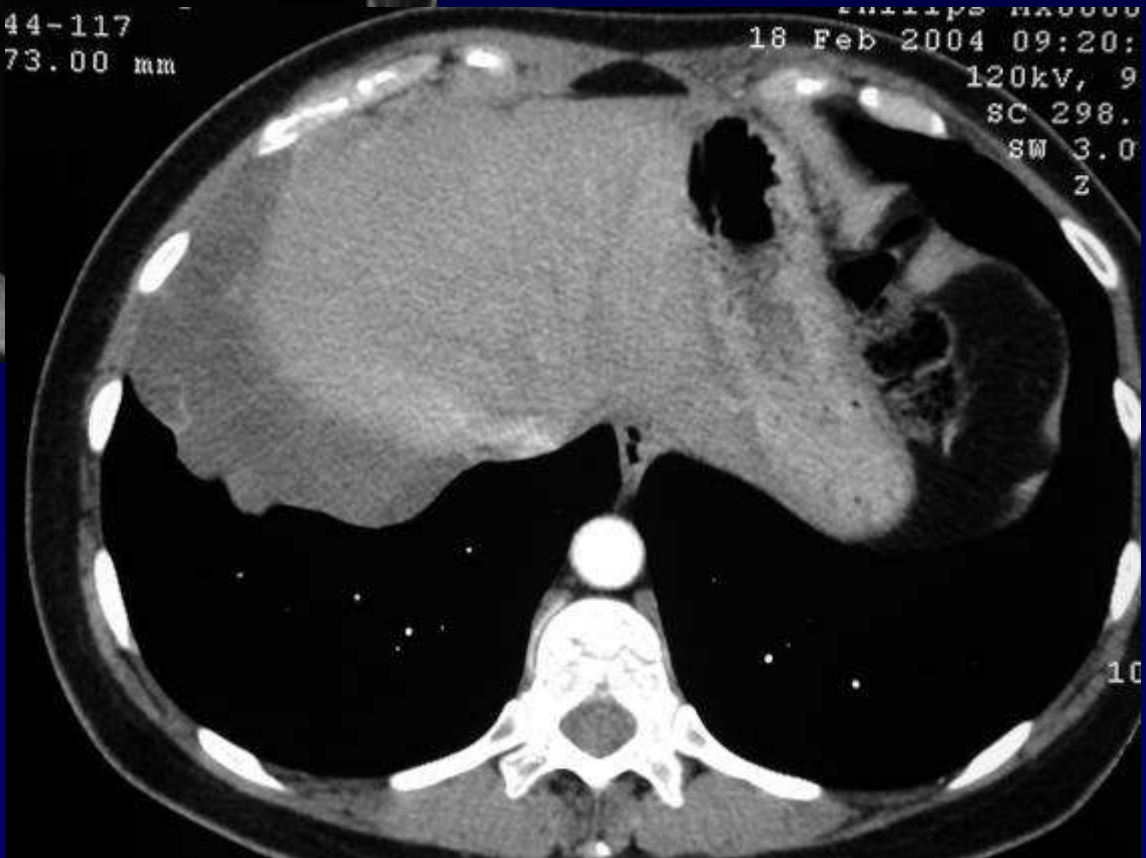


00 mm



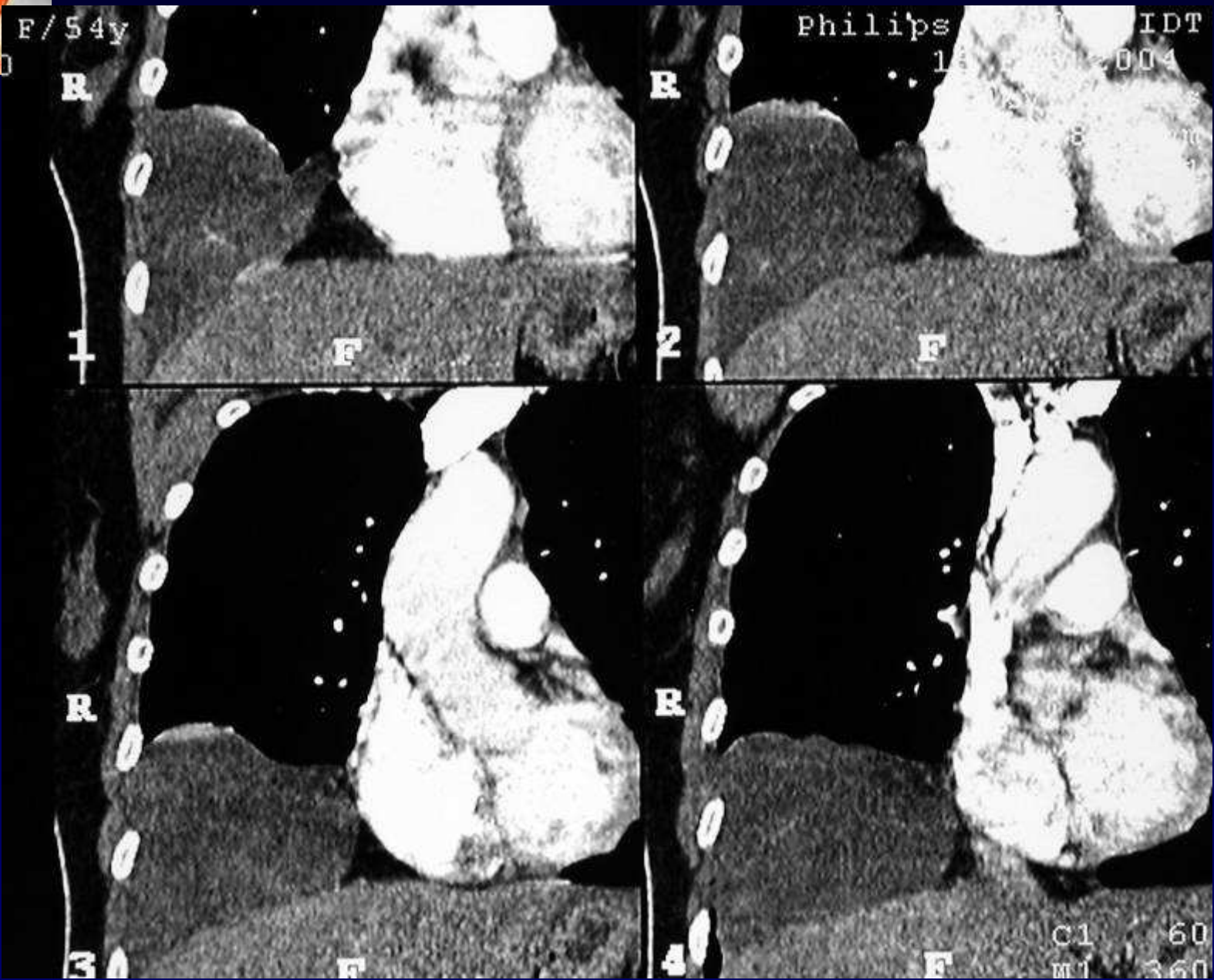
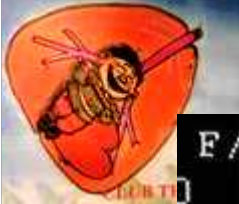18 Feb 2004 09:20:55
120kV, 89mA
SC 298.0
SW 3.00
Z 1.2

44-117
73.00 mm



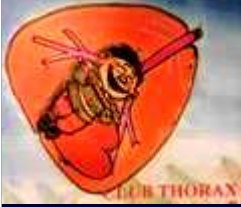18 Feb 2004 09:20:
120kV, 9
SC 298.
SW 3.0
Z

10





Diagnostic ?



Diagnostic

Léiomyosarcome myxoïde pleural

Codage : Plèvre- Tumoral malin