



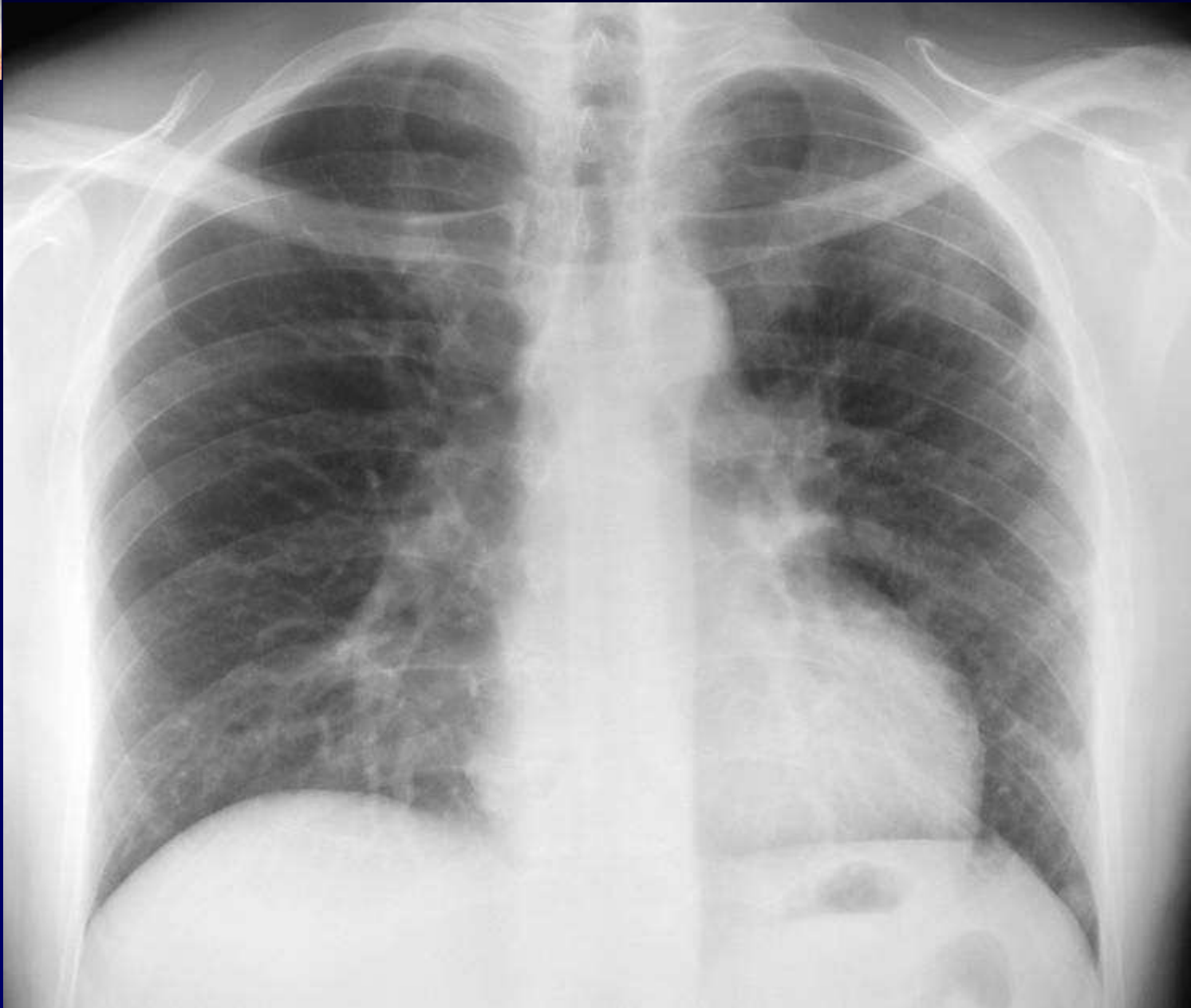
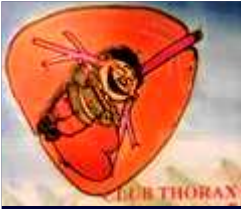Dossier 12

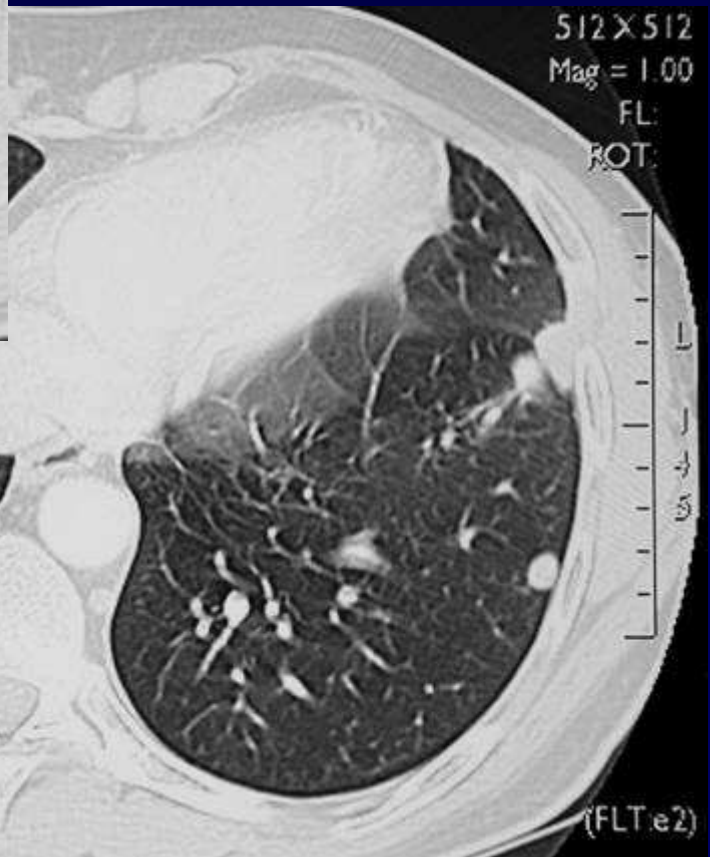
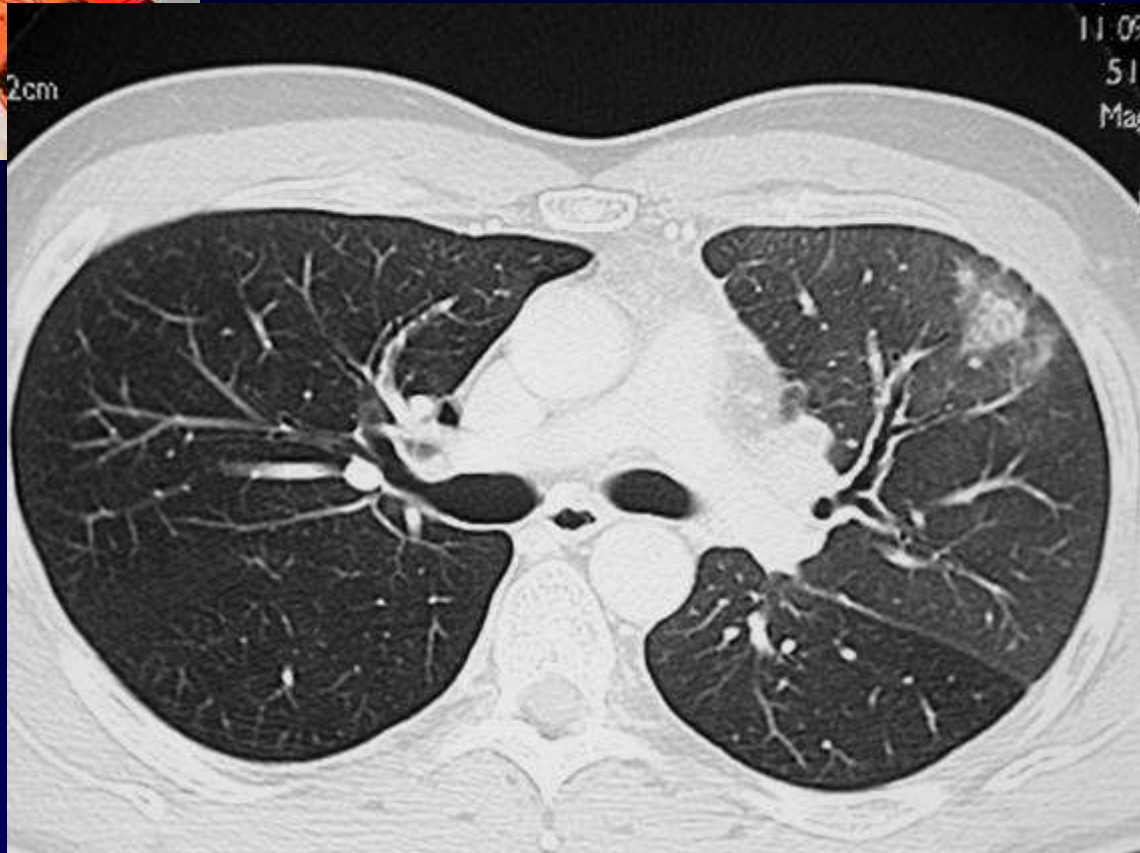D JEANBOURQUIN

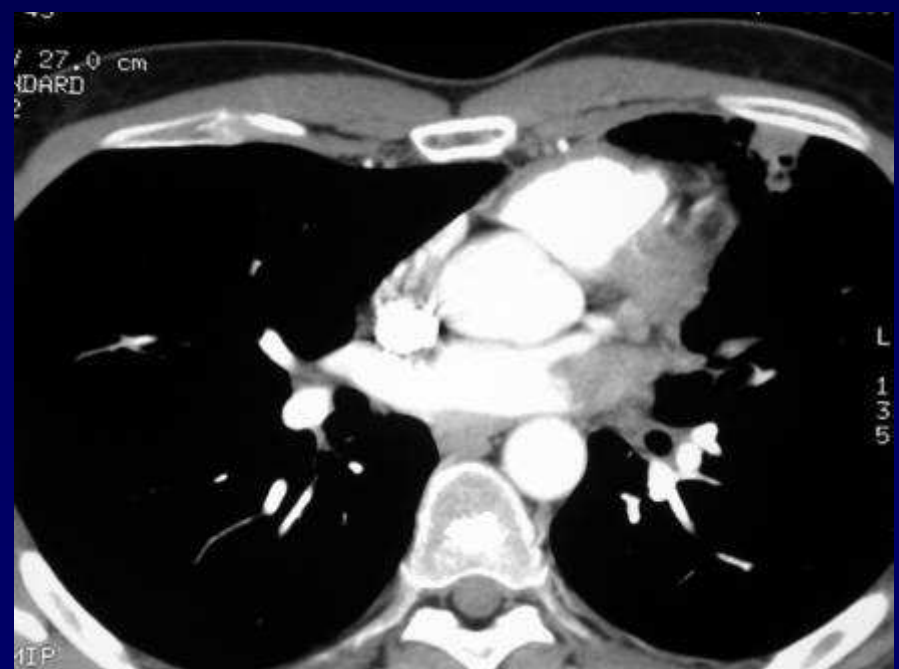
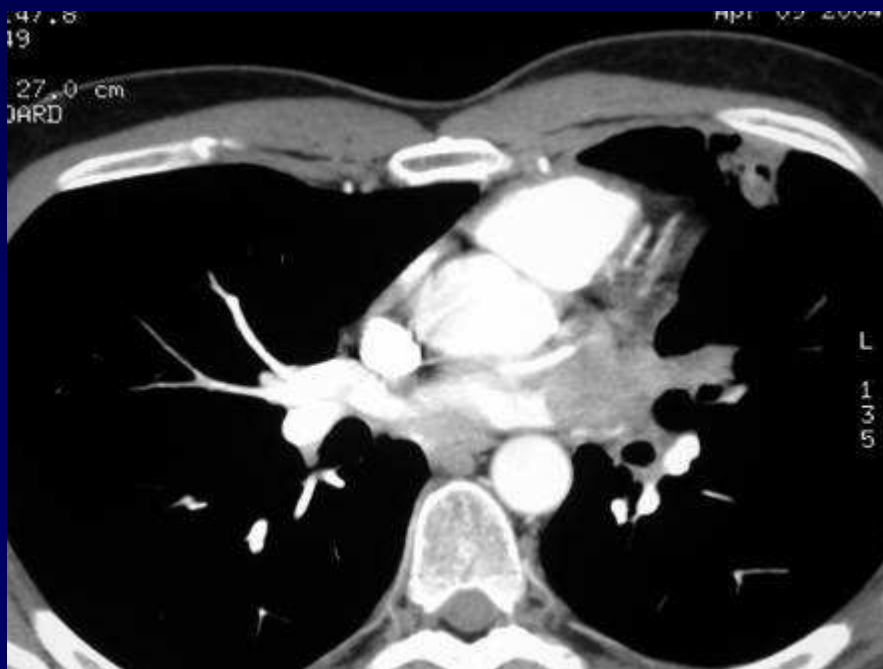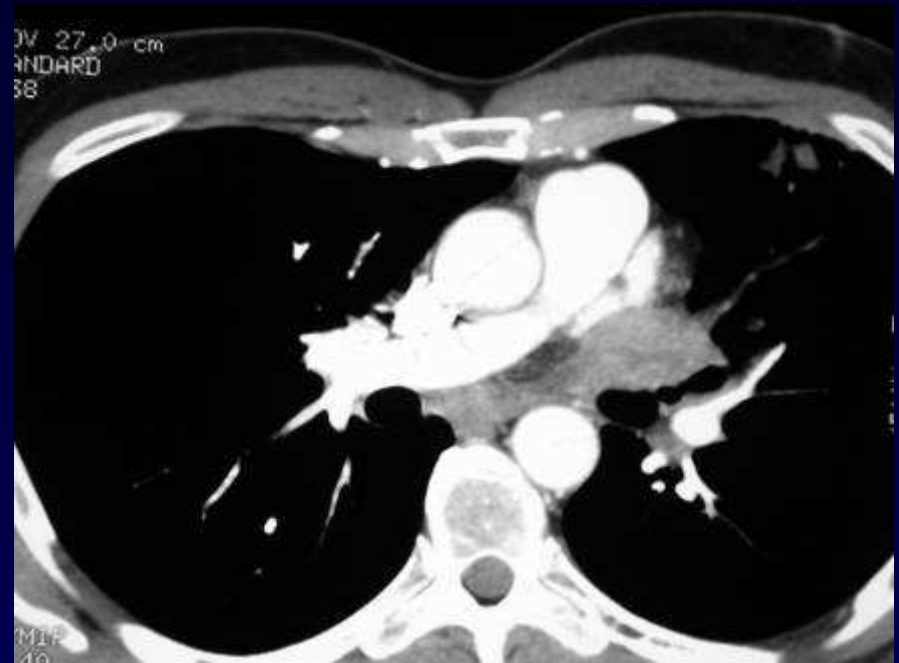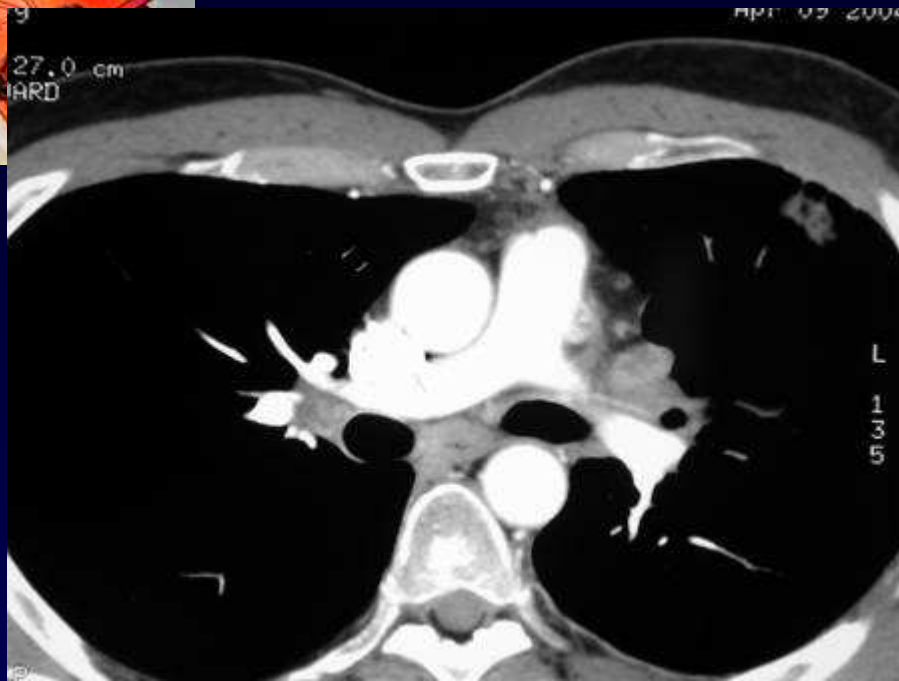
Homme de 48 ans

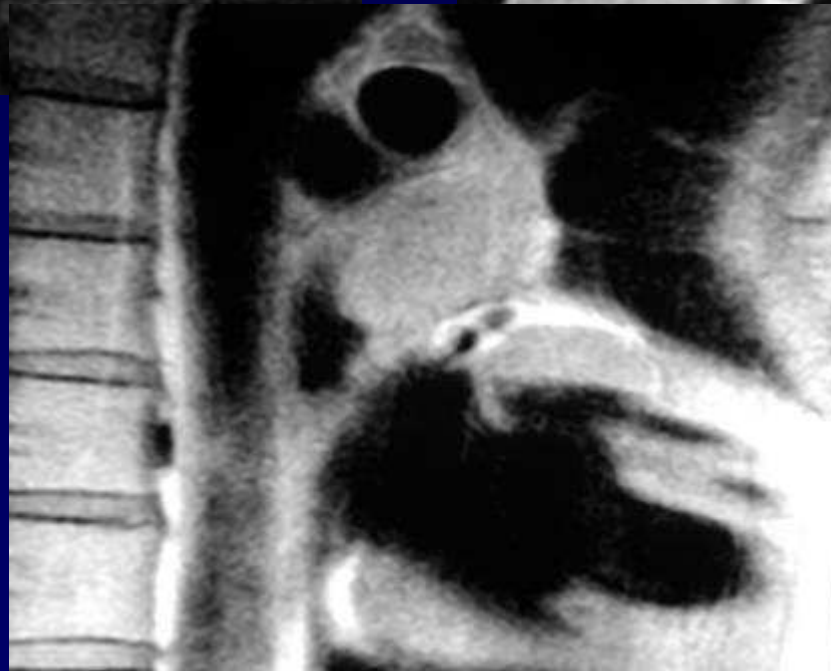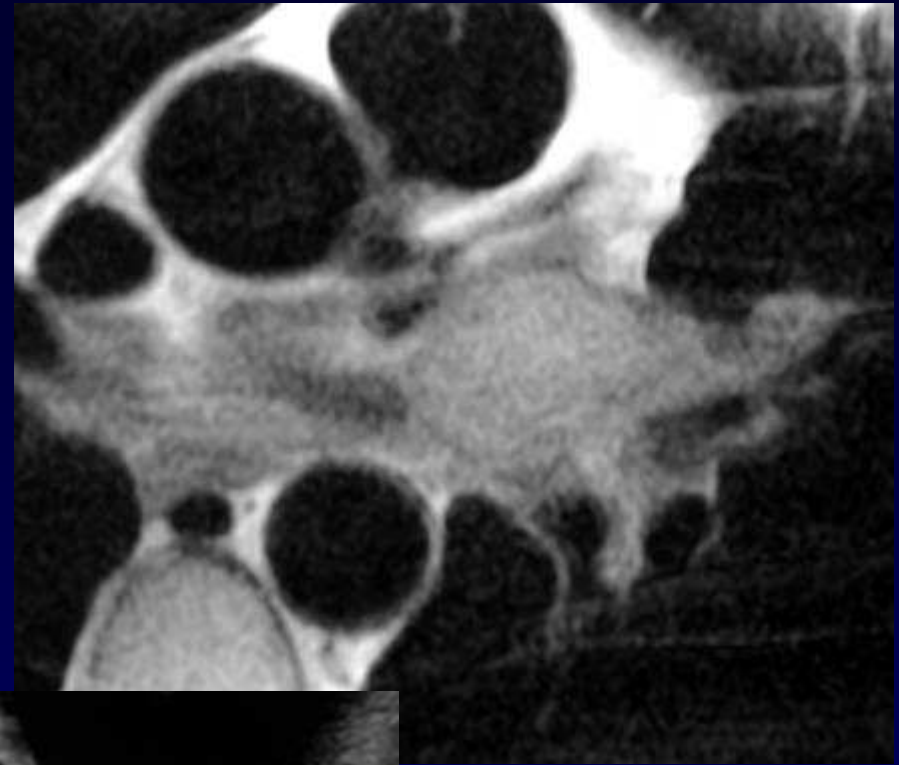
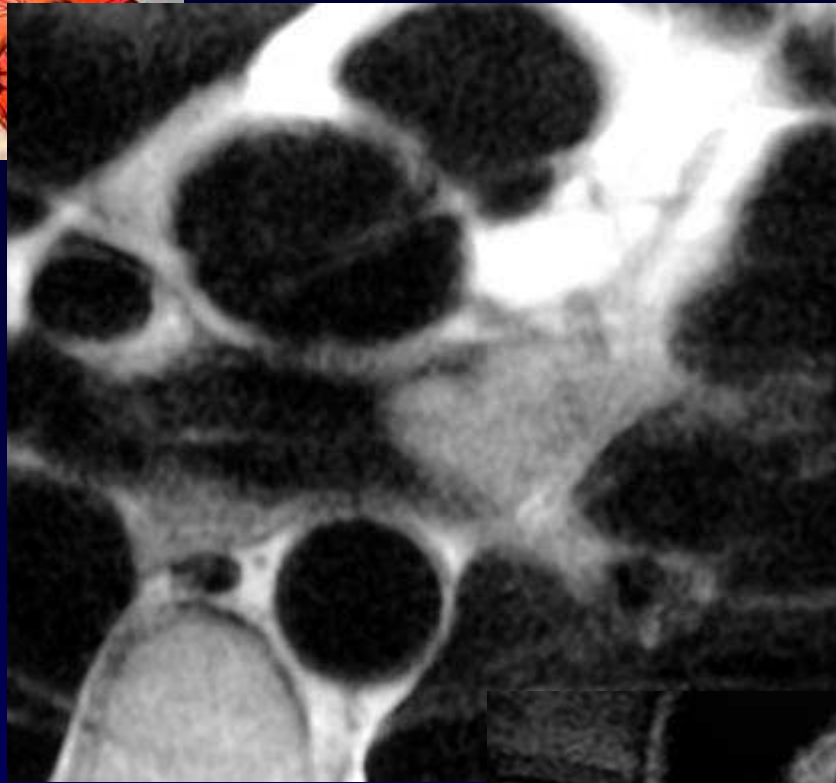
Suivi de carcinome rénal opéré,

avec métastases pulmonaires connues











Diagnostic ?



Diagnostic

**Envahissement métastatique
de la veine pulmonaire supérieure gauche,
avec aspect d'infarctus pulmonaire d'aval**

Codage : cardiovasculaire – Tumoral malin