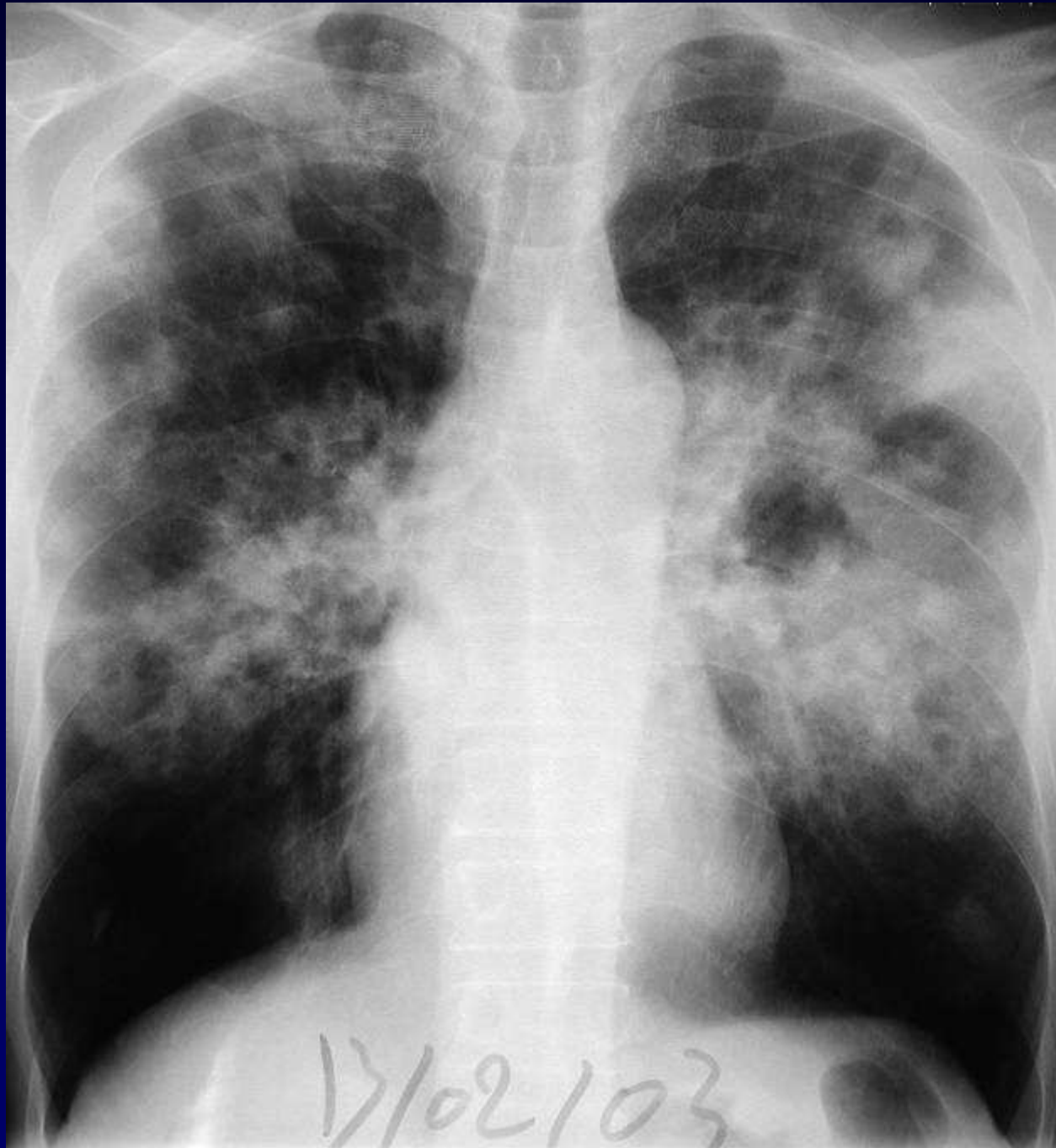

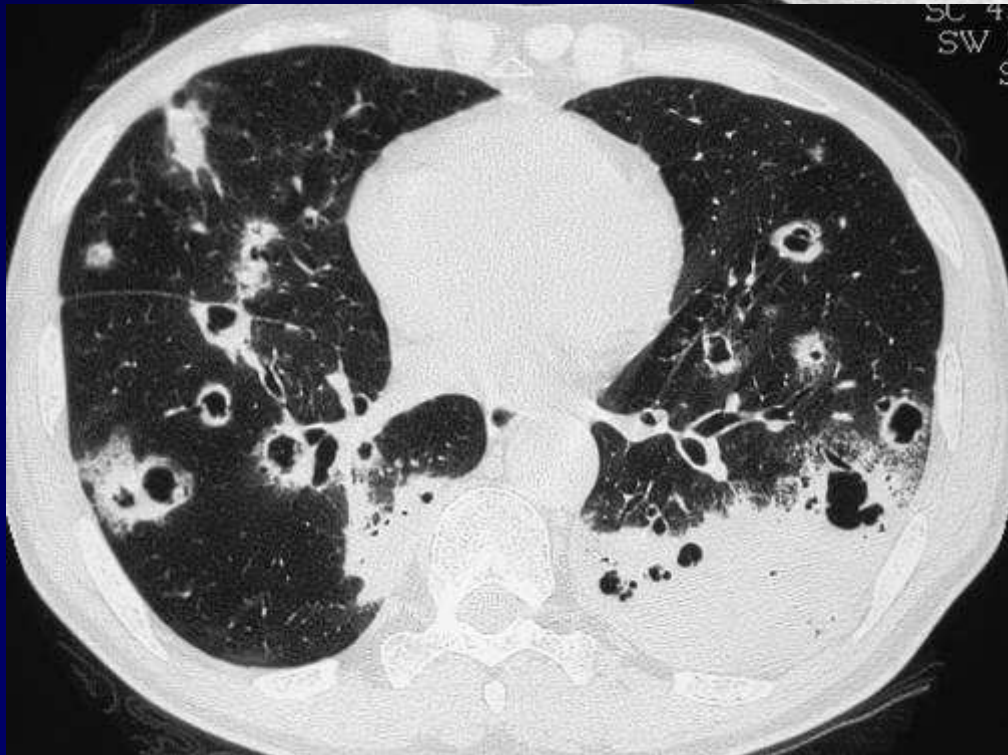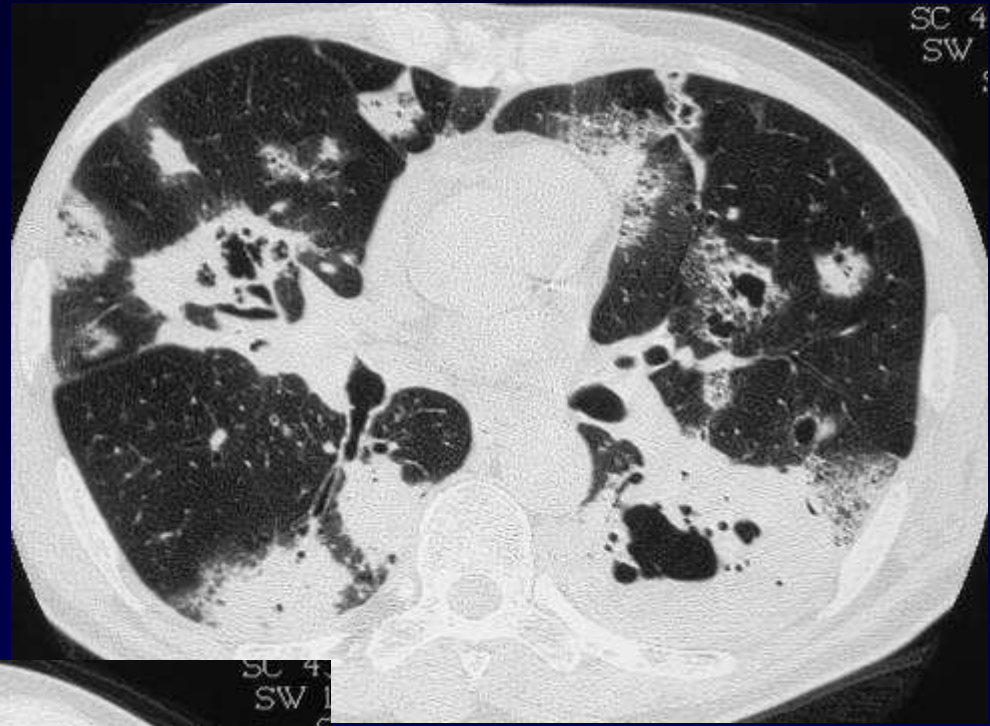
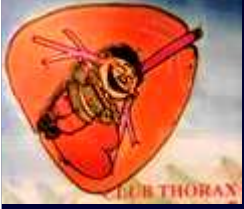

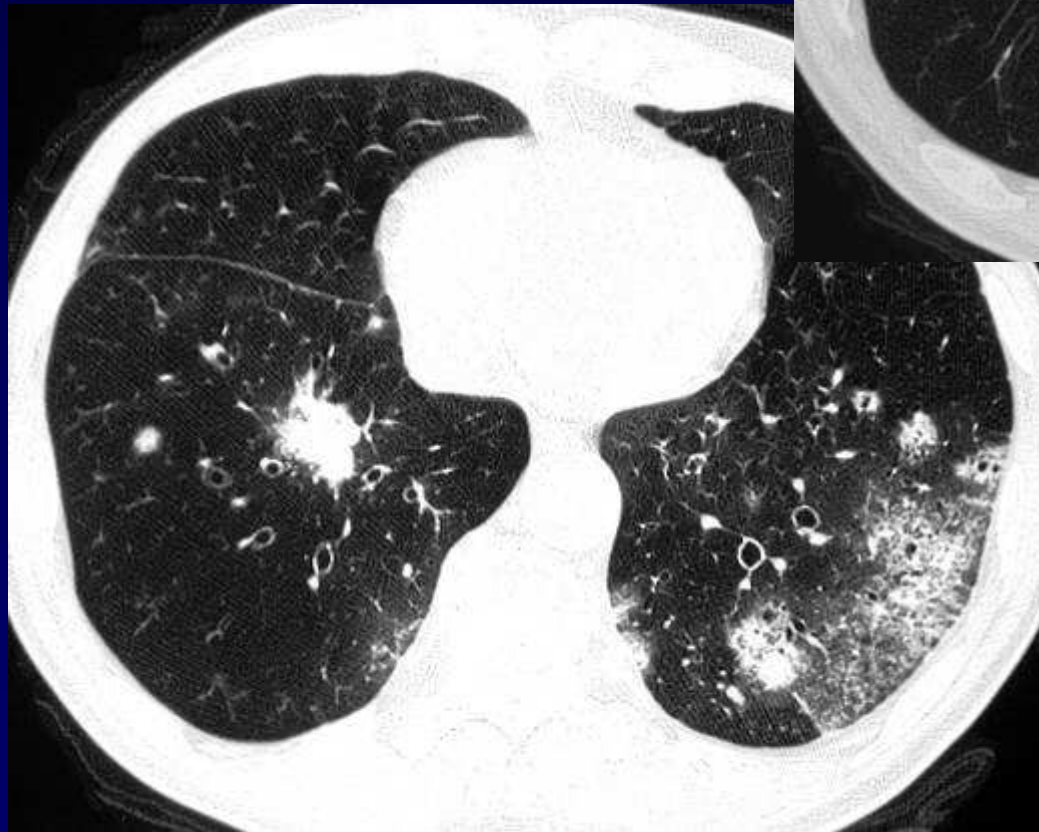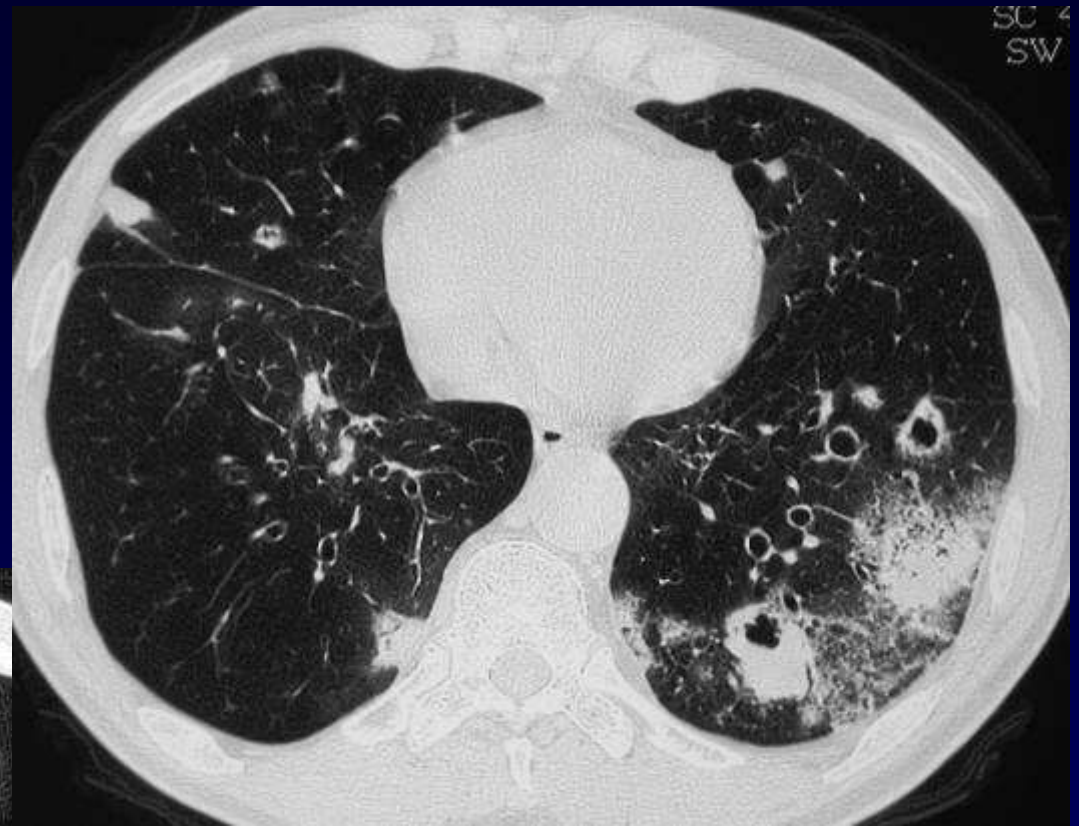
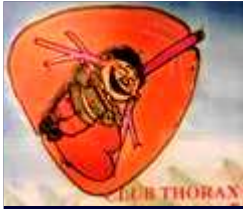## Dossier 14

**M EL HAJJAM**

Homme de 69 ans,  
Altération de l'état général,







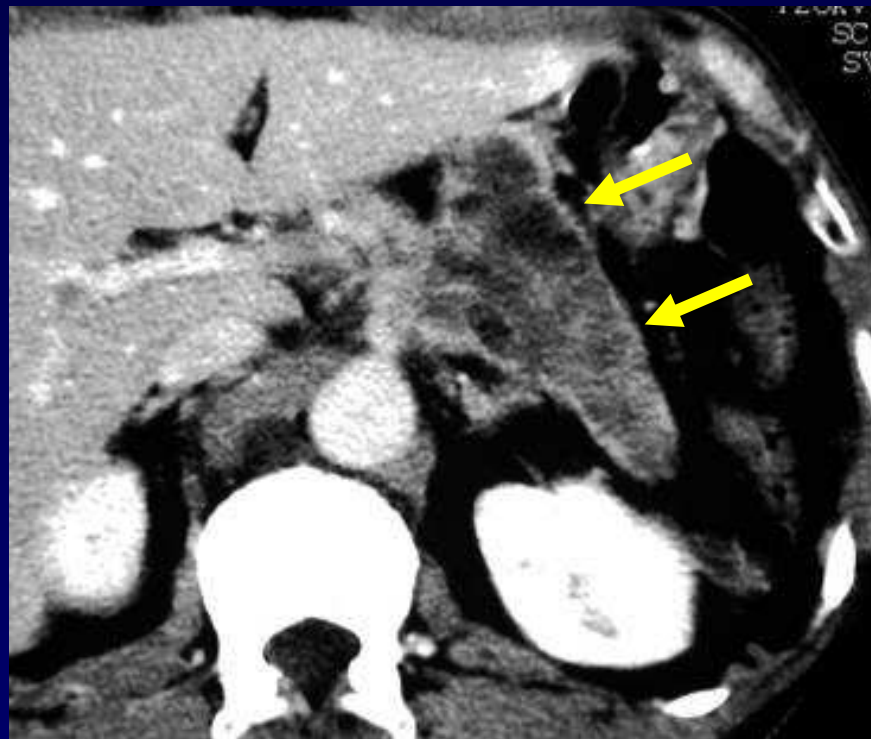


**Diagnostic ?**



## Diagnostic

# Métastases pulmonaires excavées d'un cancer du pancréas





**Aggravation  
à 2 mois**

