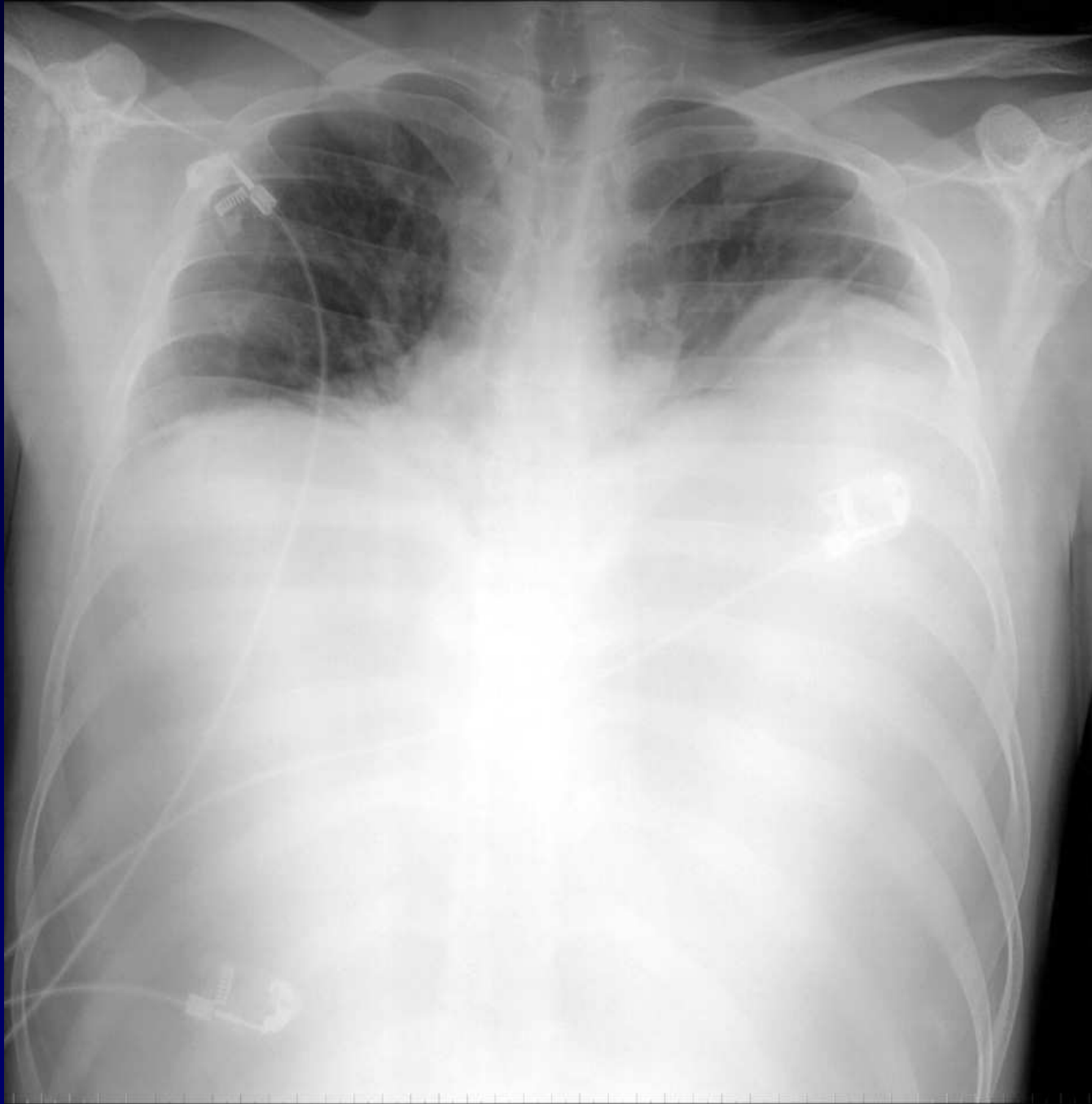

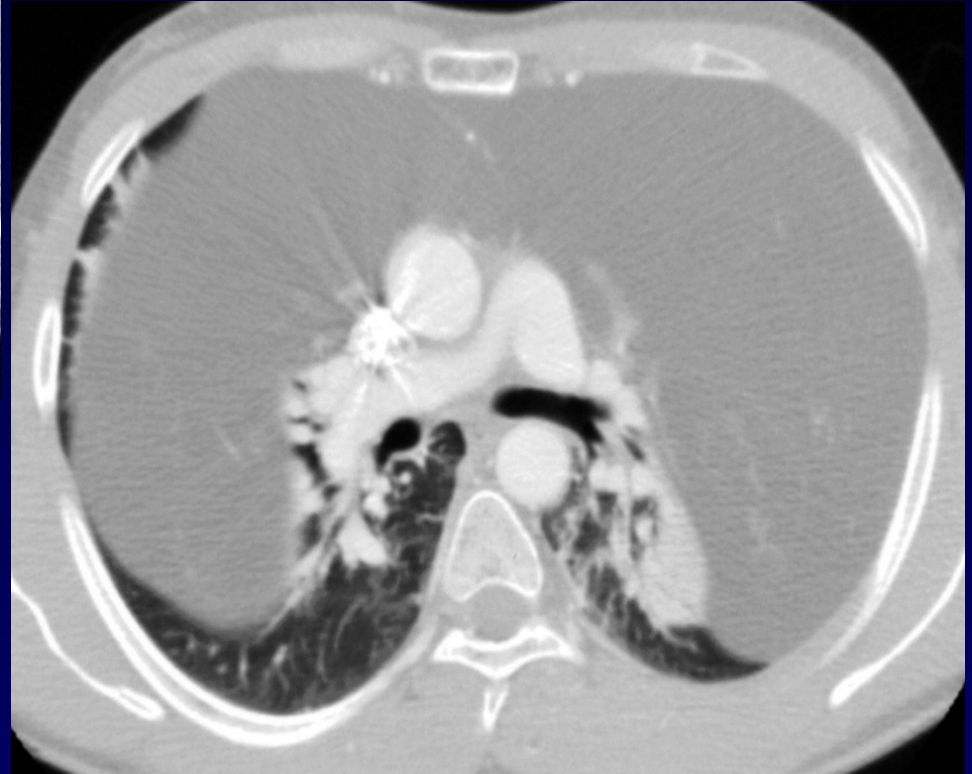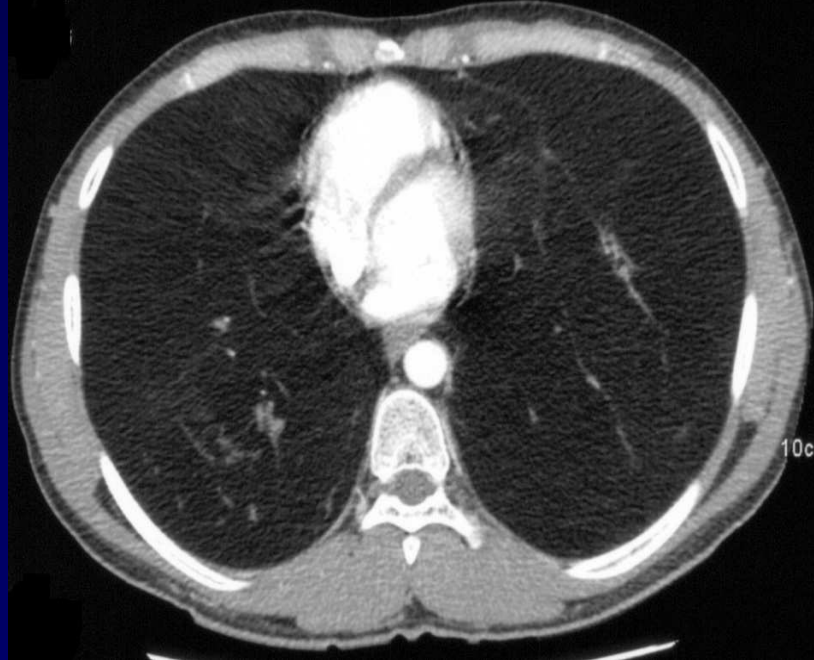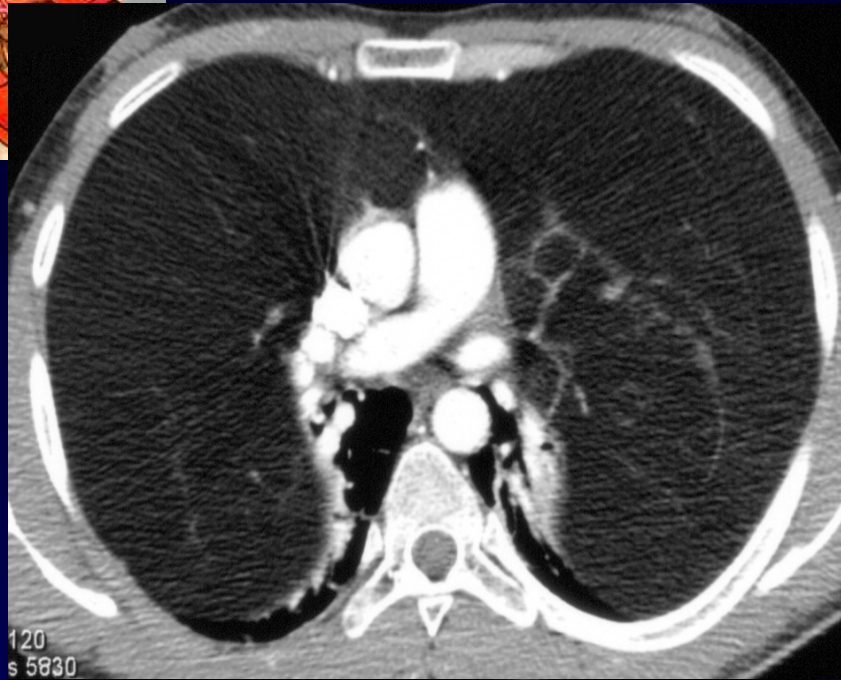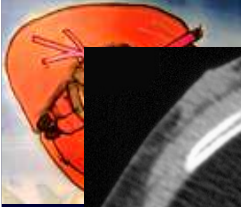


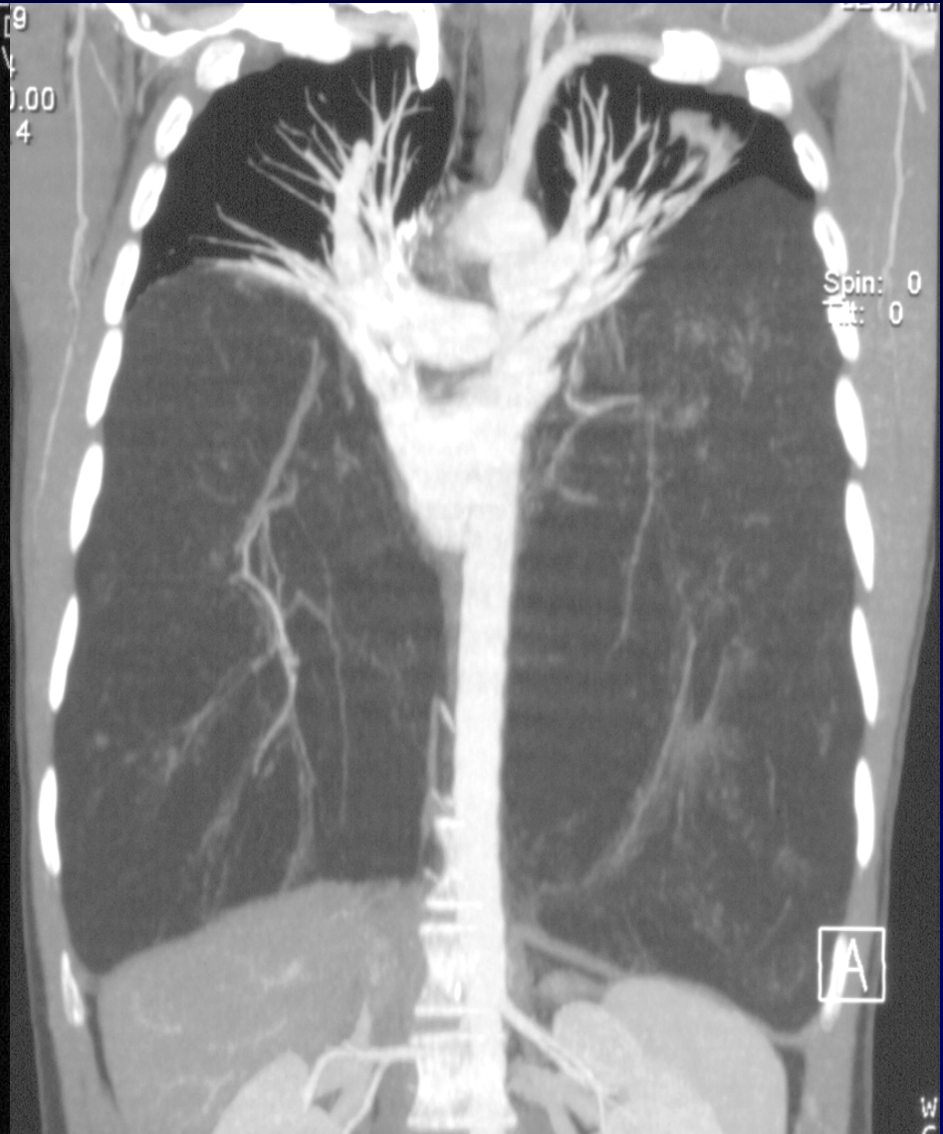
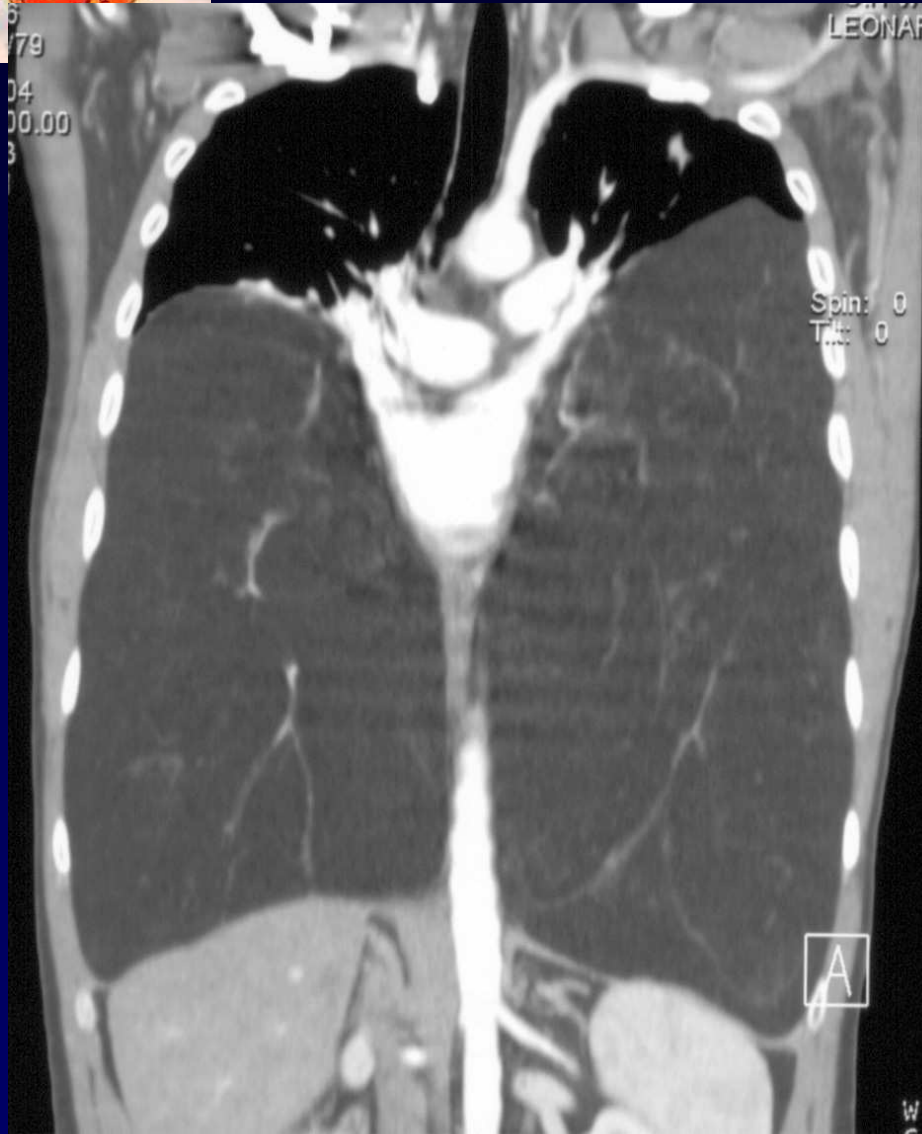## Dossier 6

**G. FERRETTI**

- Homme de 24 ans
- Sédentaire, non tabagique
- Hospitalisation pour détresse respiratoire







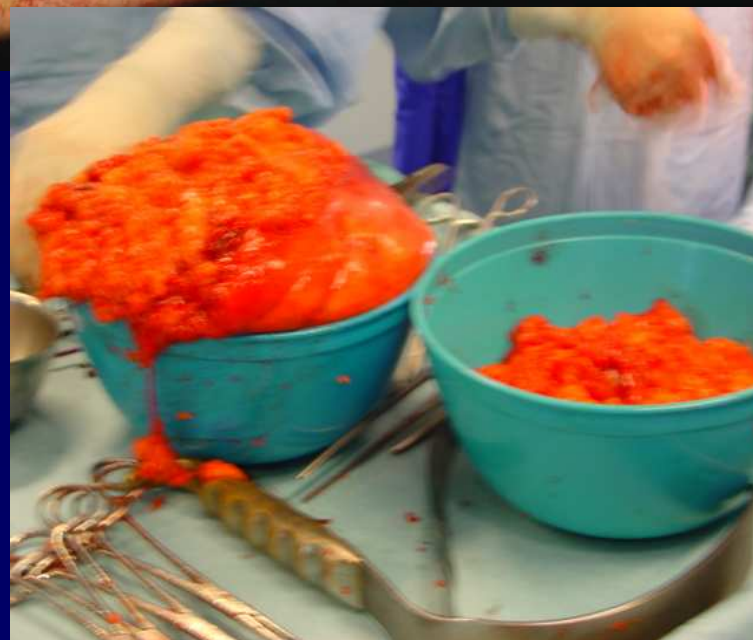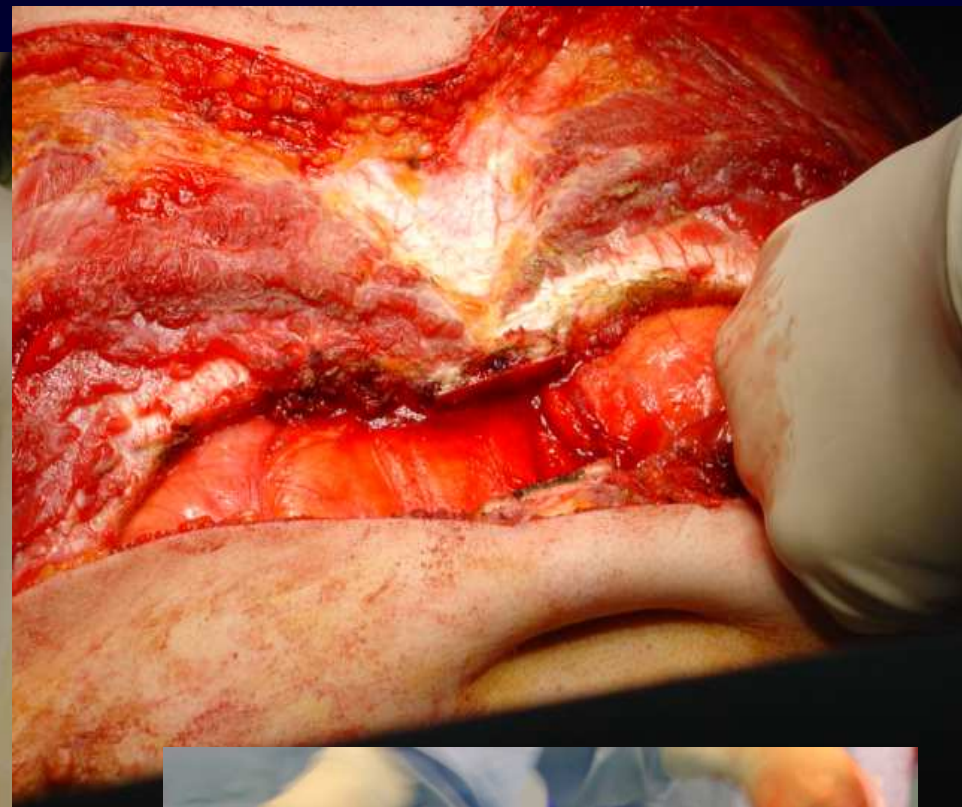

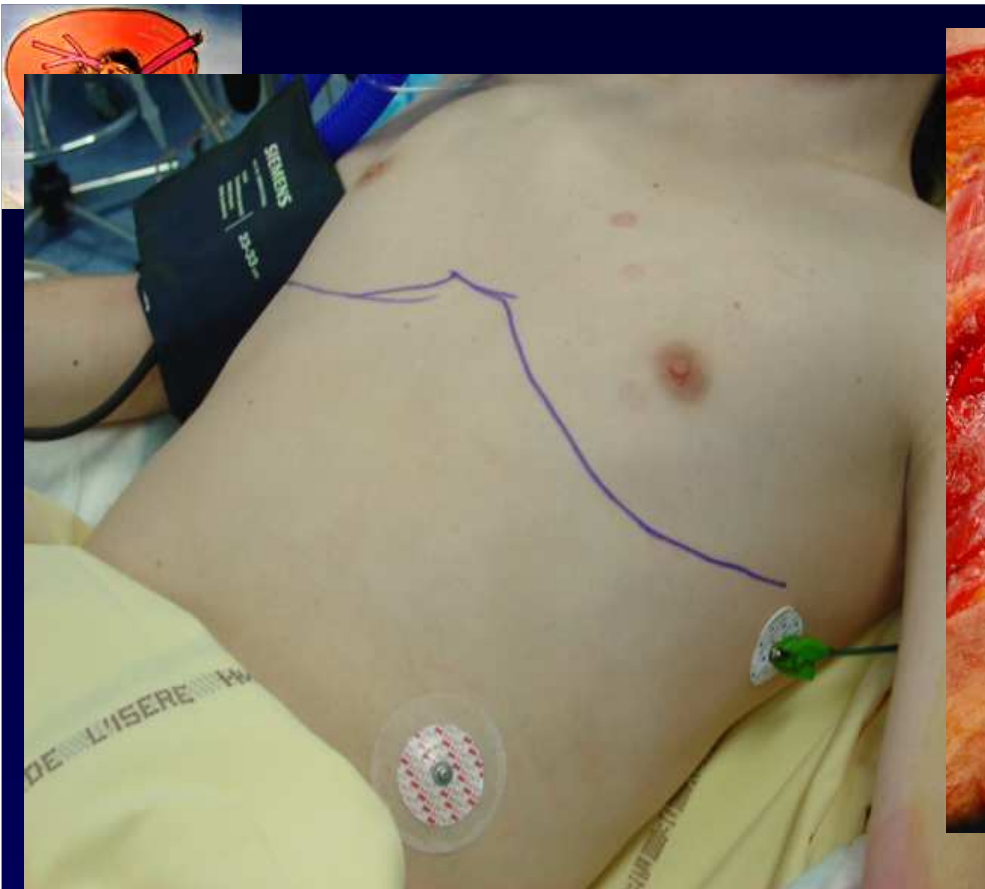
**Diagnostic ?**

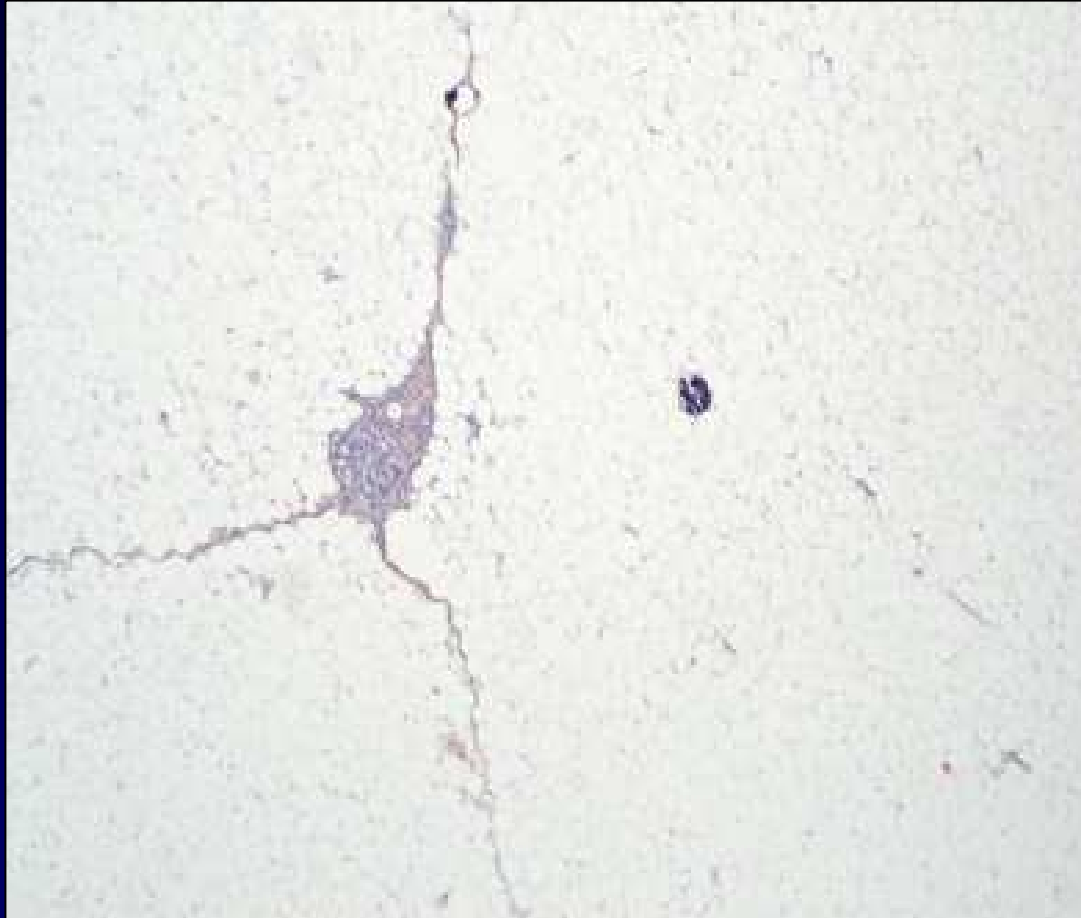


**Diagnostic**

**Thymolipome**



**Tumeur 7 kg**



**Corpuscule de Hassal**