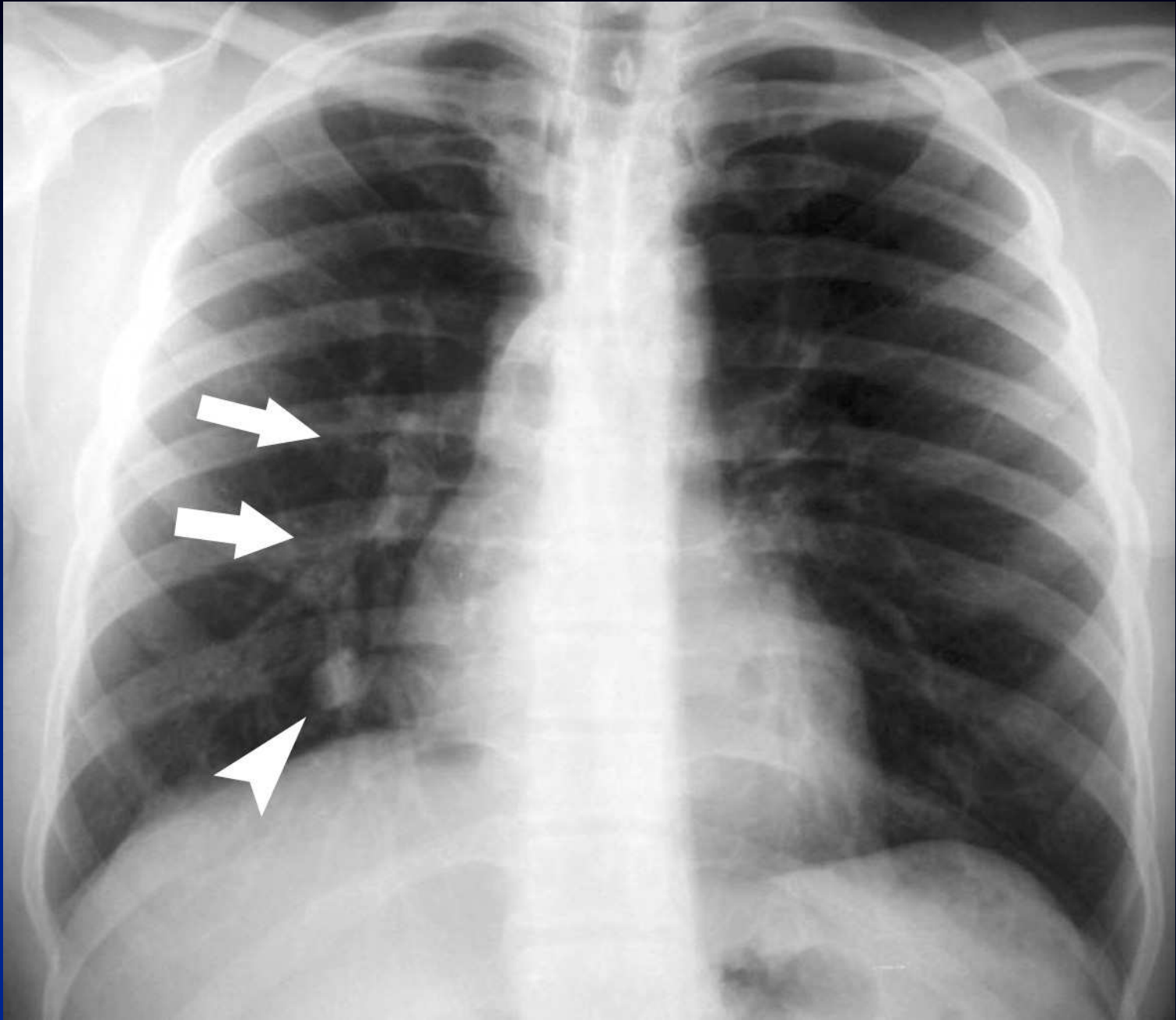
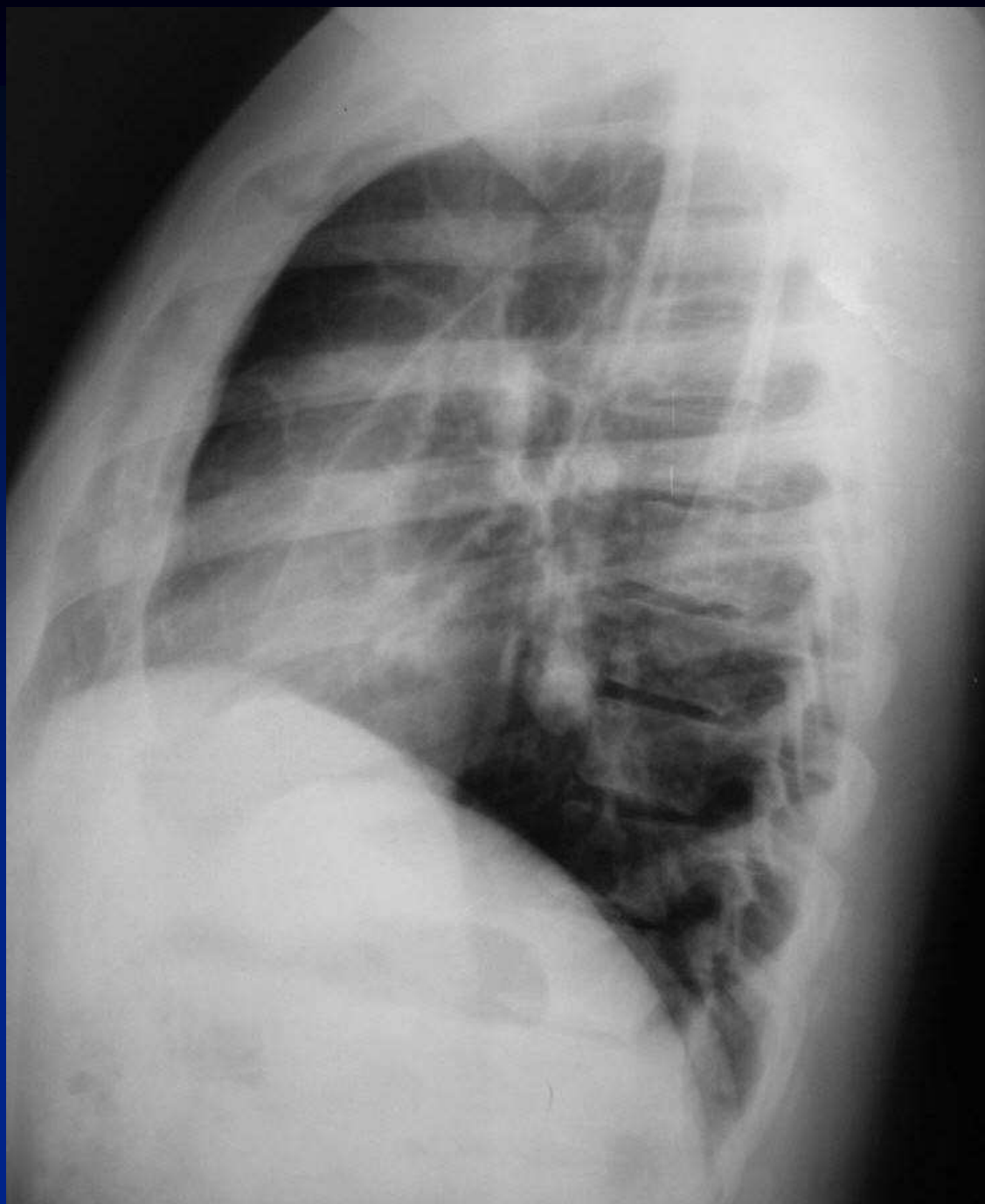

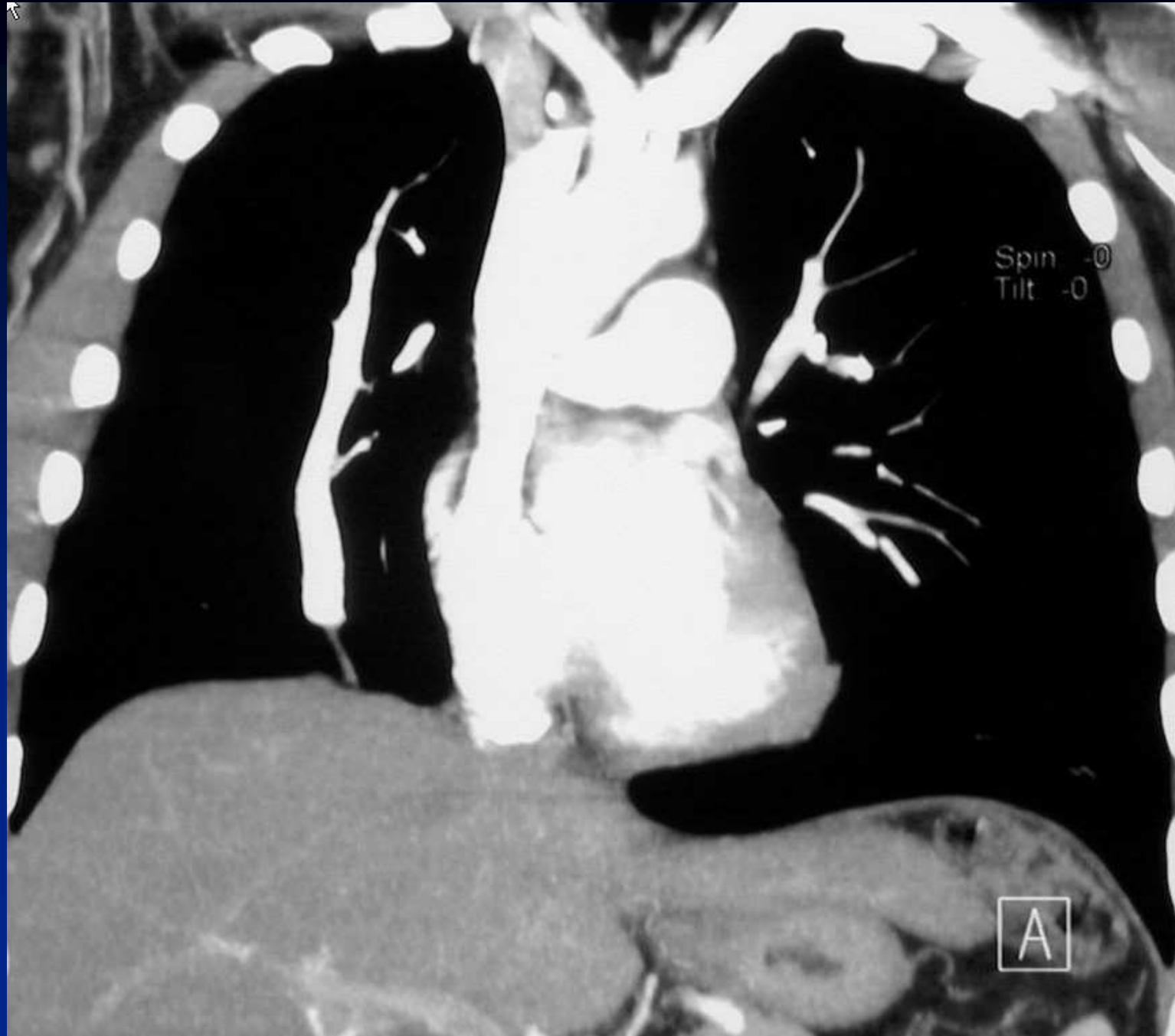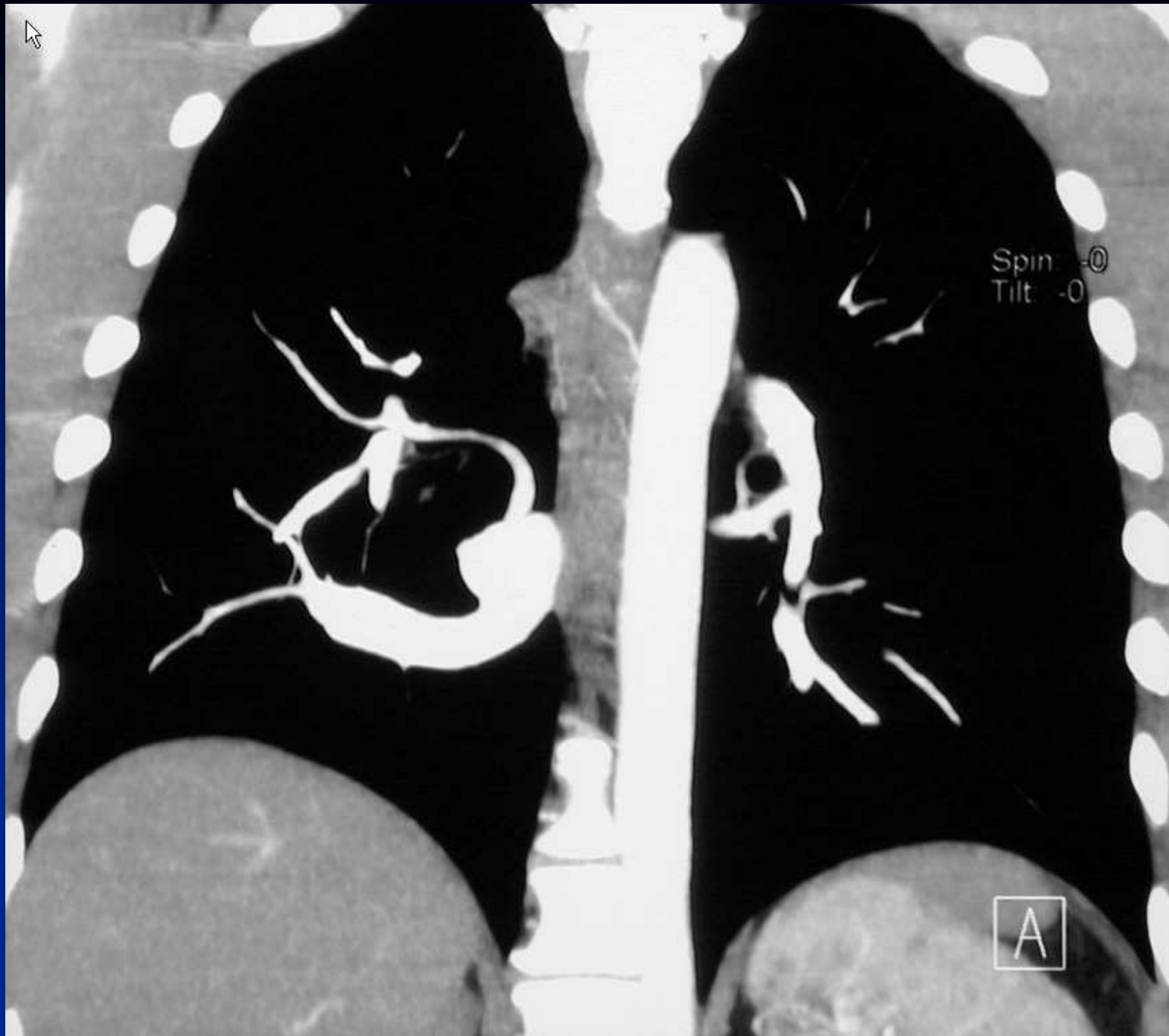B Ghaye

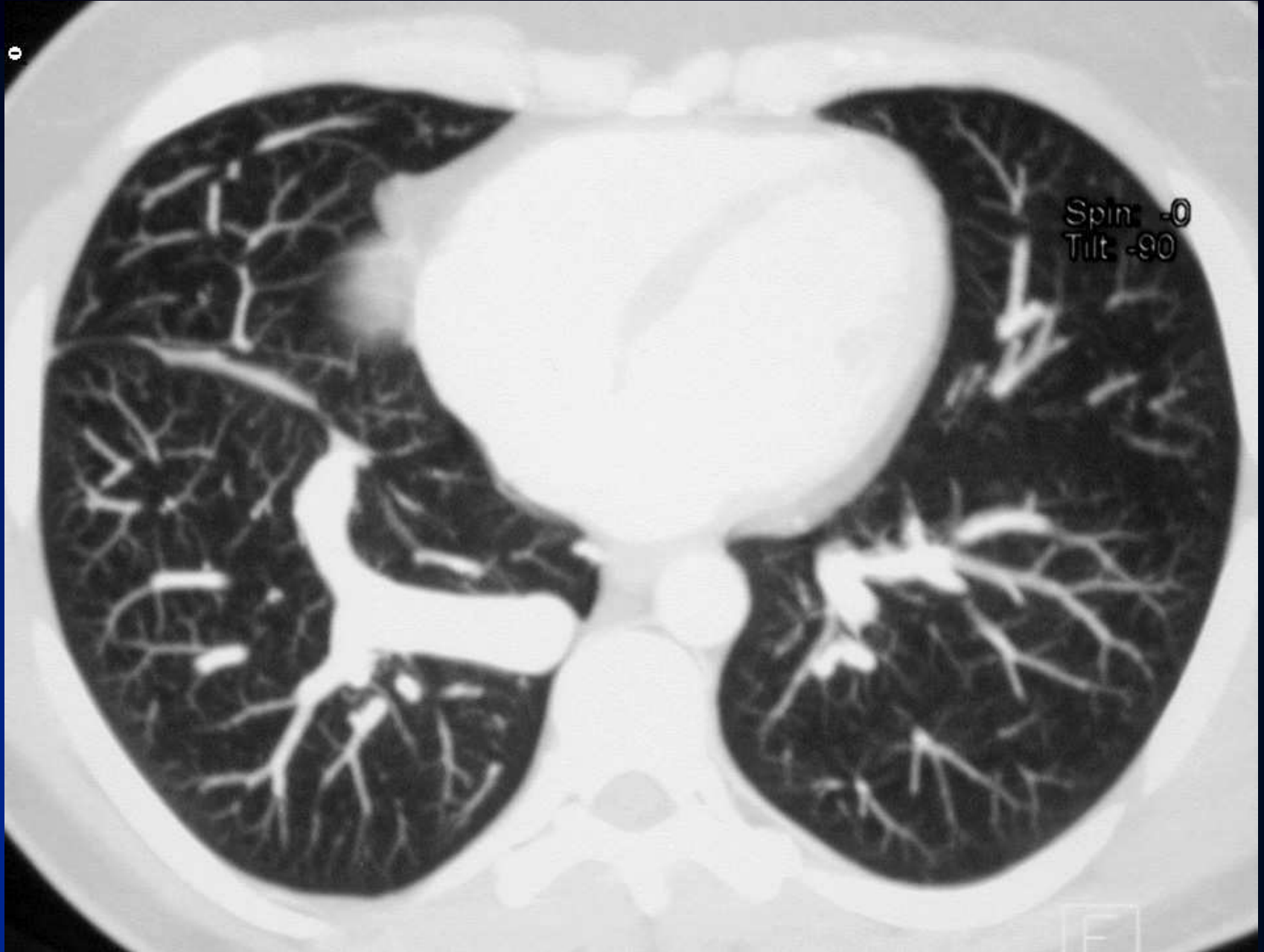- 40-year-old man
- asymptomatic
- medical history was uneventful

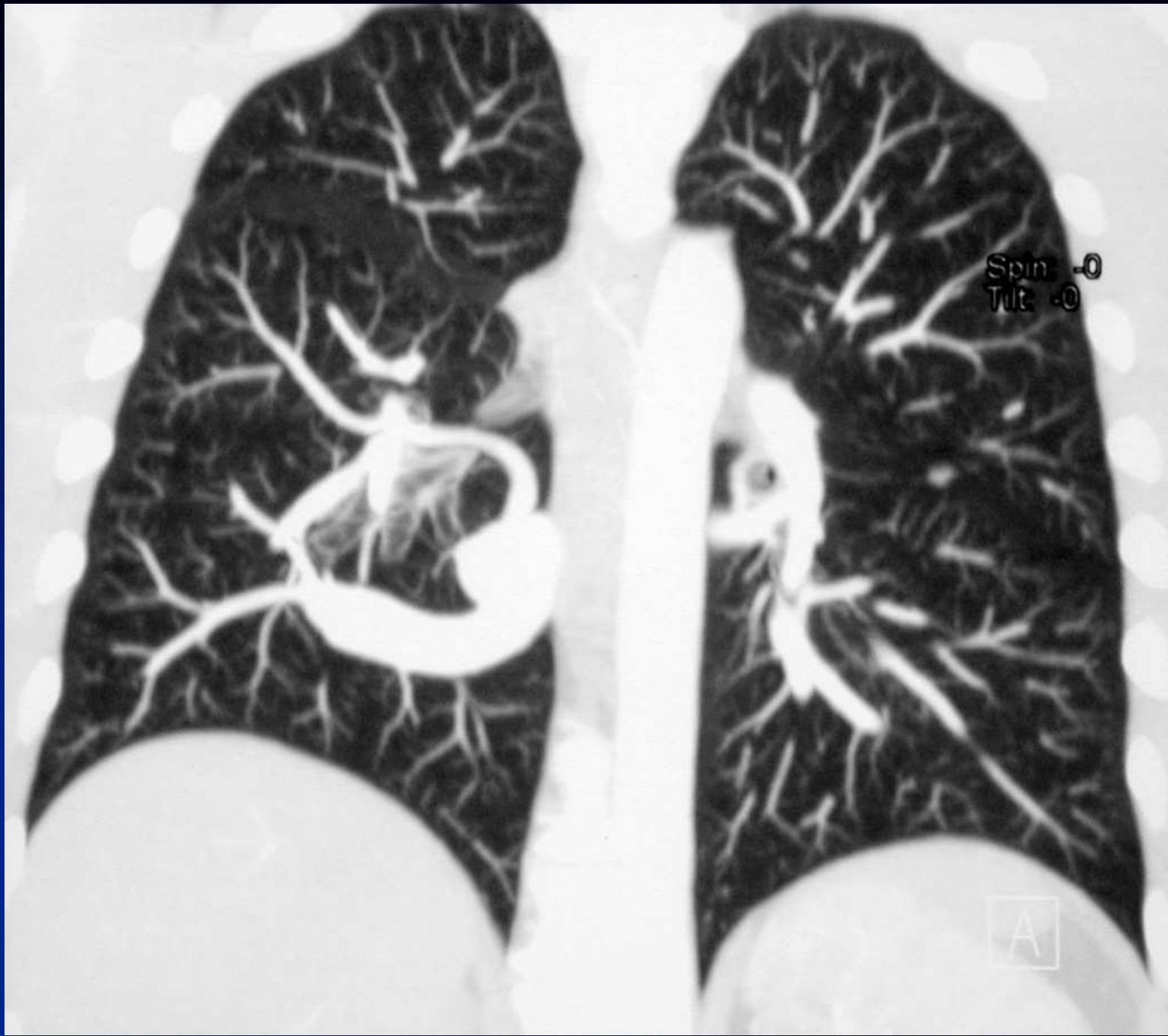


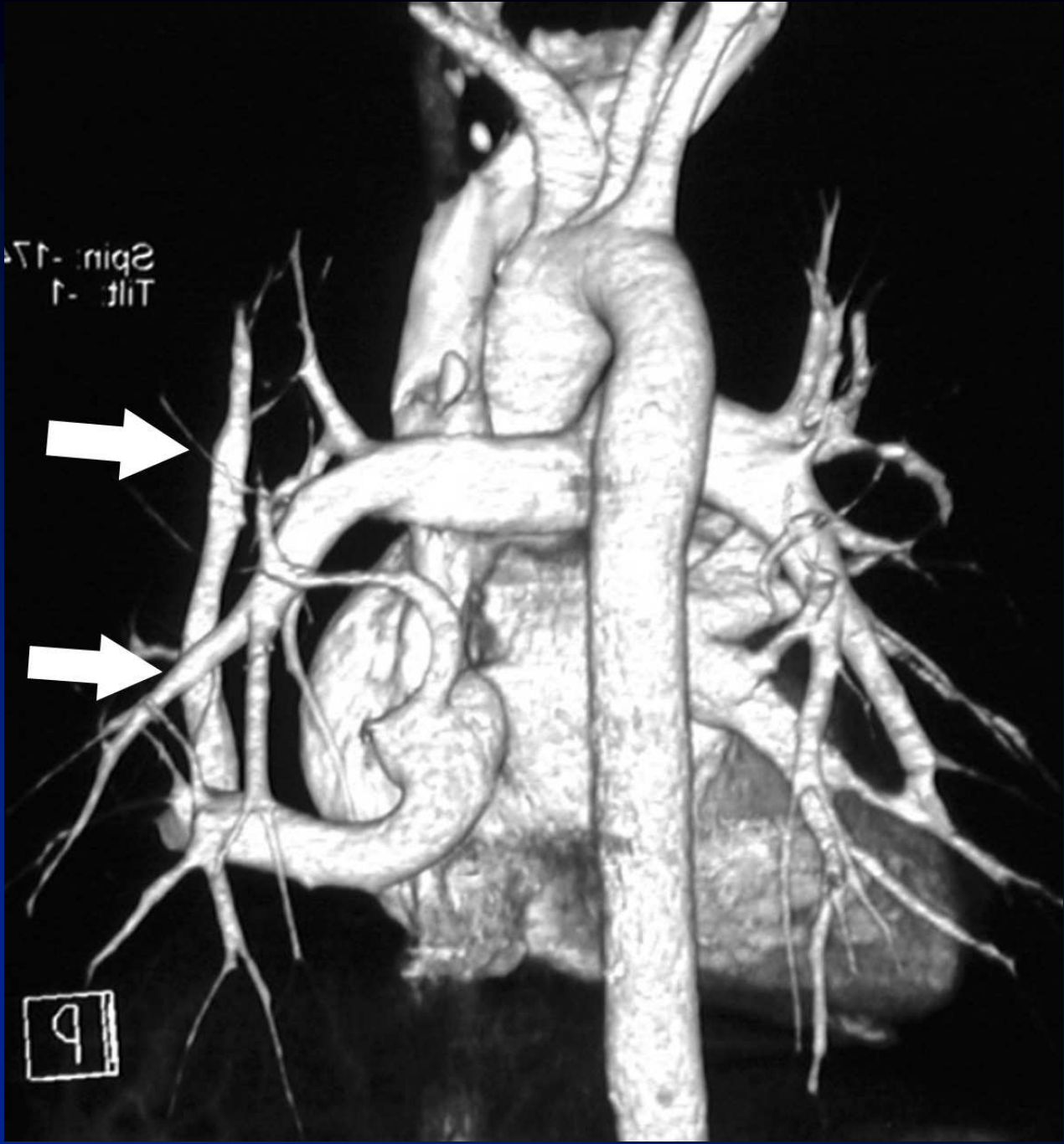






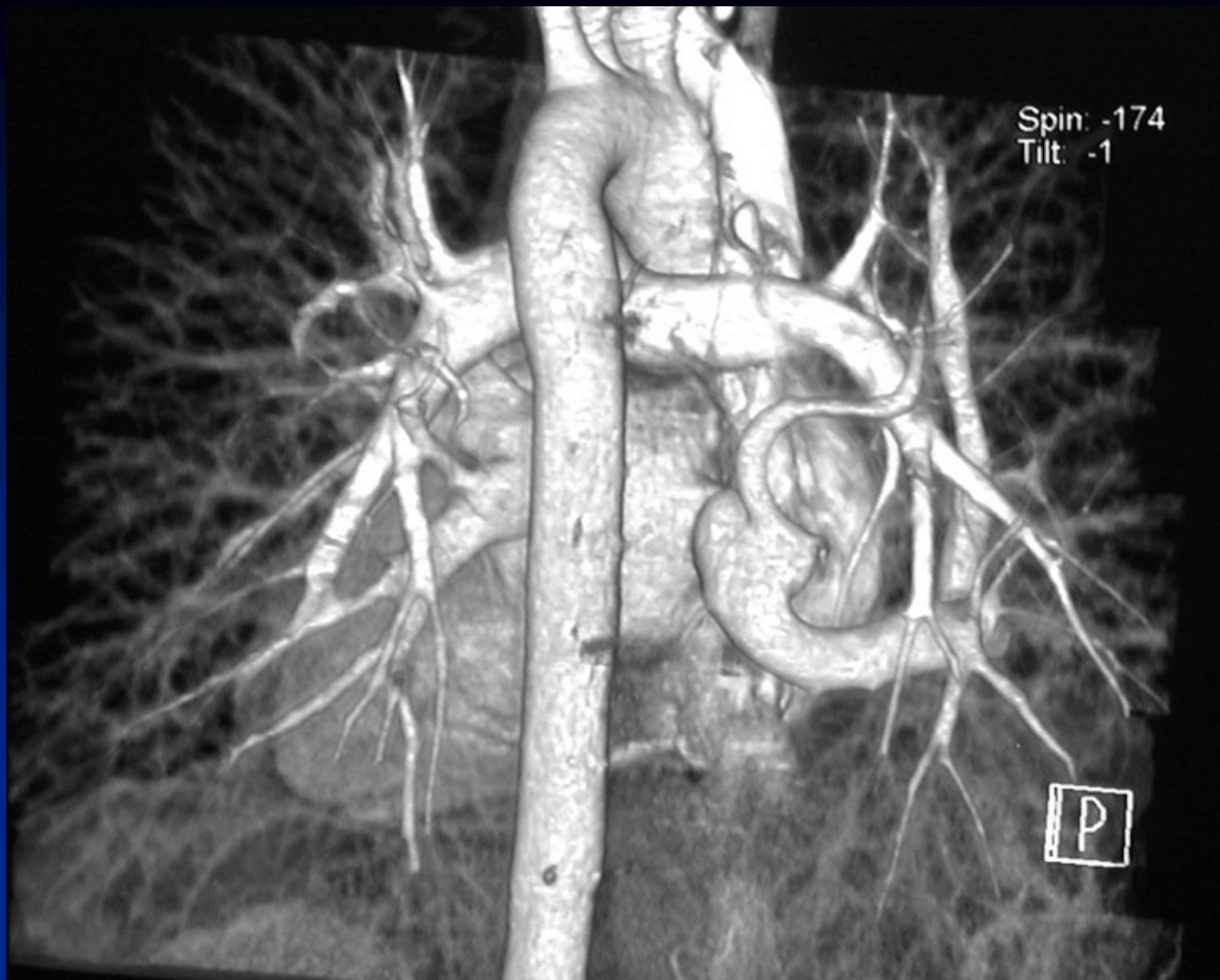





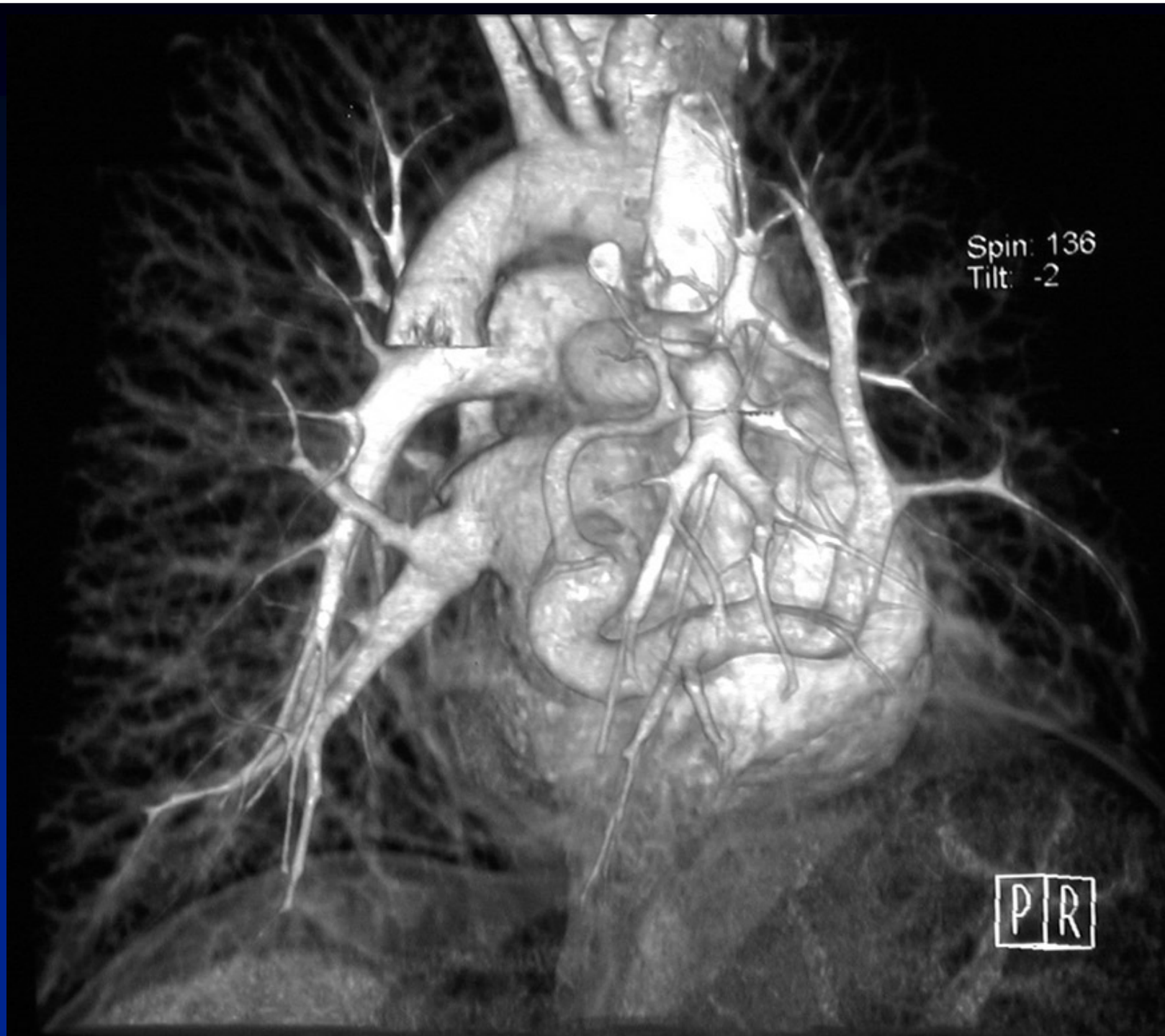
Spin: -174
Tilt: -1

9



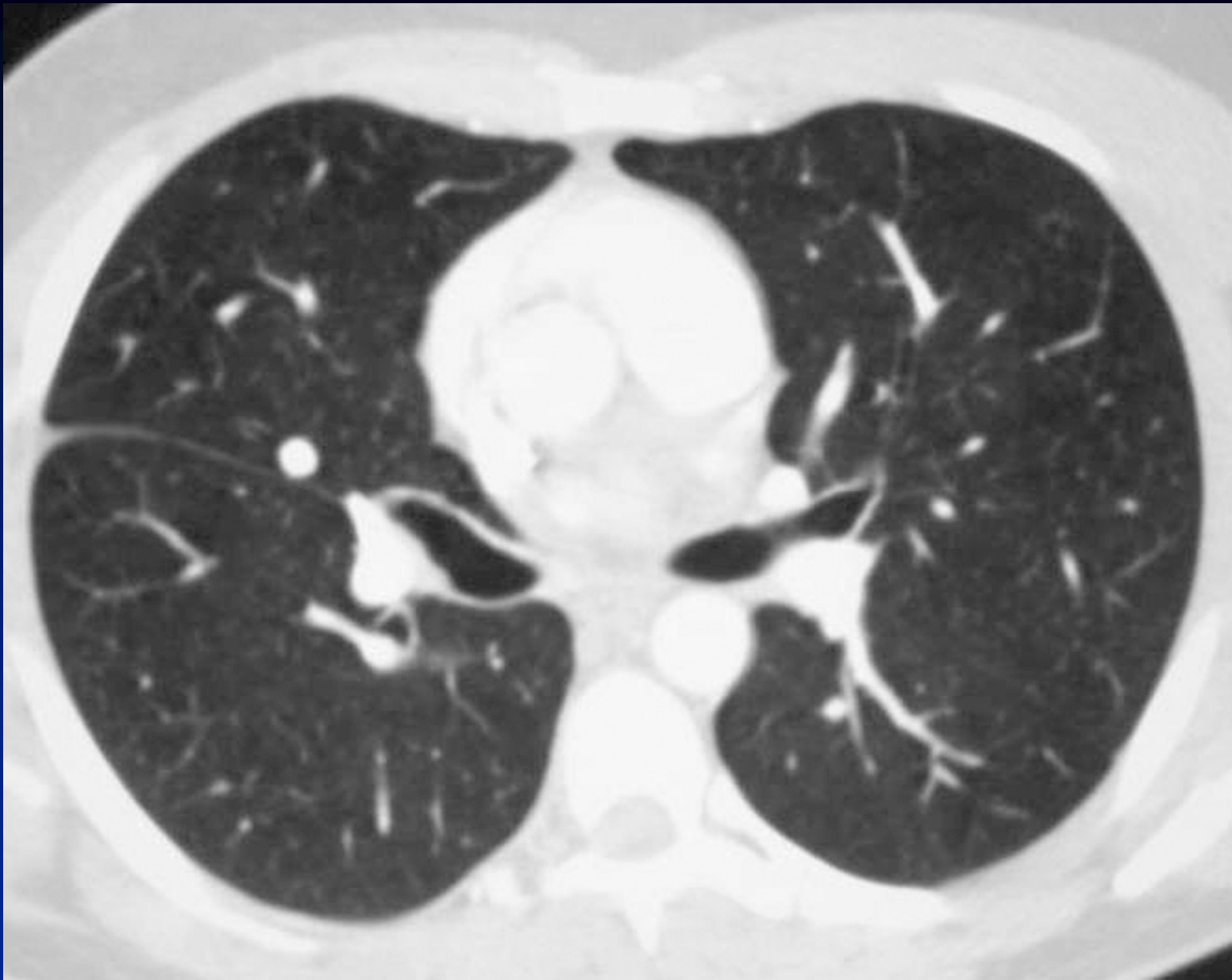Spin: -174
Tilt: -1

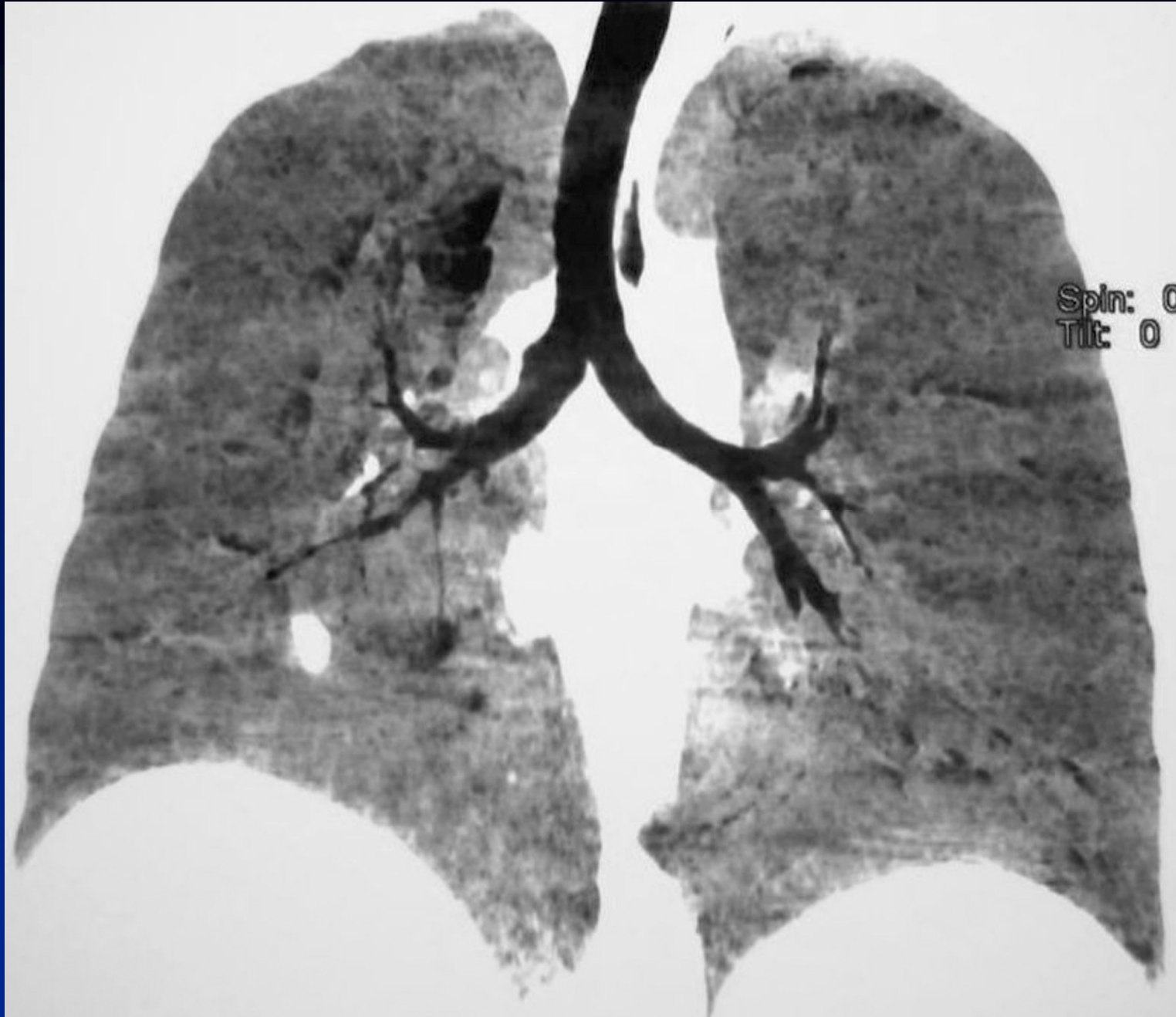P



Spin: 136
Tilt: -2

P|R





Spin: 0
Tilt: 0

Diagnosis ?

Diagnosis

- **Right meandering pulmonary vein associated with left thoracic isomerism**
- **Pseudo-scimitar syndrome (normal drainage)**