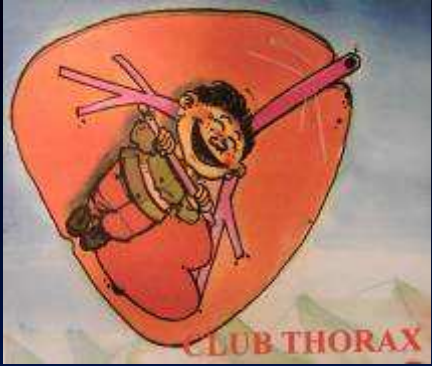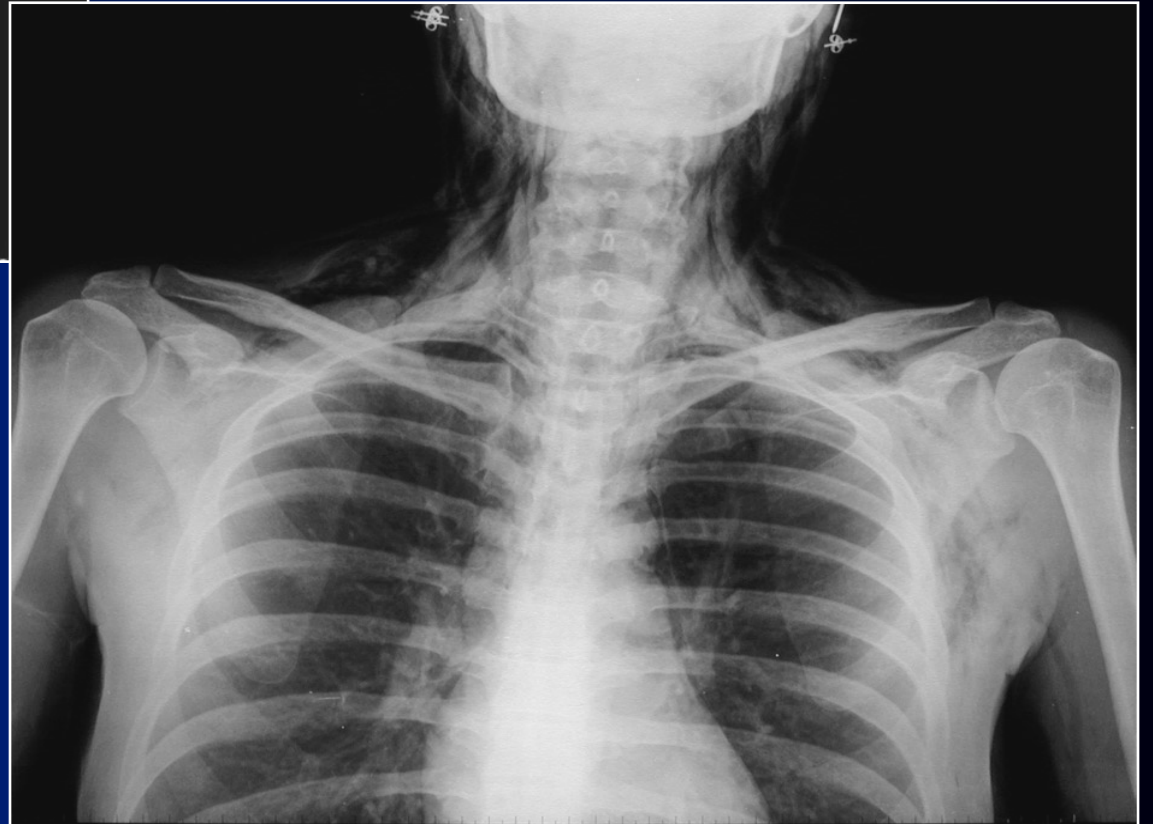

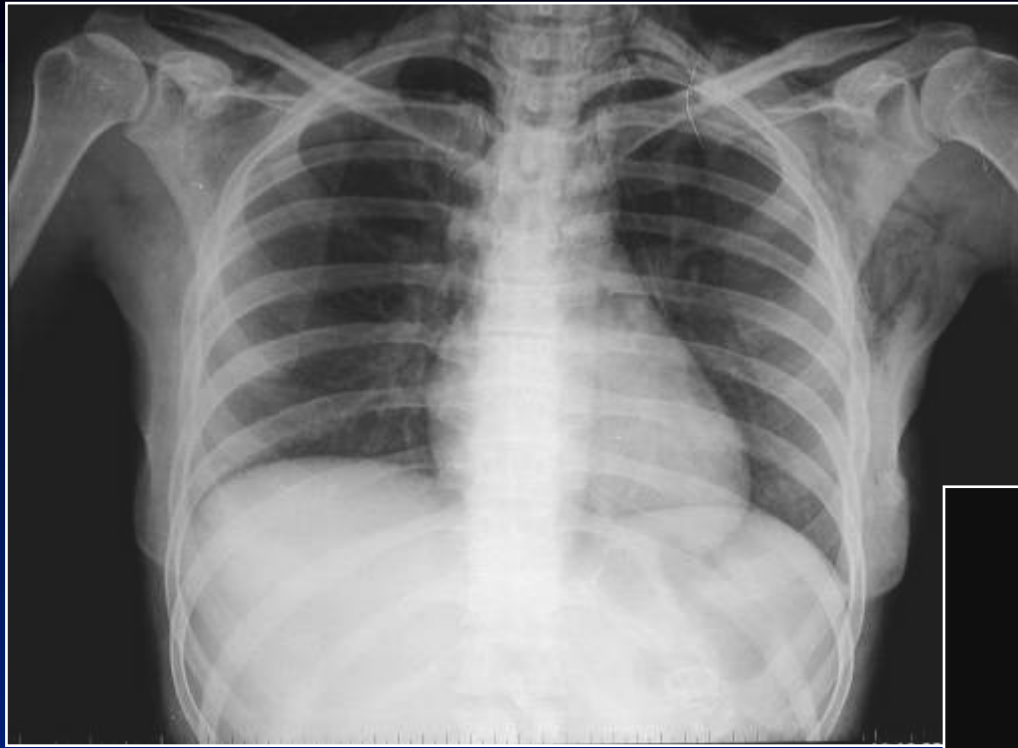
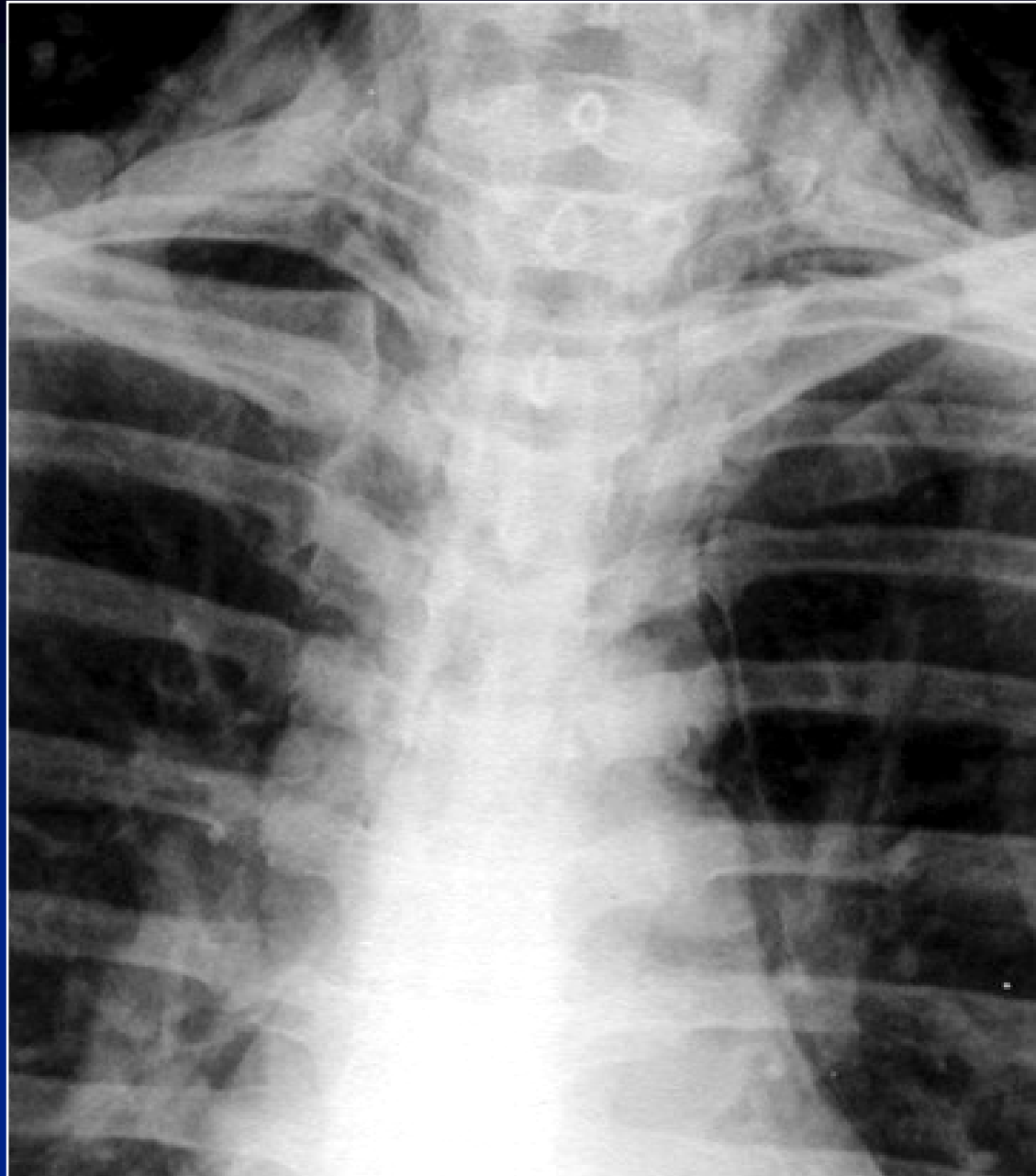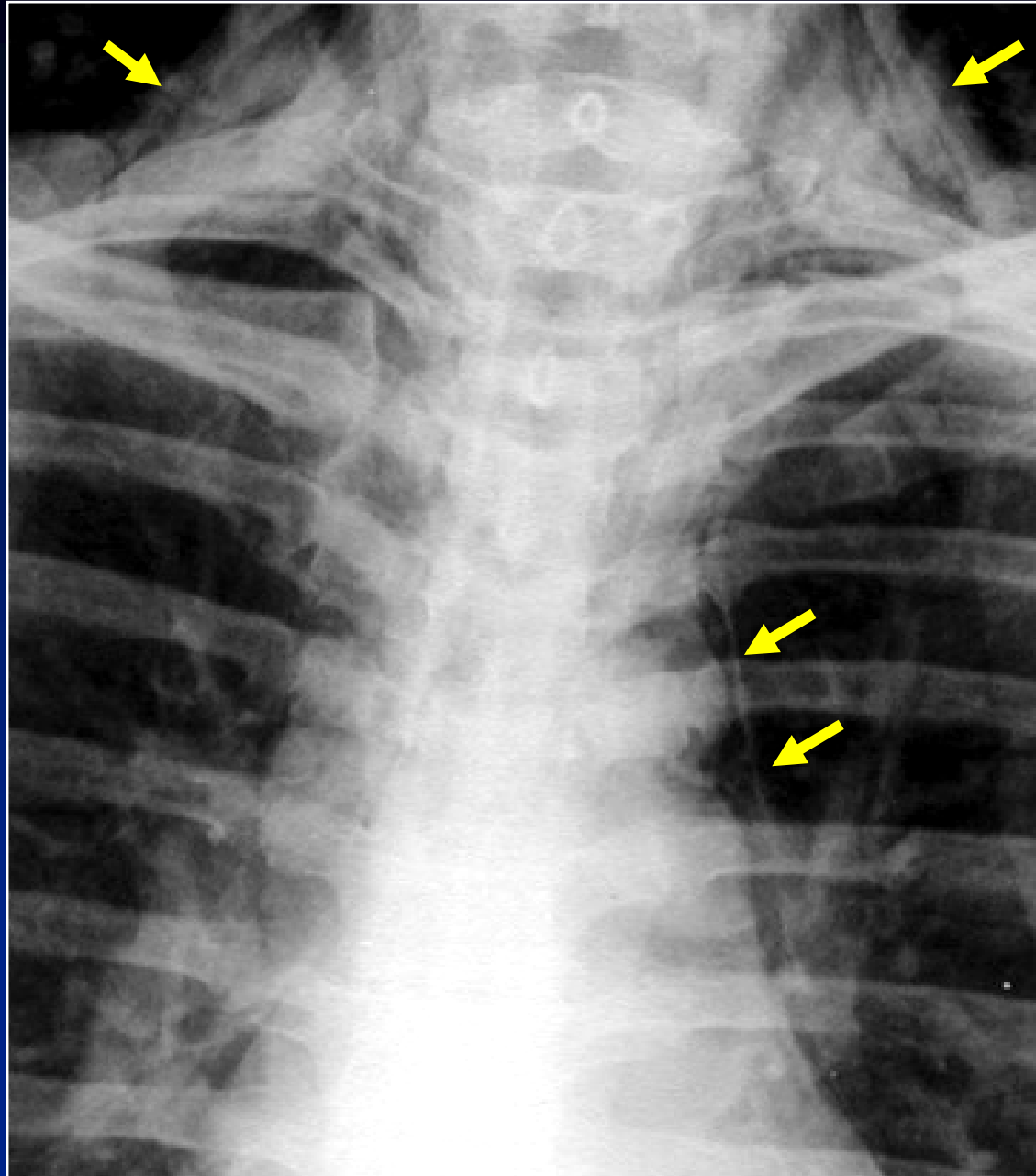


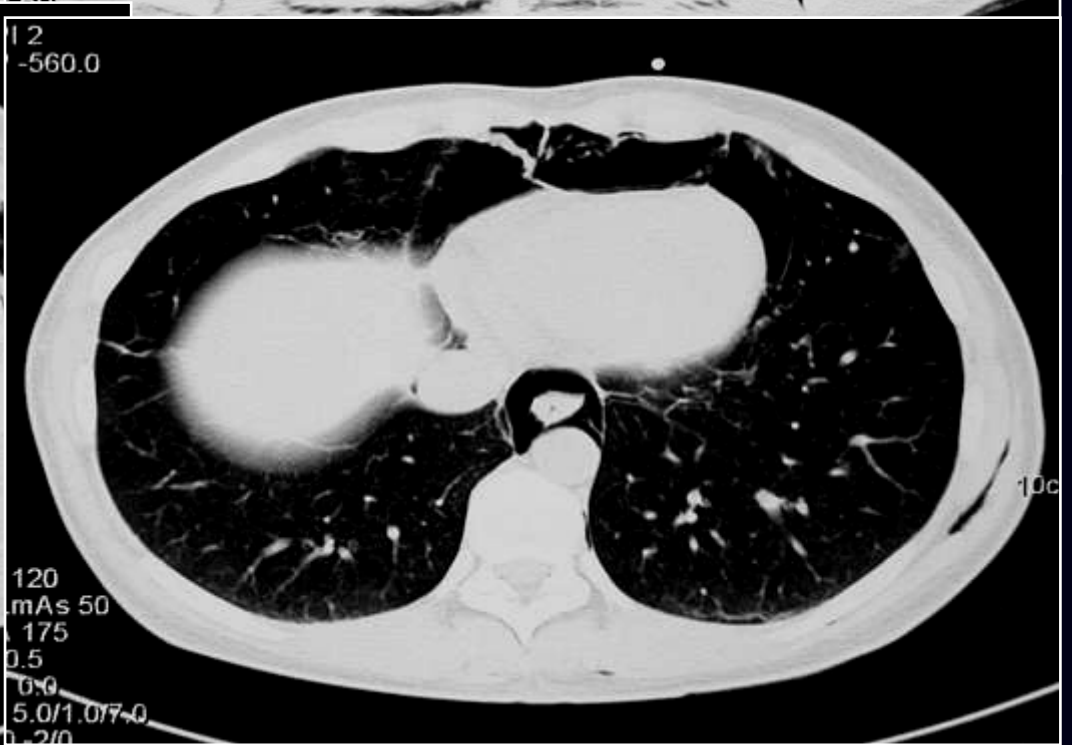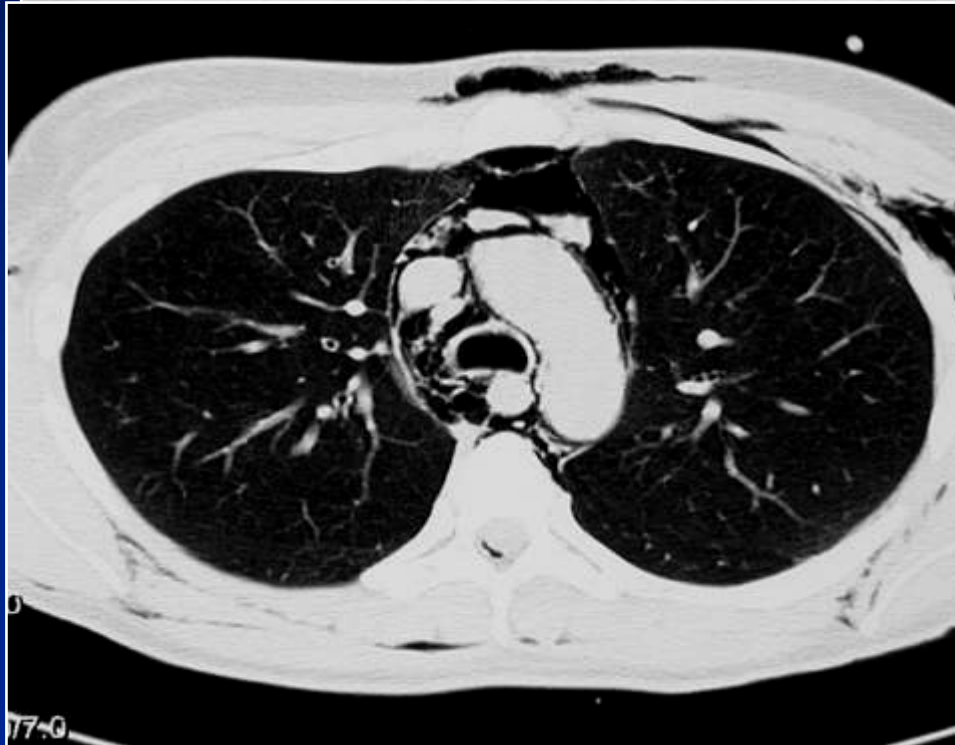
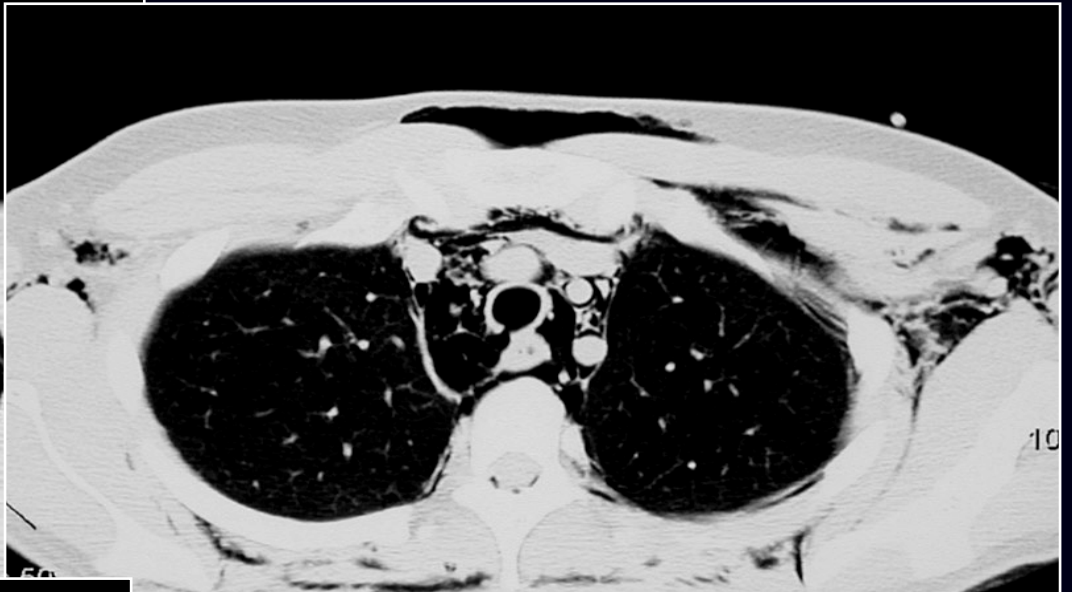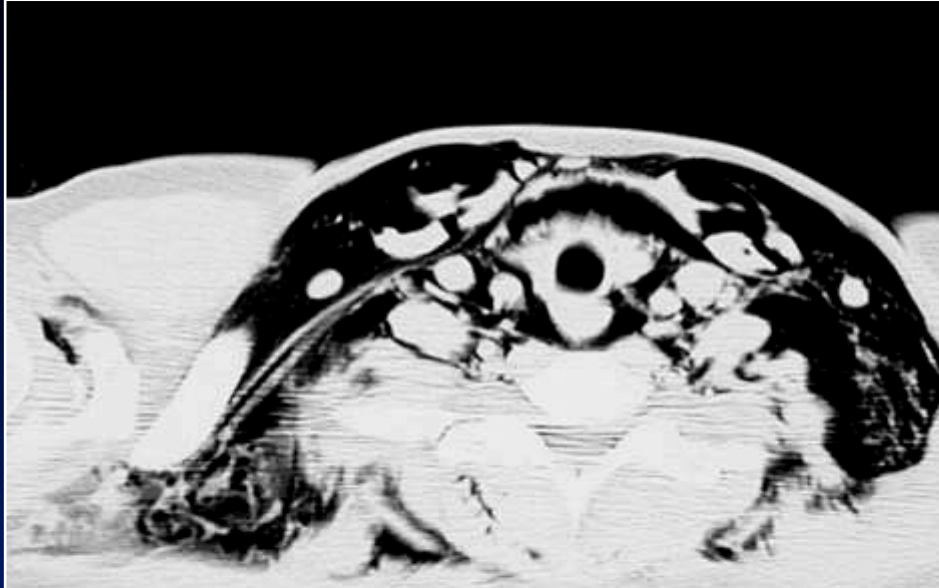
B Ghaye

- **Femme de 31 ans**
- **Intervention chirurgicale**
- **Détresse respiratoire post-extubation**
- **Emphysème pariétal**





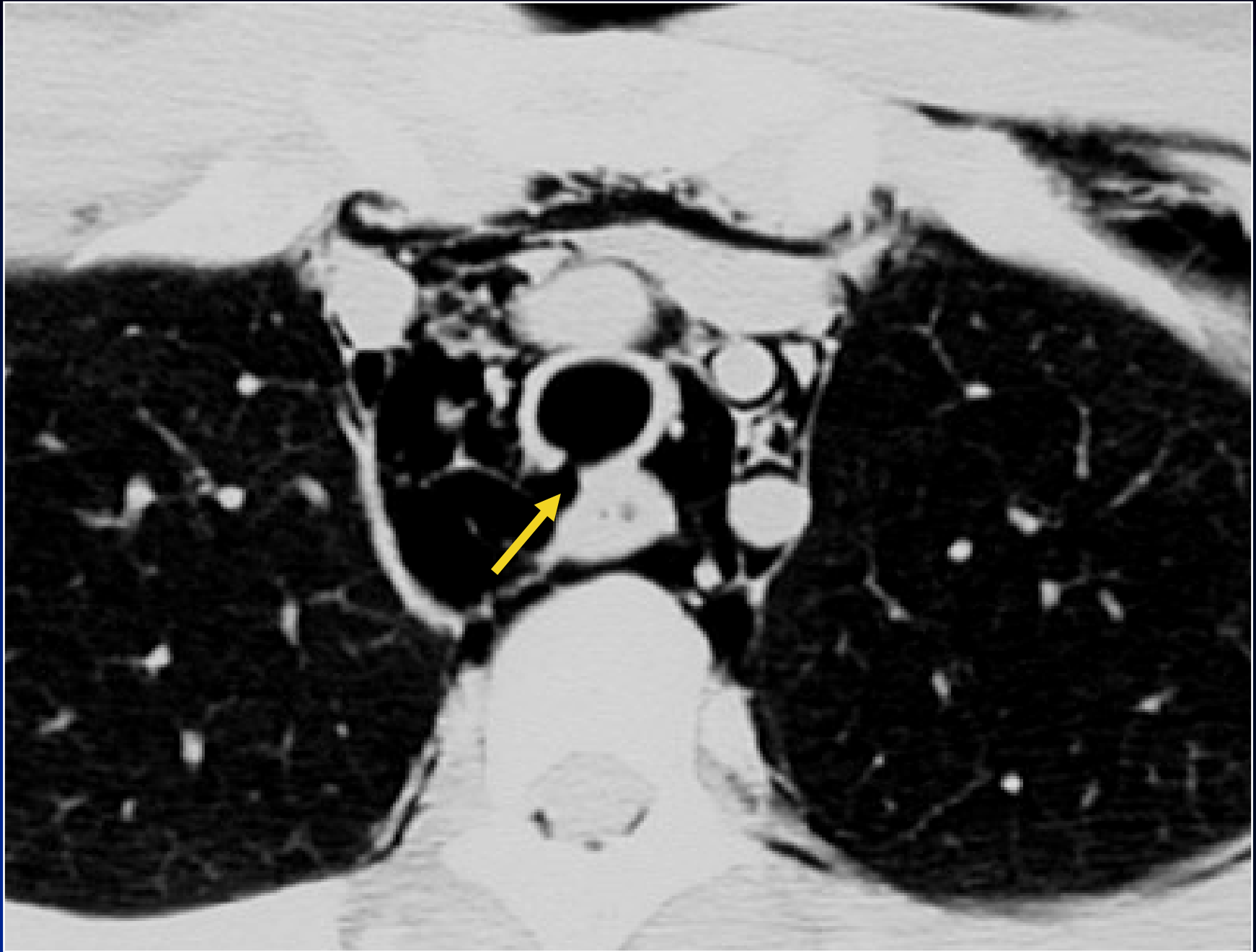


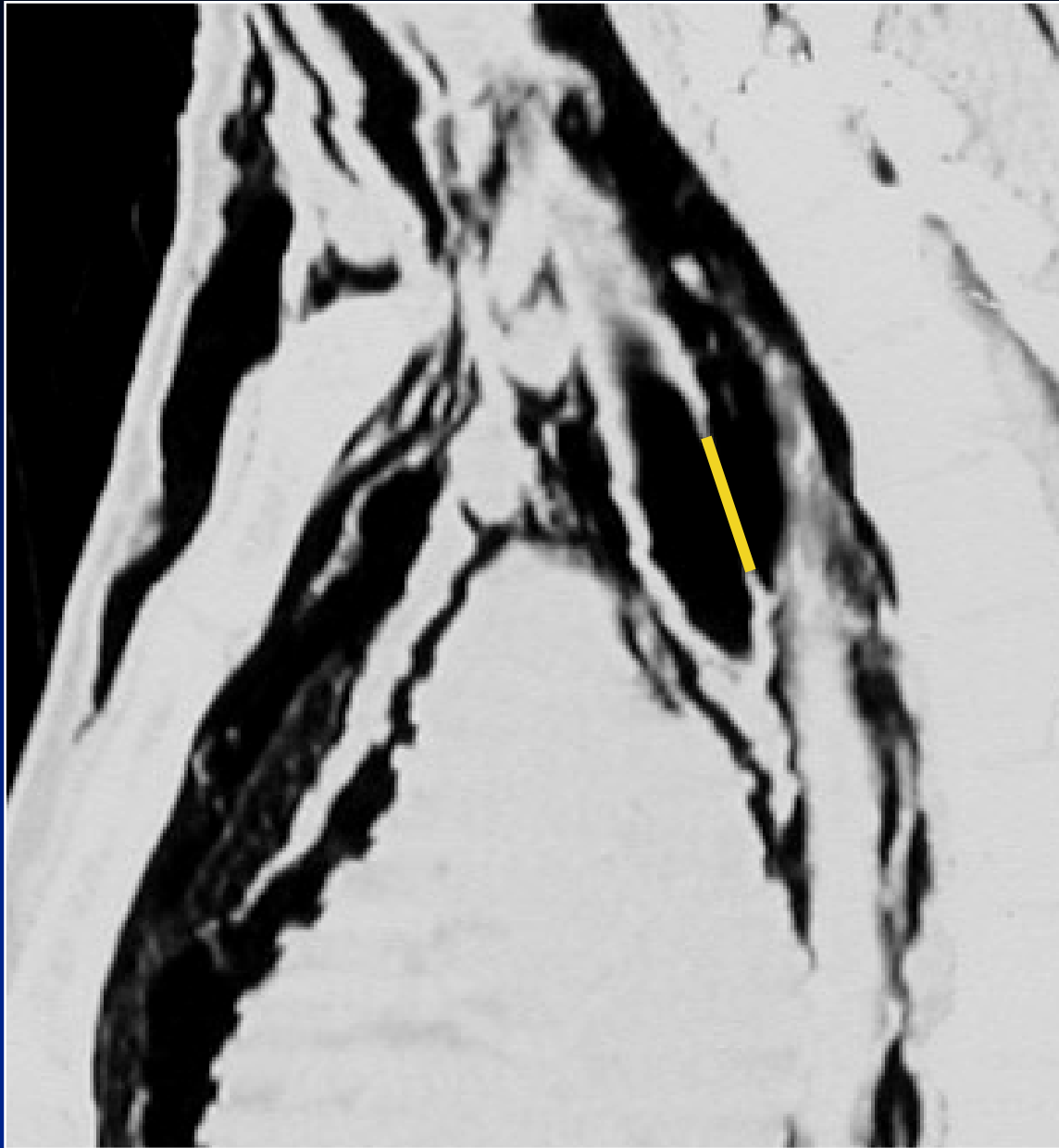


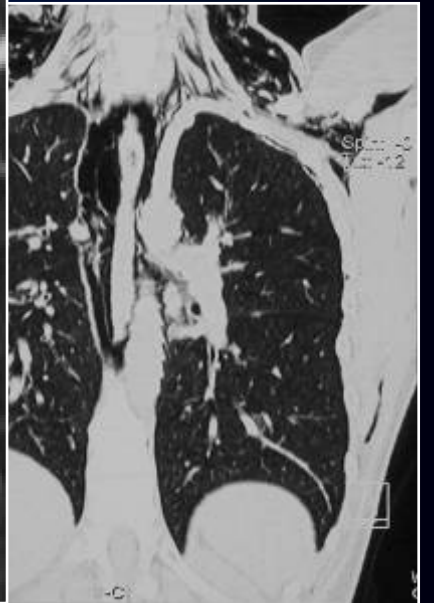
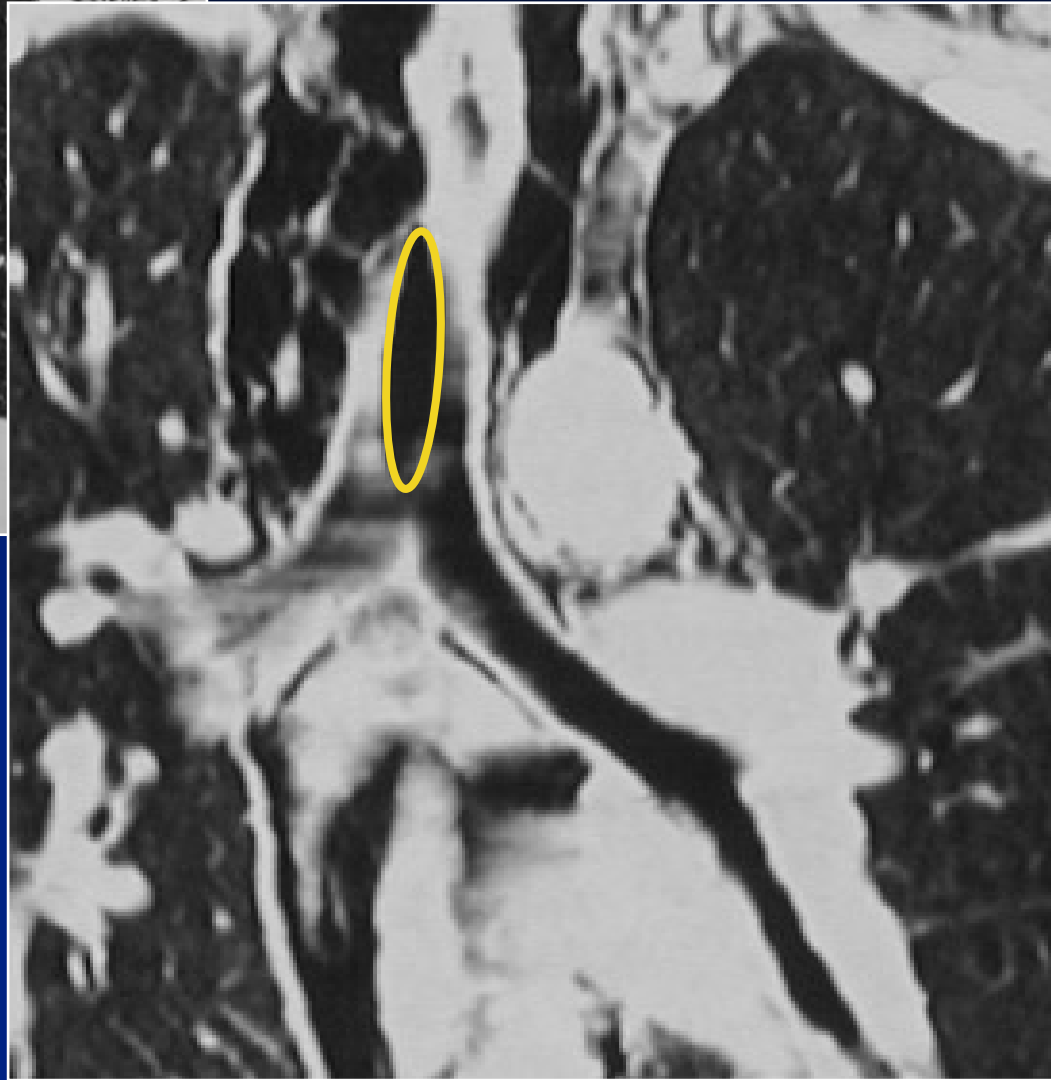
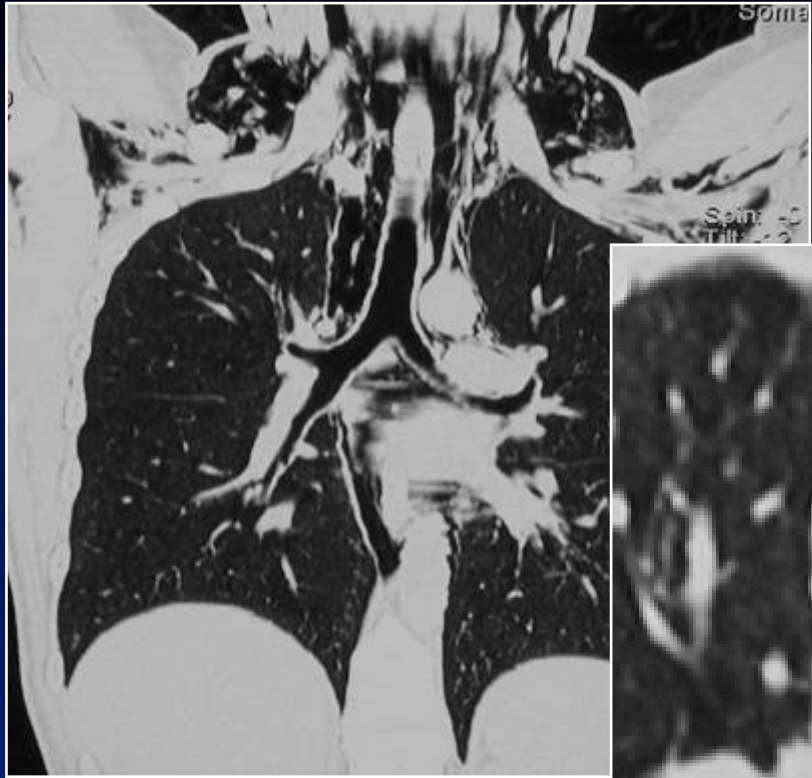
Diagnostic ?

Diagnostic

Rupture trachéale post-intubation



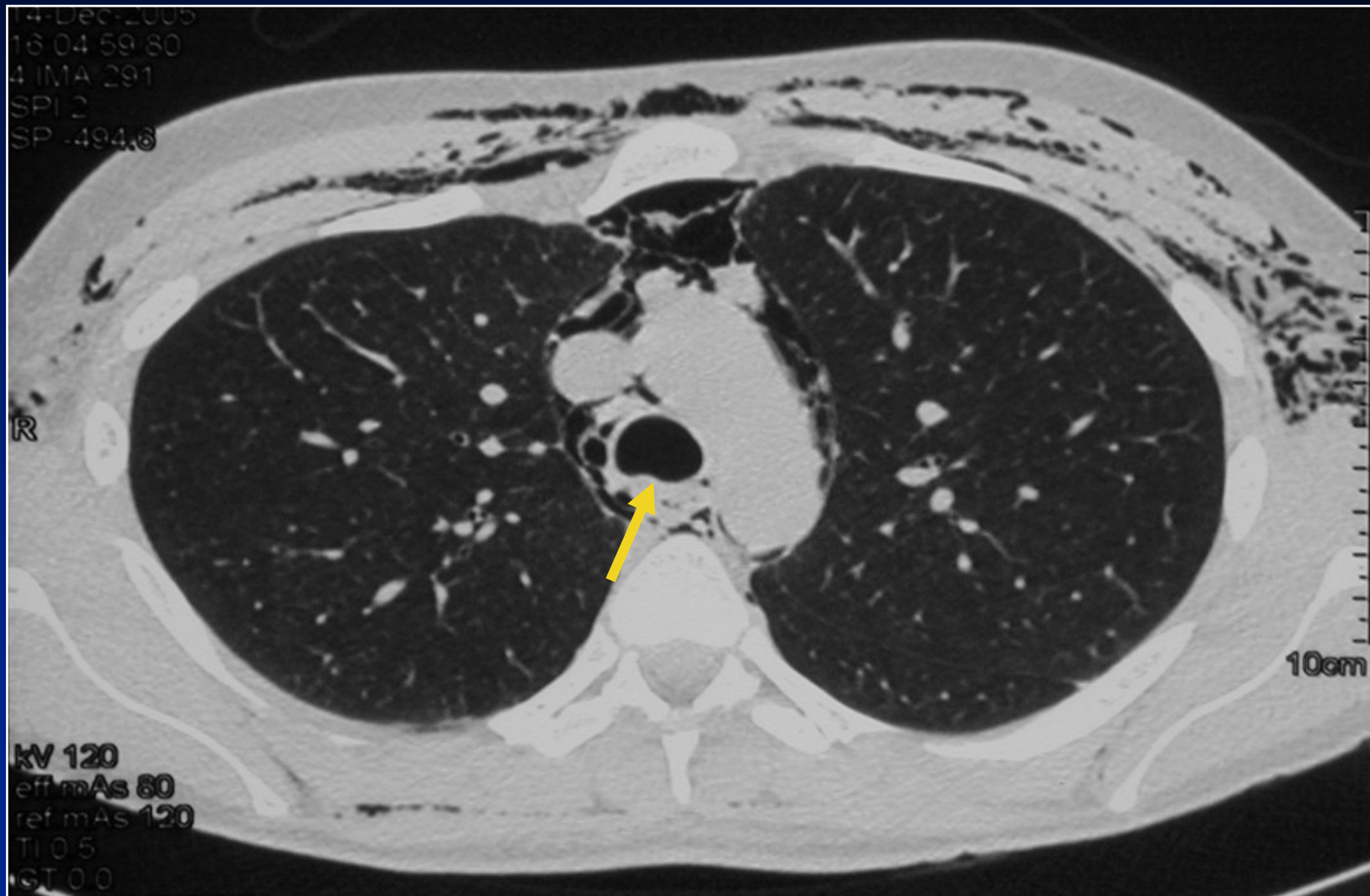




Evolution

- **Traitement conservateur**
- **Bonne évolution**

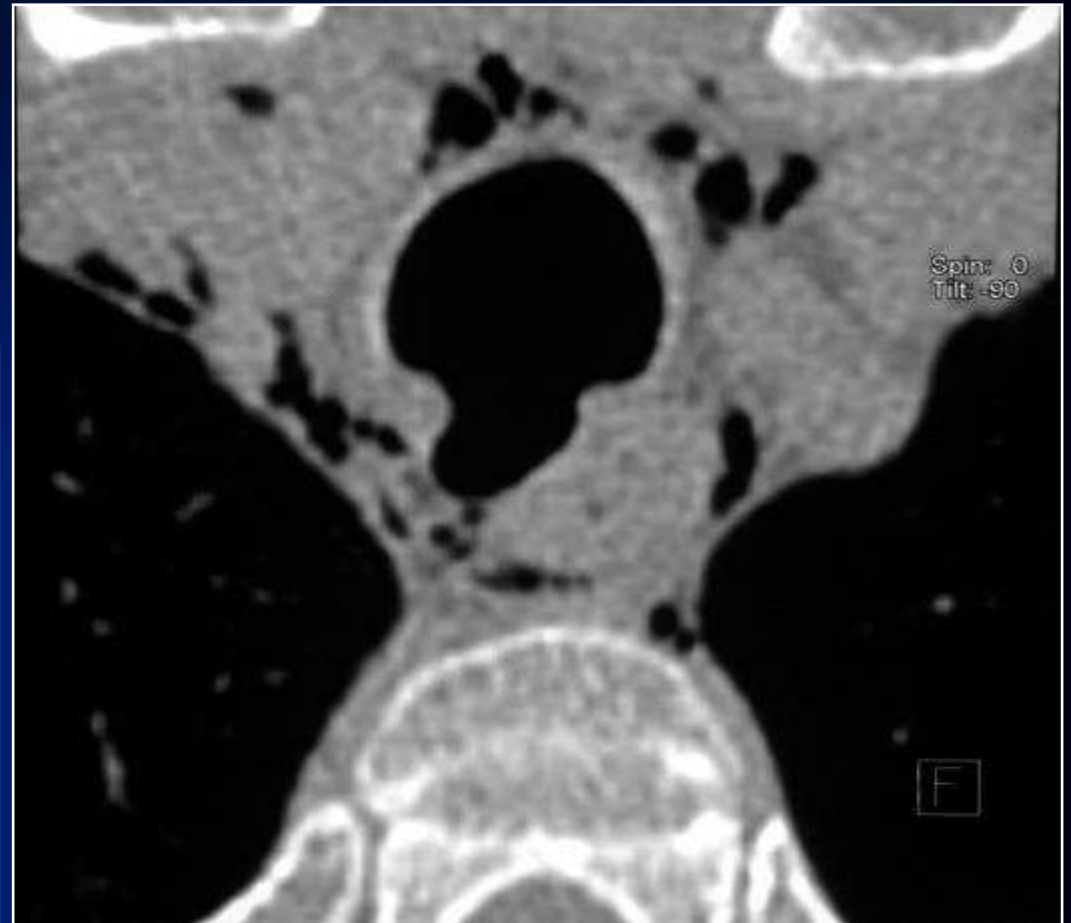
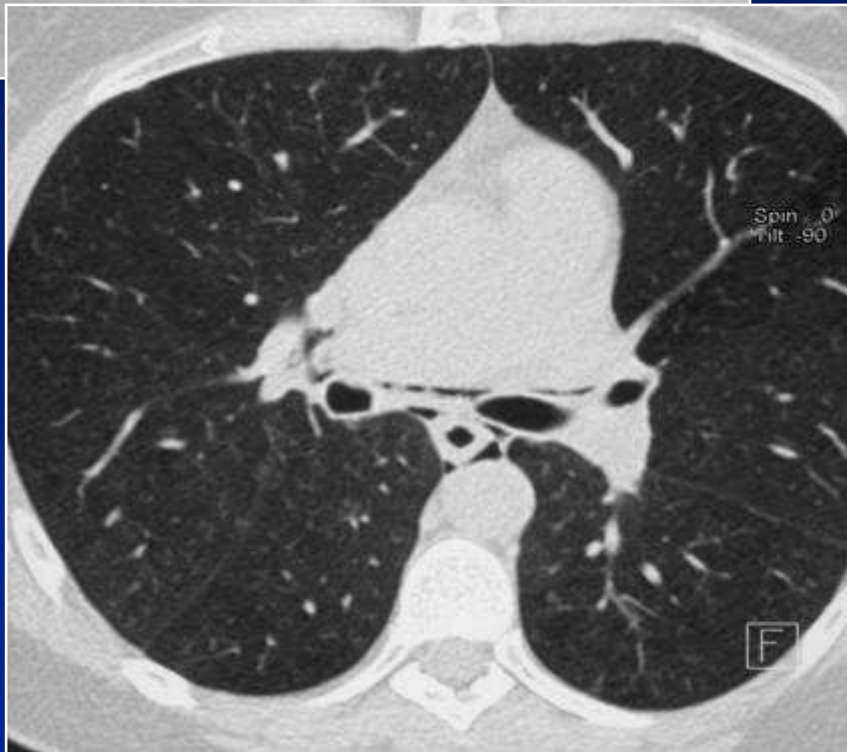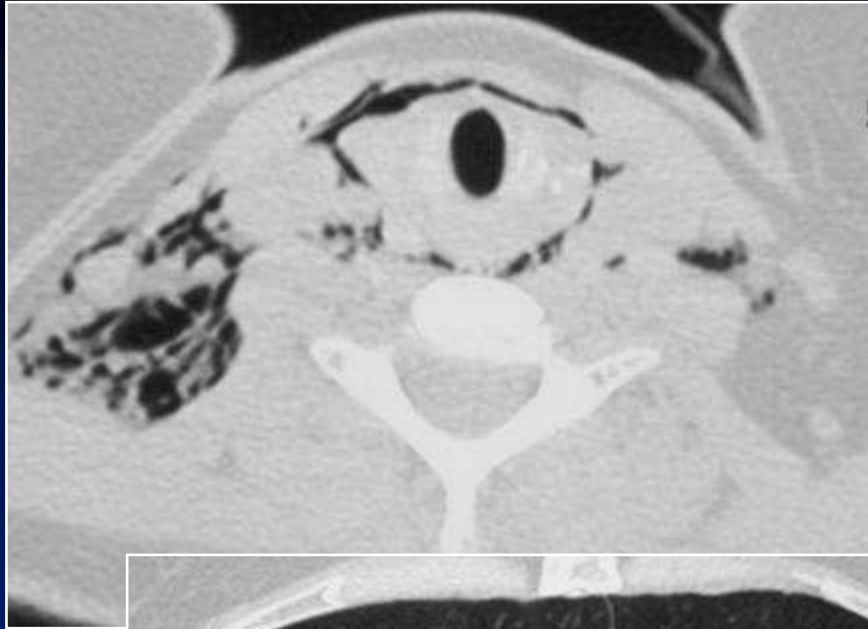
Cicatrisation de la plaie trachéale



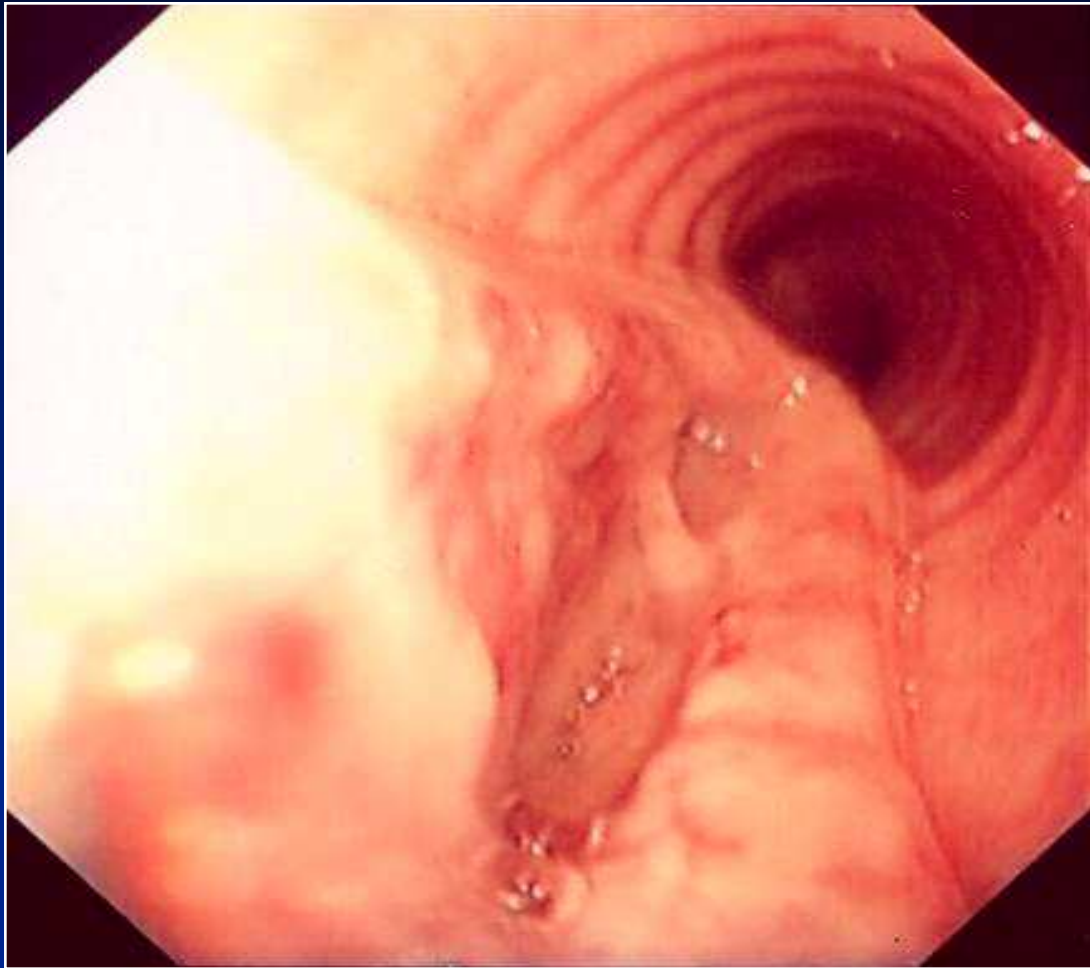
Discussion

- Mécanismes de plaie trachéale :
 - Hyper-inflation du ballonnet
 - Plaie directe
- Localisation postérieure des lésions
 - Paroi membraneuse de la trachée
 - Jonction entre la paroi membraneuse et le cartilage
- Facteurs de risque
 - Tube trachéal de taille inadaptée
 - Patiente de petite taille
 - Intubation difficile

Autre cas



Fibroscopie



Endoscopie virtuelle

