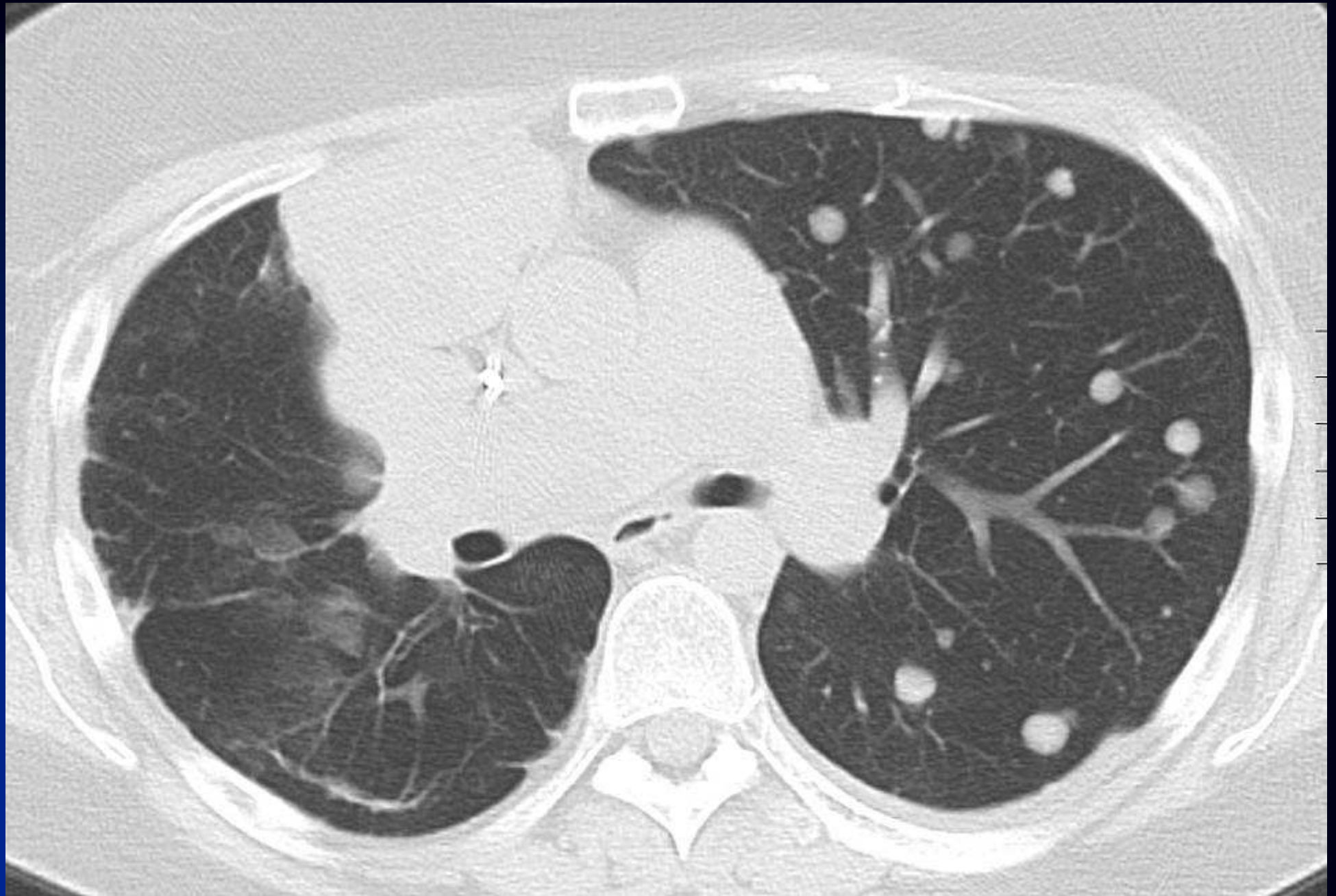
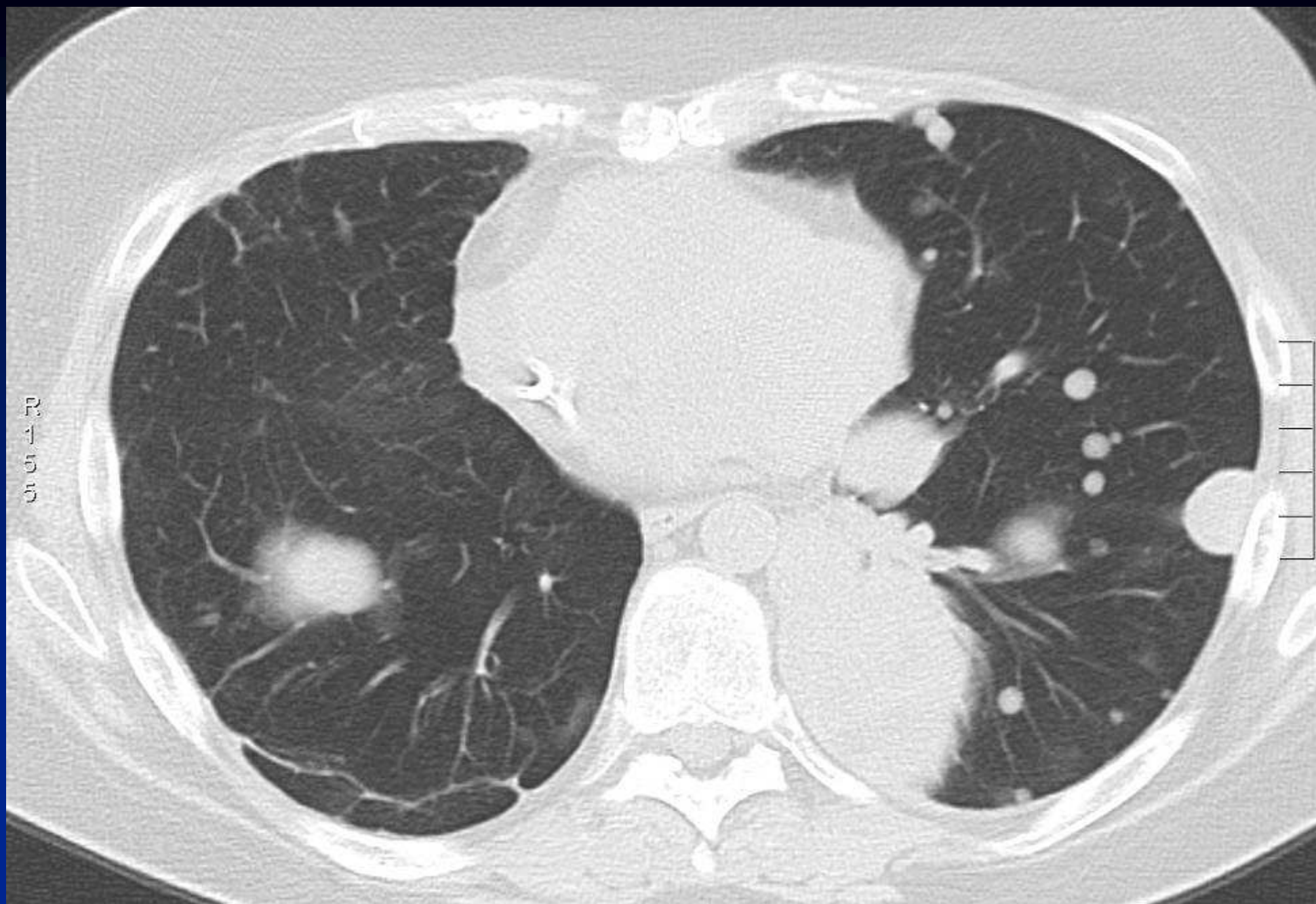


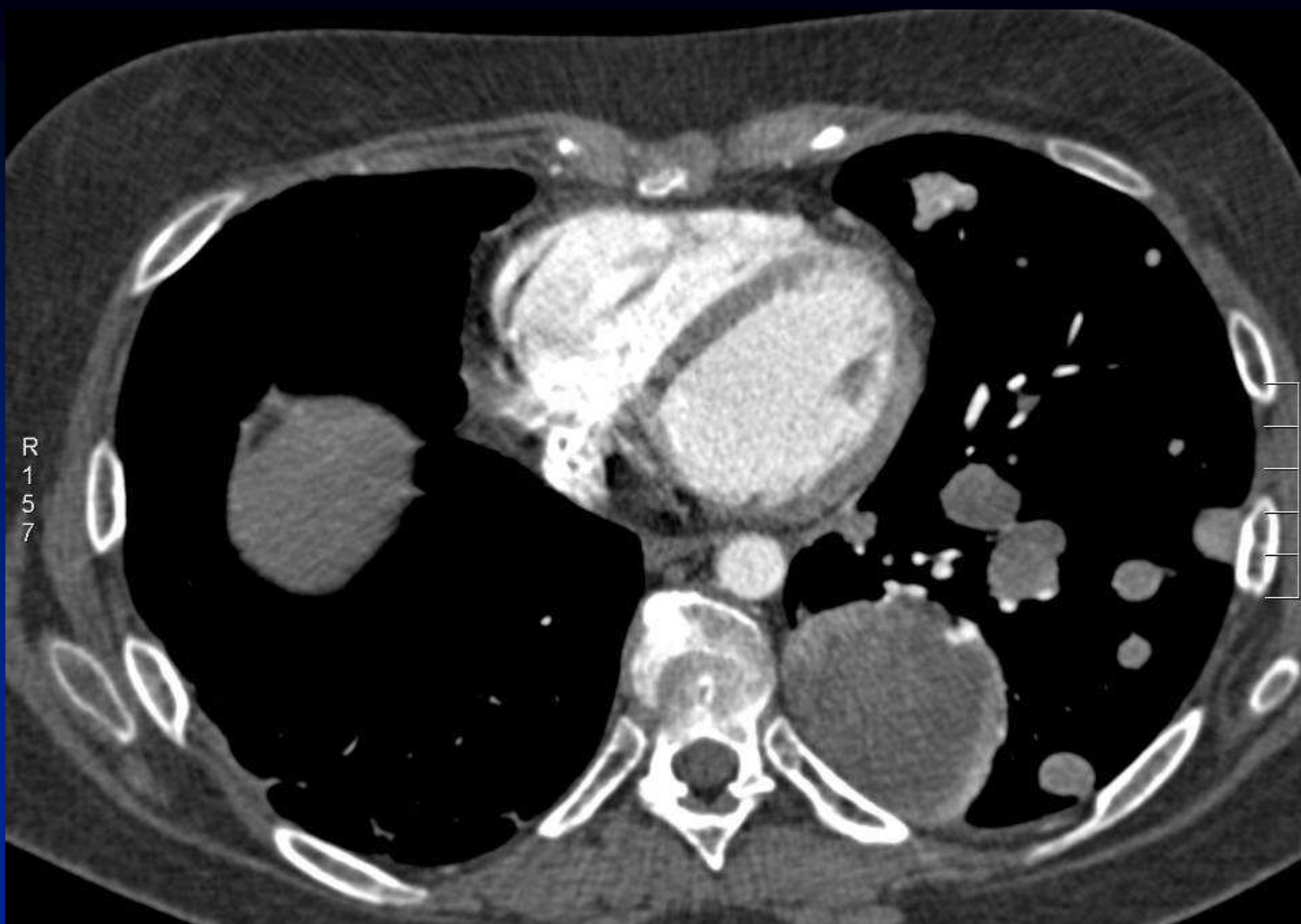B Ghaye



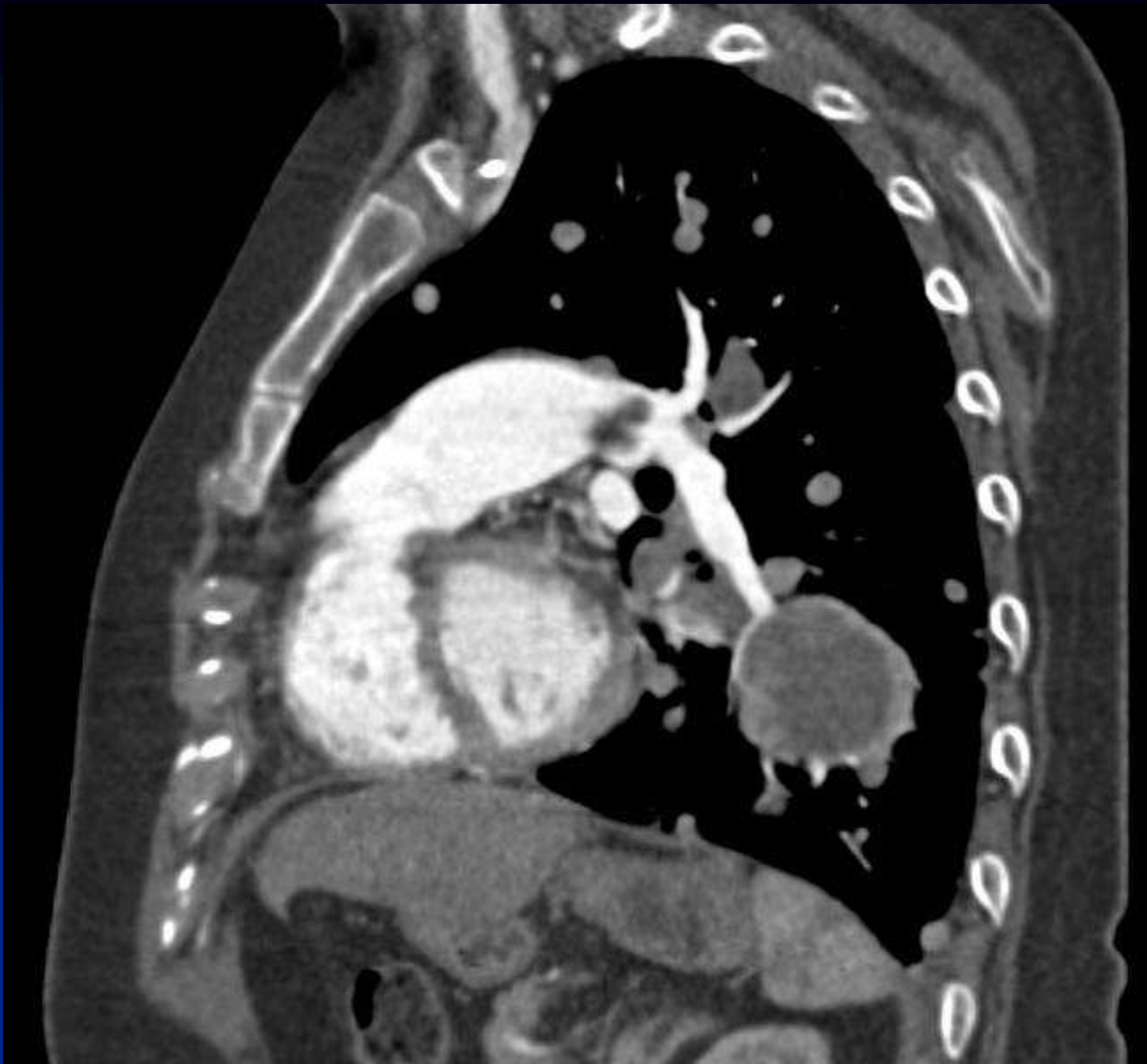- **Femme de 25 ans**
- **Tumeur de la cuisse droite**
- **Dyspnée**

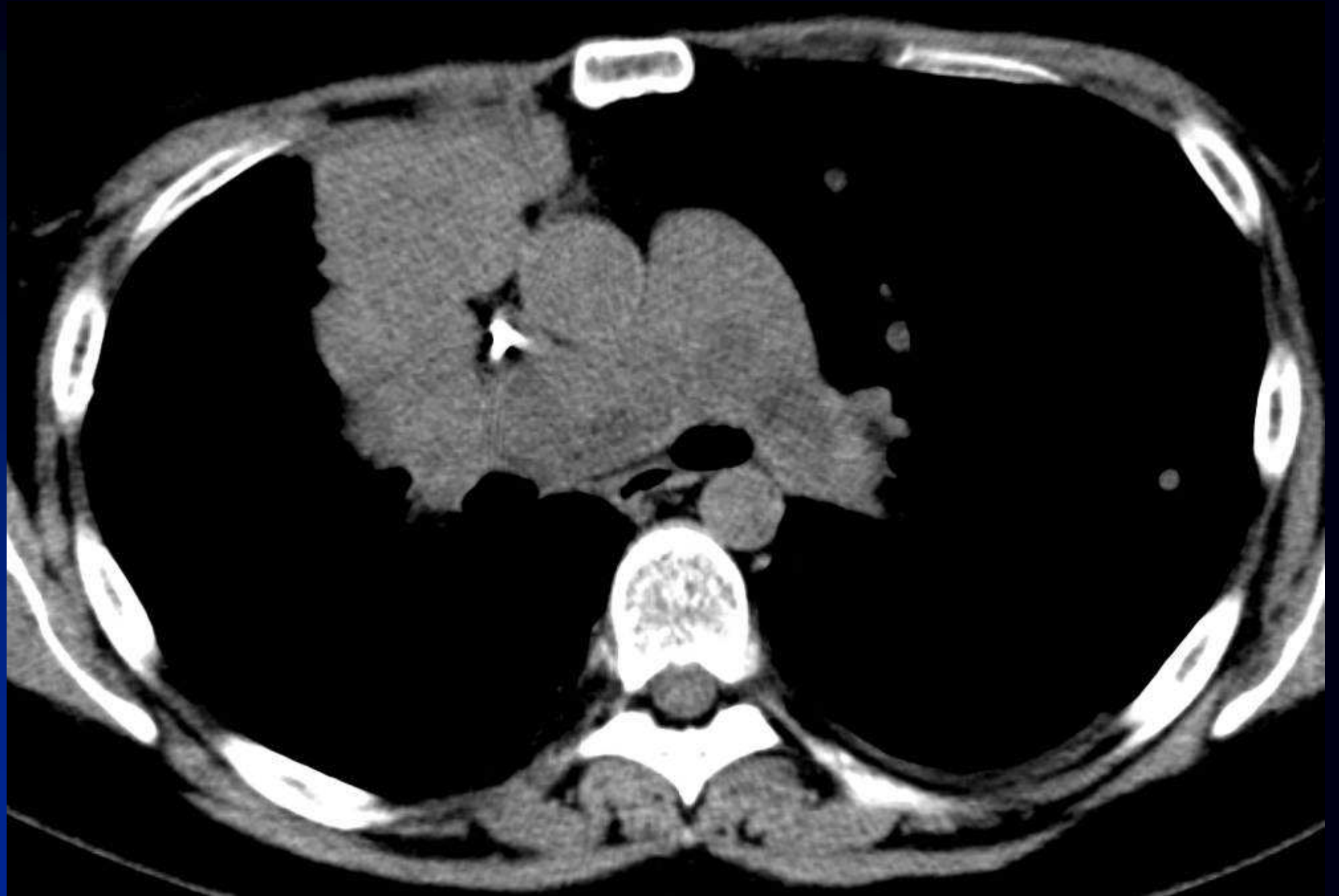

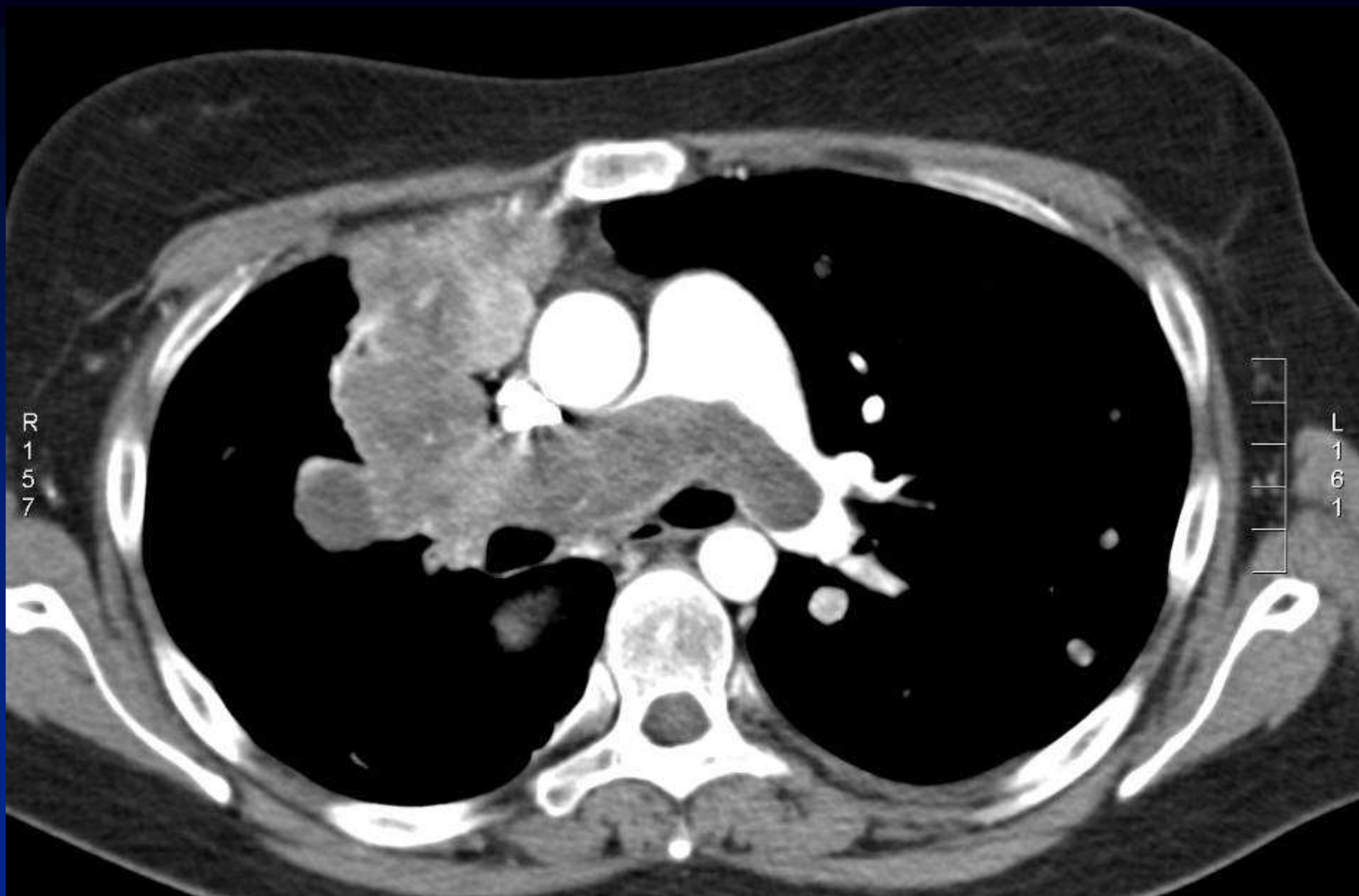


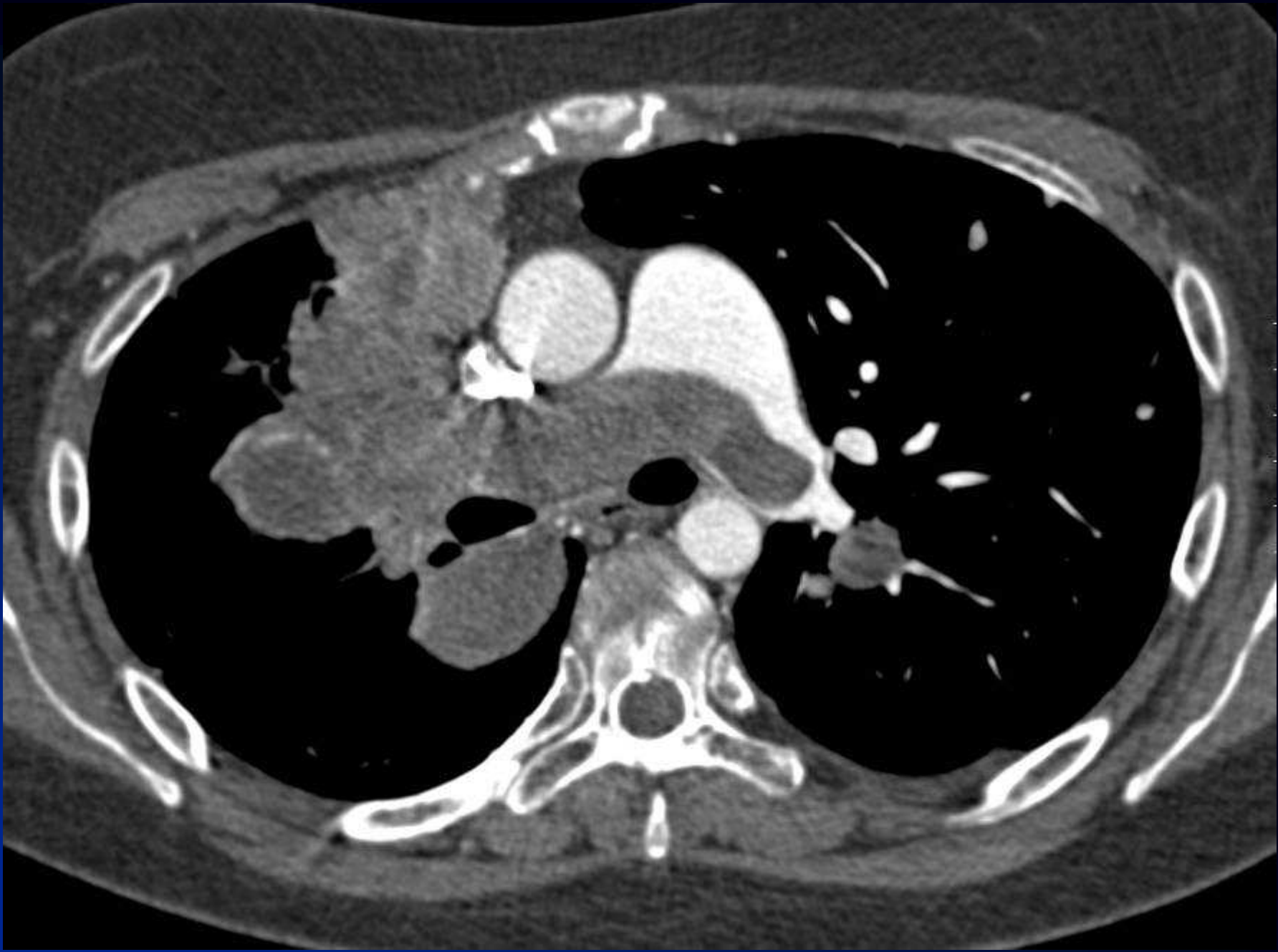


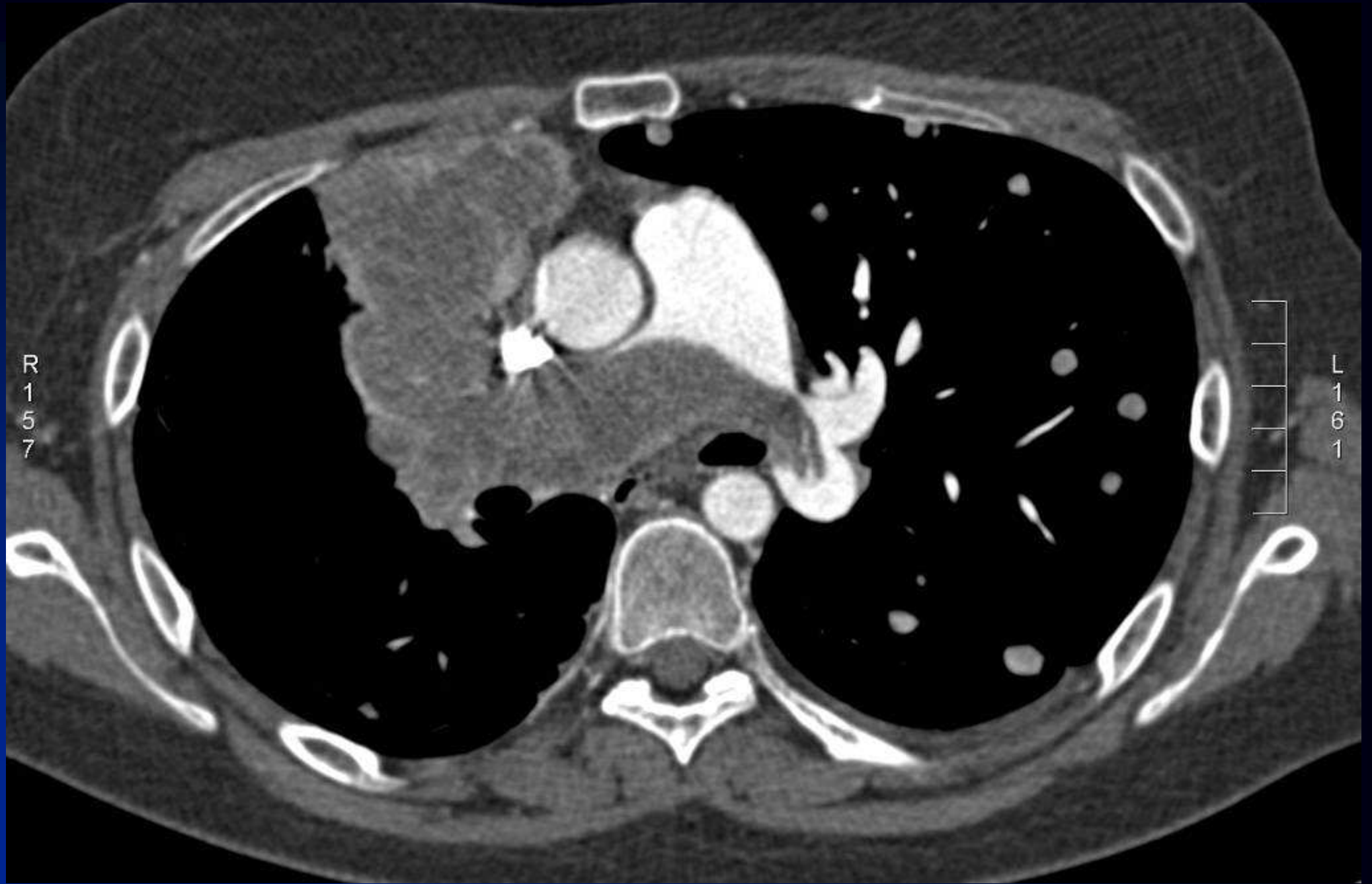R 1 5 7

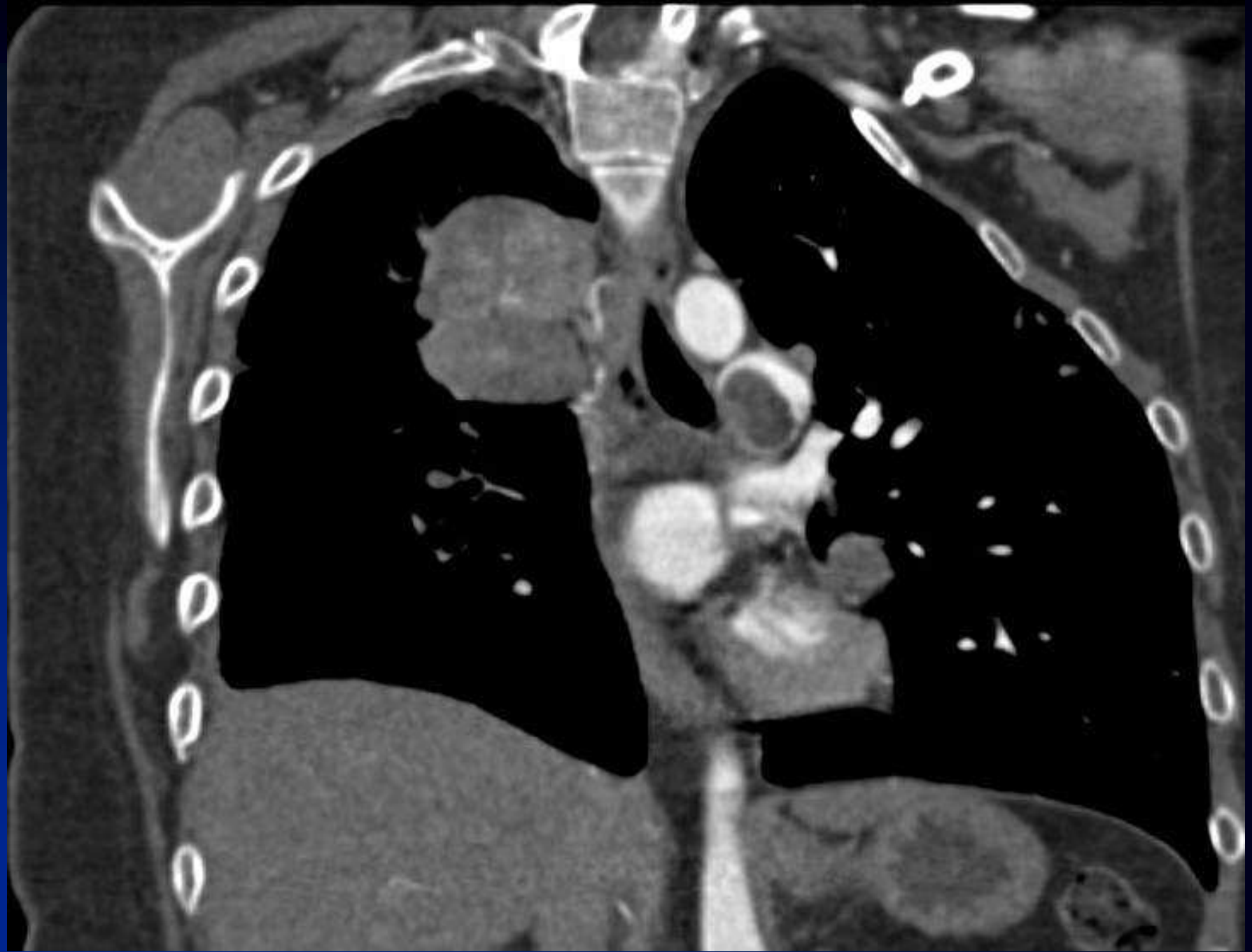


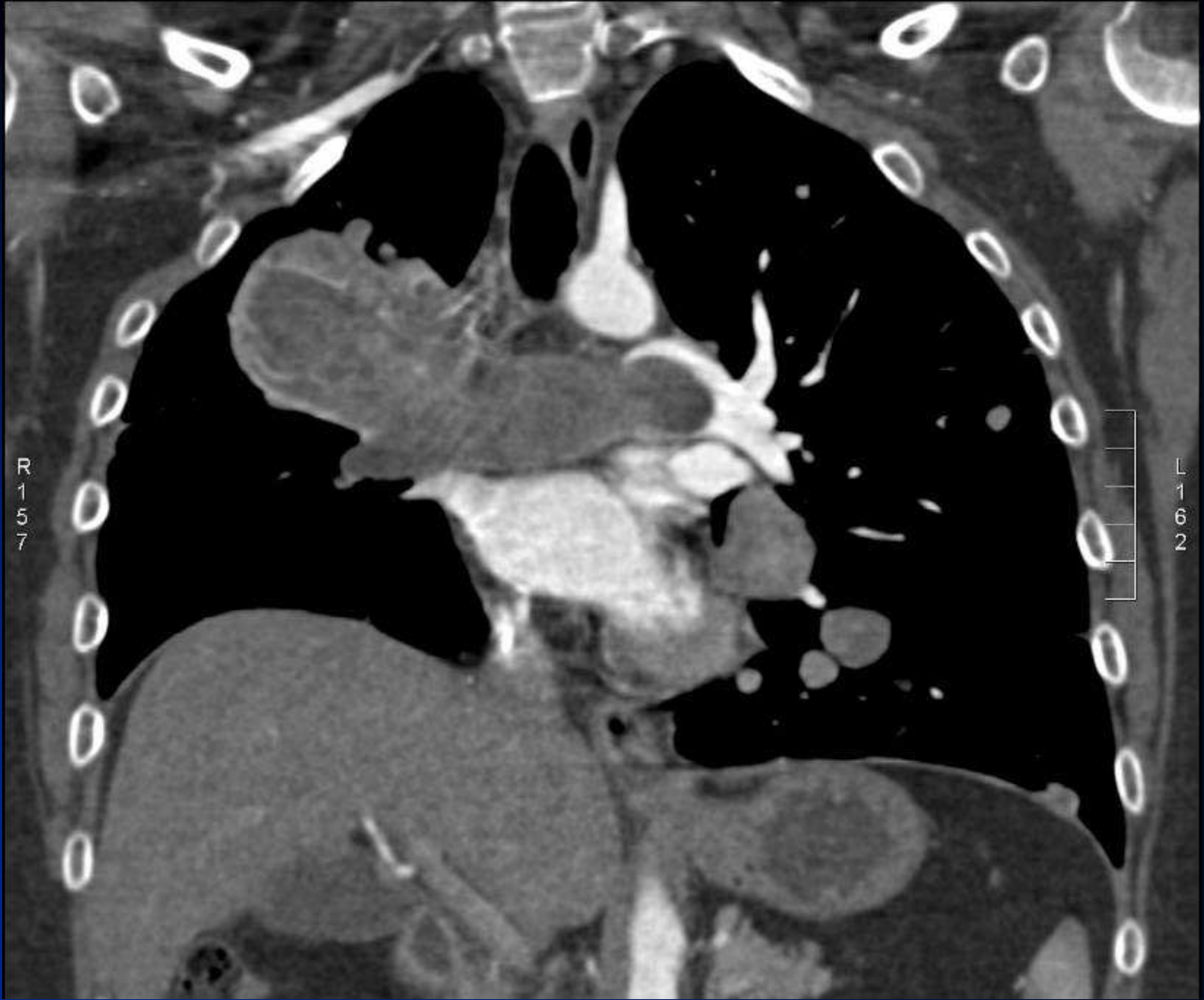












Diagnostic ?

Diagnostic

Sarcome des parties molles de la cuisse

Métastases pulmonaires et des artères pulmonaires