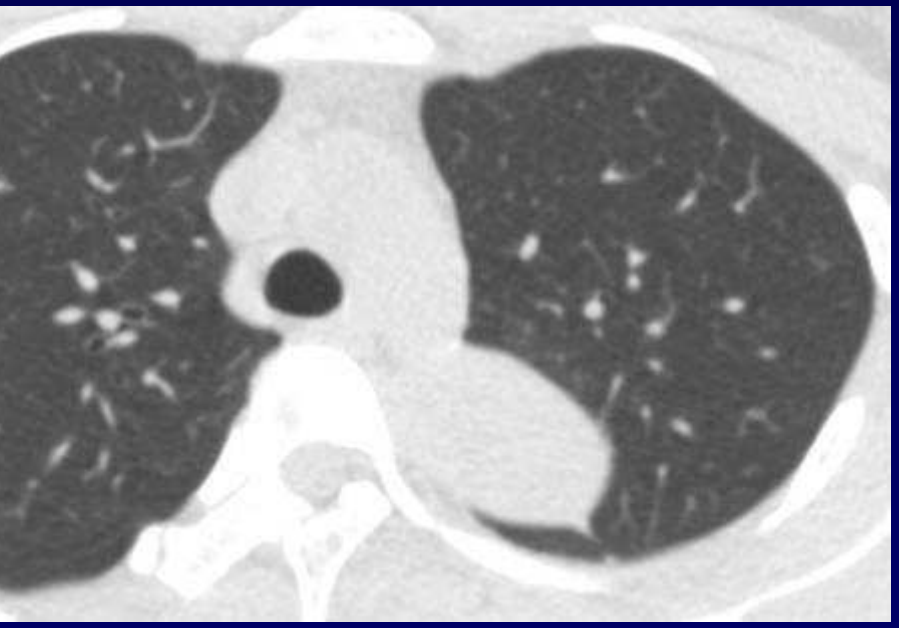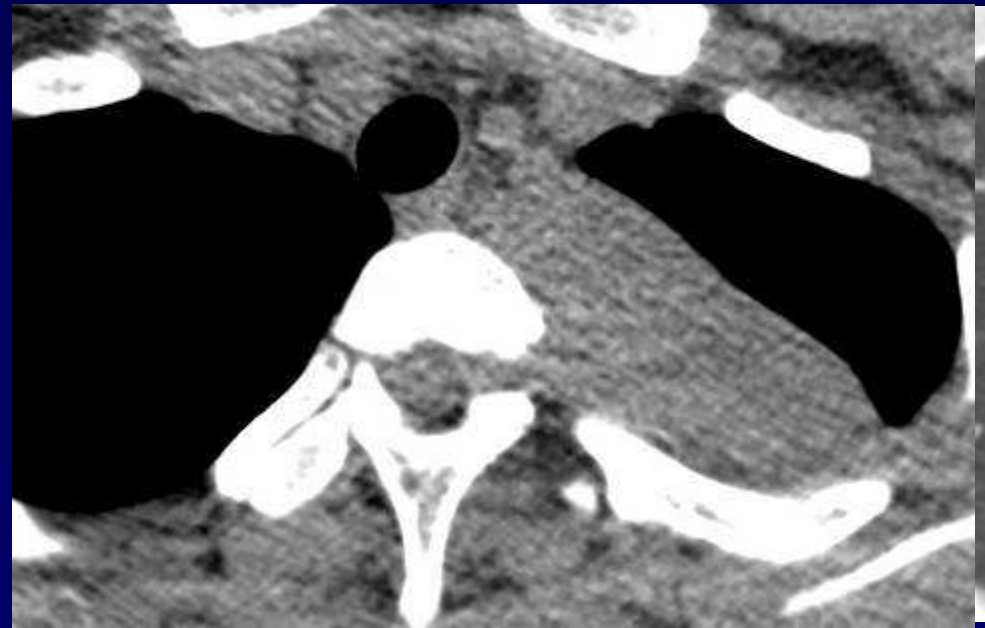
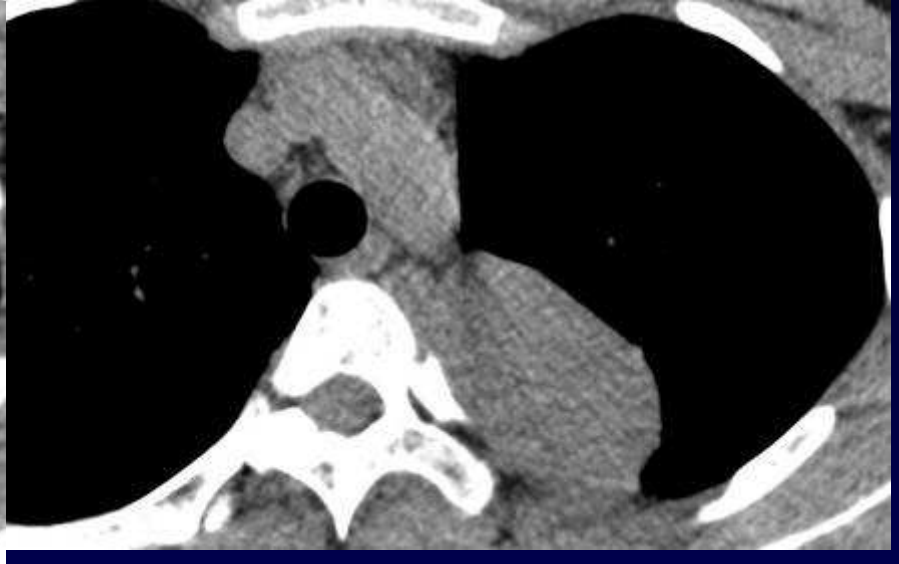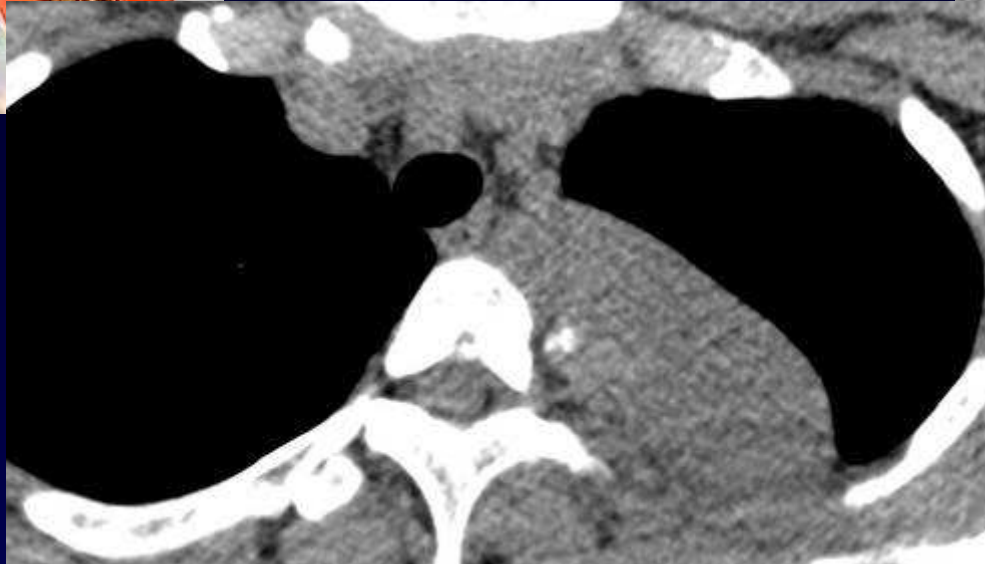


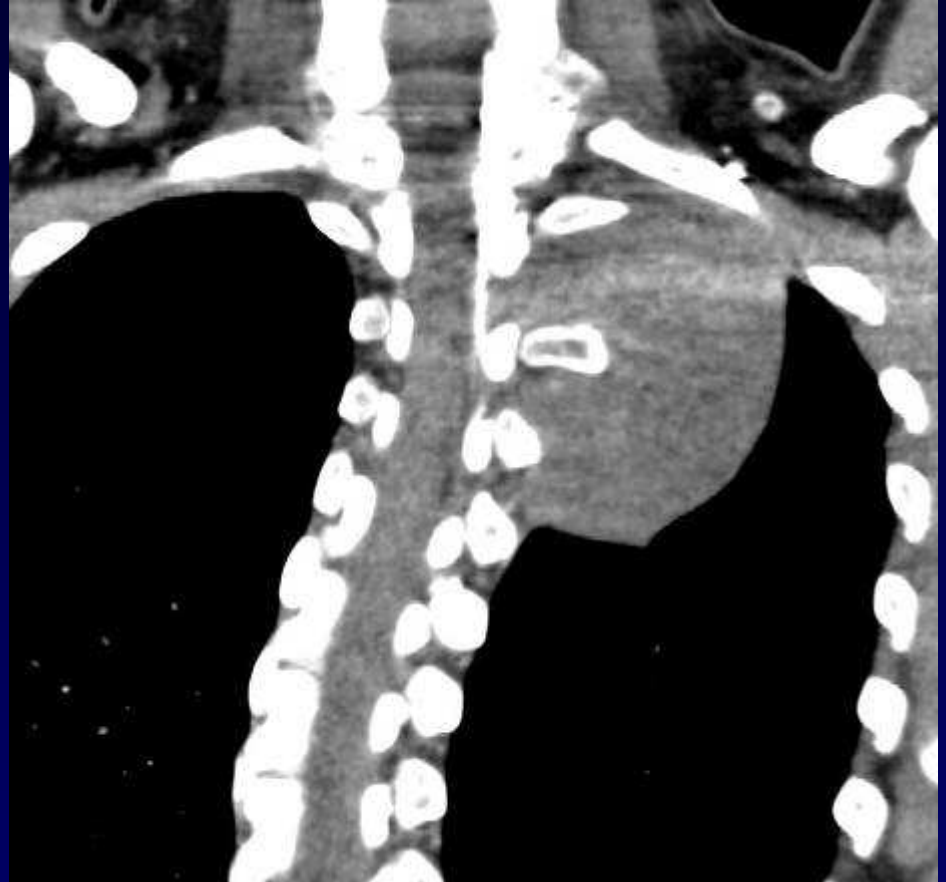
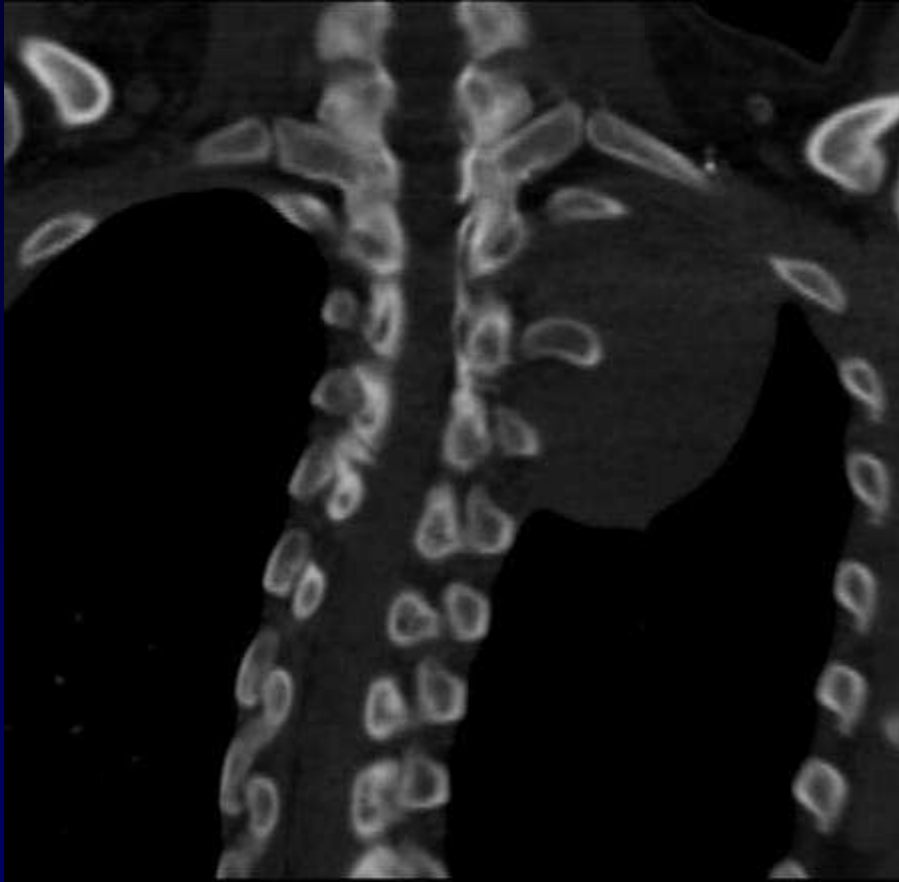


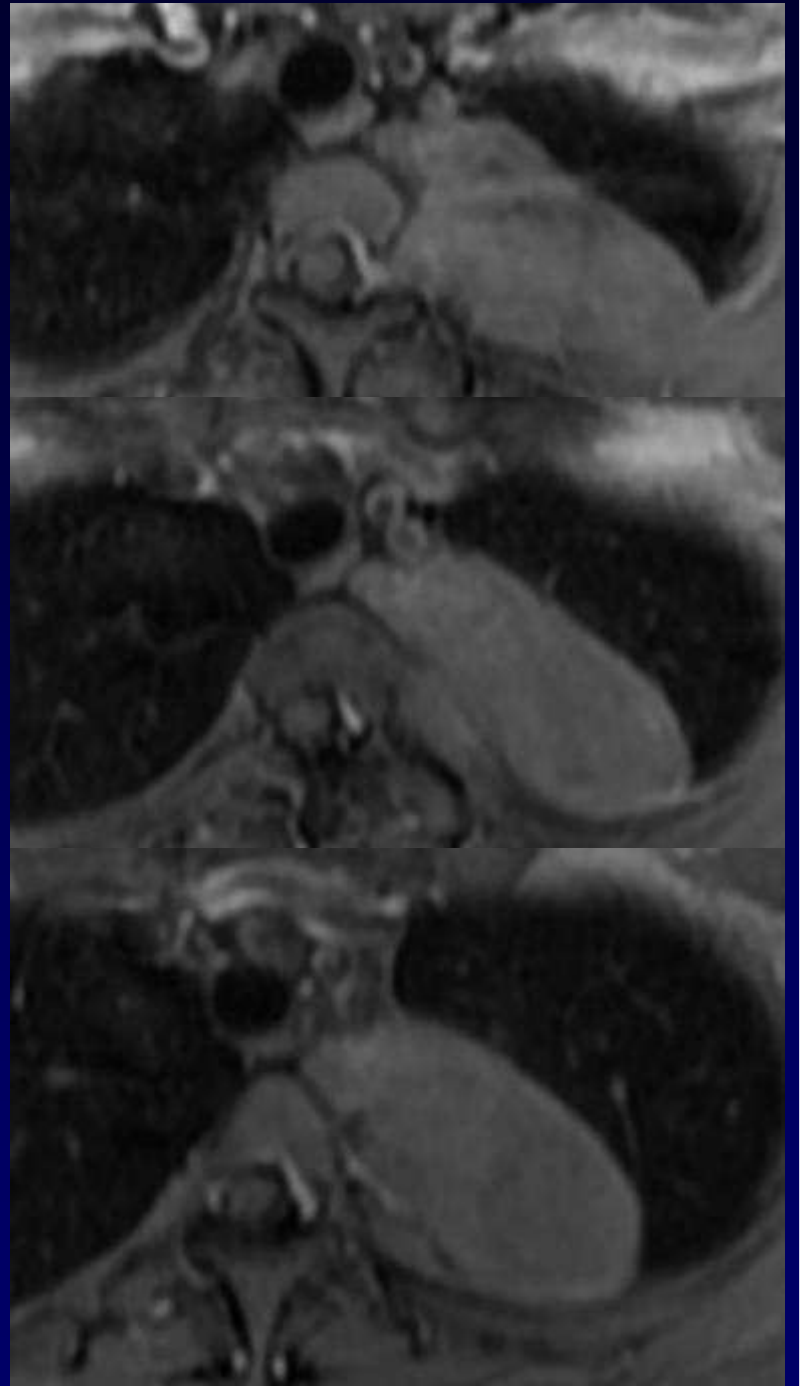
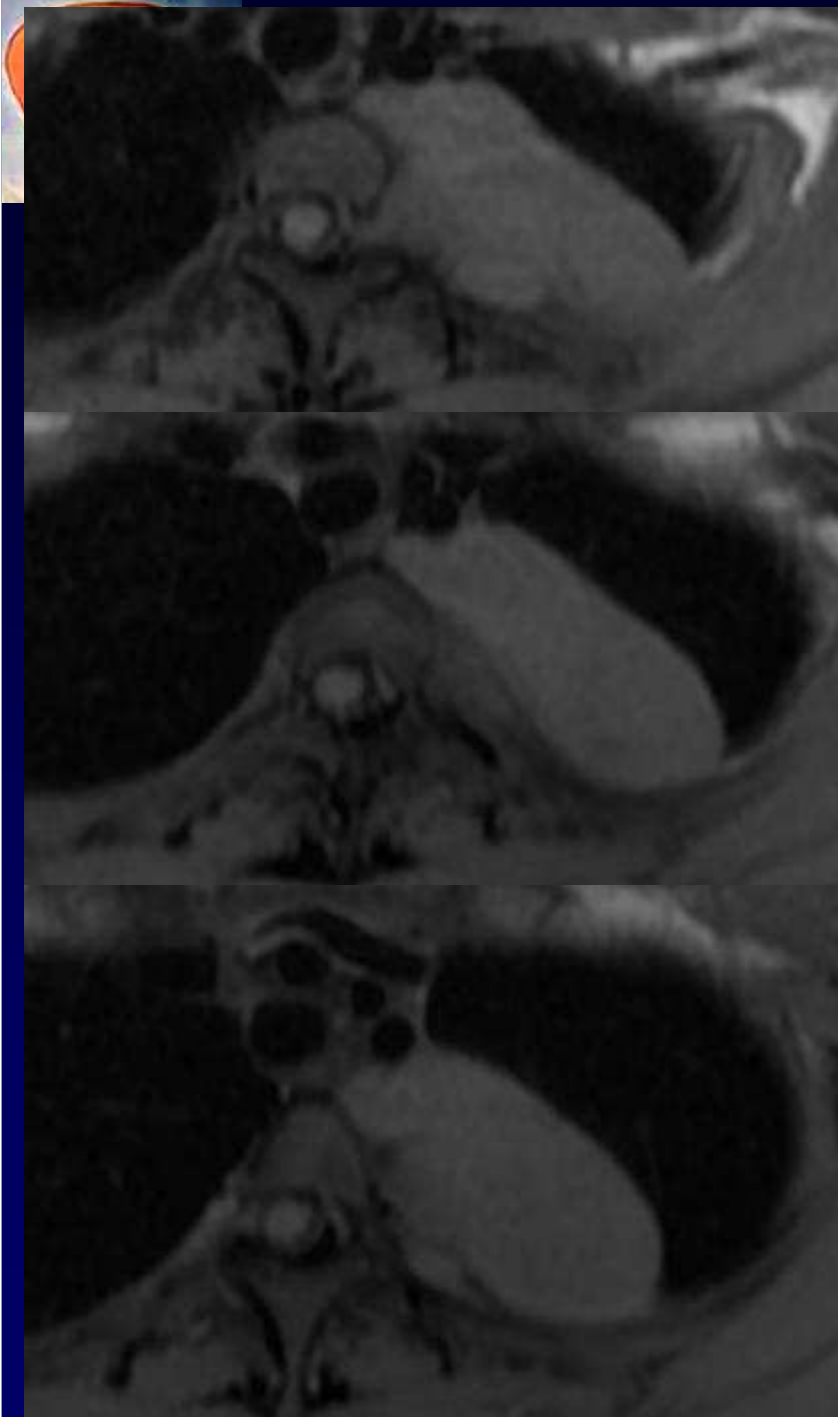
MP. DEBRAY

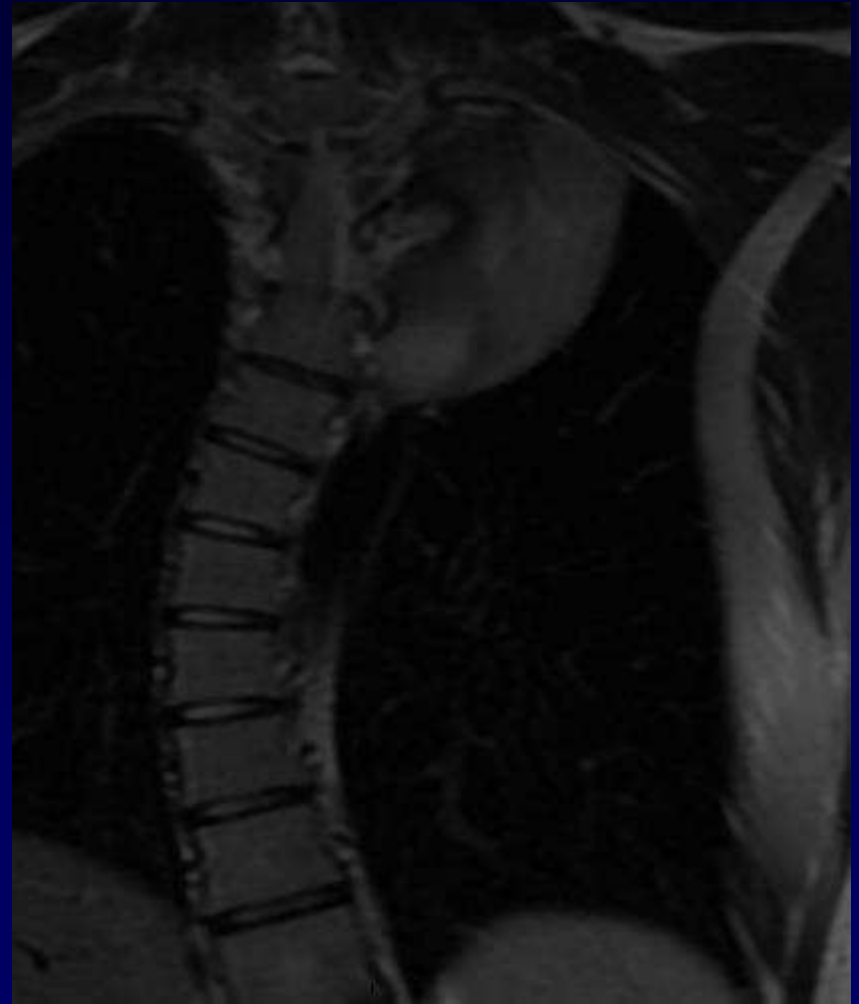
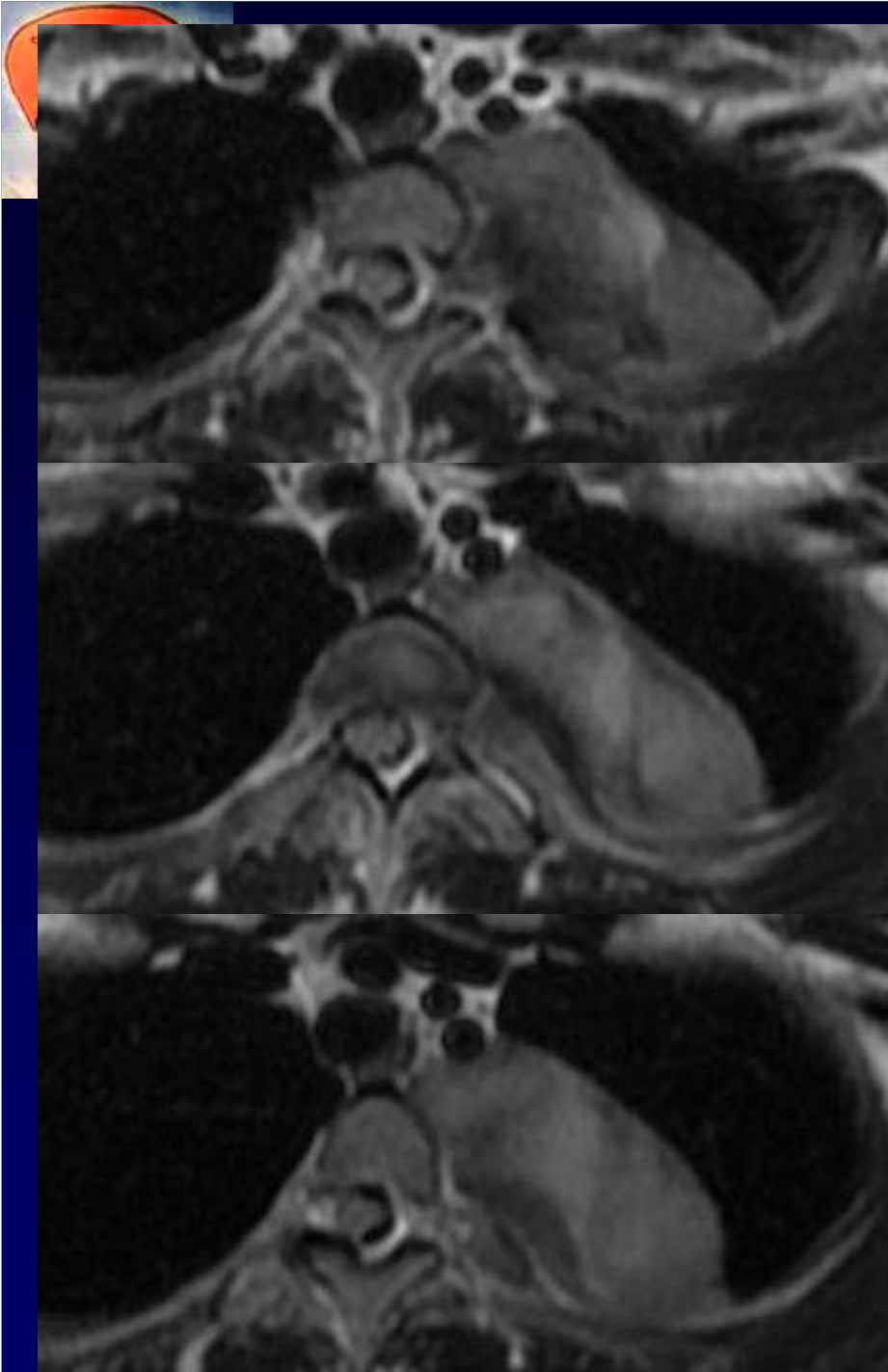
Femme de 30 ans

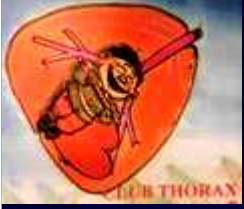Anomalie radiographique de découverte fortuite











Diagnostic ?



Diagnostic

Neurofibrome