

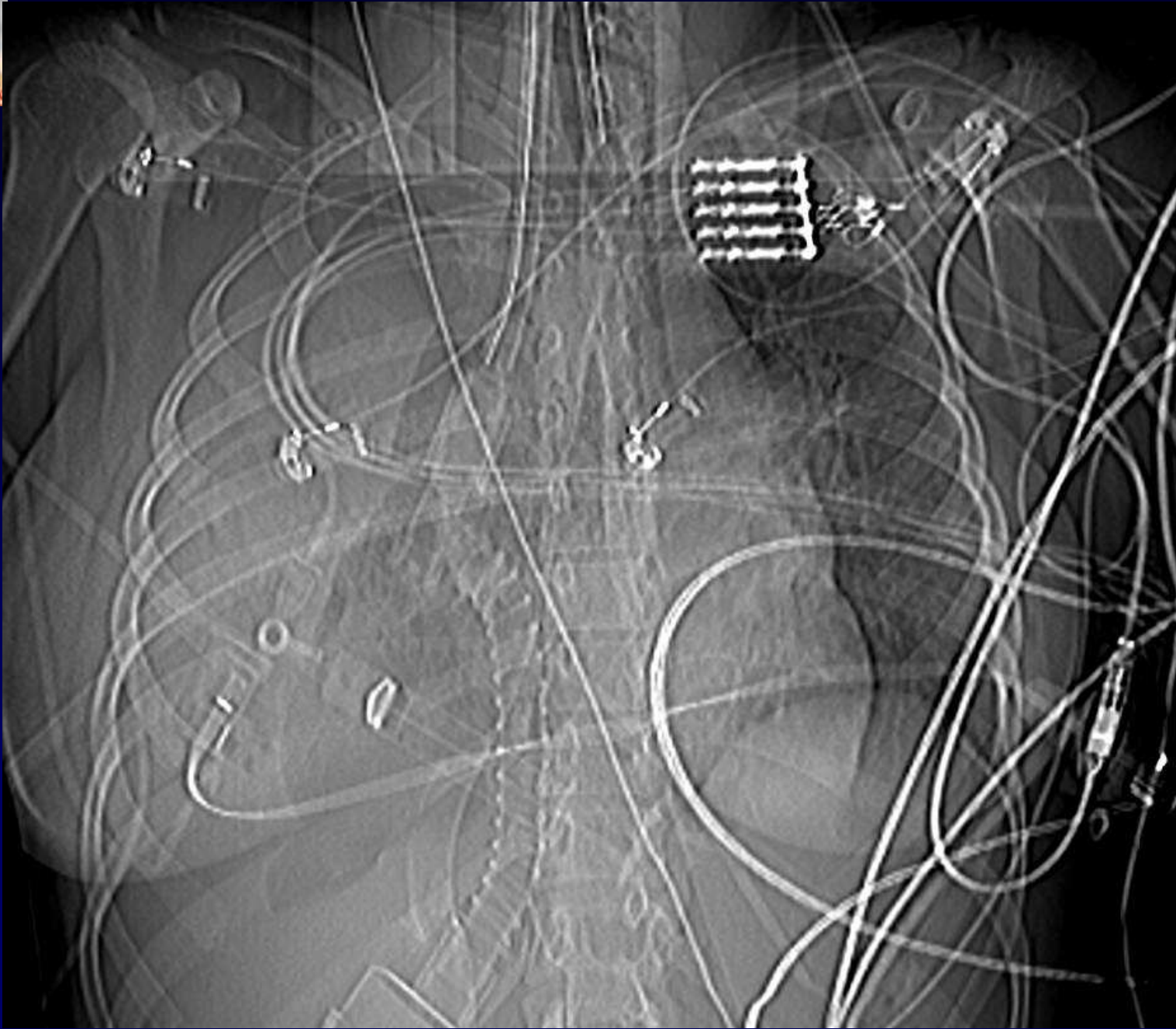


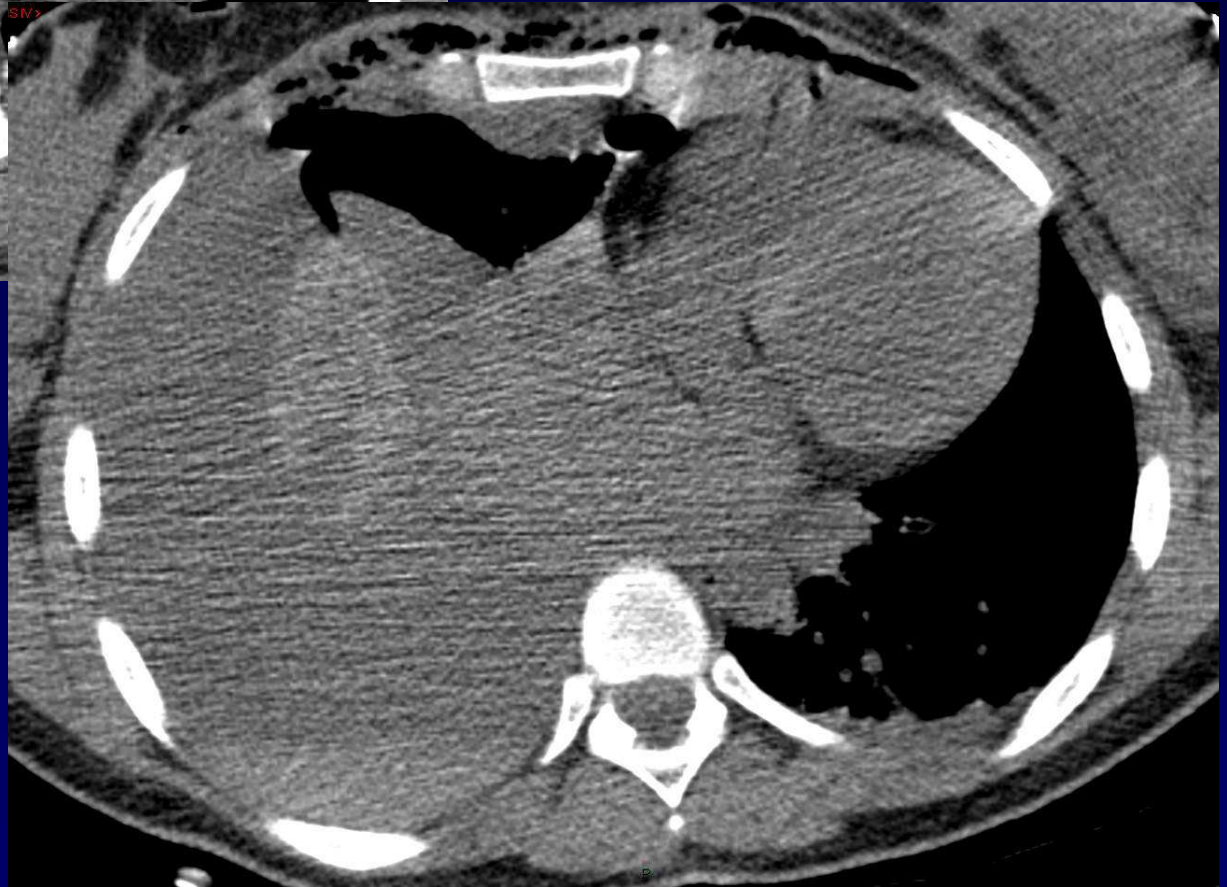
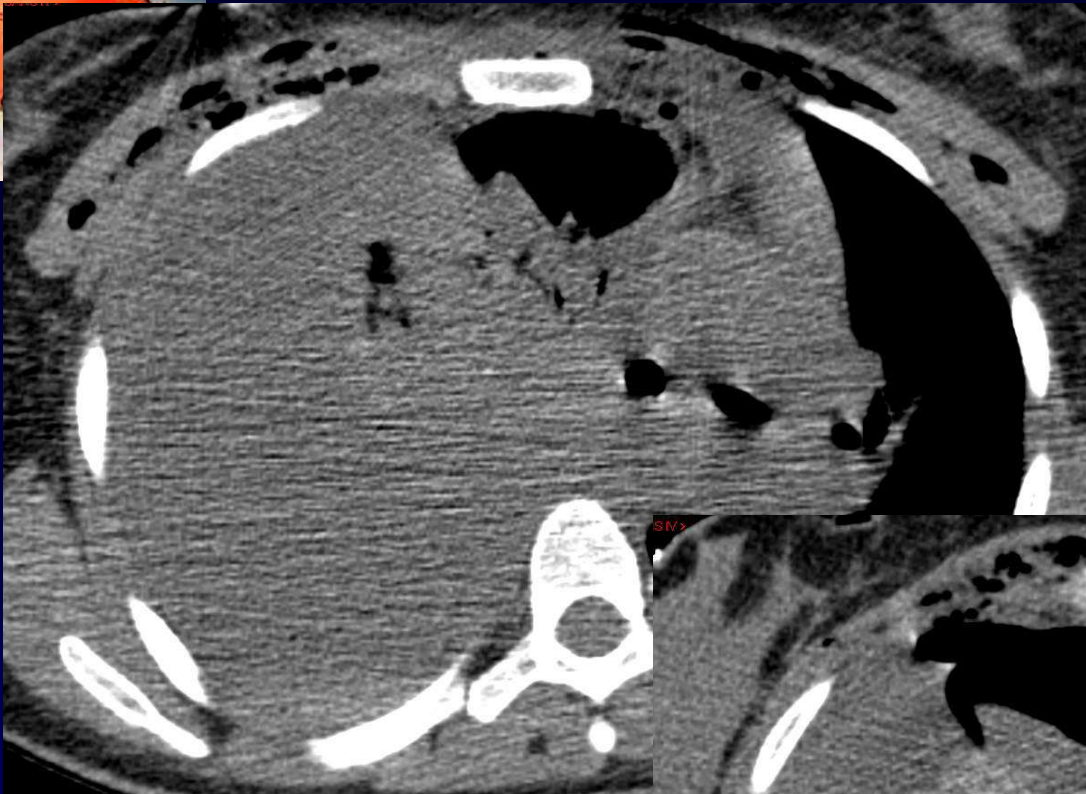
**MP. DEBRAY**

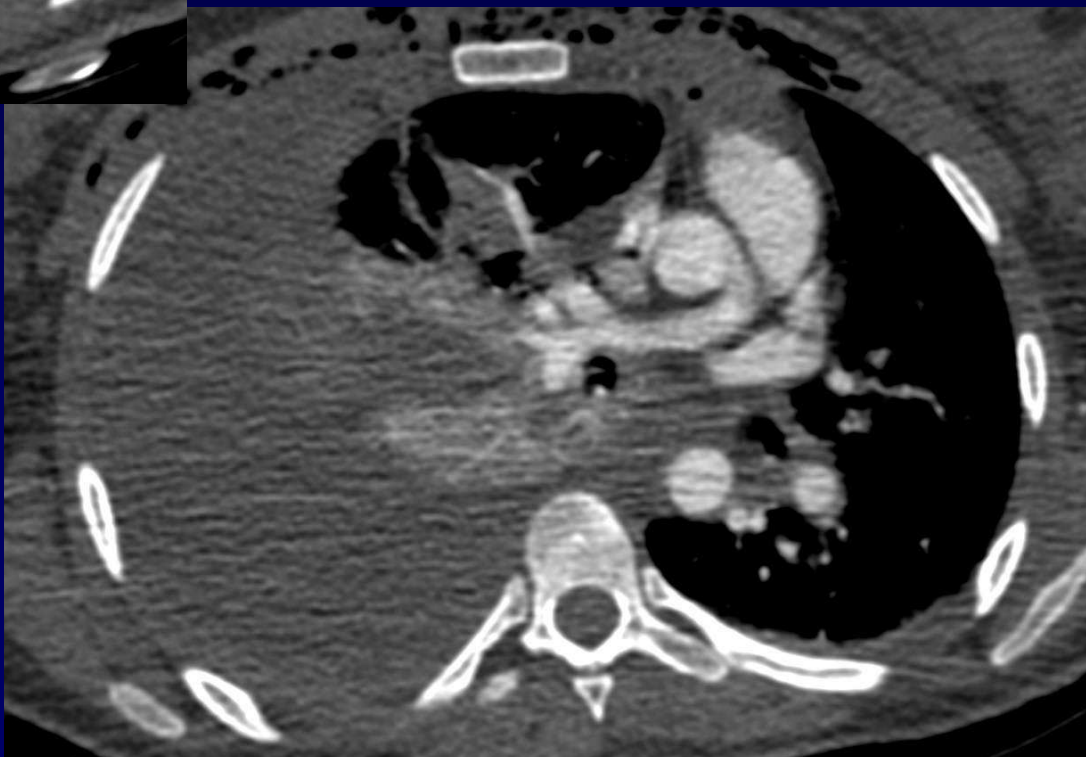
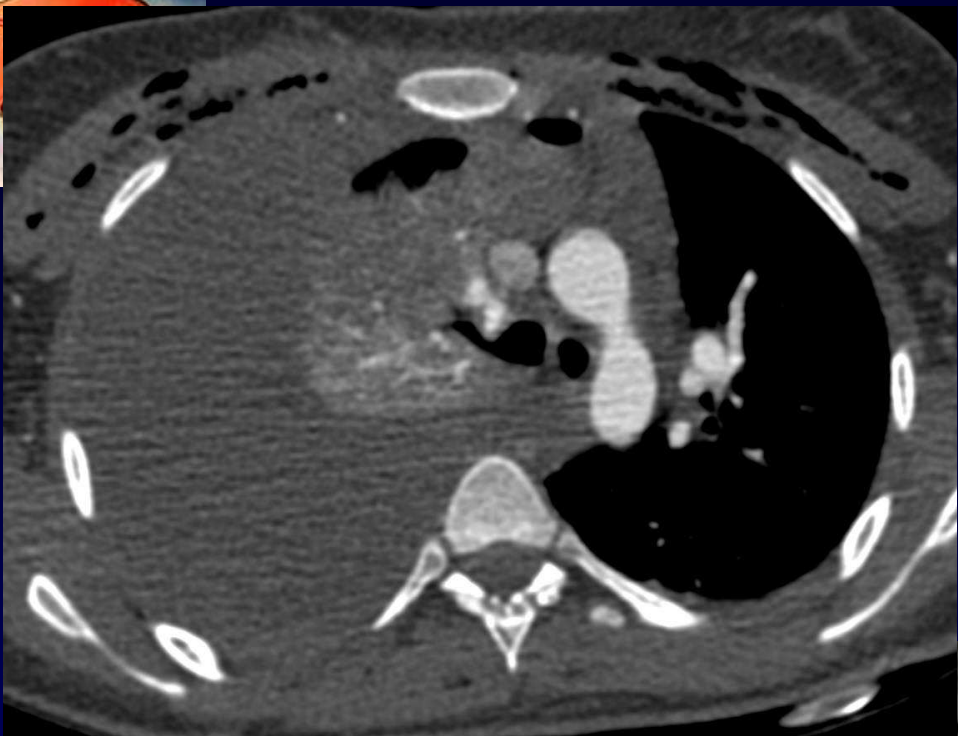
**Femme de 30 ans**

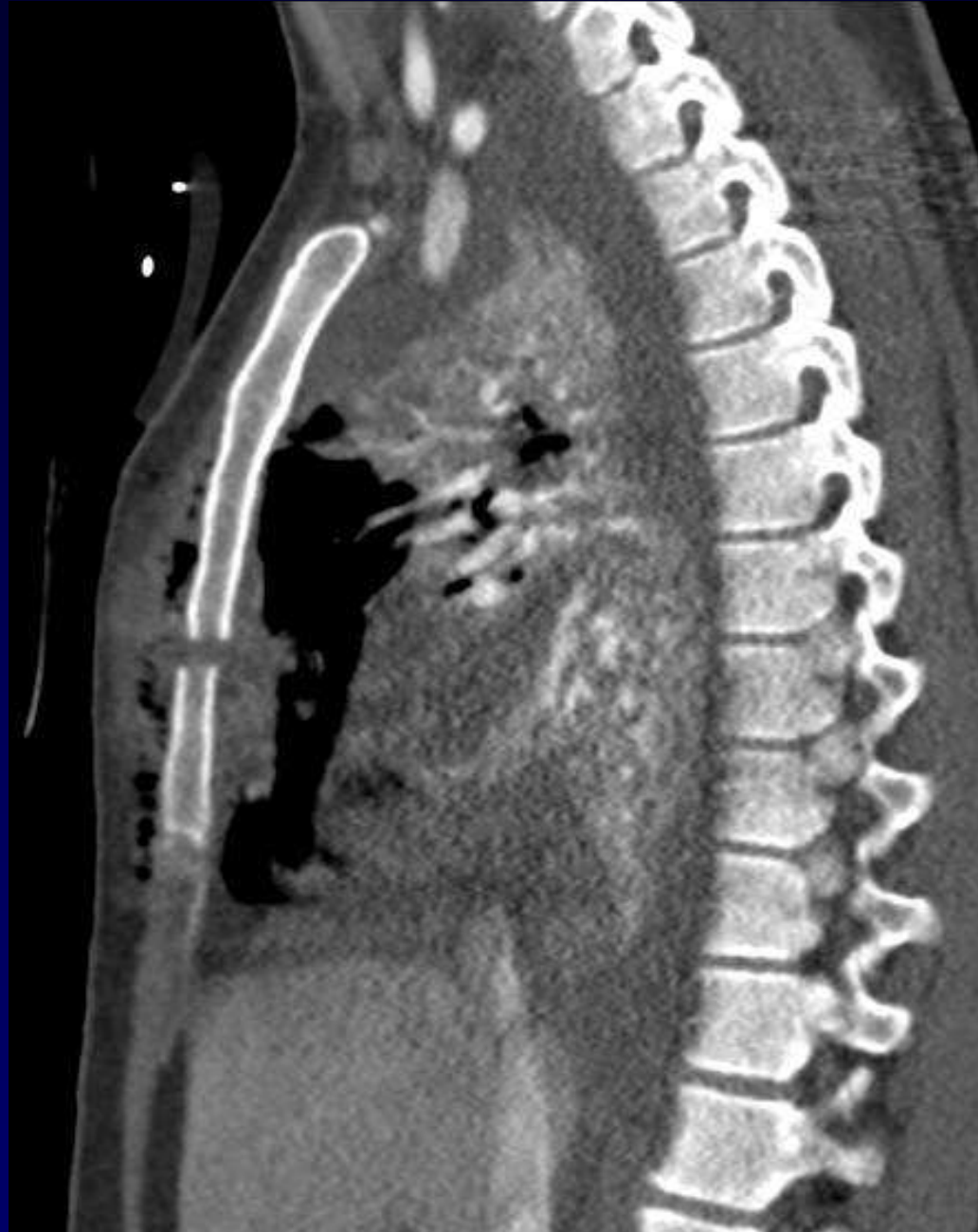**AVP**

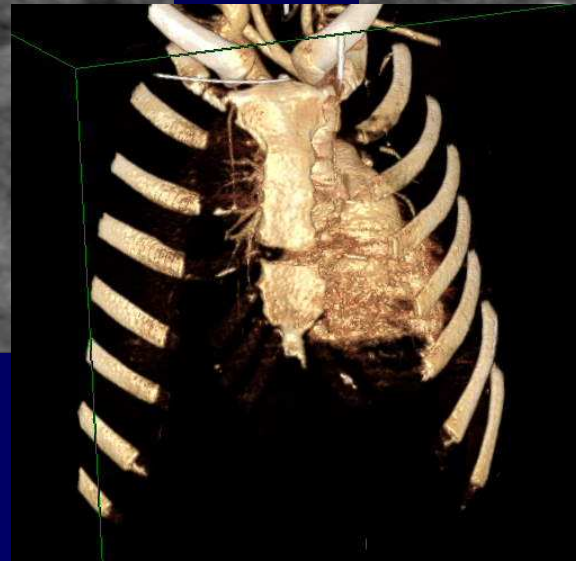
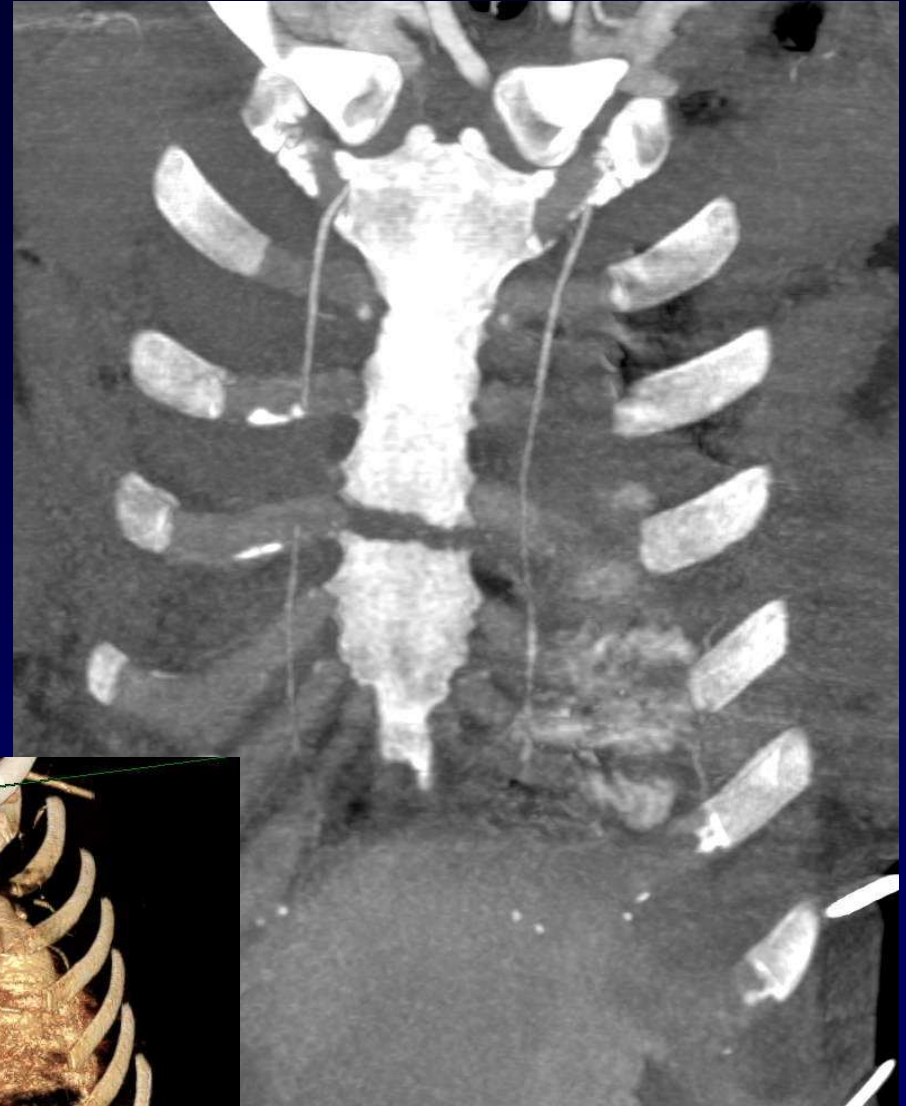
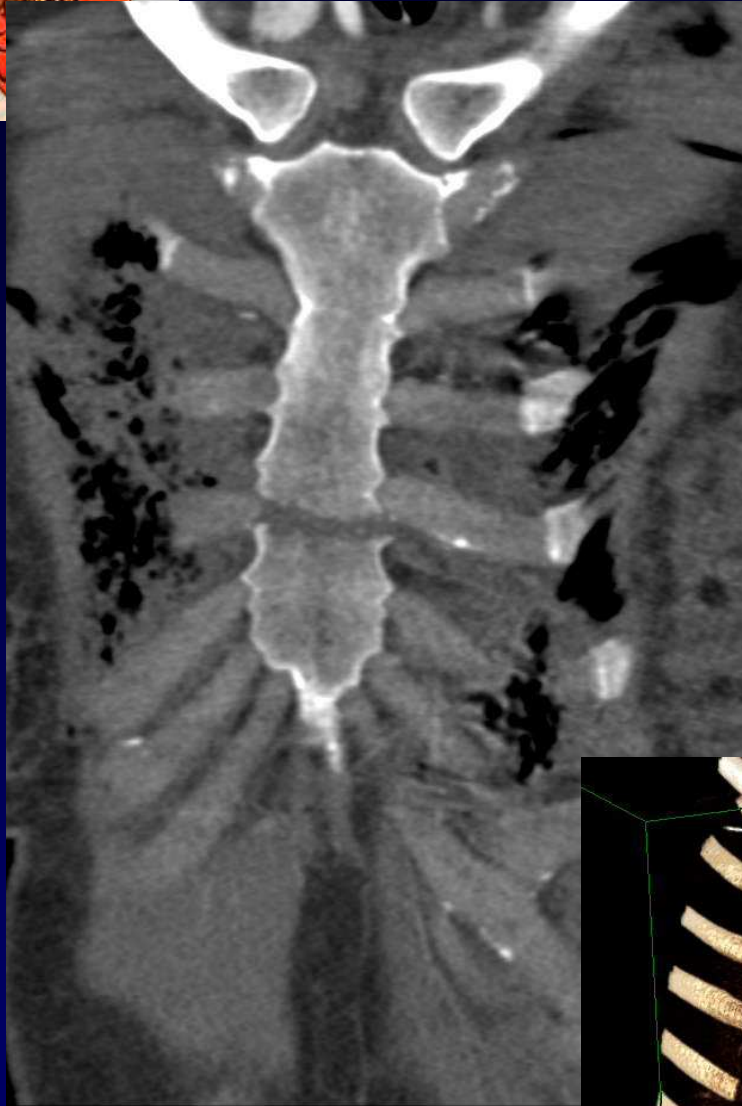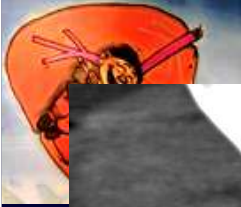**Instabilité hémodynamique**













**Diagnostic ?**



# Diagnostic

**Hémothorax droit secondaire à une fracture du sternum avec rupture des vaisseaux thoraciques internes droits**

