



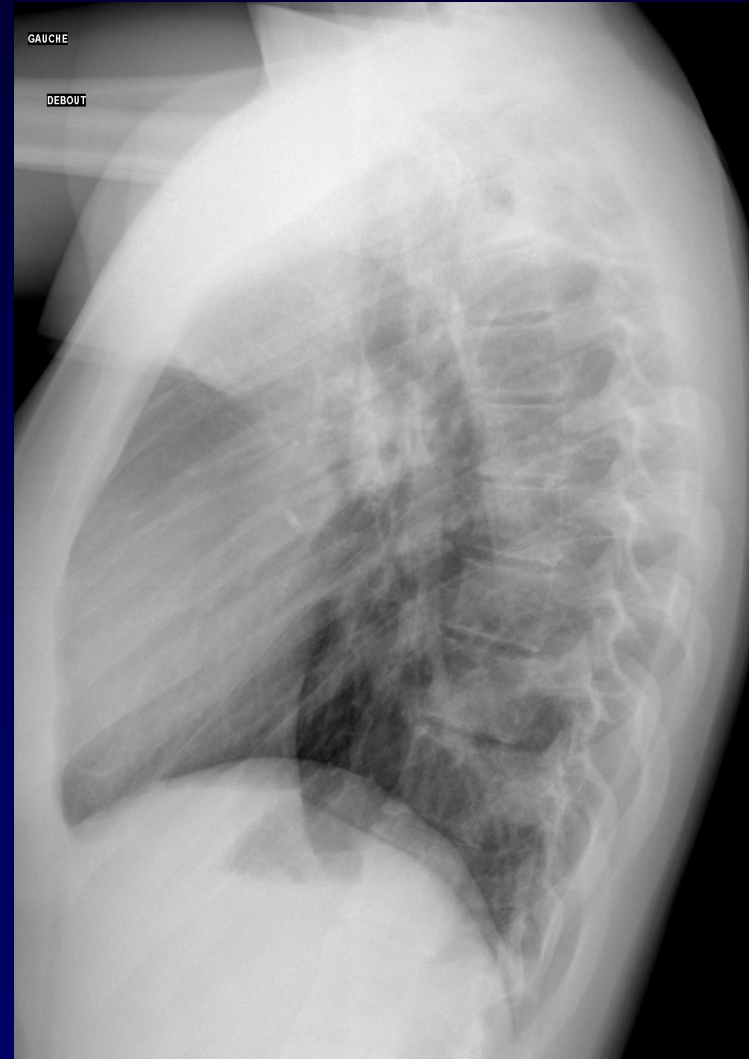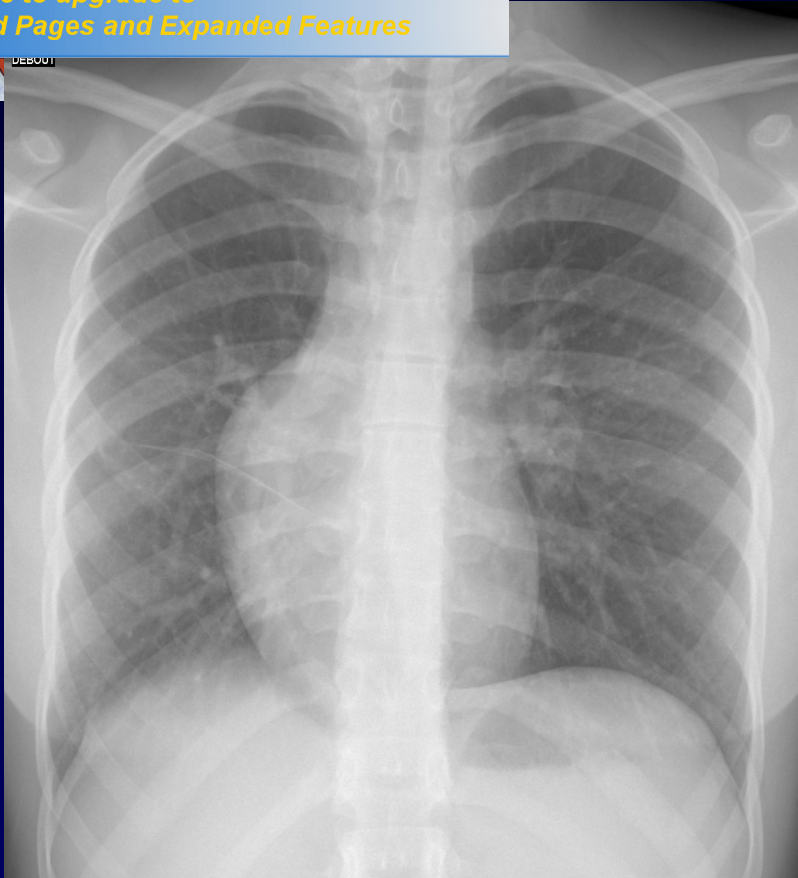
DOSSIER 3

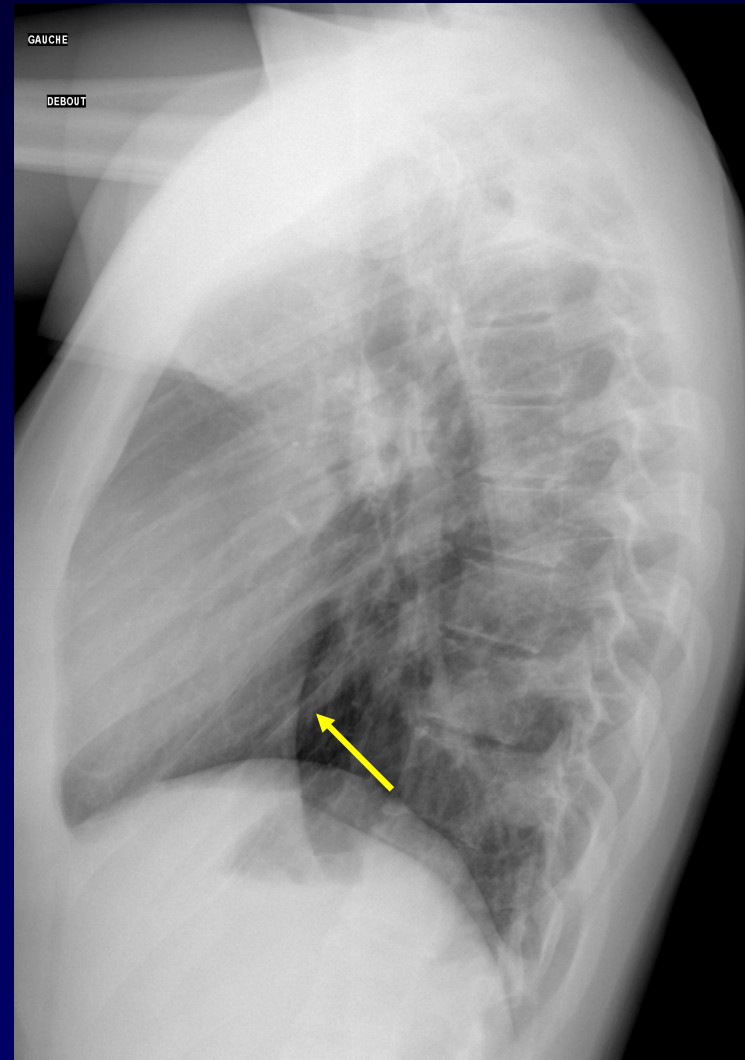
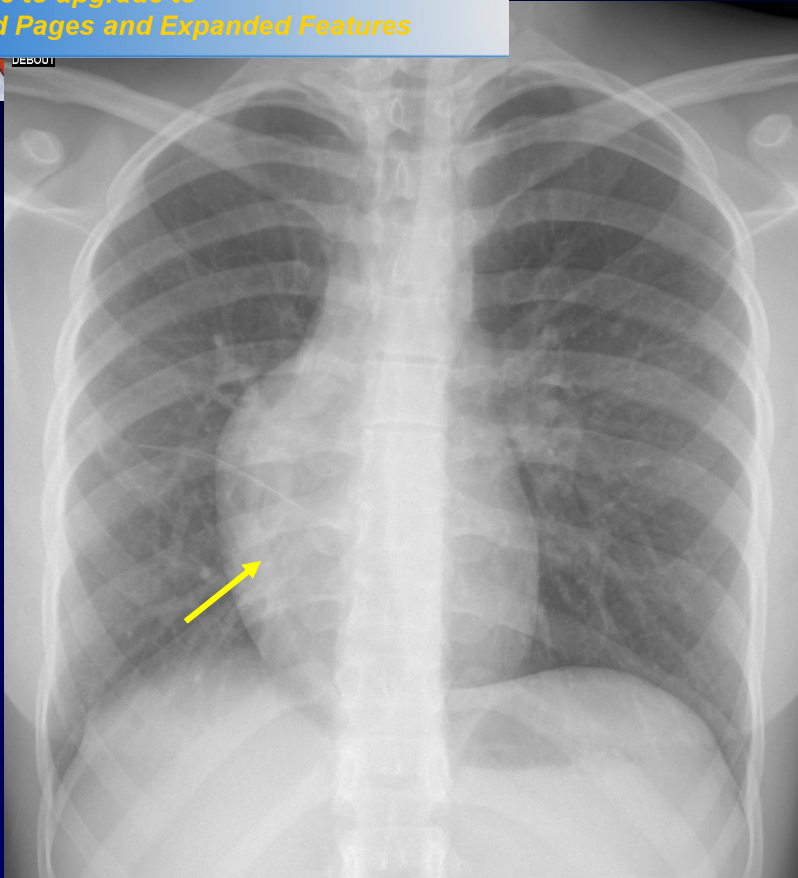
**J GIRON ó P FAJADET**

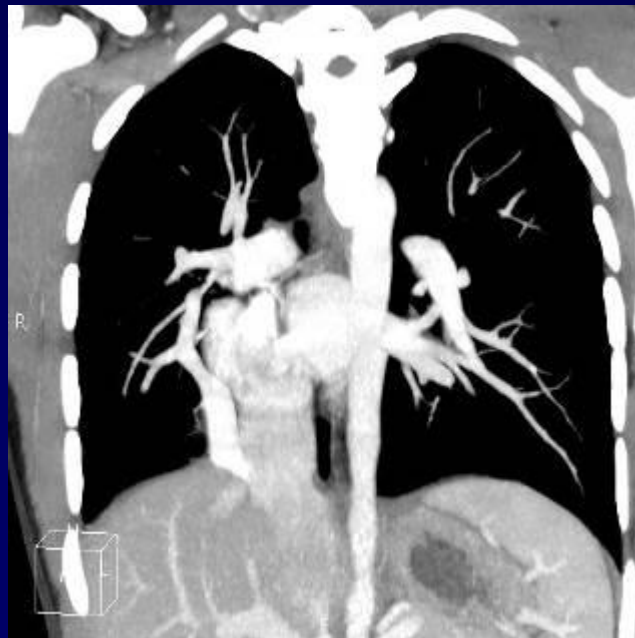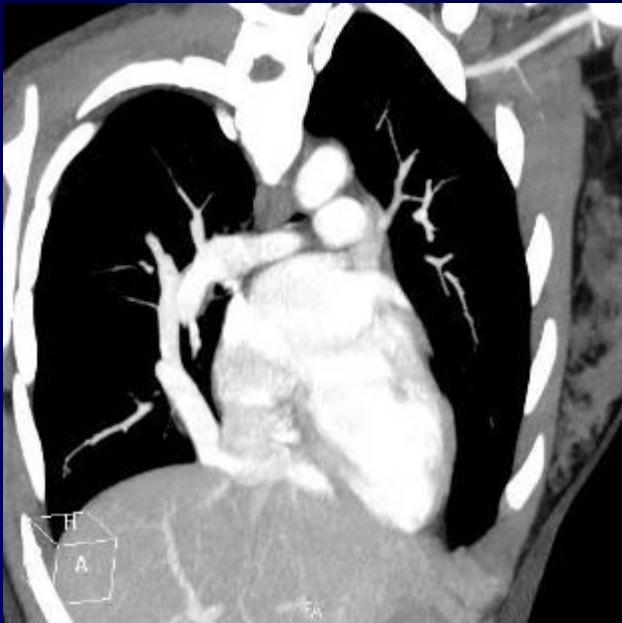
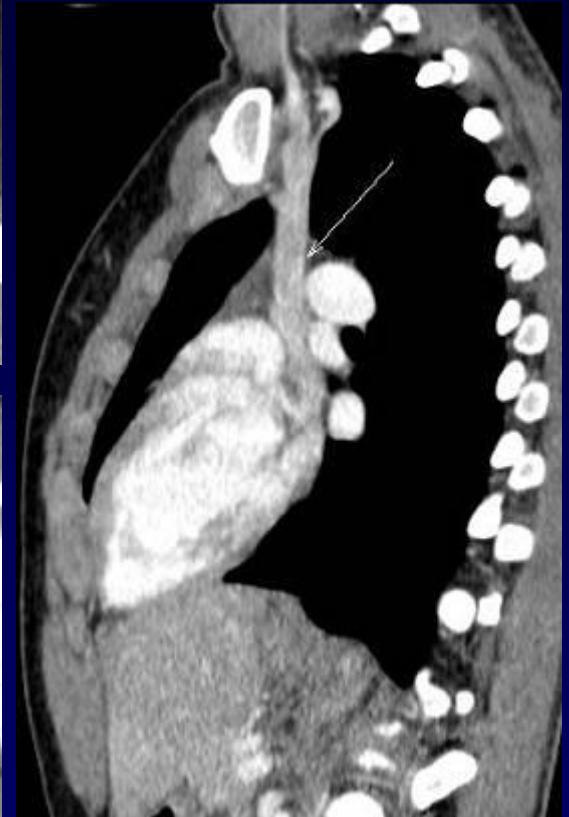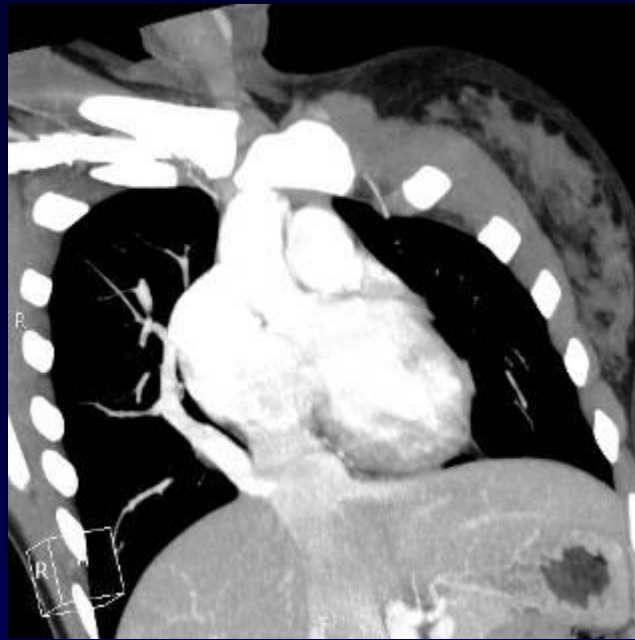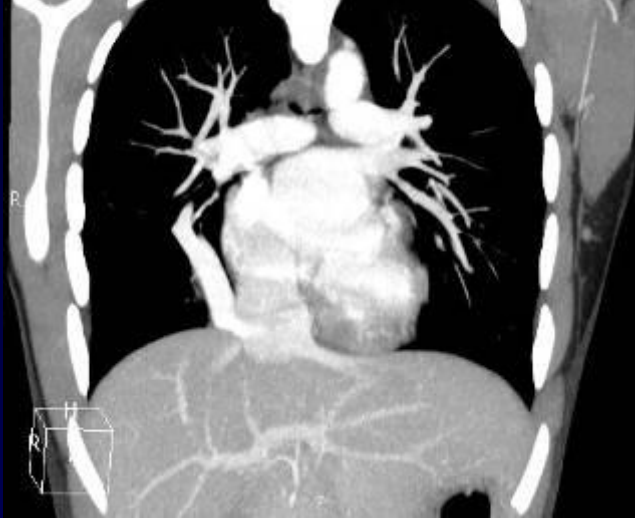
**Jeune femme de 20 ans**

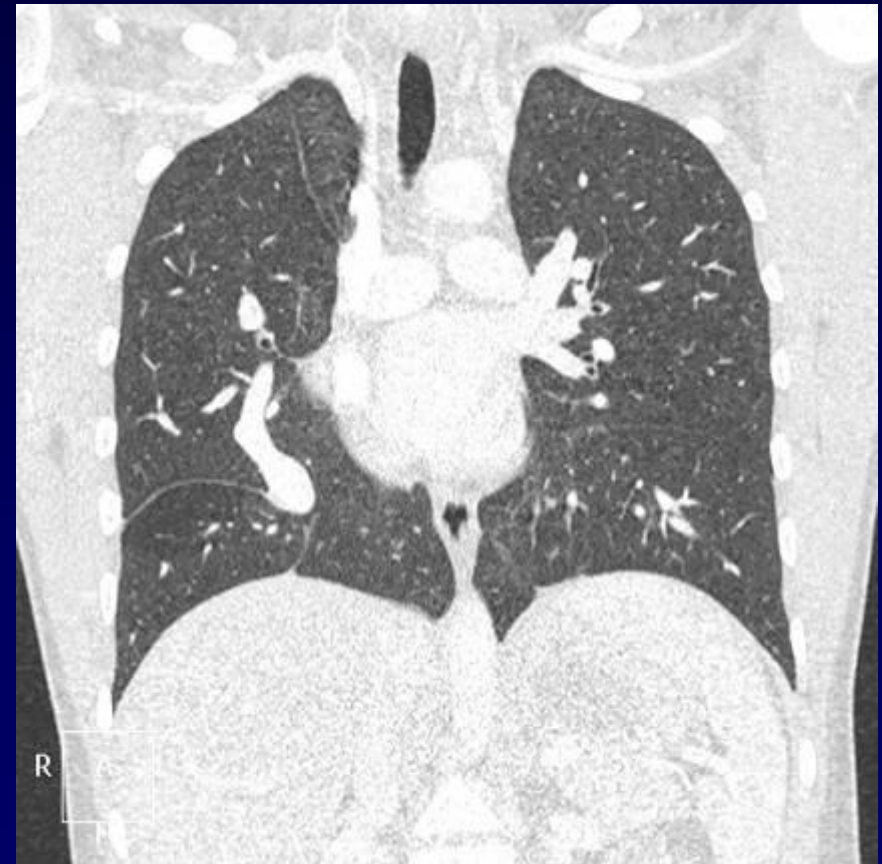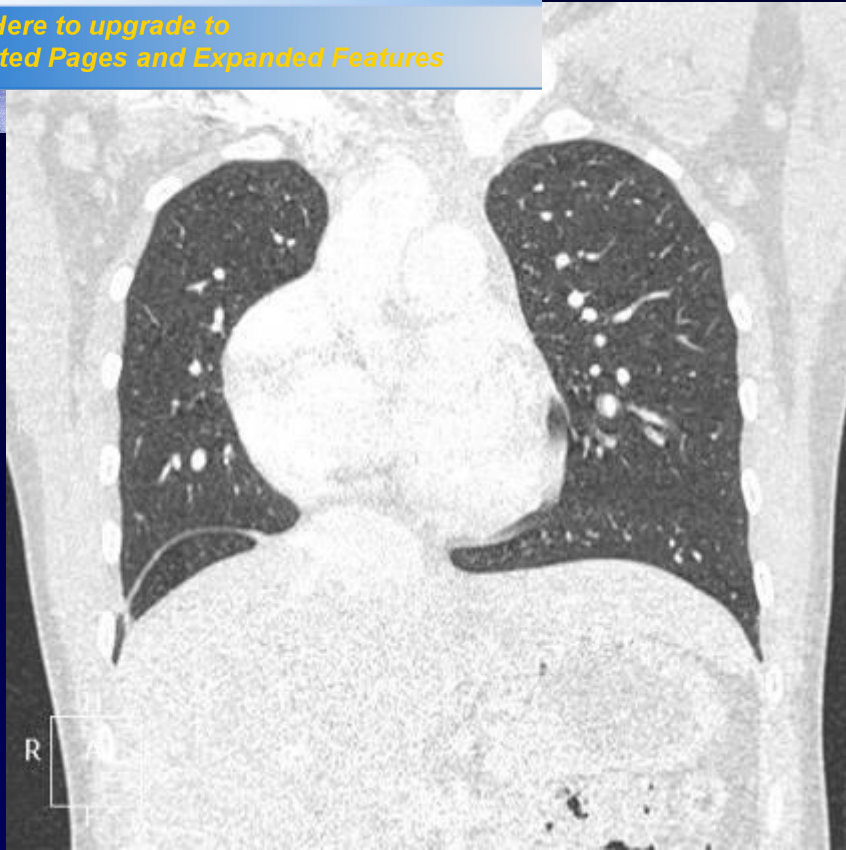
**Clinique : palpitations**

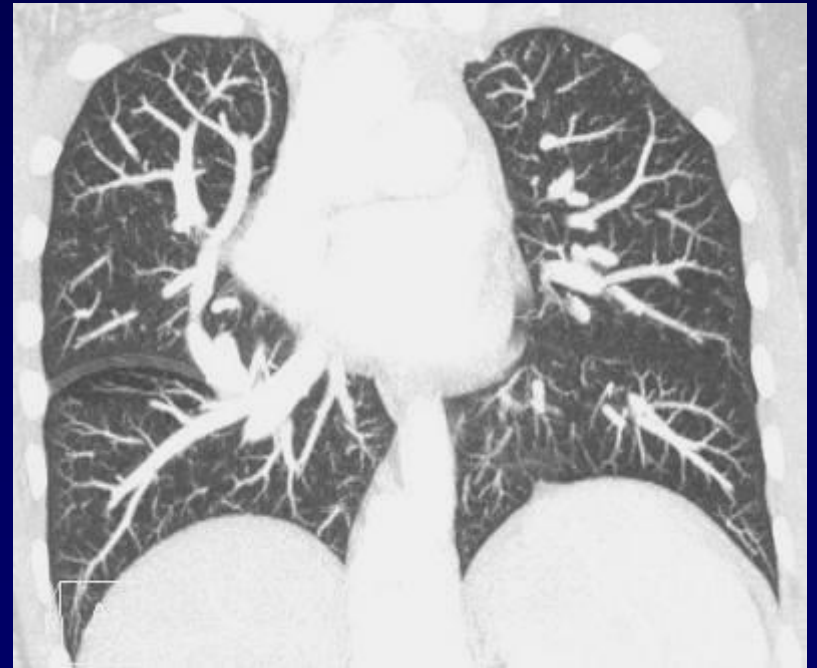
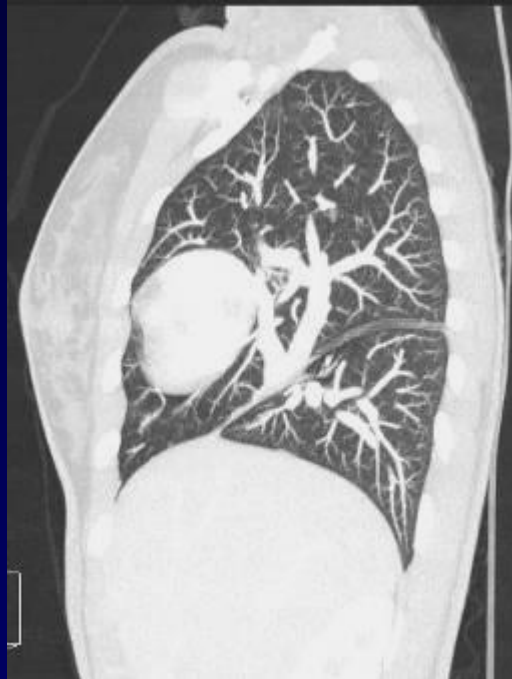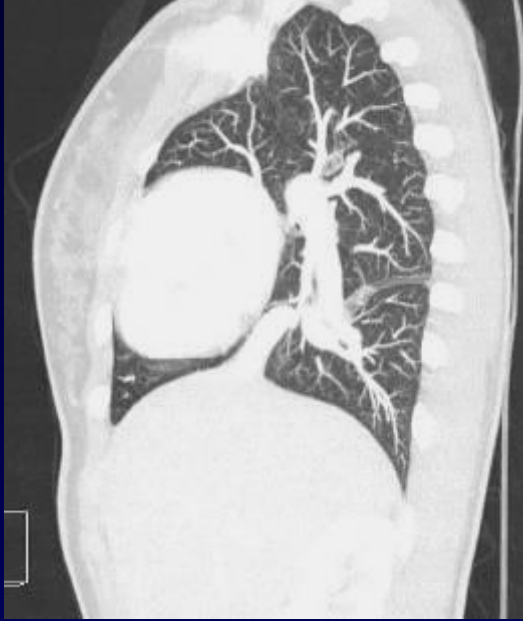**ECG normal**











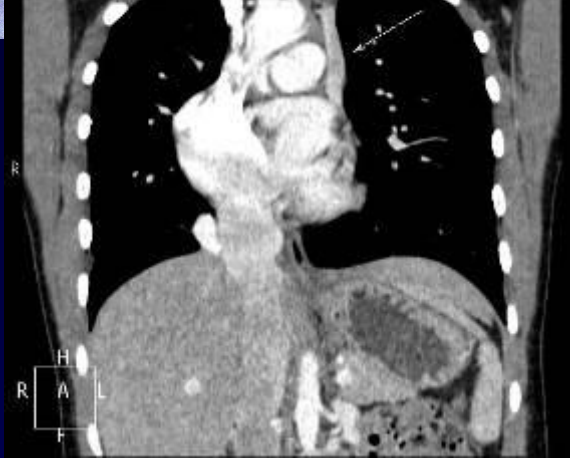

*Your complimentary  
use period has ended.  
Thank you for using  
PDF Complete.*

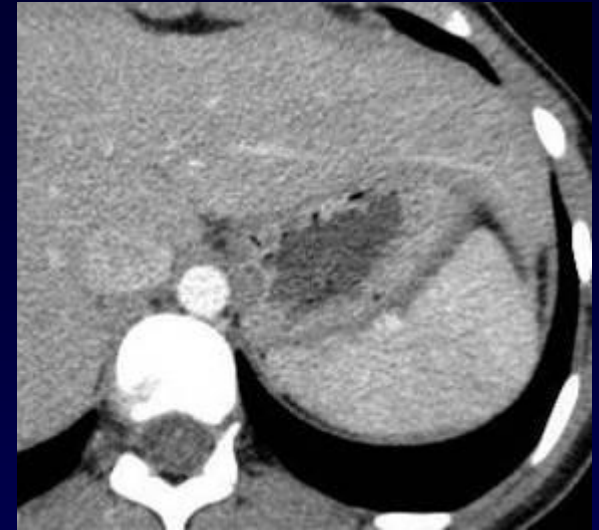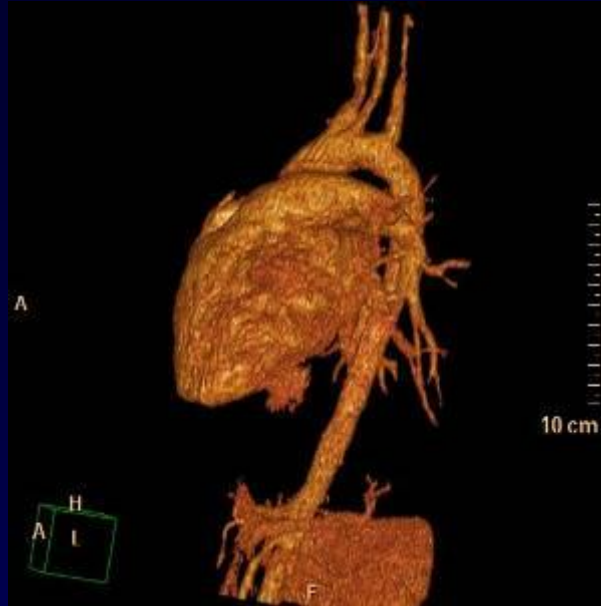[Click Here to upgrade to  
Unlimited Pages and Expanded Features](#)



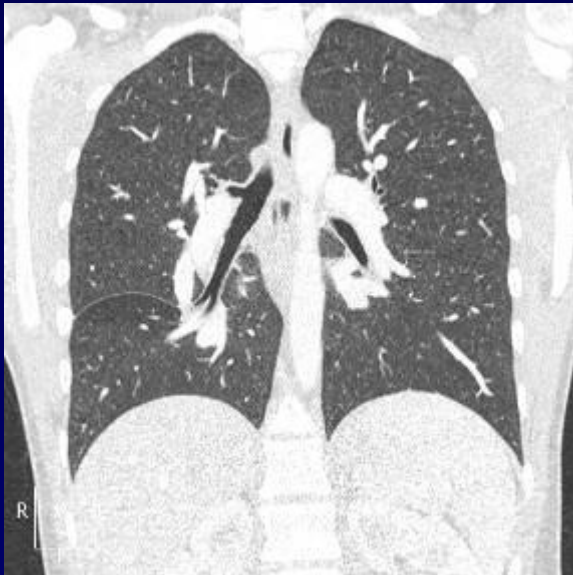# Diagnostic ?



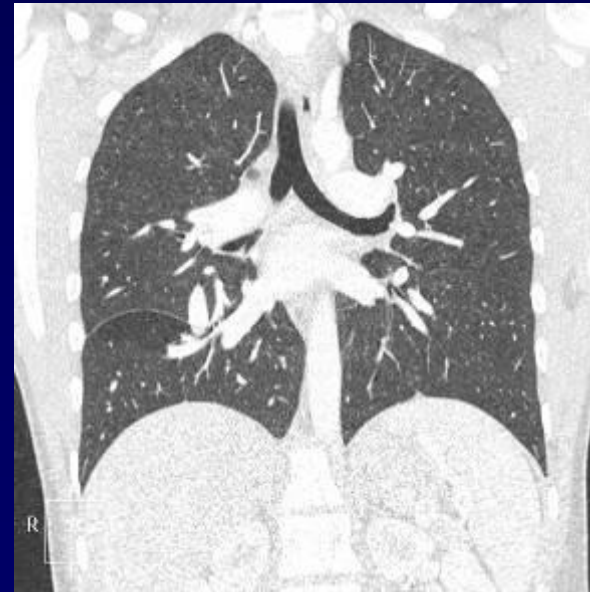**VCS double**



**Rate normale**



**APD normale**



**APG normale**



*Your complimentary  
use period has ended.  
Thank you for using  
PDF Complete.*

[Click Here to upgrade to  
Unlimited Pages and Expanded Features](#)



# Diagnostic ?



# Diagnostic

## Malformation complexe

Syndrome de HALASZ

Syndrome de CIMETERRE

Retour veineux pulmonaire anormal total droit (RVPA)

Pas de lévo- isomérisme

Dextrocardie avec communication inter-auriculaire (CIA)

Double veine cave supérieure

# Discussion

## Problème thérapeutique

**Traiter la CIA seule ?**

**Traiter la CIA et le RVPA : lourd !**