

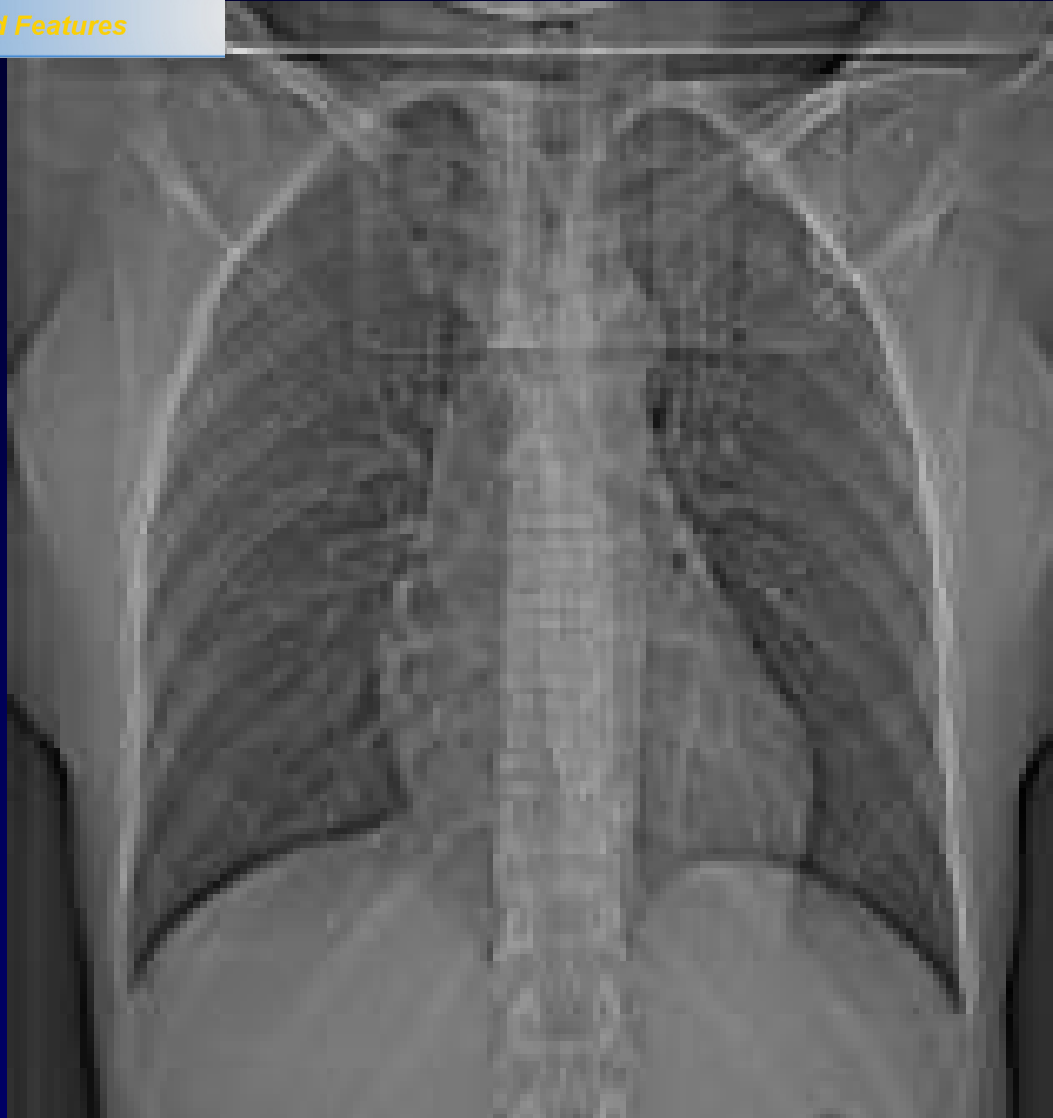

J GIRON- P FAJADET

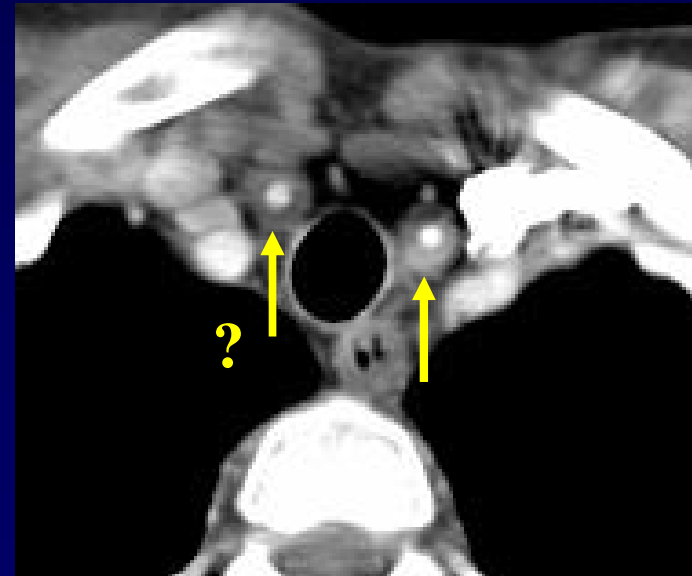
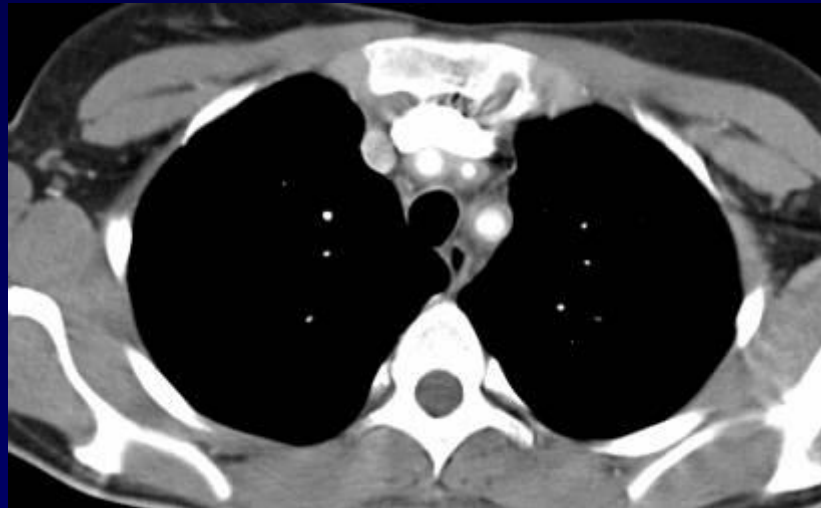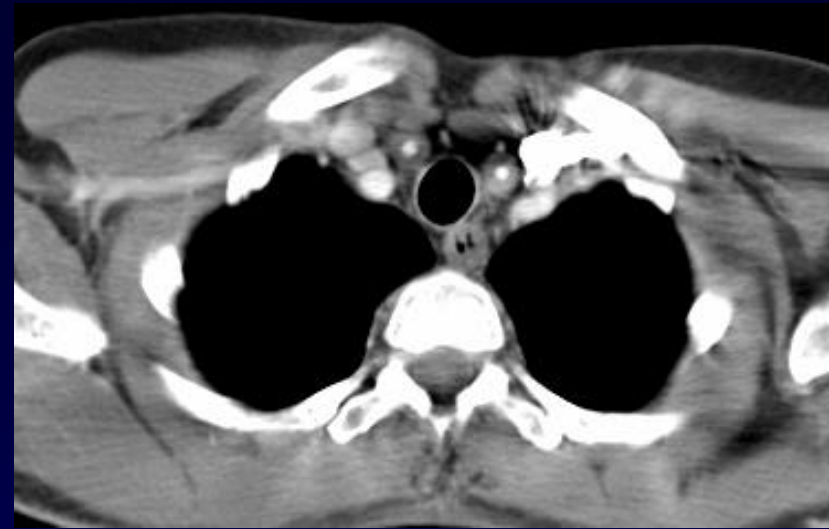
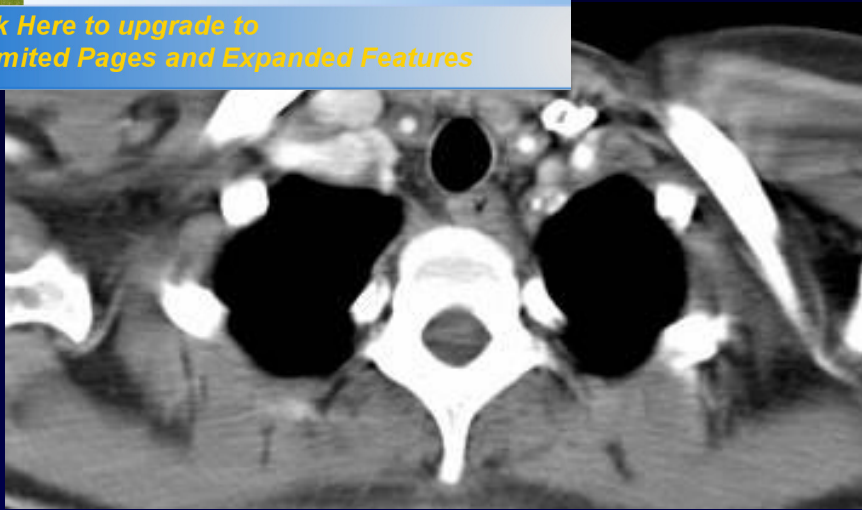
Jeune femme de 19 ans

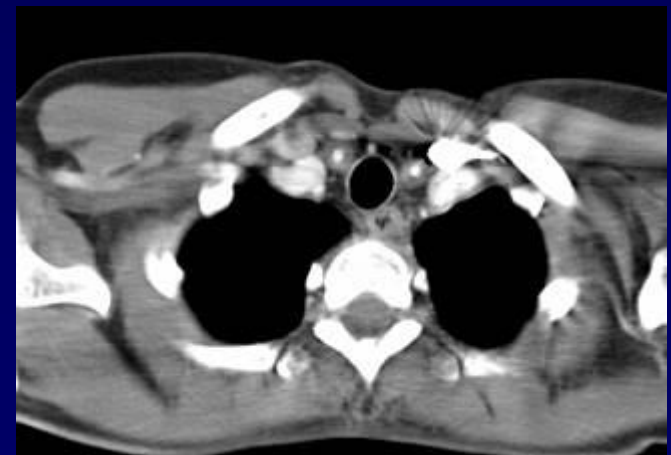
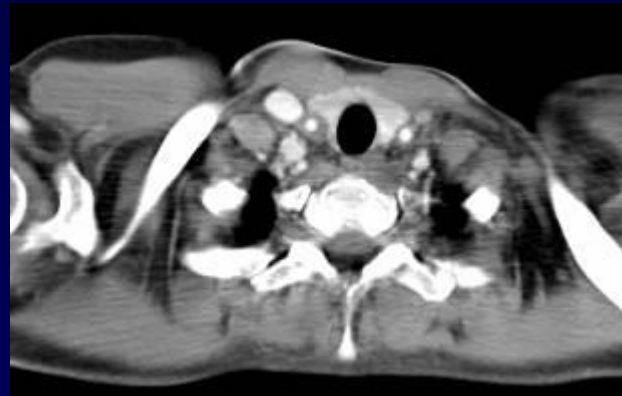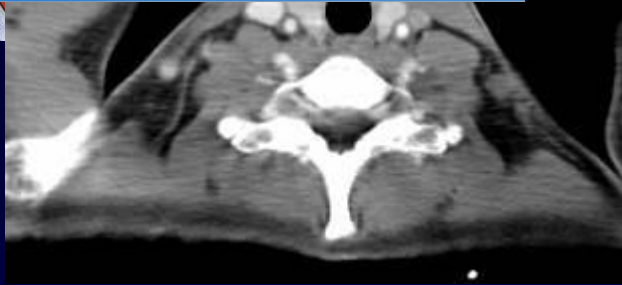
Fatigue, dyspnée

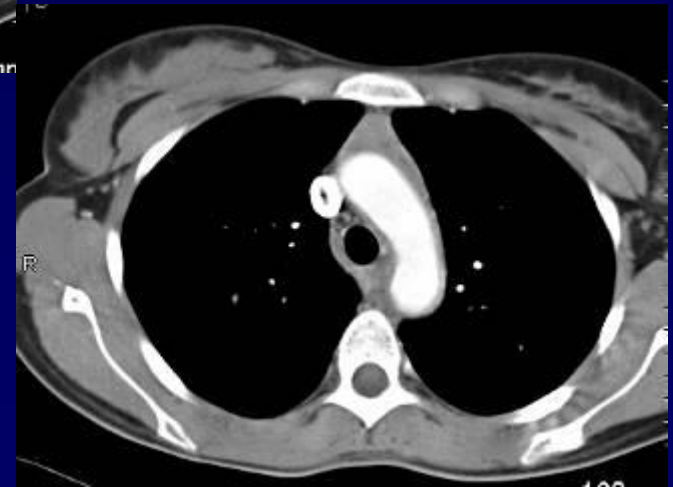
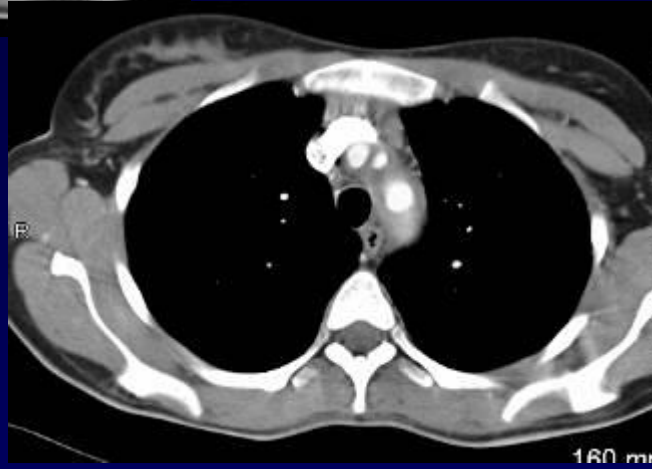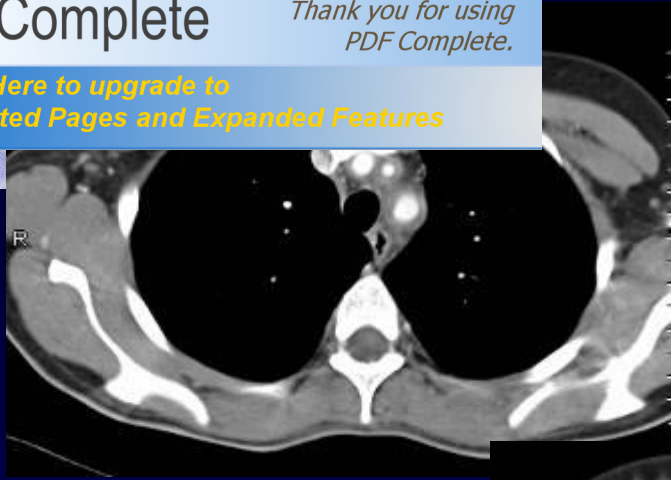
Syndrome inflammatoire +++



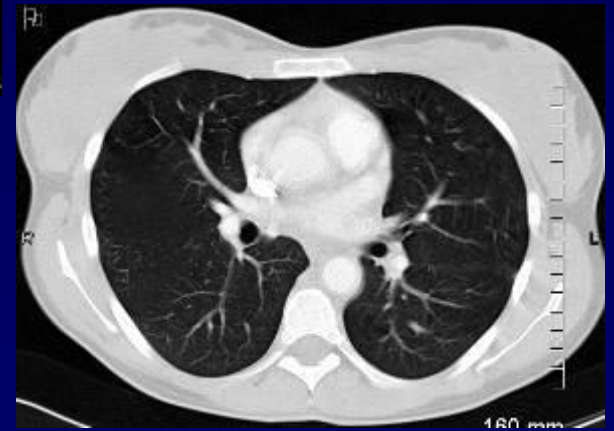
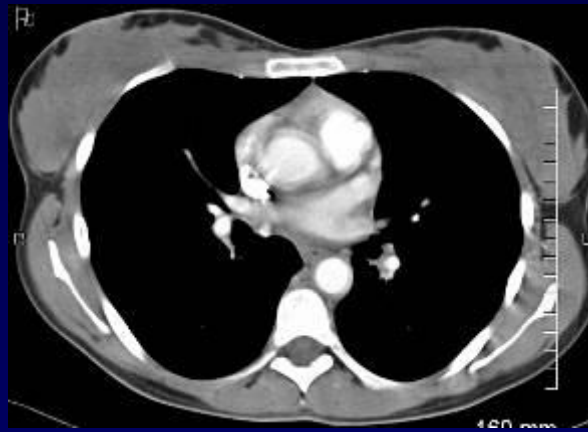
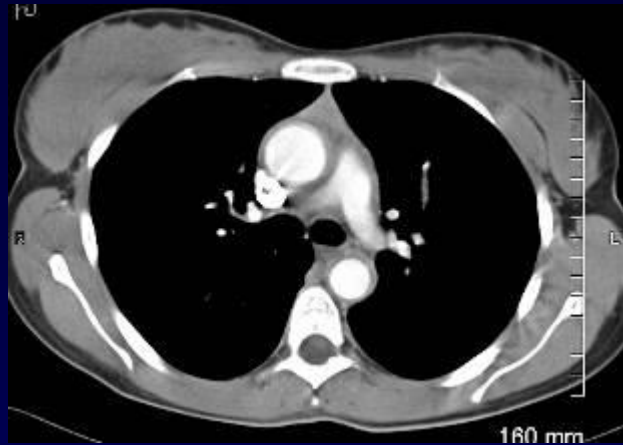
Radiographie thoracique normale

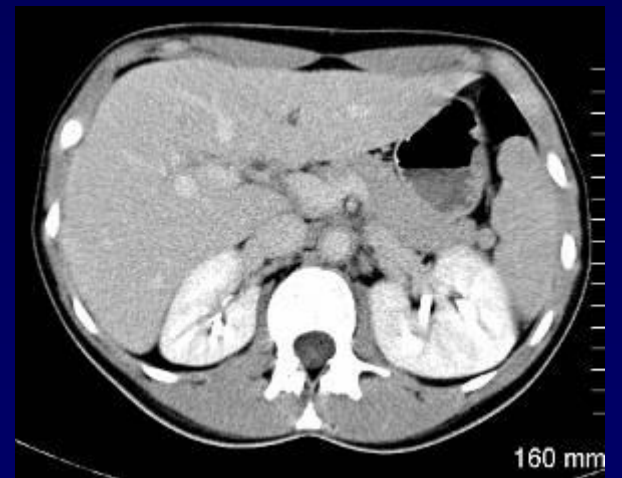
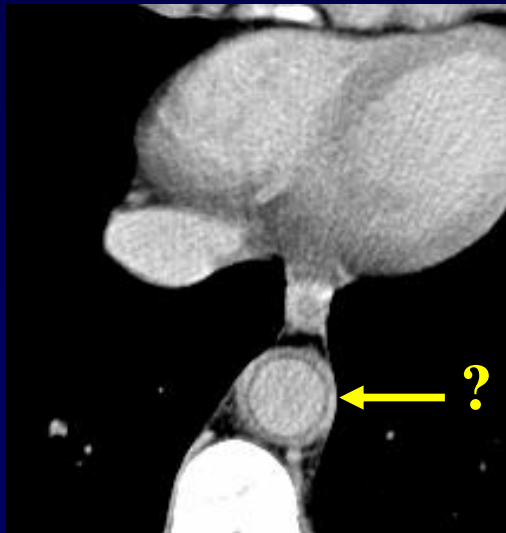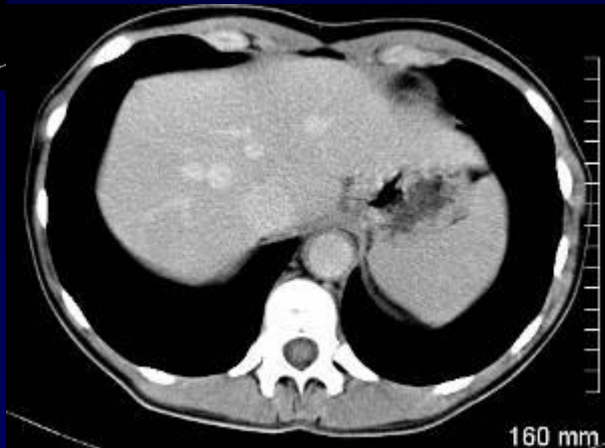
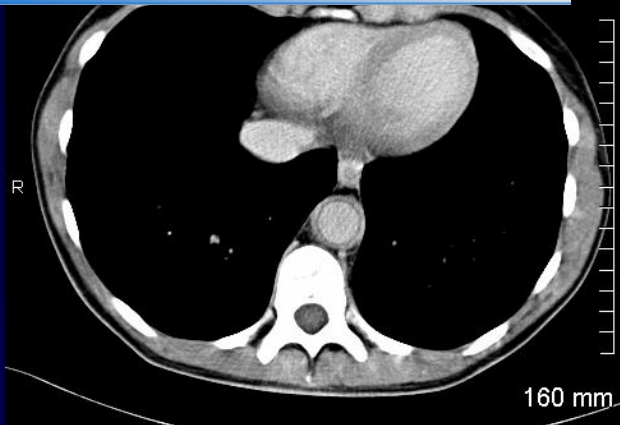


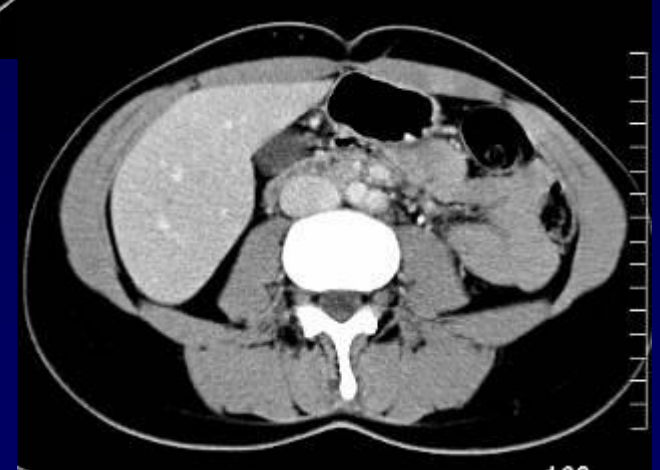
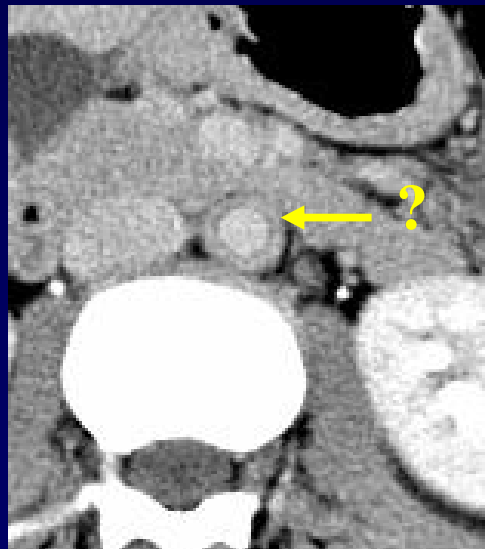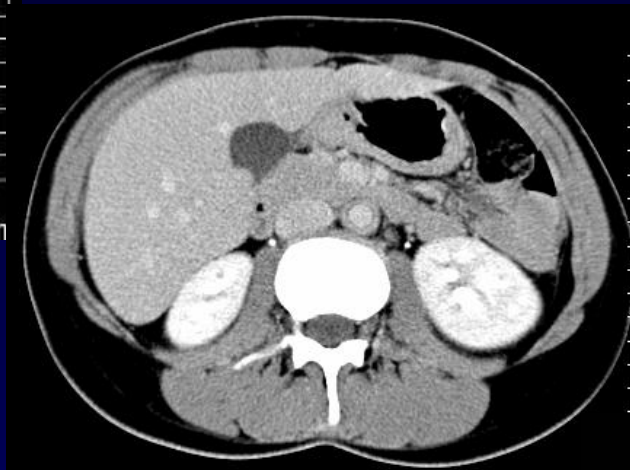
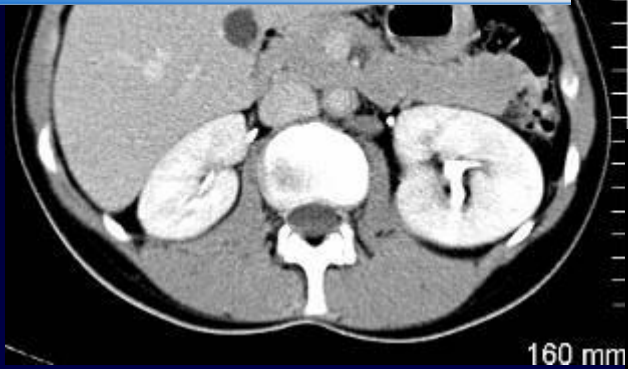




CLUB THORAX









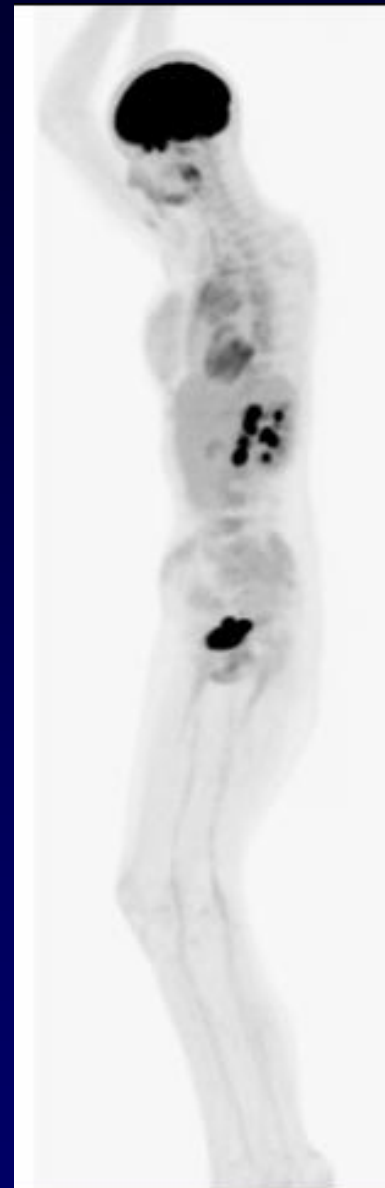
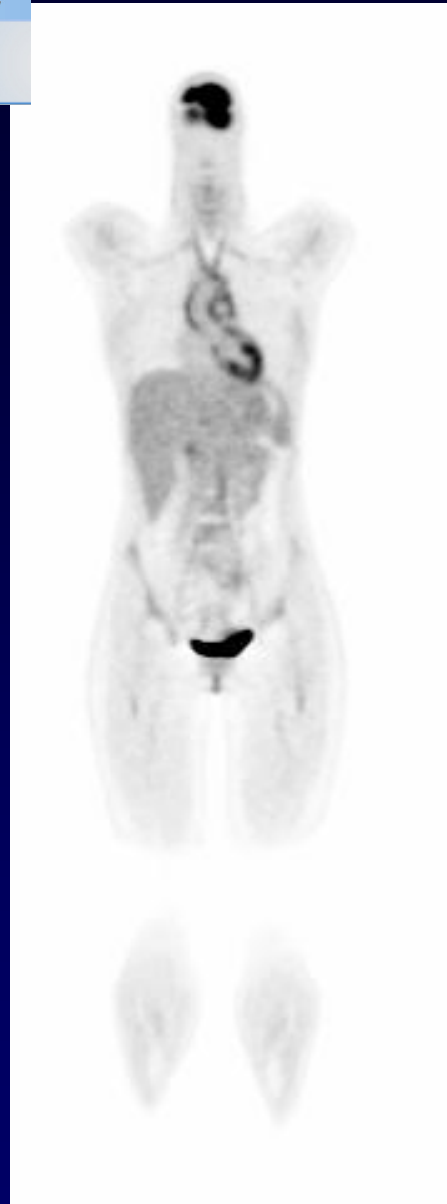*Your complimentary
use period has ended.
Thank you for using
PDF Complete.*

[Click Here to upgrade to
Unlimited Pages and Expanded Features](#)

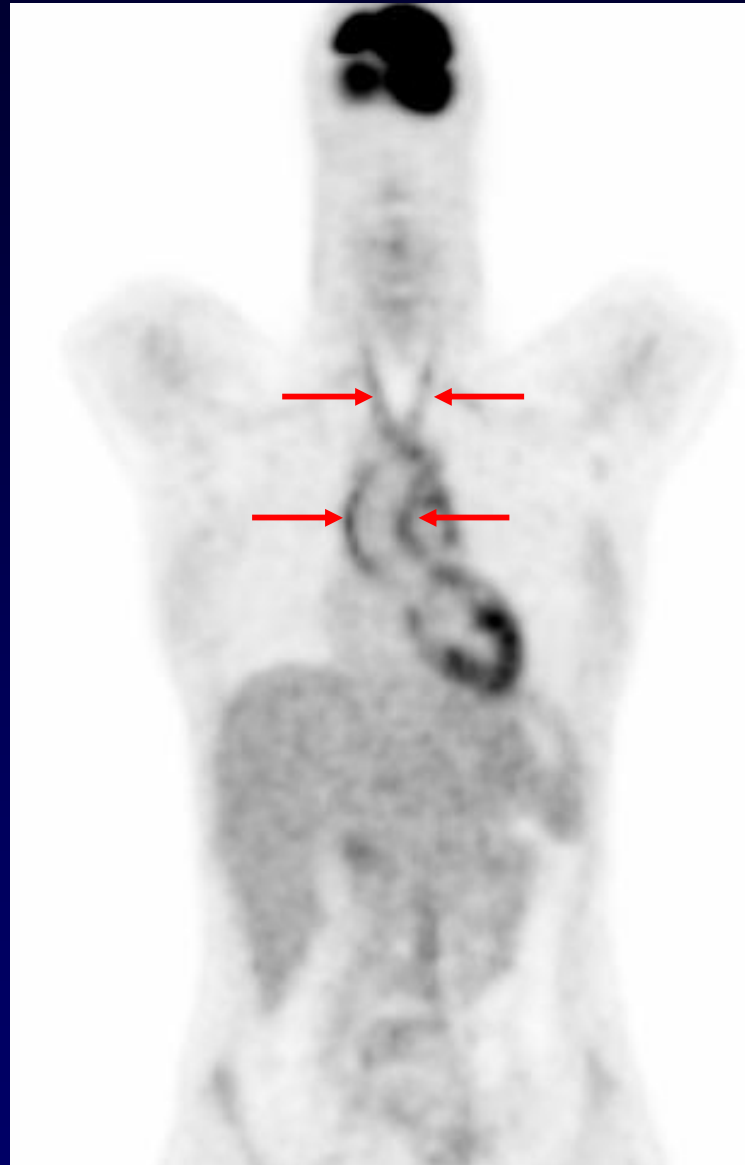

Diagnostic ?

TEP-TDM au FDG



cine vasculaire





*Your complimentary
use period has ended.
Thank you for using
PDF Complete.*

[Click Here to upgrade to
Unlimited Pages and Expanded Features](#)



Diagnostic ?



Diagnostic

Péri-aortite diffuse

Maladie de TAKAYASU

Codage : Cardiovasculaire - Inflammatoire



Discussion

Maladie de TAKAYASU

Absence d'HTAP en échocardiographie

La dyspnée s'explique par l'anémie

Absence d'atteinte coronarienne

Suivi à faire par IRM aortique, car patiente je une