



Dossier 3

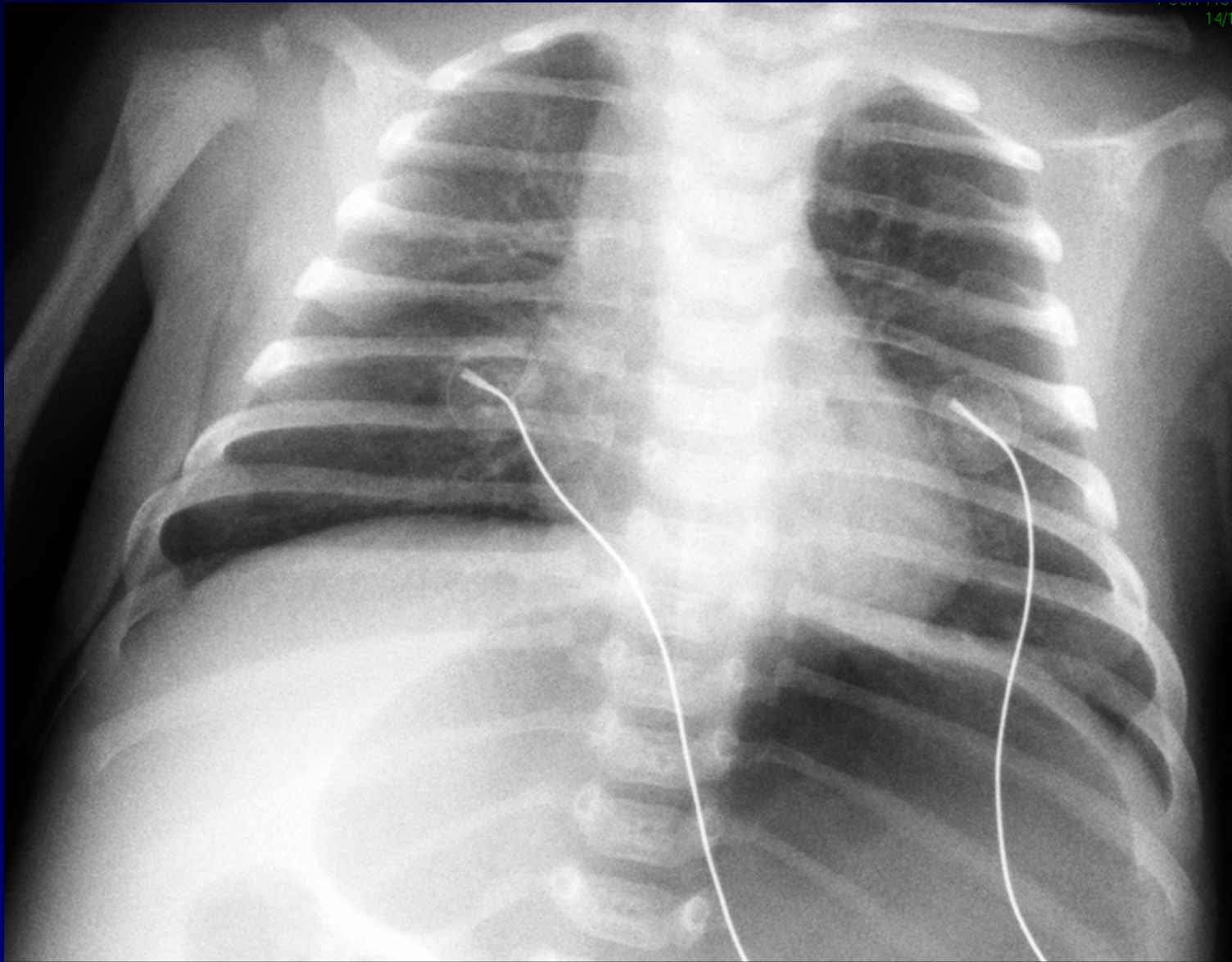
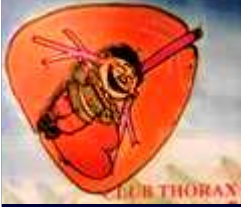**M EL HAJJAM
P LACOMBE**

Nourrisson de 2 mois

Gêne respiratoire

Vomissements

**Détresse respiratoire après fibroscopie
oesophagienne**

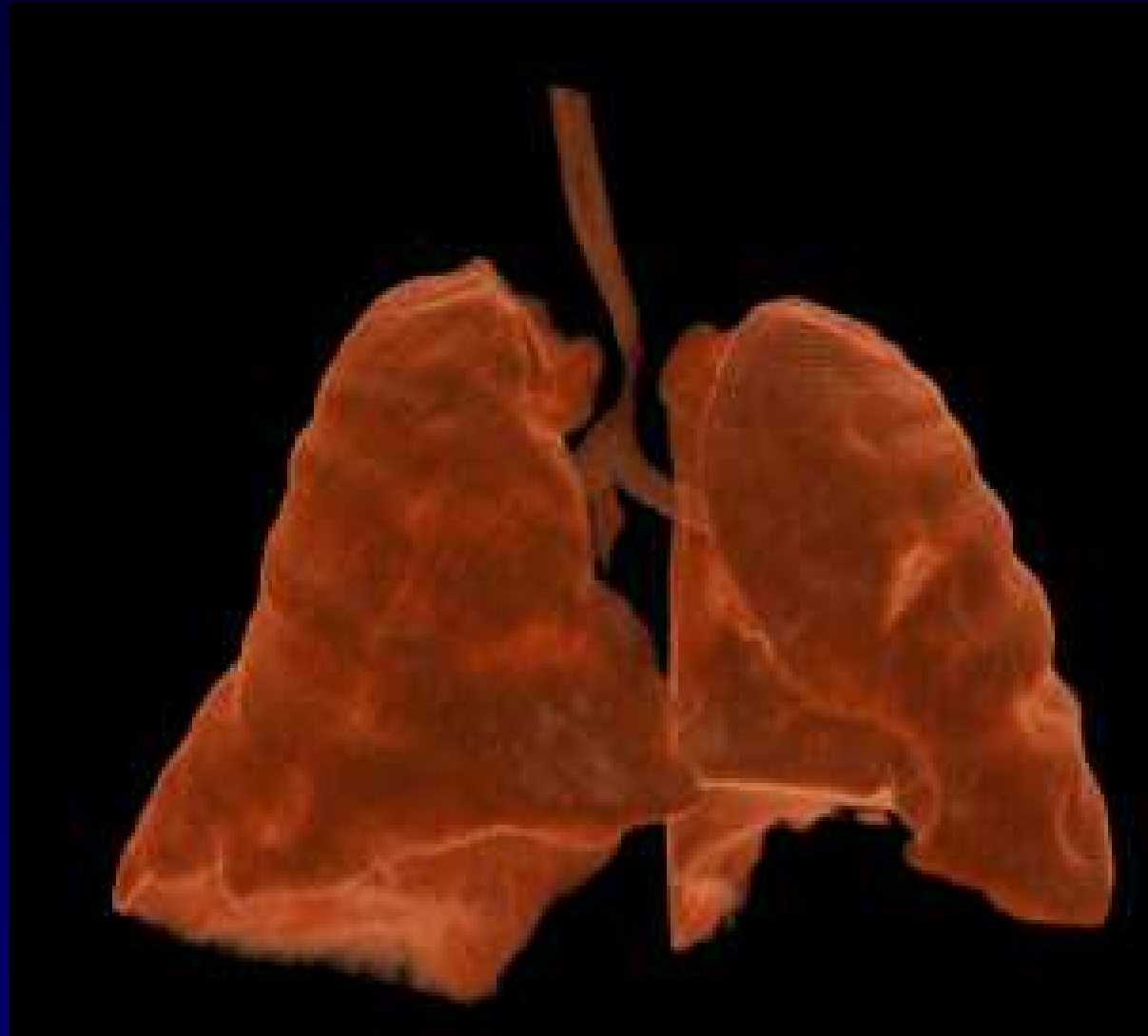


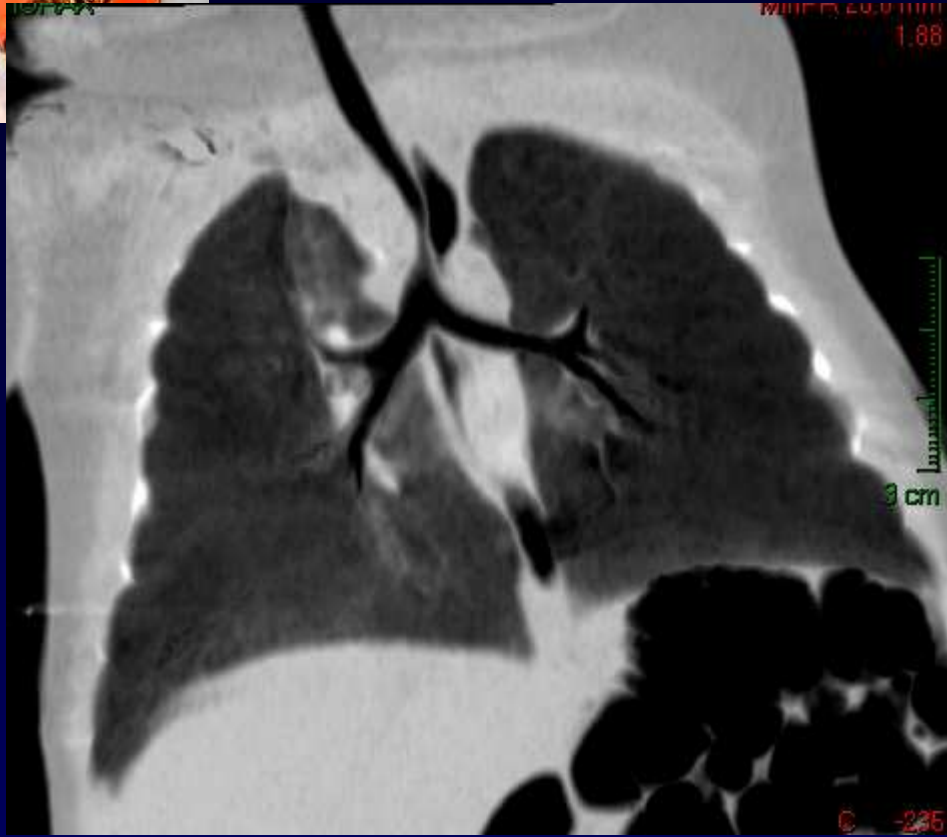
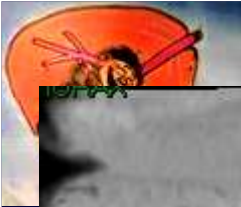

Diagnostic ?

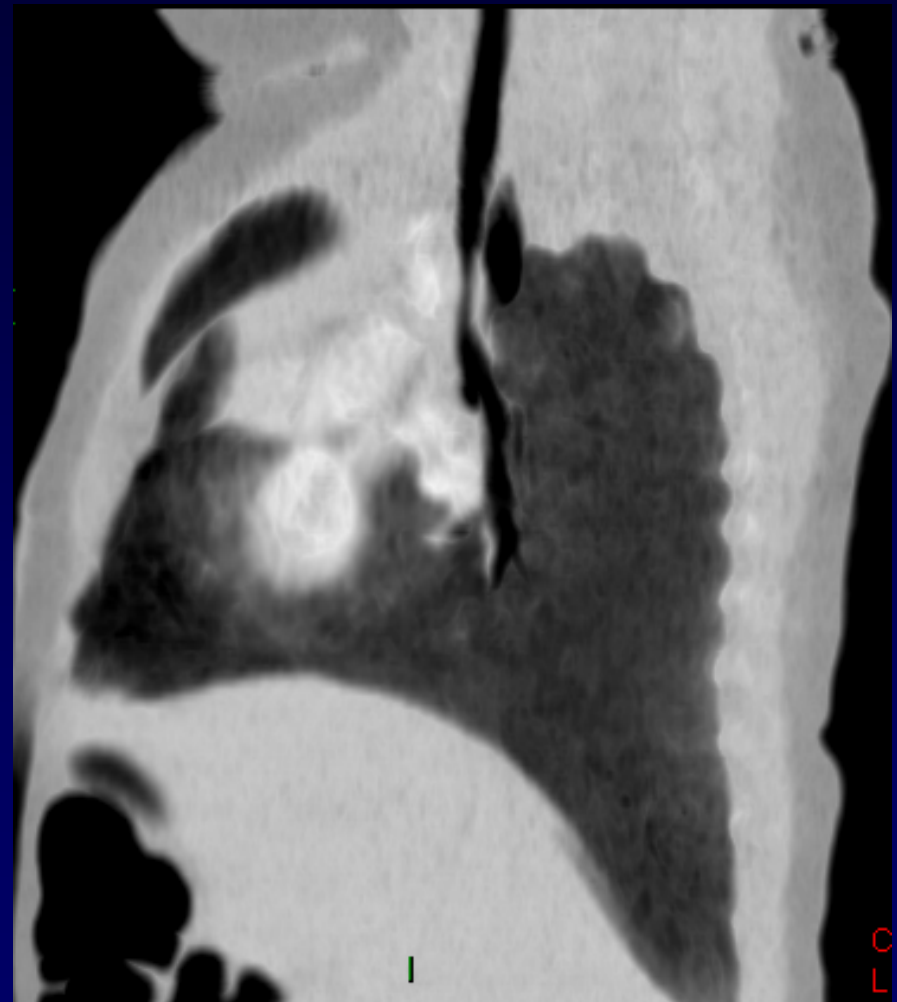


TDM - VRT





TDM – mini-MIP

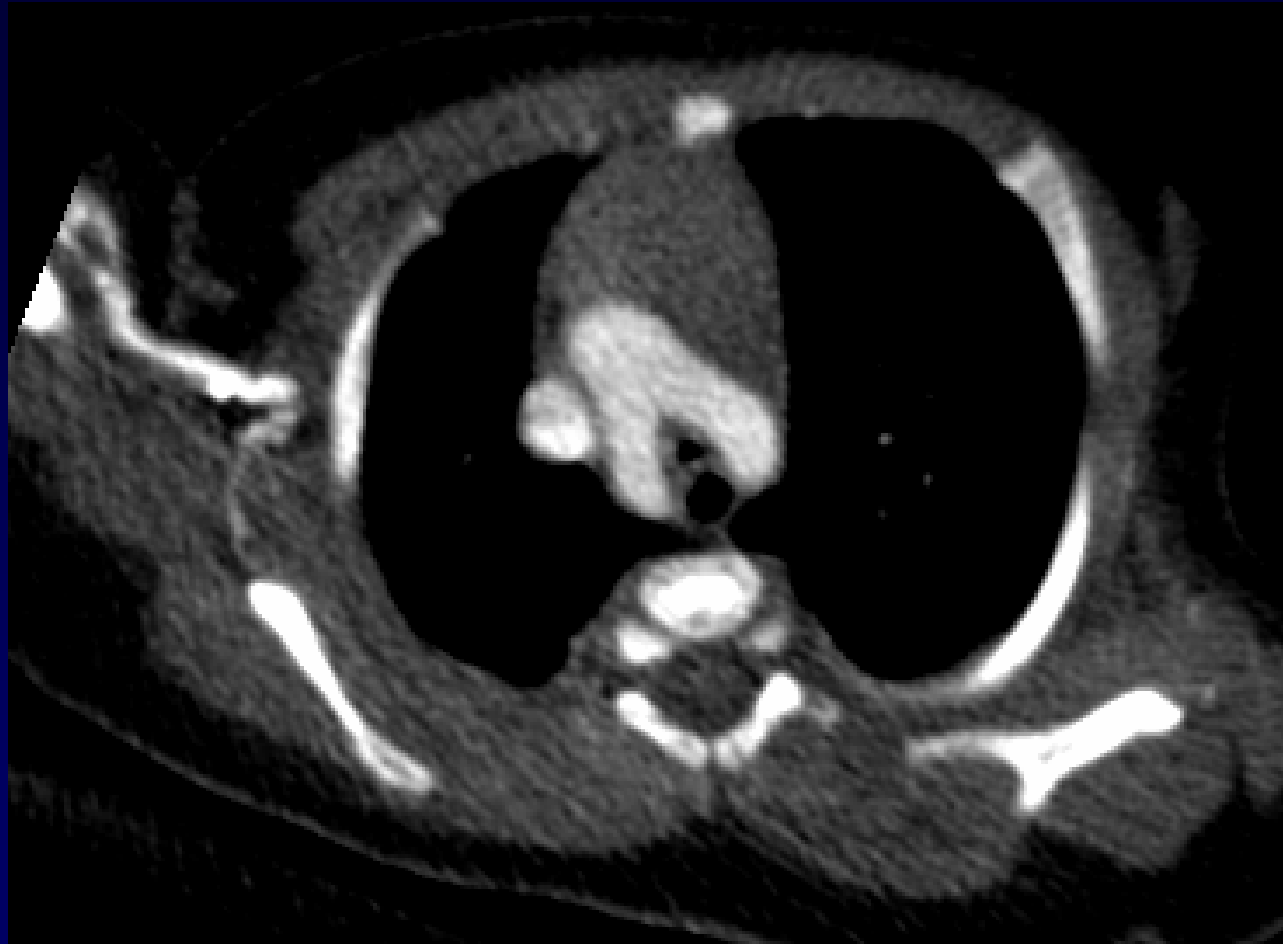

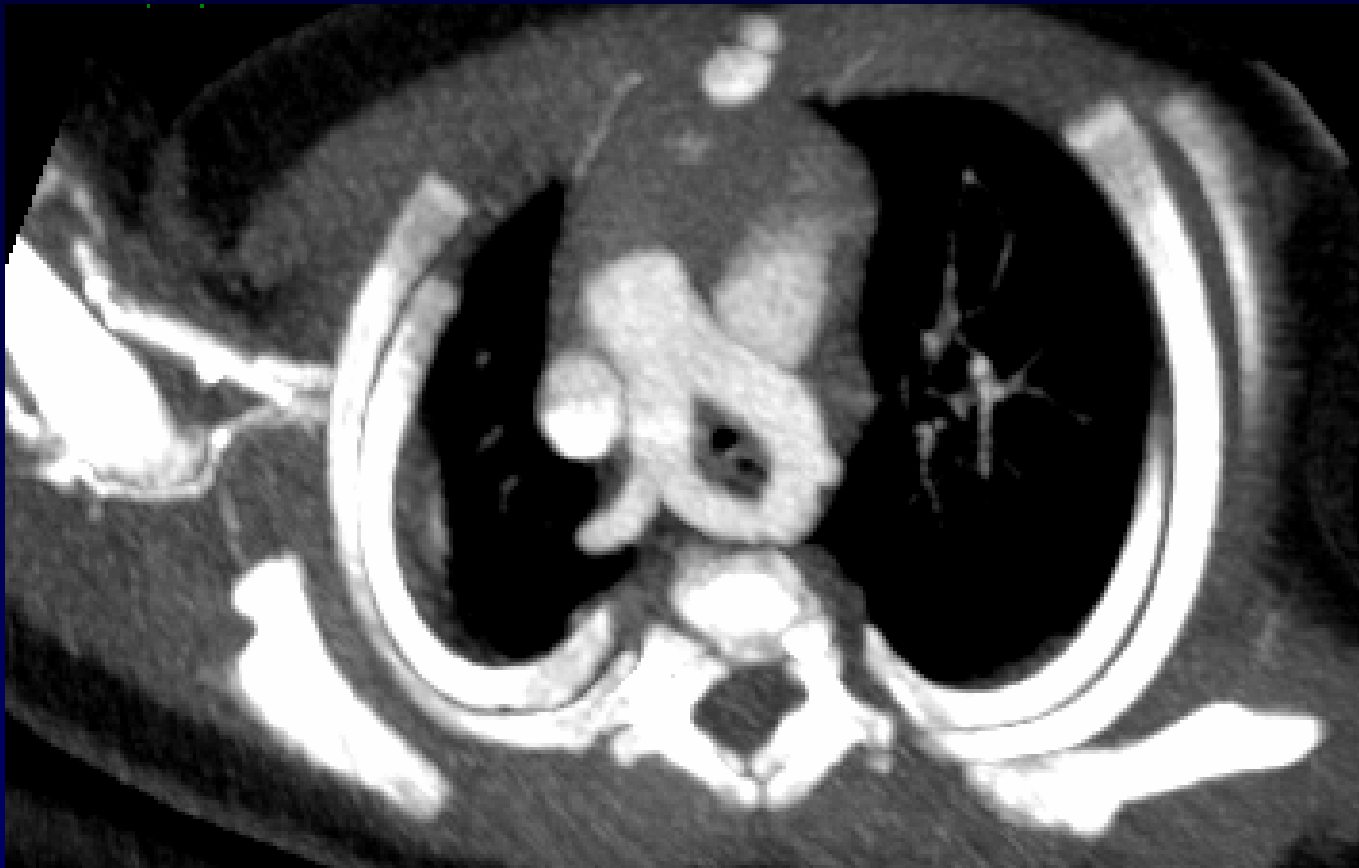

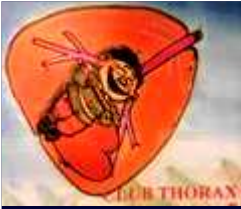
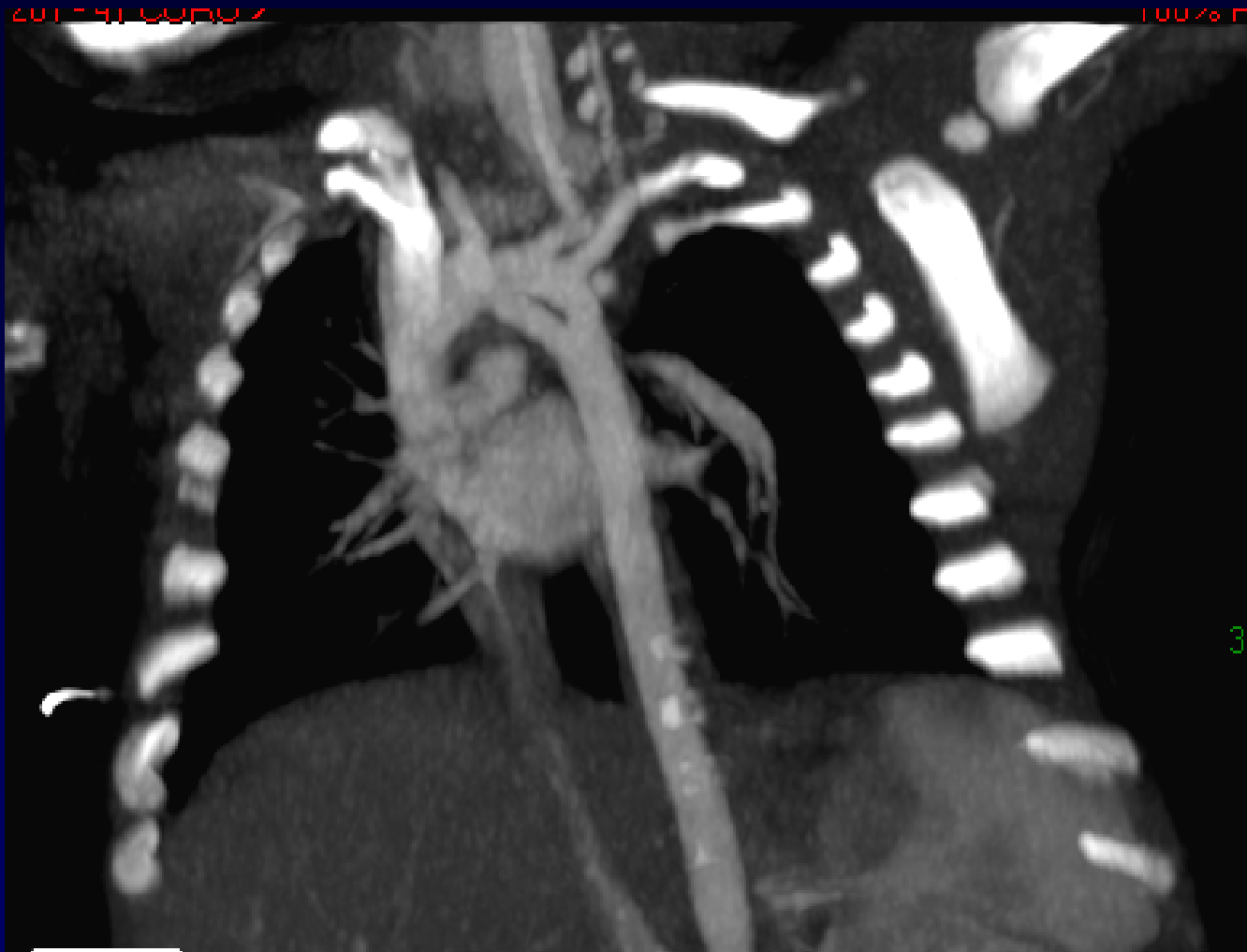Diagnostic ?

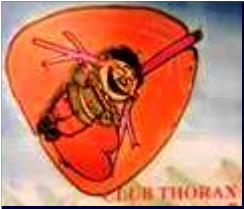

TDM THORACIQUE



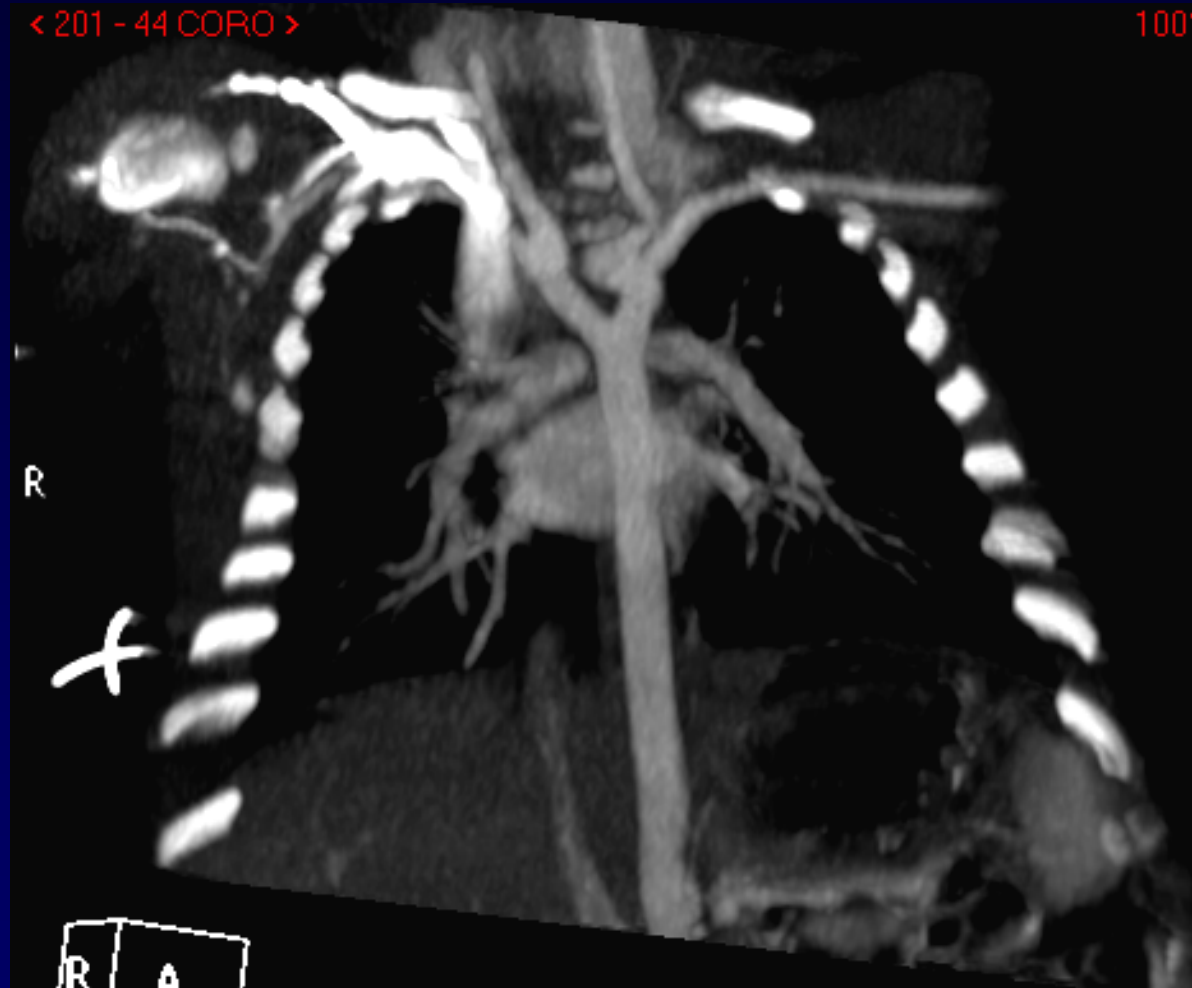


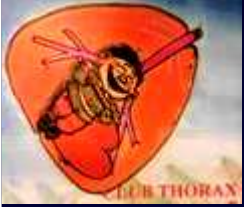


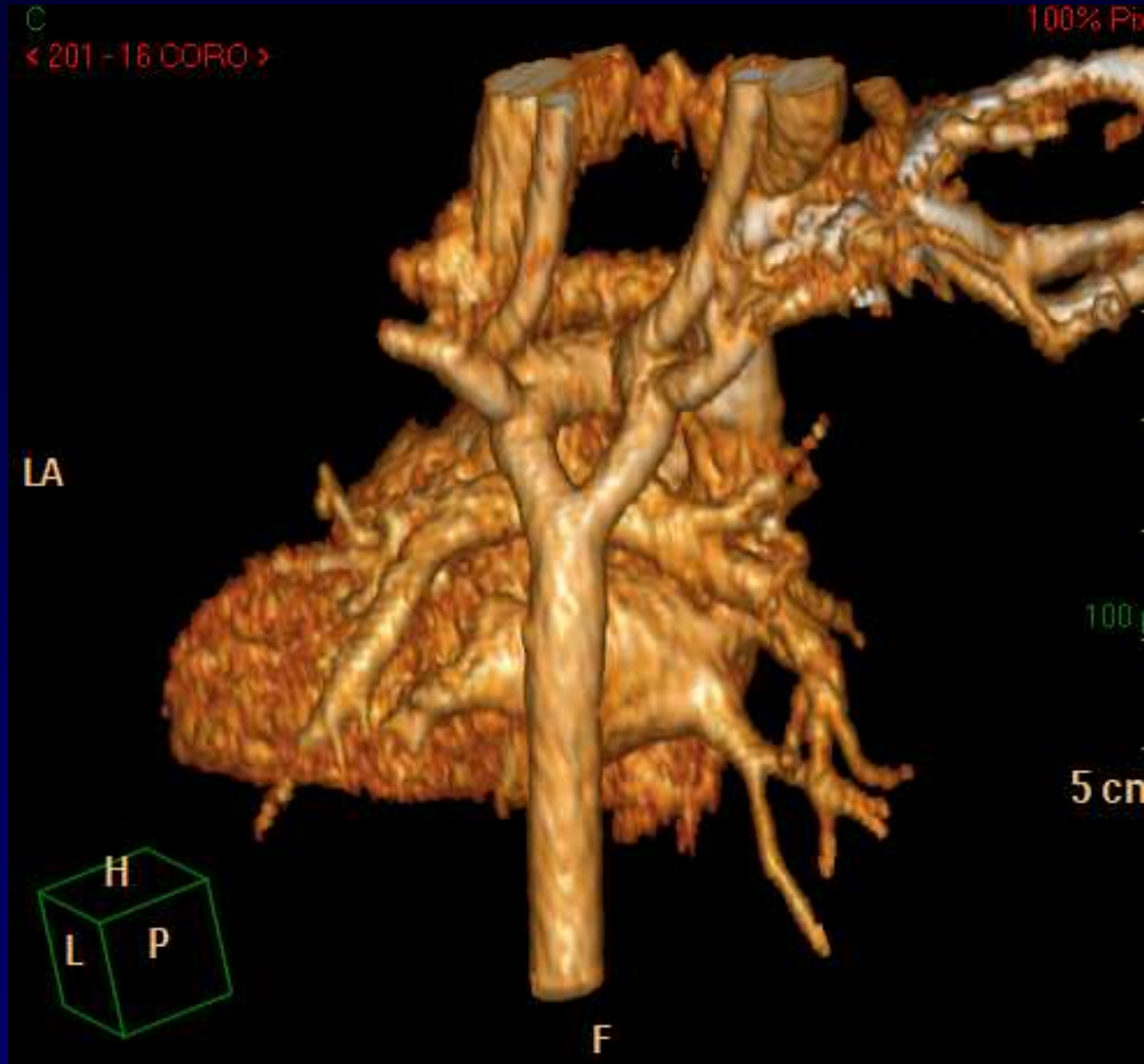
< 201 - 44 CORO >

100%





TDM - VRT





Diagnostic

Double arc aortique

Codage : Cardiovasculaire – Anatomie - Congénital



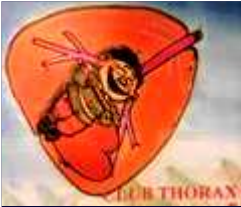Traitement - Evolution

Double arc aortique

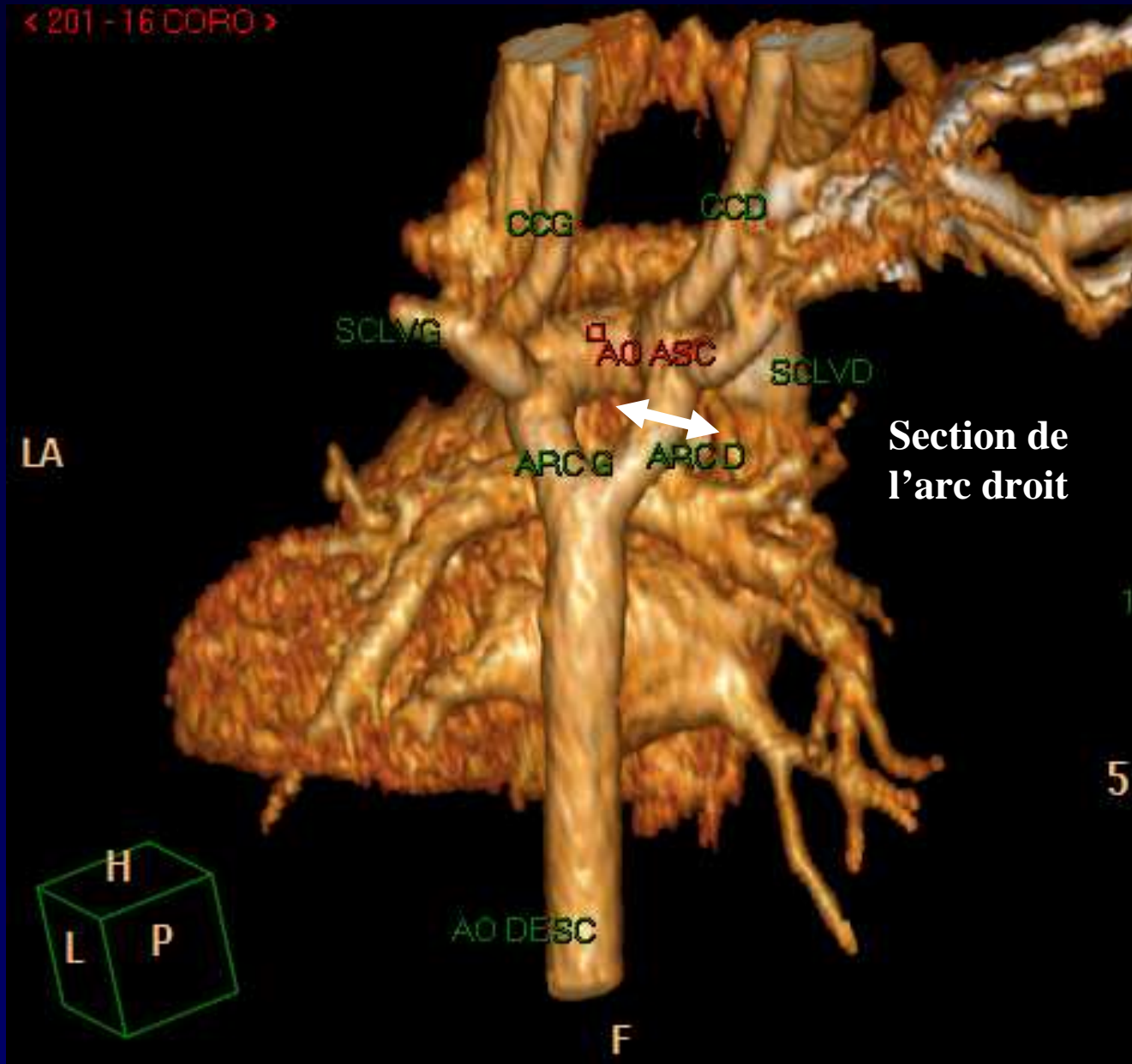
Traitement chirurgical :

**Section de l'arc aortique droit en aval de
l'artère sous clavière droite**

Evolution favorable

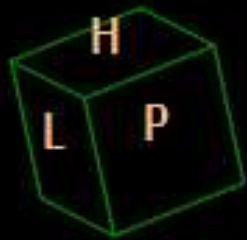

< 201 - 16 COFO >



Section de
l'arc droit

LA



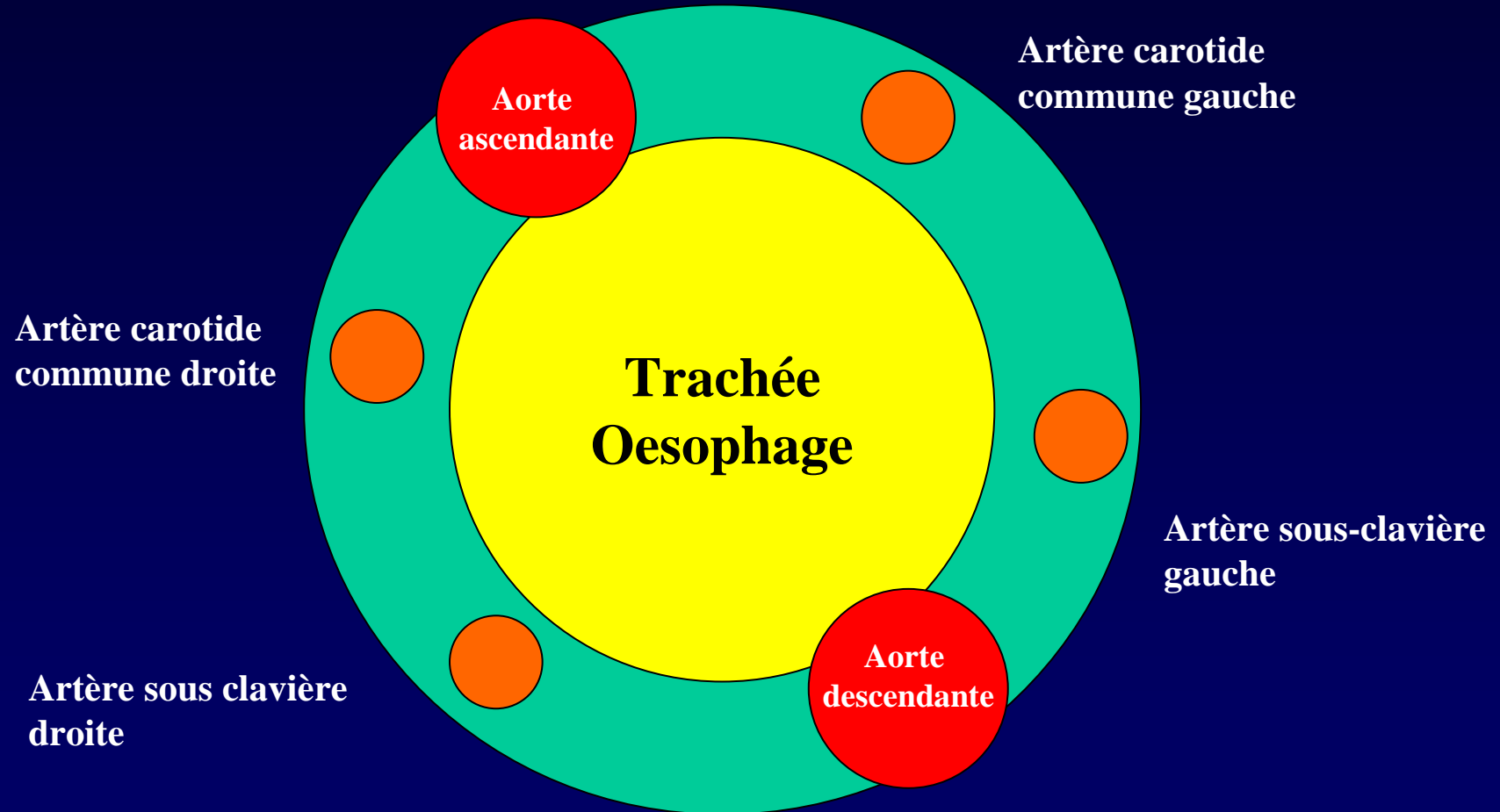
F

10

50



Discussion : Schéma du double arc aortique embryonnaire





Références

1 - Edwards JE.

Anomalies of the derivatives of the aortic arch system
Med Clin North Am 1948 ; 32 : 925

2 - El Hajjam M. et al

Imagerie de l'aorte thoracique
Imagerie Thoracique de l'Adulte. Ed. Masson 2003