



Dossier 14

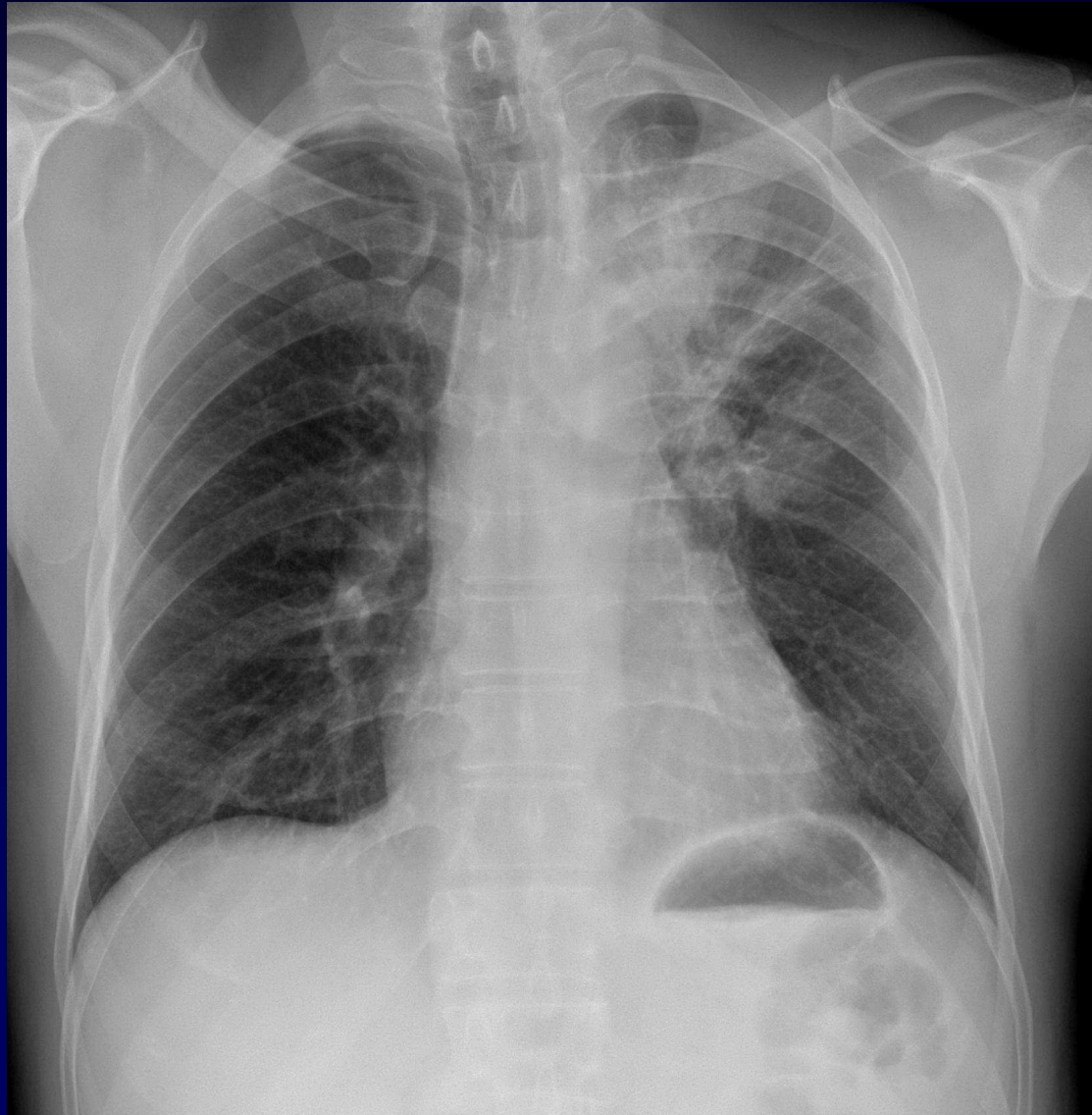J GIRON

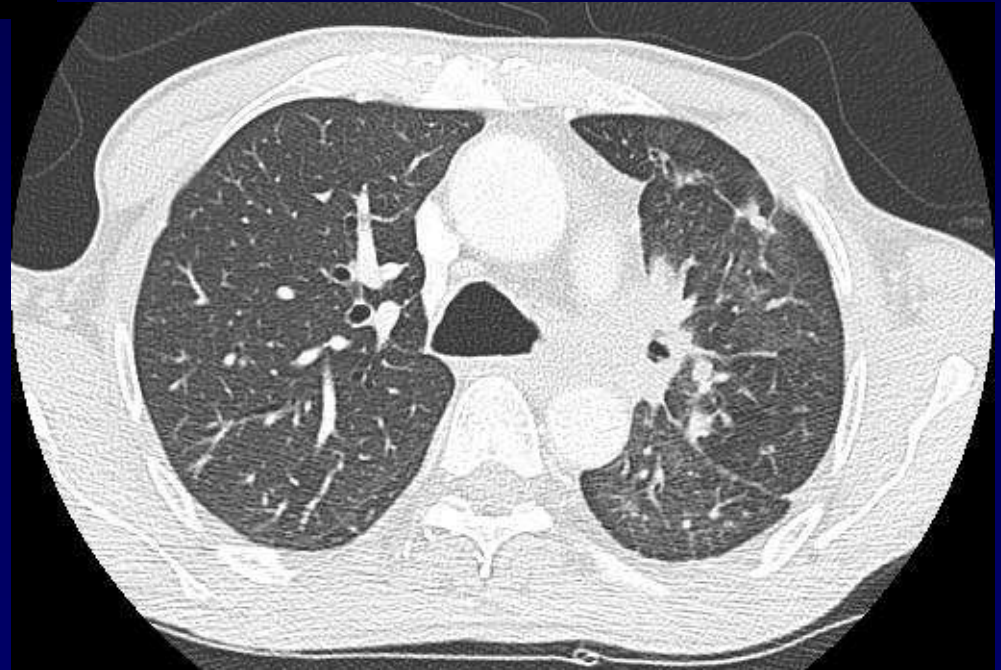
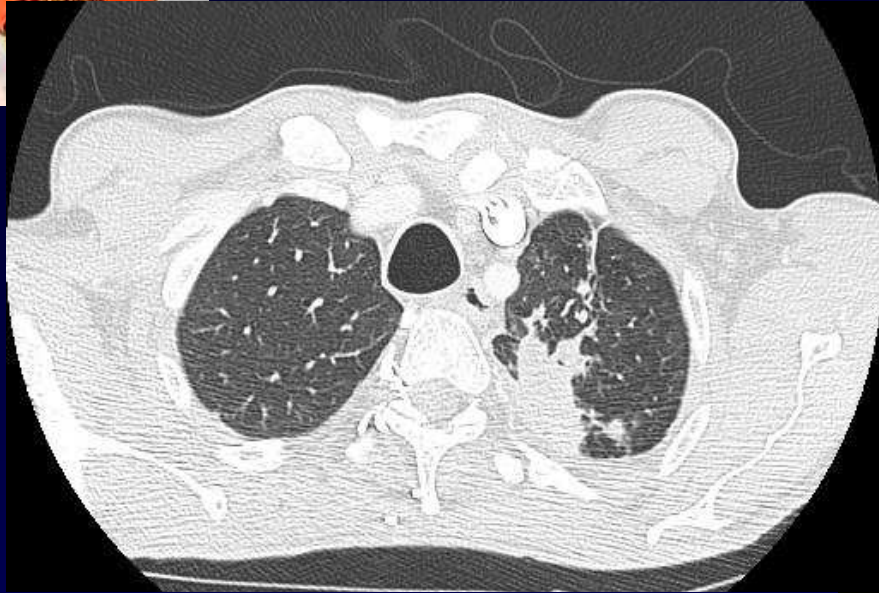
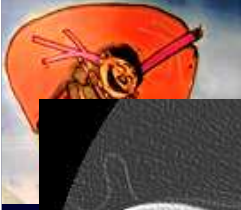
P FAJADET

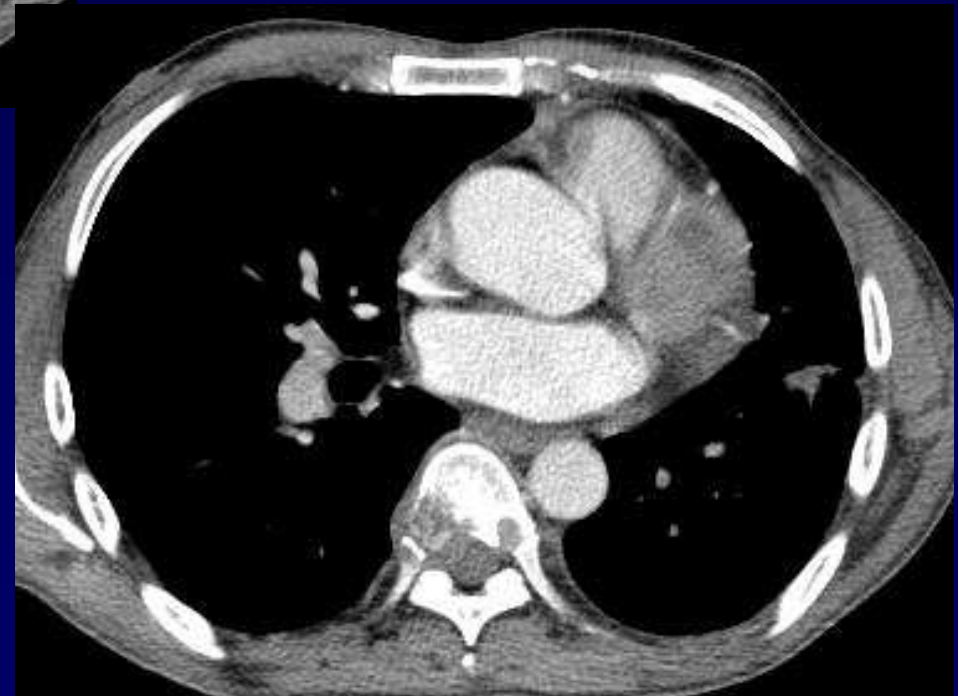
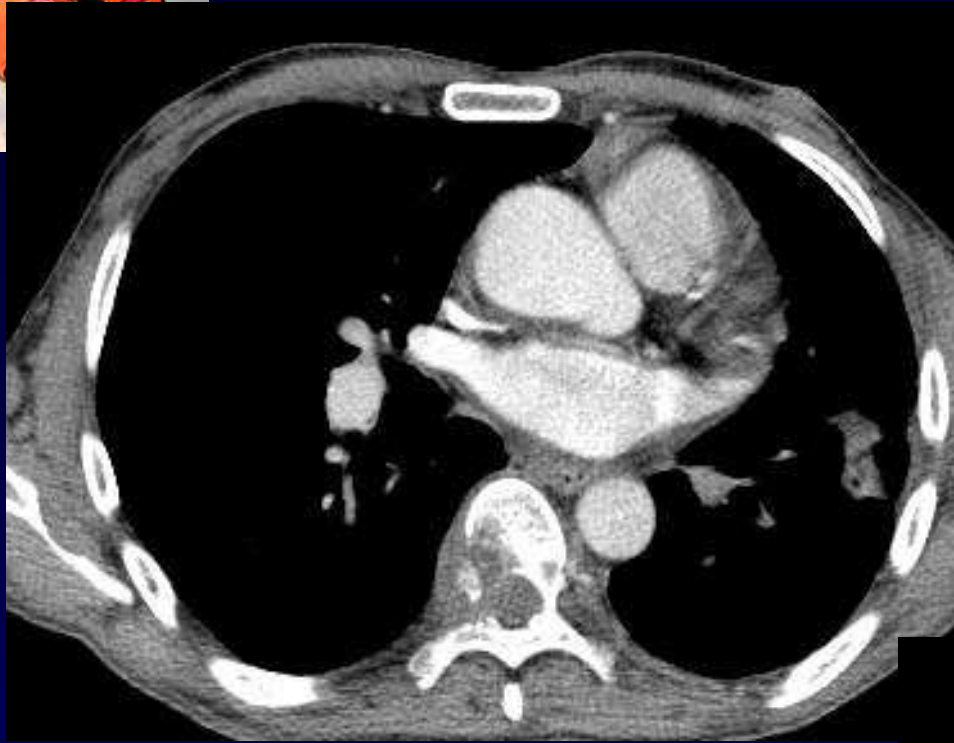
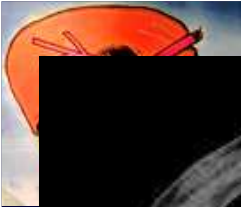Homme de 40 ans

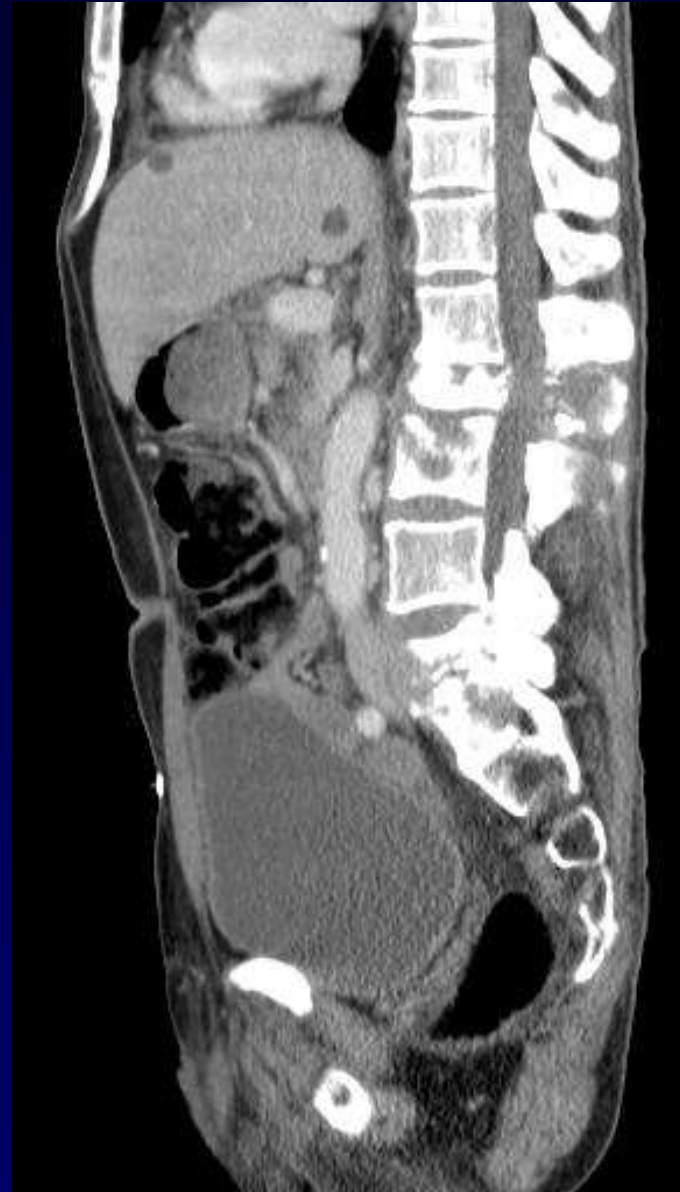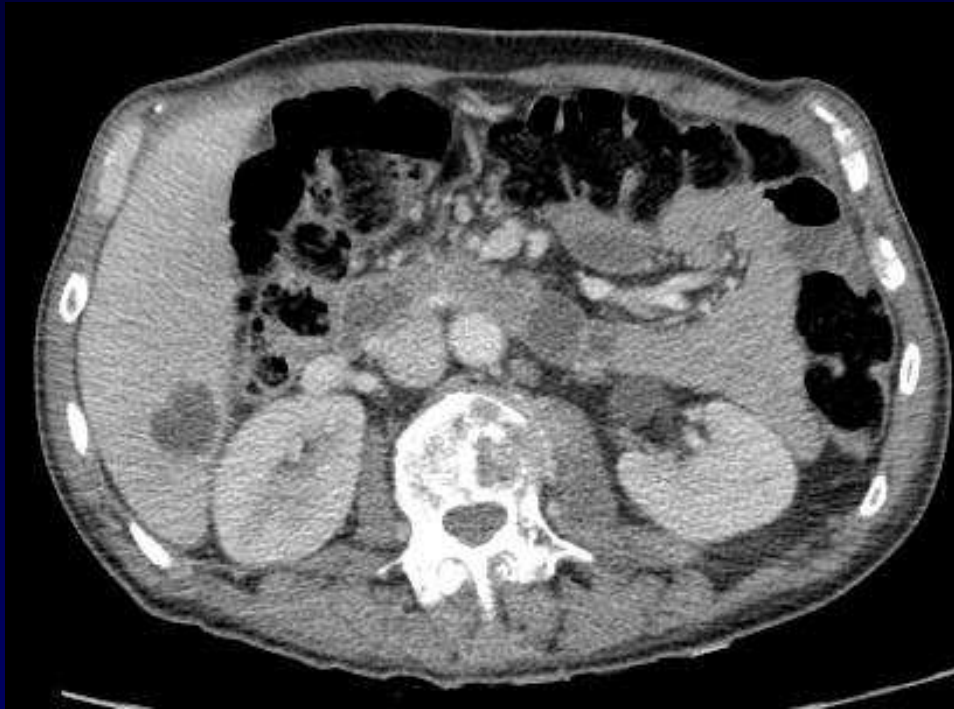Clinique : Carcinome épidermoïde de la verge

Métastases ?





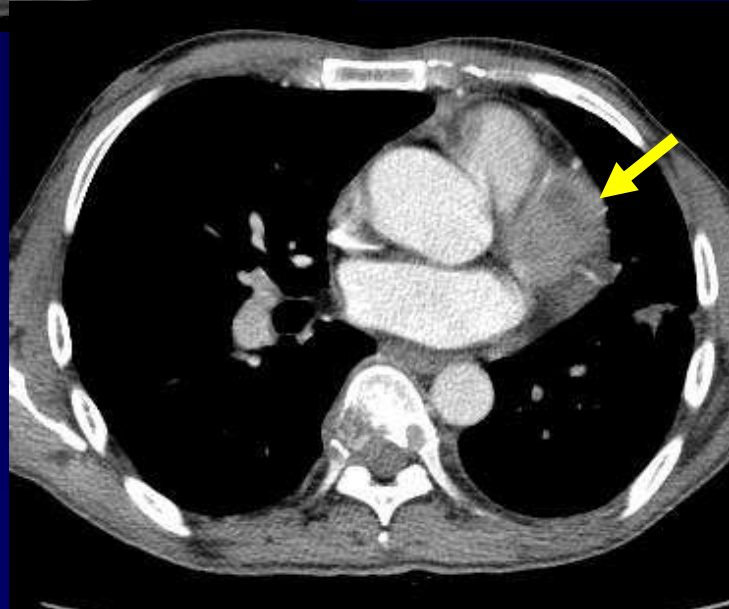
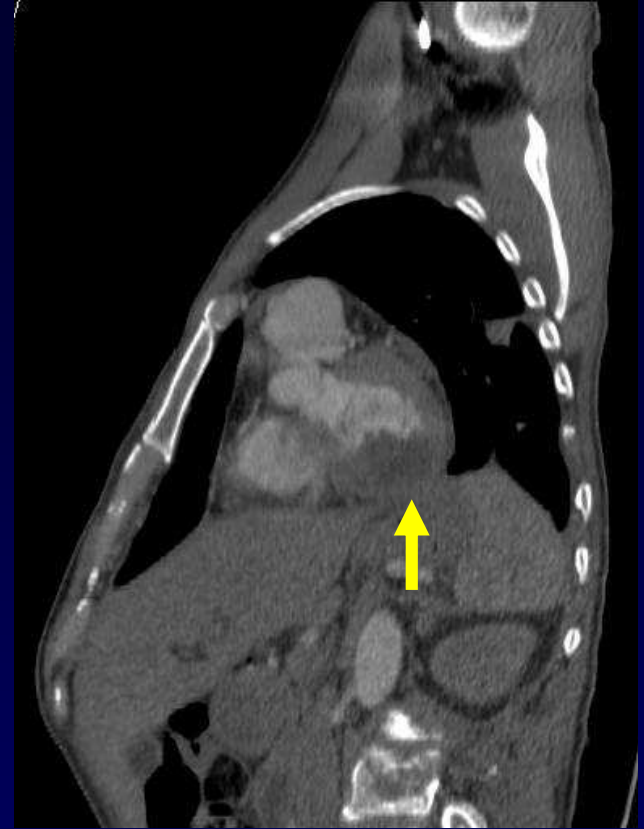
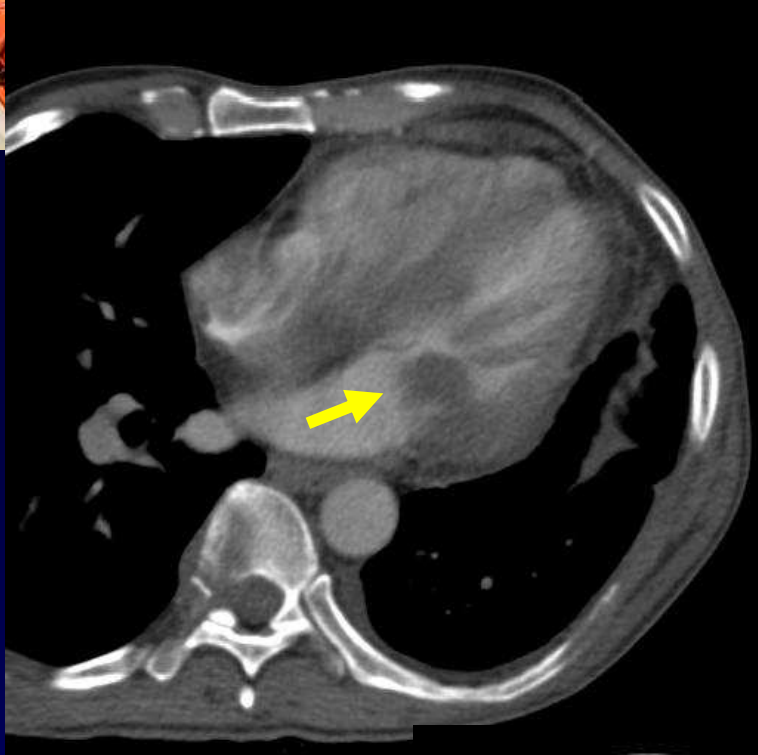
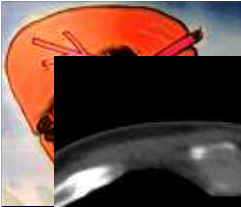






Diagnostic

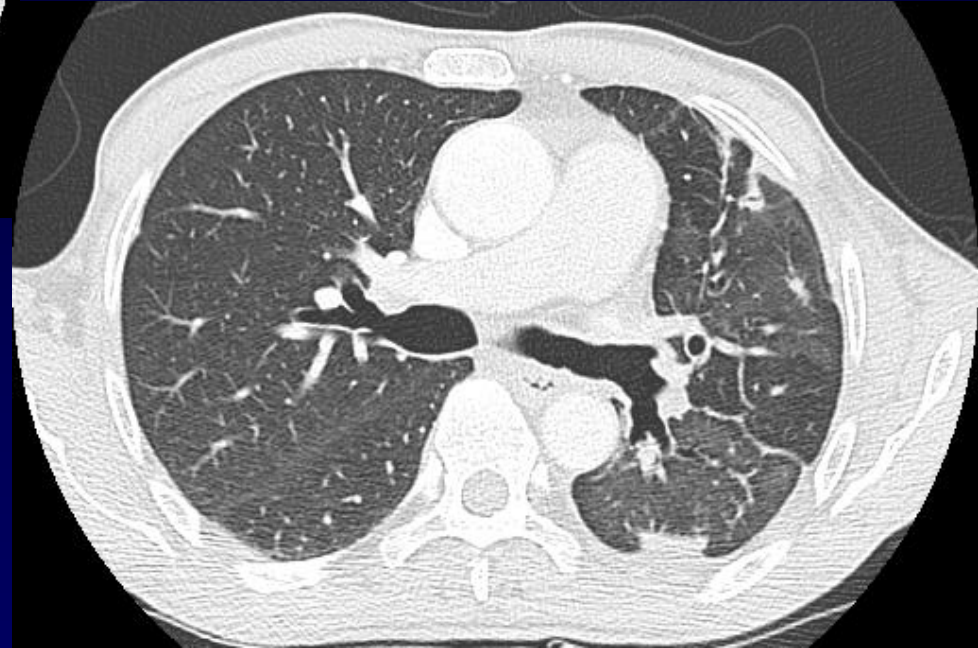
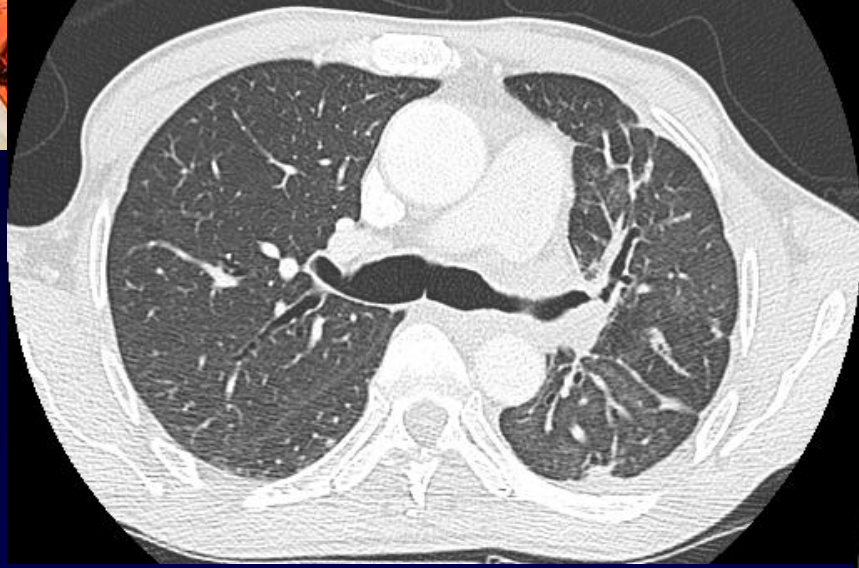**METASTASE OSSEUSES
HEPATIQUES ET...**





Diagnostic

**VRAISEMBLABLES METASTASES
MUSCULAIRES CARDIAQUES
GAUCHES**



A noter : Hypogénésie de l'APG
Artères trans-pleurales