



Dossier 15

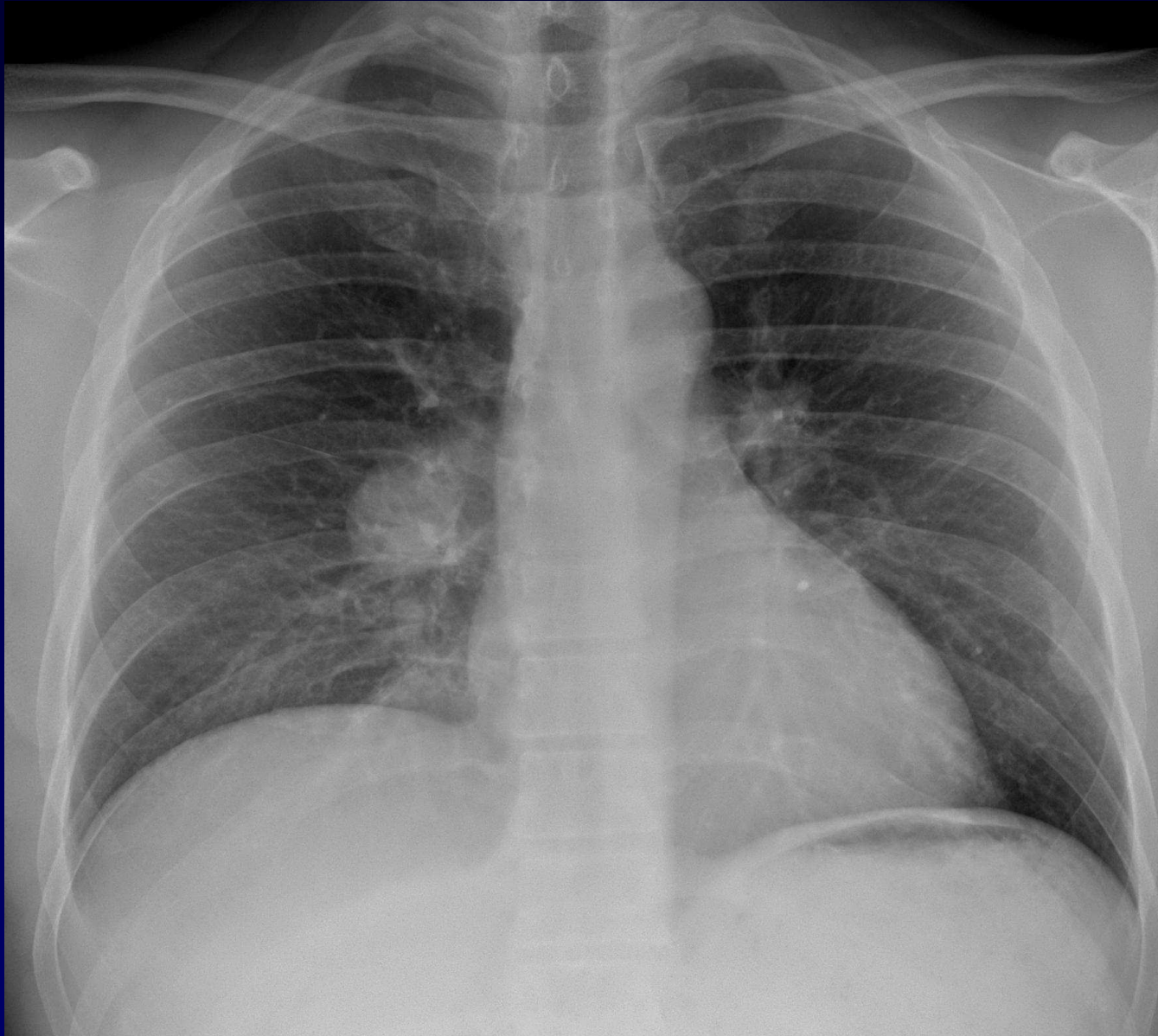
J GIRON

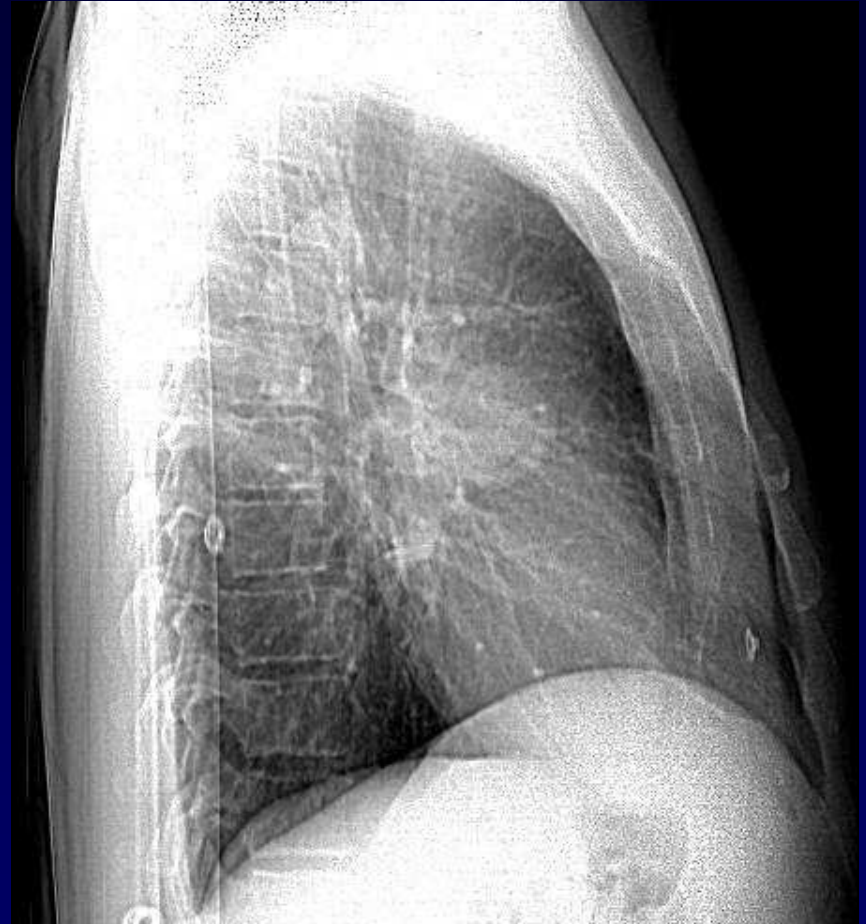
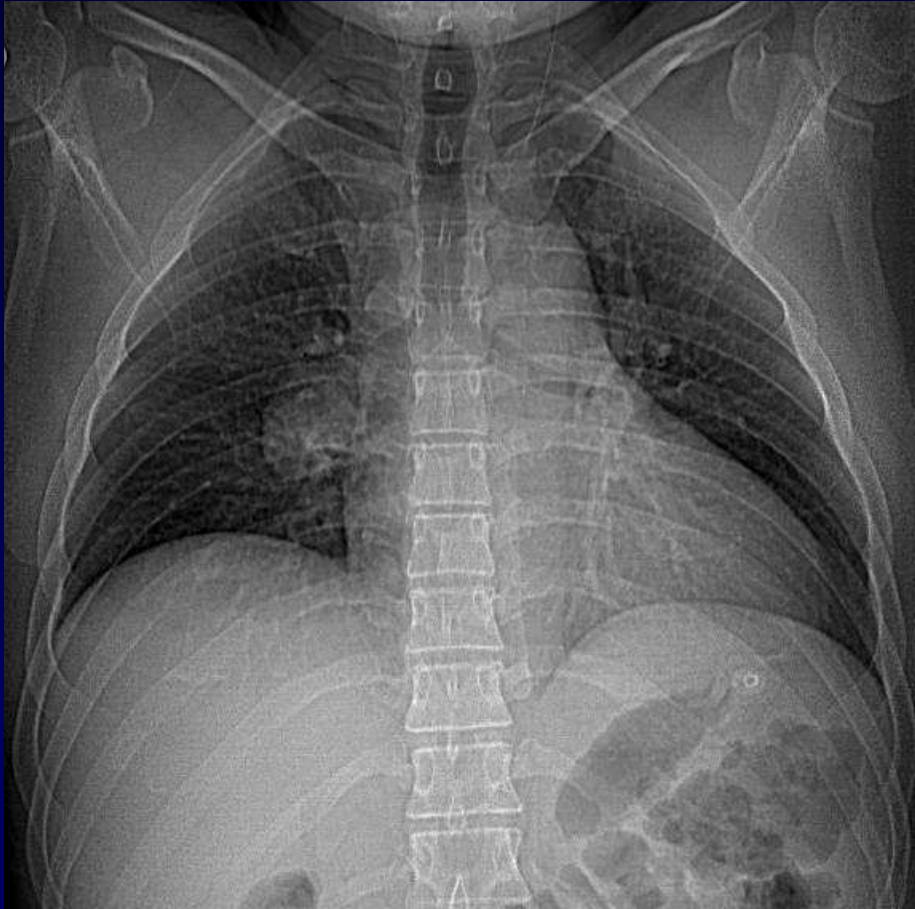
P FAJADET

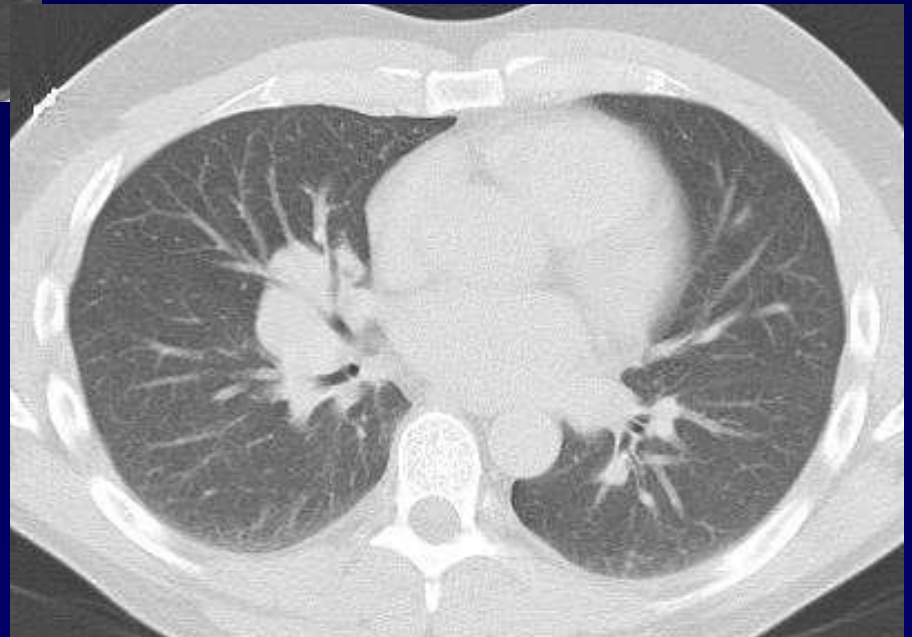
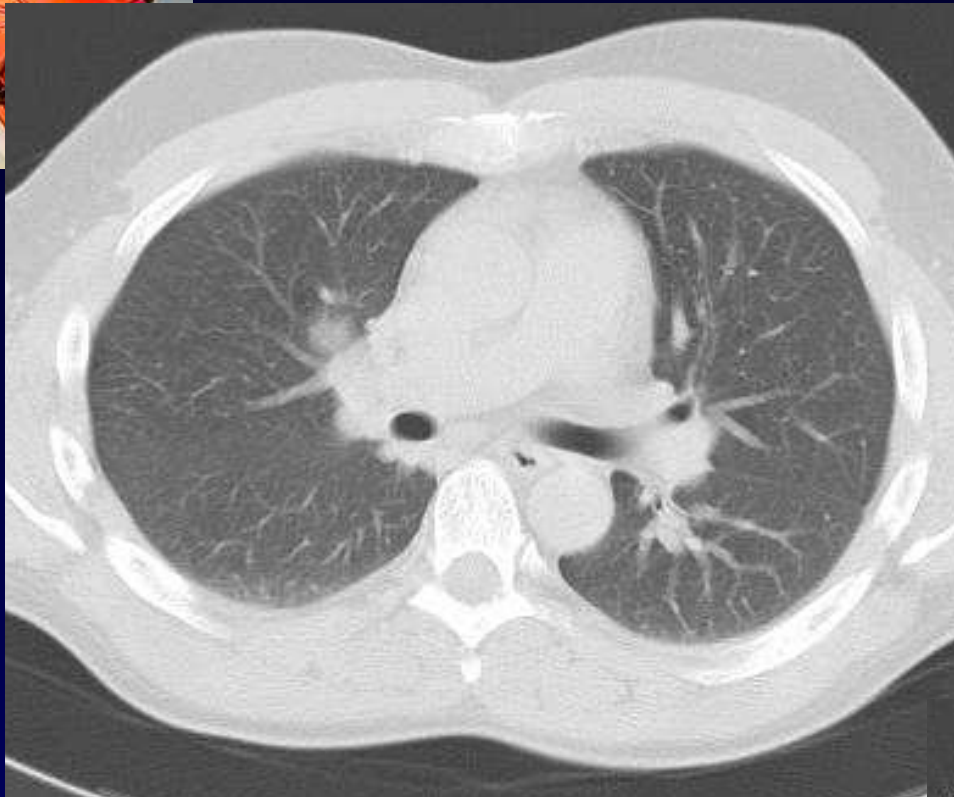
Homme de 35 ans

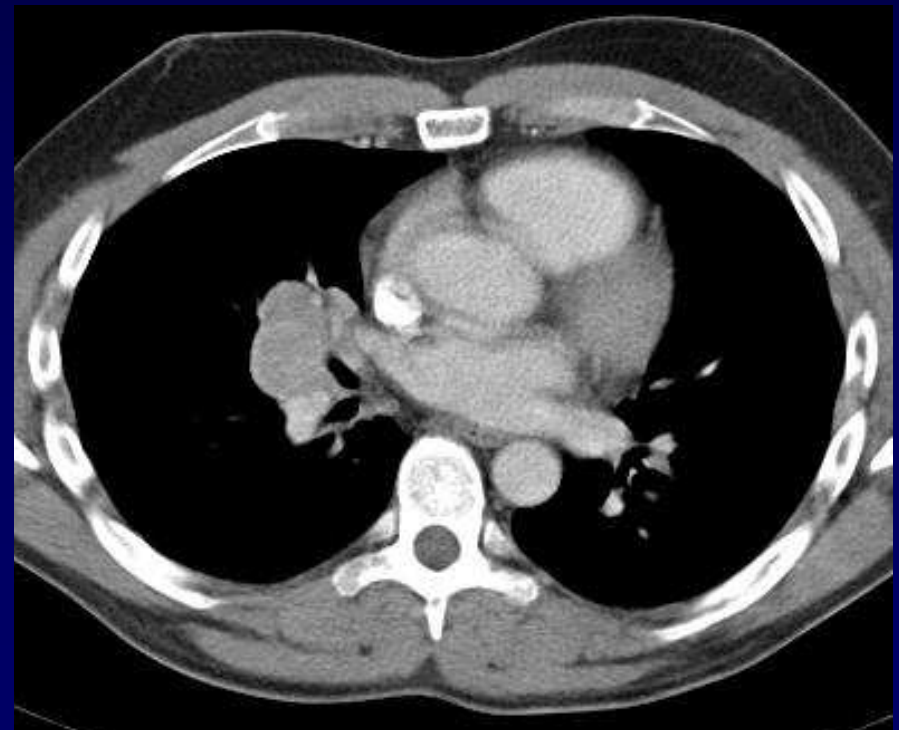
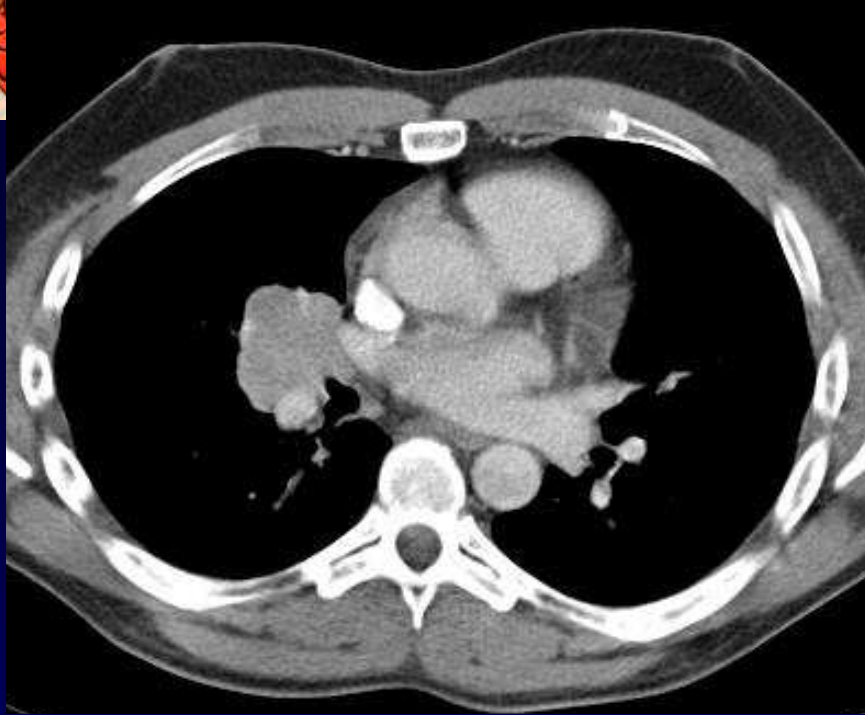
Clinique : Asymptomatique...

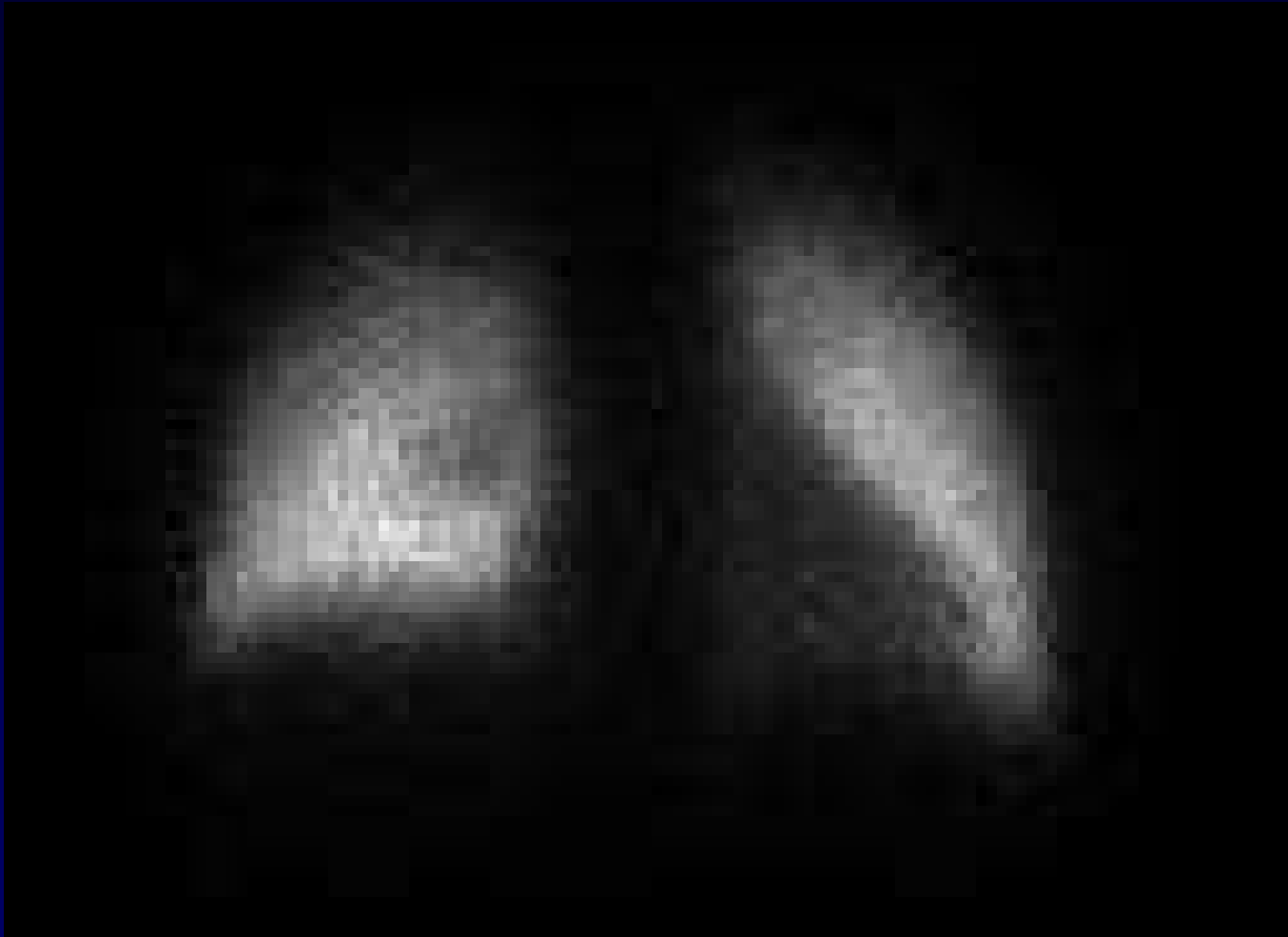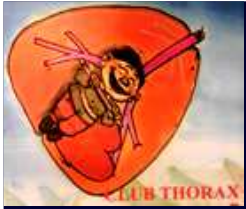Radio thorax d'embauche

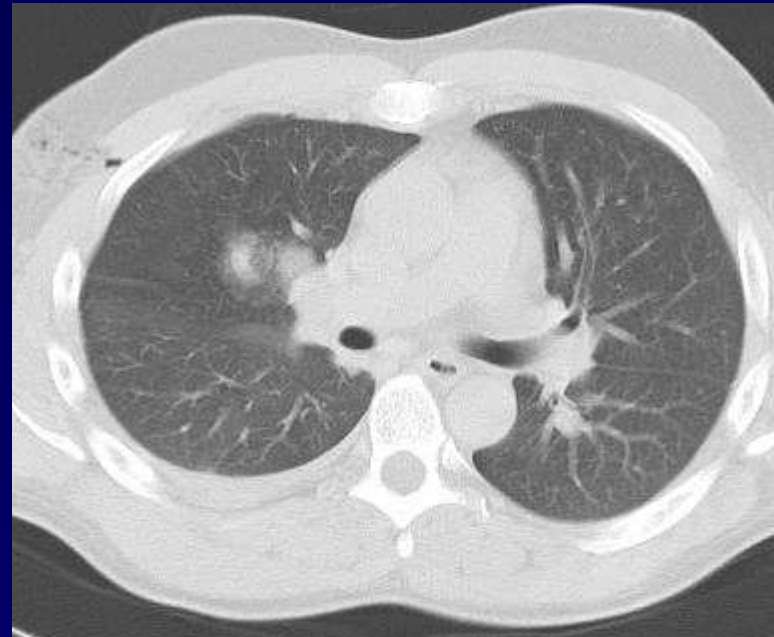
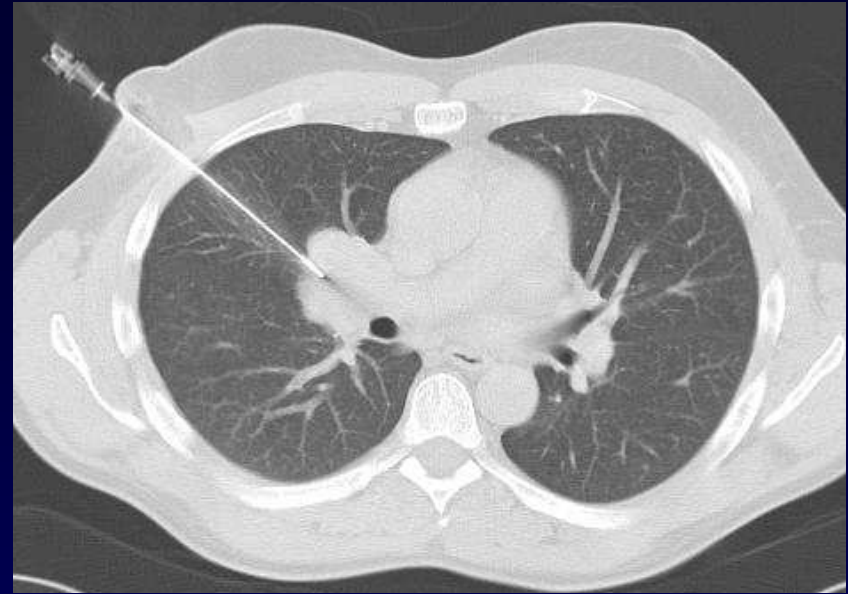
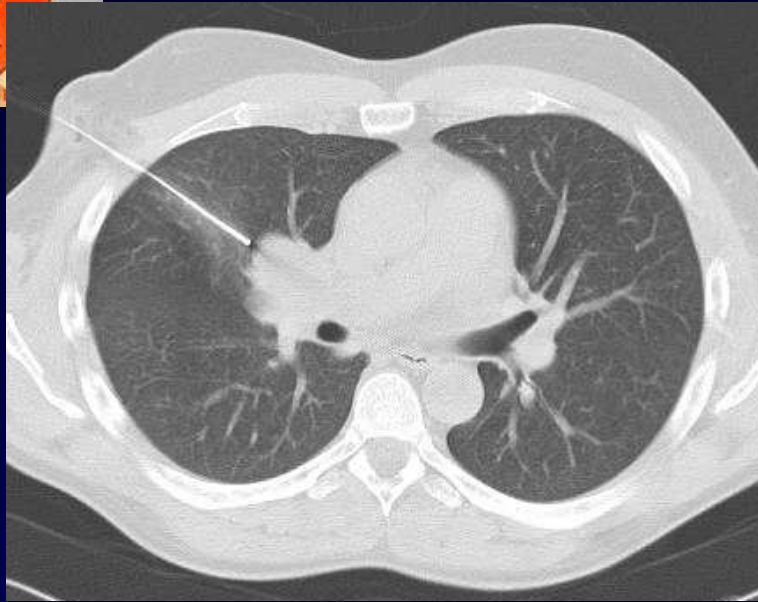














Diagnostic ?



Diagnostic

ADENOMEGALIES NON COMPRESSIVES

Biopsies thoraciques sous TDM :

NON MALIGNES

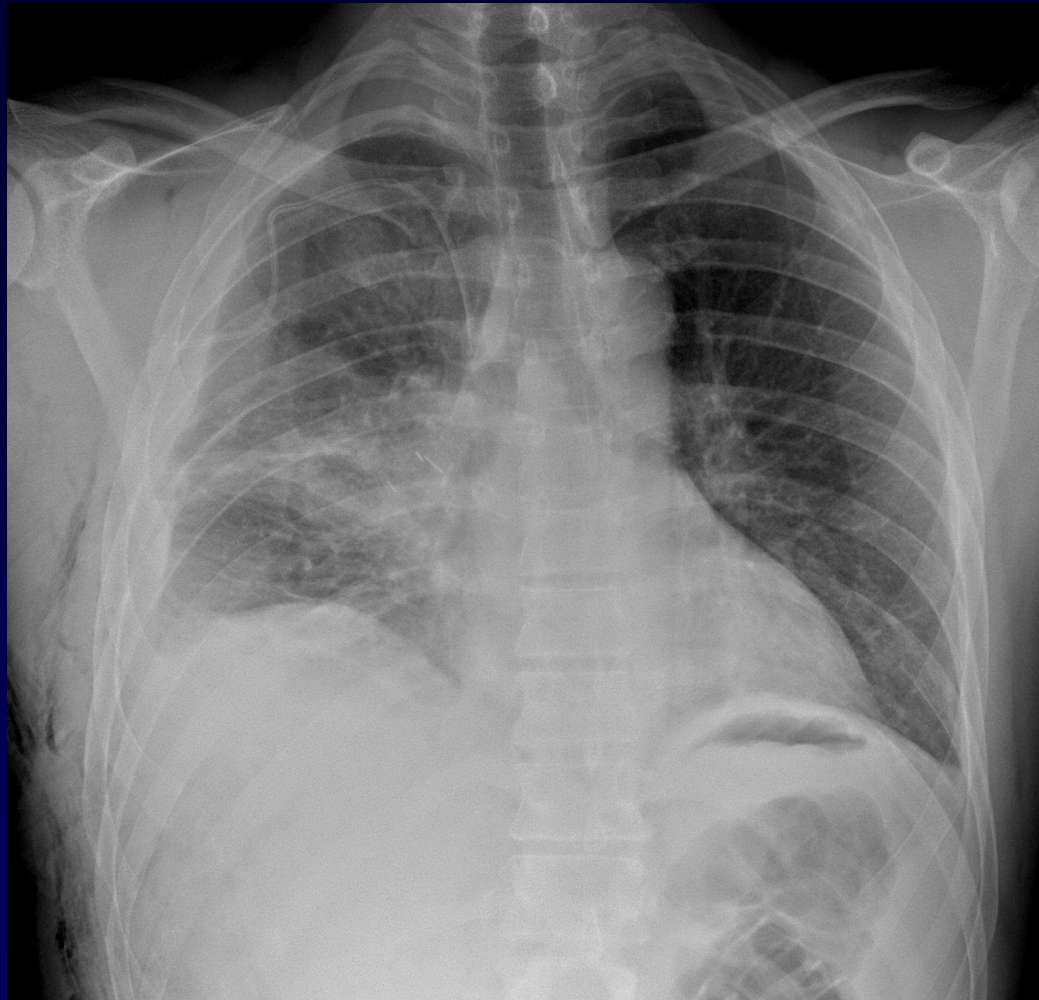NON LYMPHOMATEUSES

INFLAMMATOIRES ?

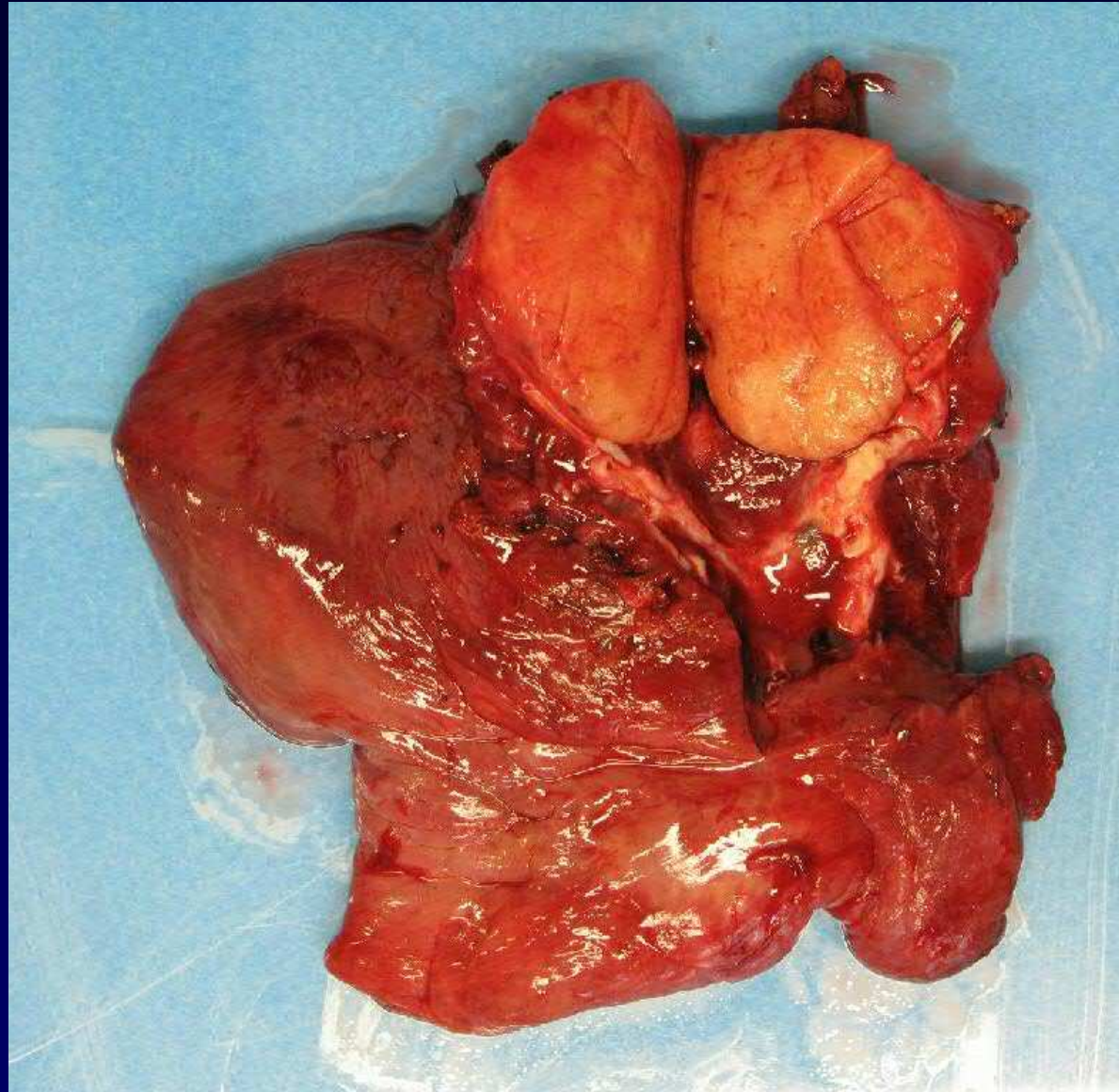


Evolution - Discussion

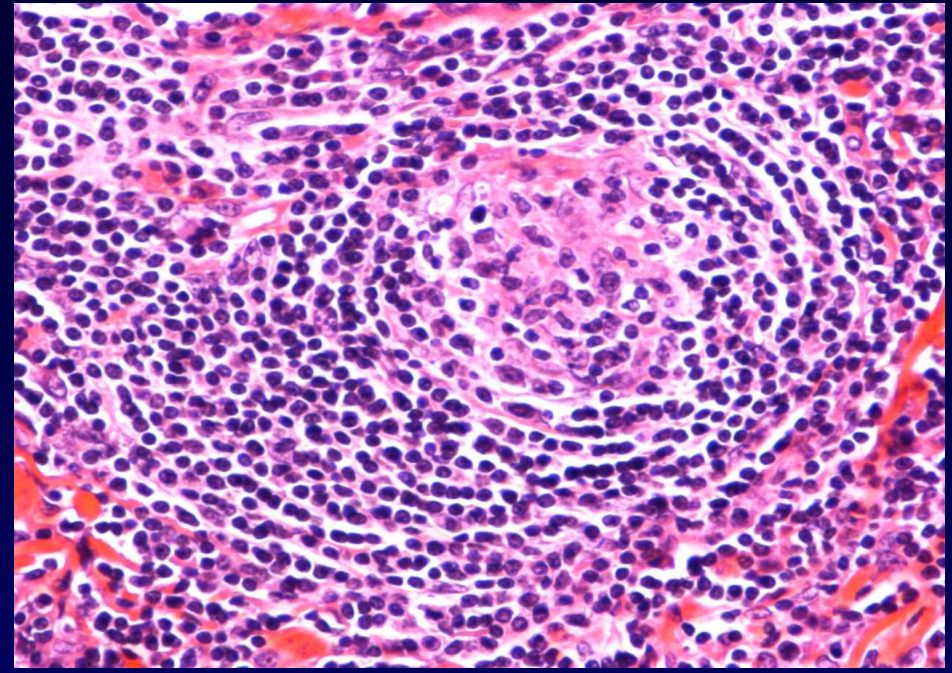
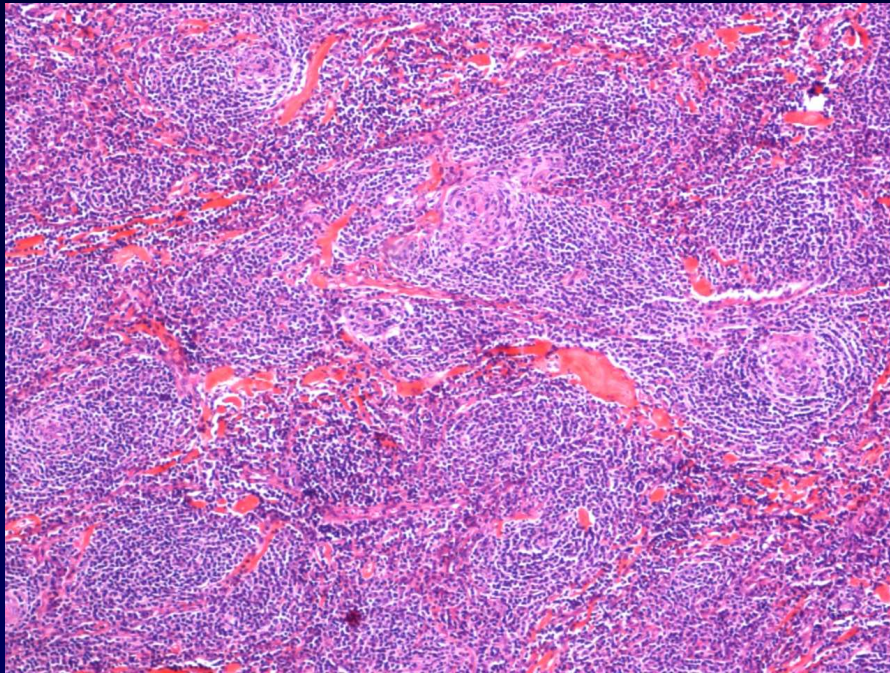
**PNEUMONECTOMIE ?
TRAITEMENT MEDICAL ?
CERTITUDE HISTOLOGIQUE !**



**Décision collective (RCP)
prélèvement chirurgical
pour diagnostic anapath. définitif**



MACRO: ADP BIEN LIMITEES



LYMPHOCYTES BANAUX ALIGNES « en bulbes »
VEINULES NOMBREUSES
HYALINISATION

Courtoisie I. Rouquette (CHU Toulouse)



Diagnostic

MALADIE DE CASTELMAN

**Forme vasculaire hyaline
(unique , peu agressive)**



MALADIE de CASTELMAN

– Forme vasculaire hyaline

– Forme plasmocytaire

ADP Multiples

ADP compressives

VIH