

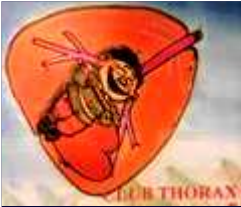

Dossier 3

Alexis LACOUT

Homme de 68 ans

Non fumeur

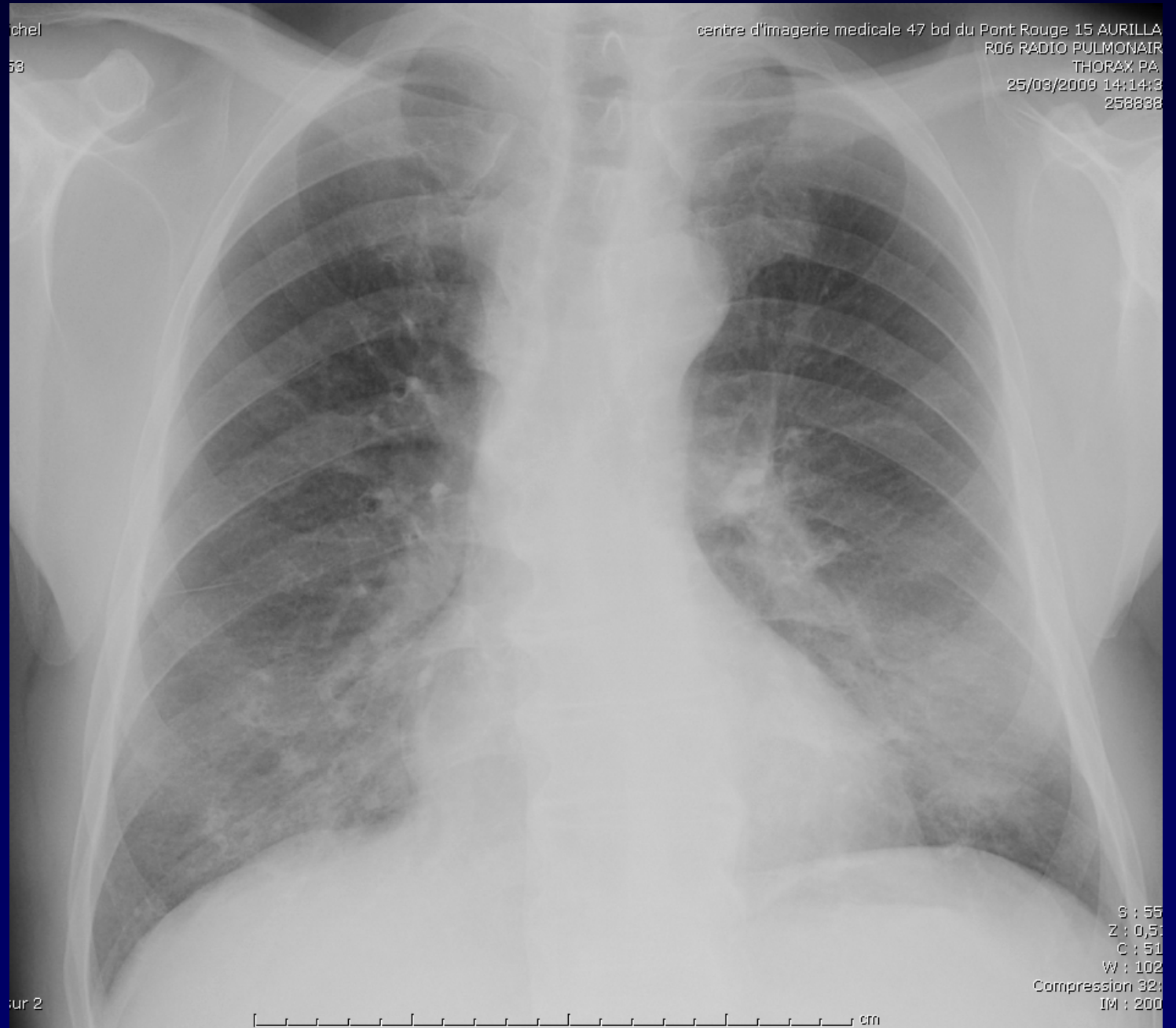
Toux ++



chel


58

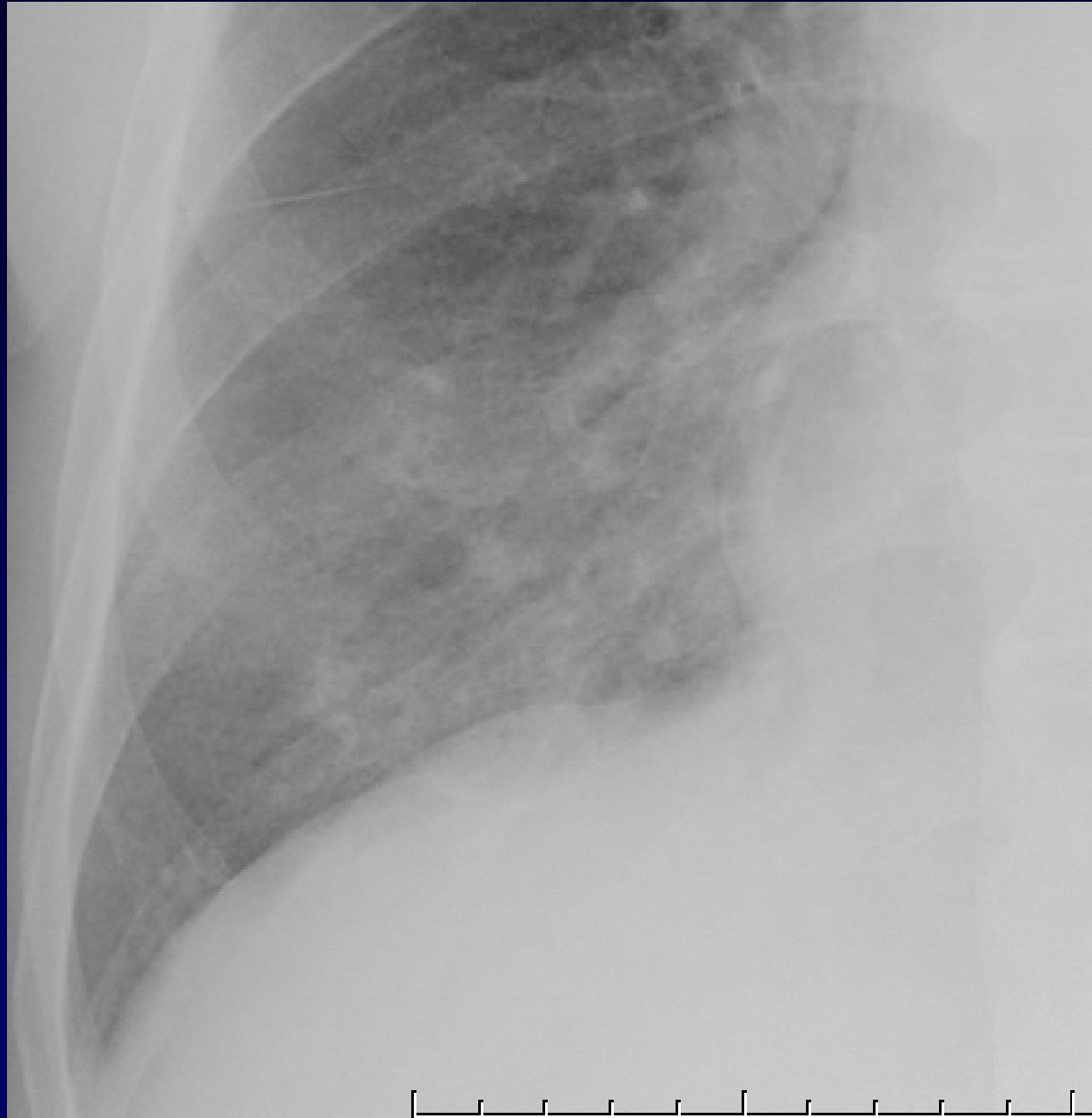
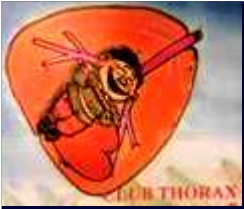centre d'imagerie medicale 47 bd du Pont Rouge 15 AURILLA
R06 RADIO PULMONAIRE
THORAX PA
25/03/2009 14:14:3
258838

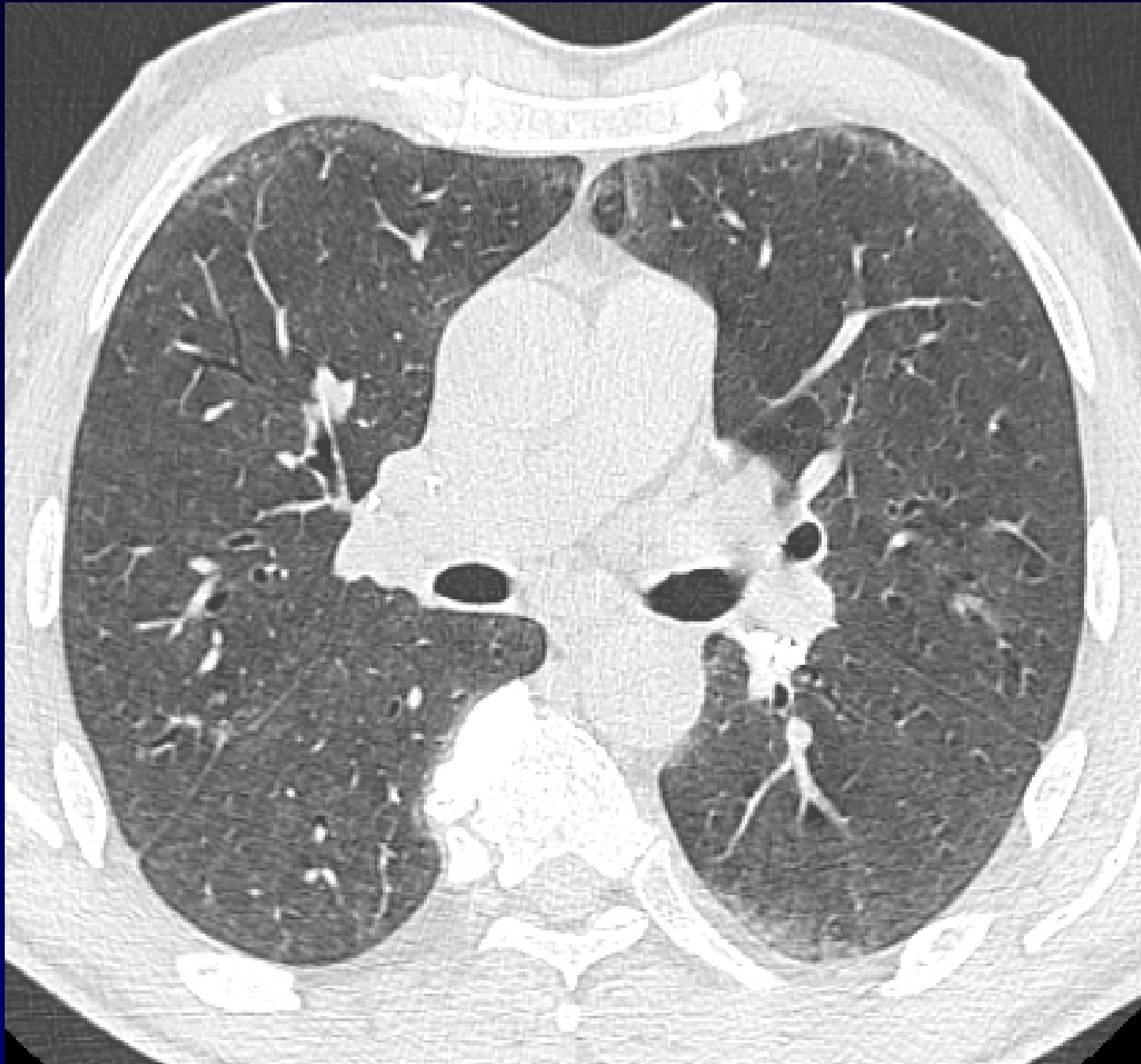
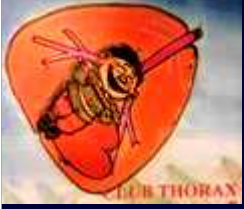

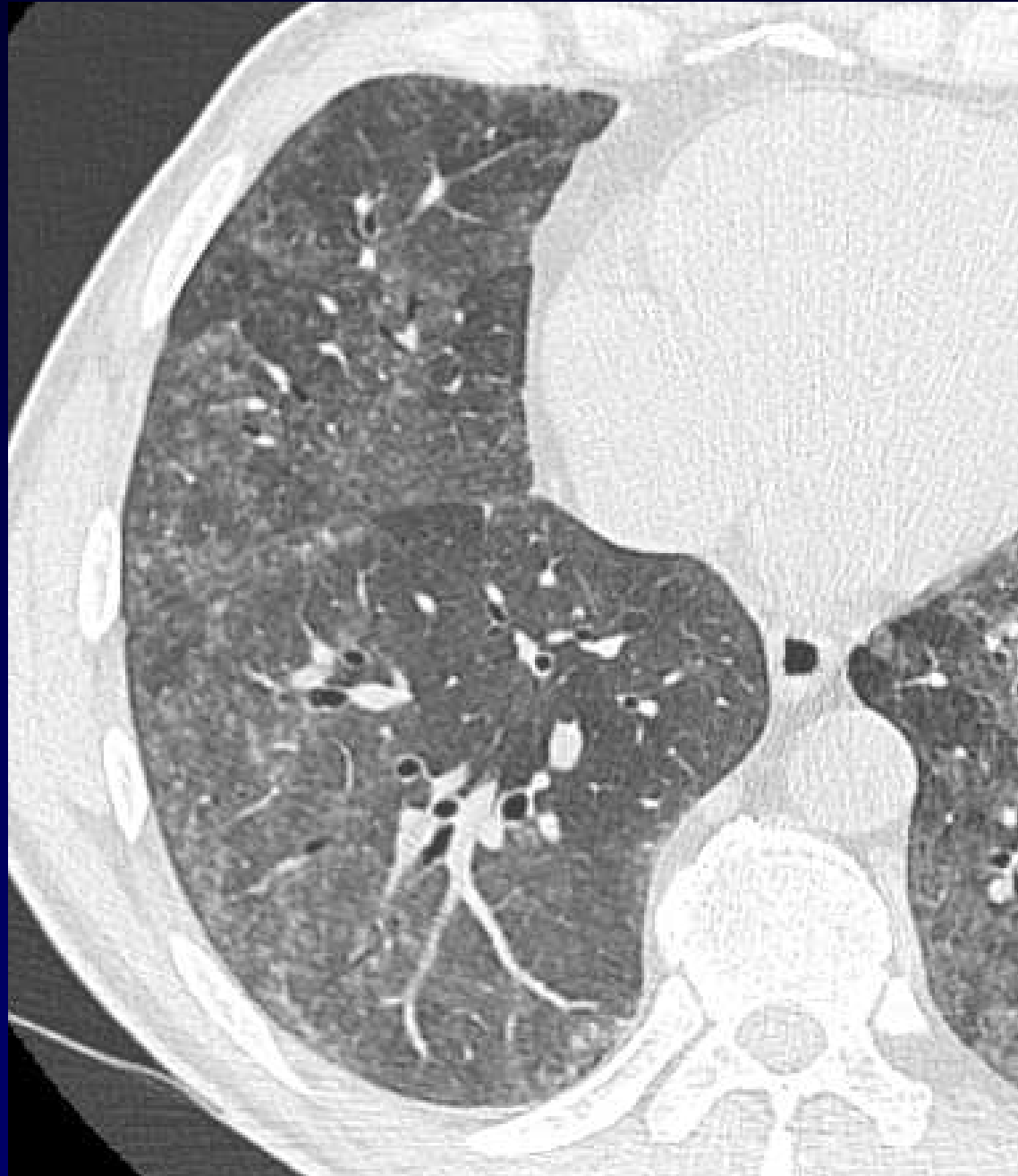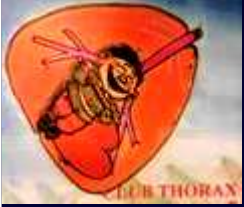S : 55
Z : 0,51
C : 51
W : 102
Compression 32:
IM : 200

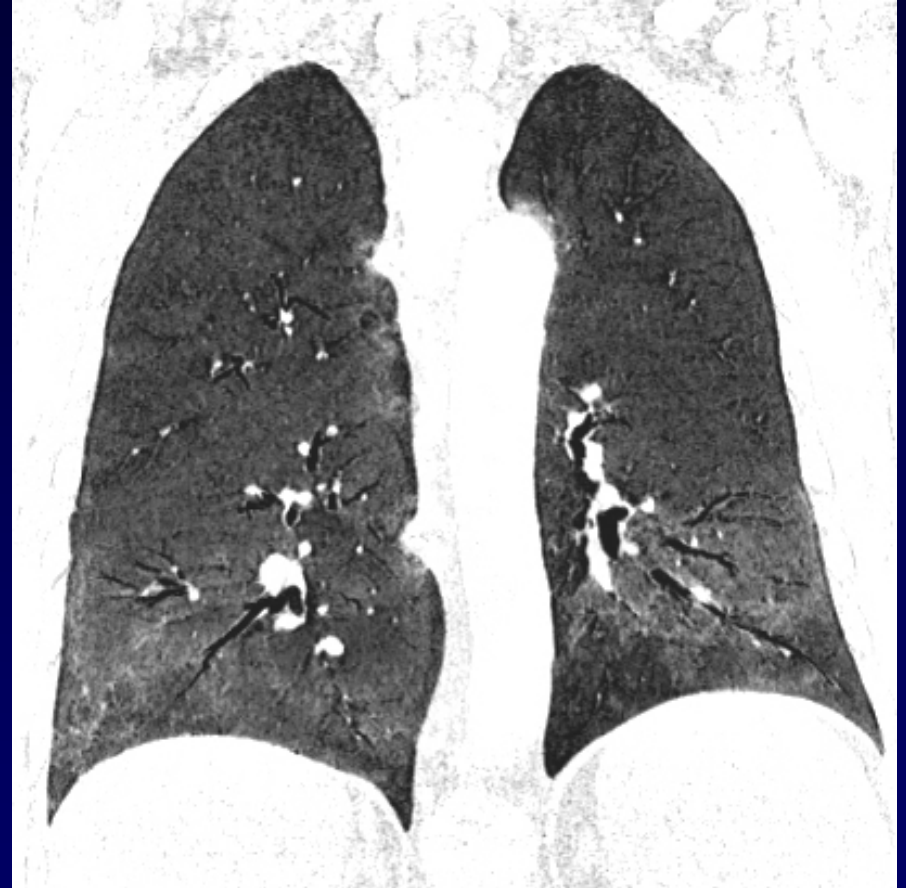
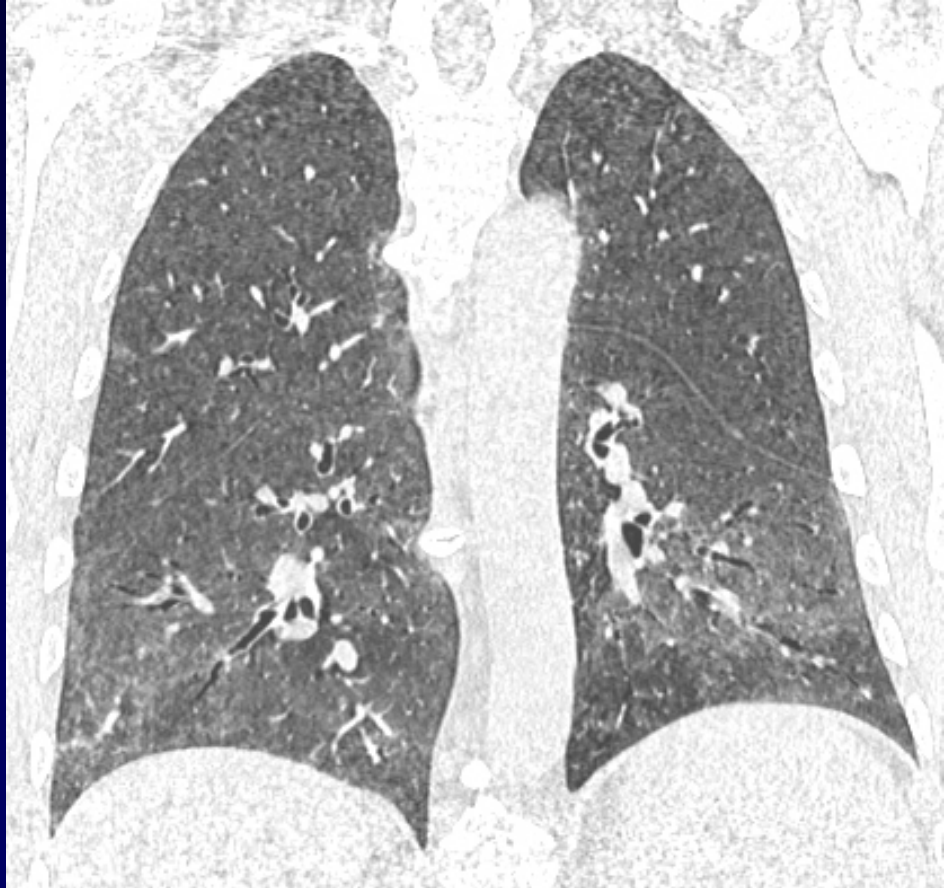
ur 2













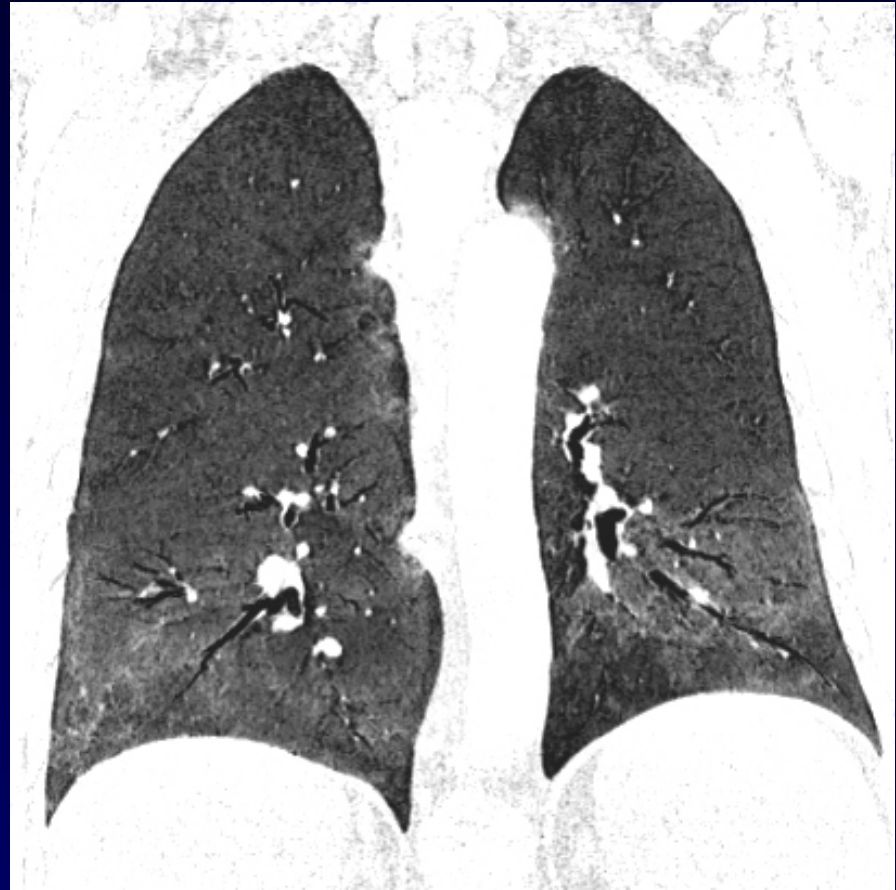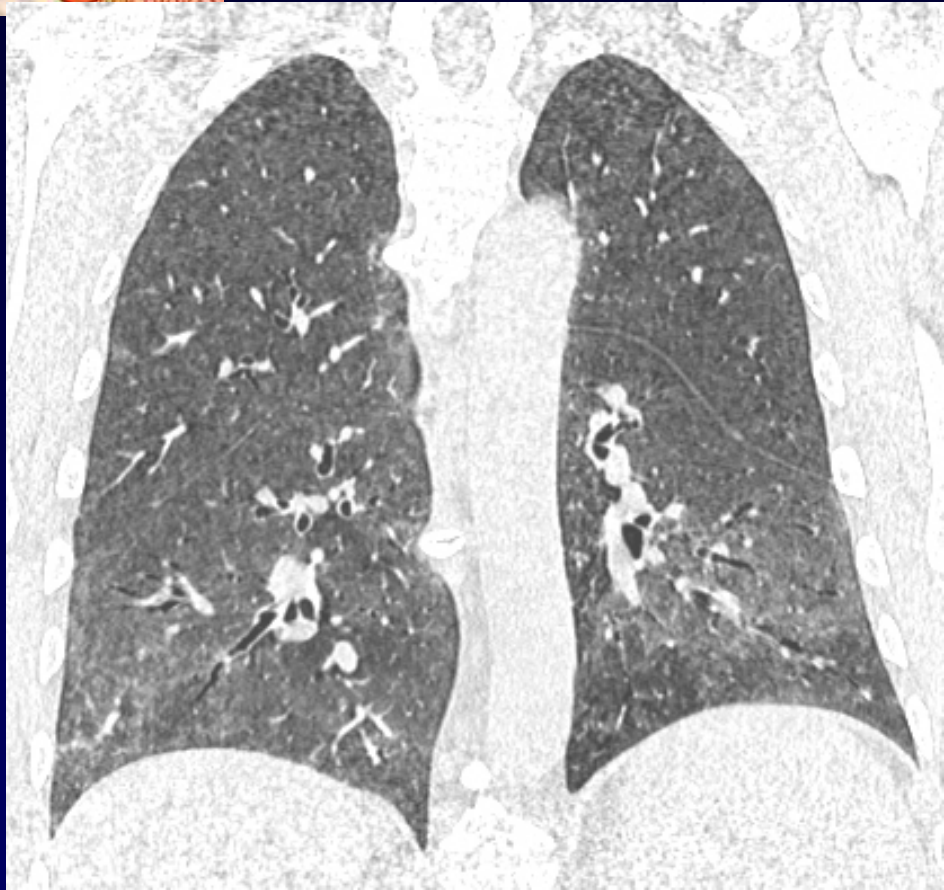
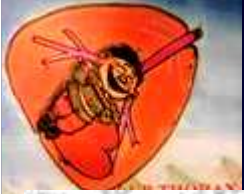Diagnostic ?



Diagnostic

Pneumopathie d'hypersensibilité (PHS)

Poumon de fermier



Syndrome interstitiel à grains très fins :
micronodules flous centrolobulaires formant un verre dépoli
Les images prédominent ici aux bases