



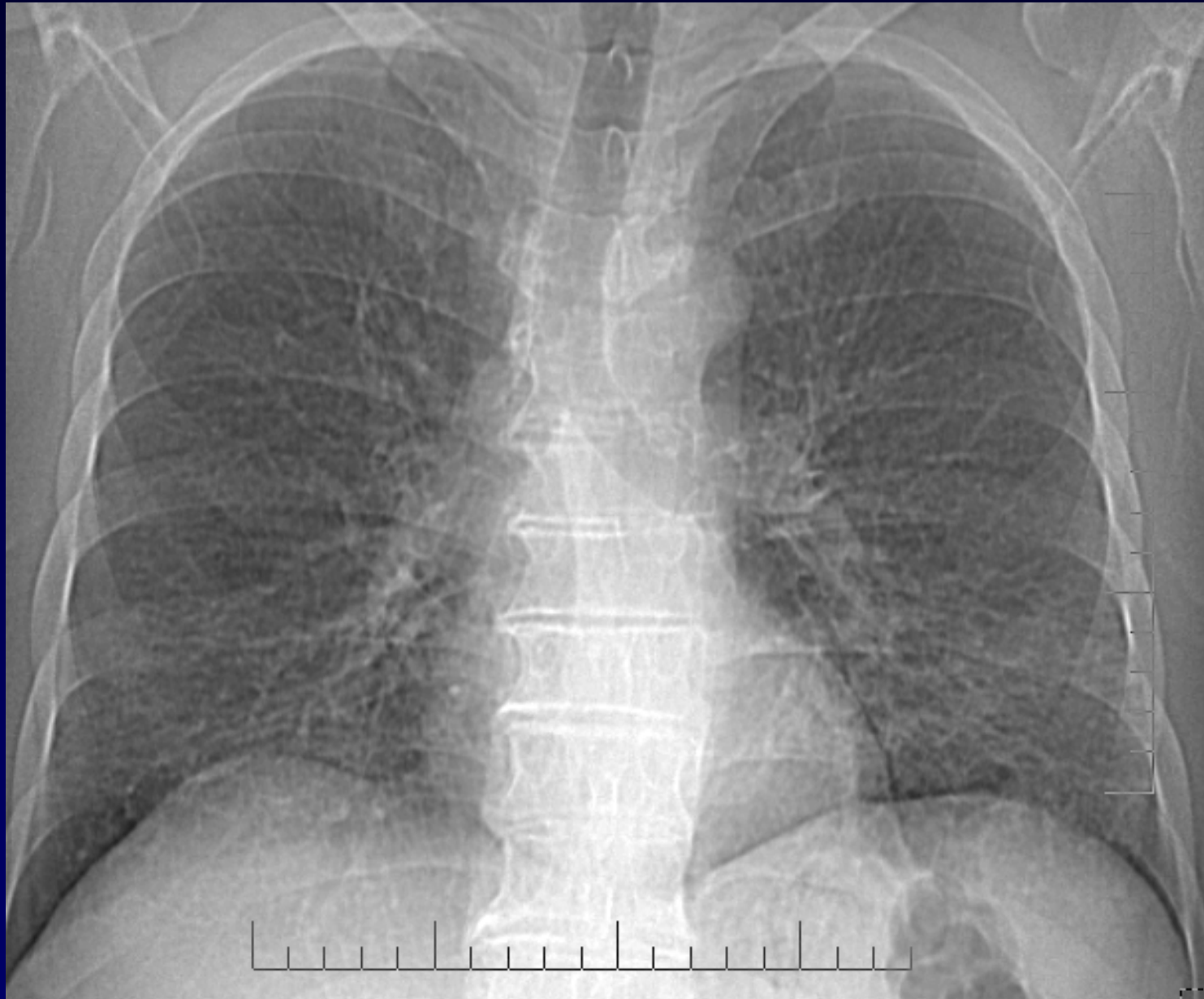Dossier 4

Alexis LACOUT

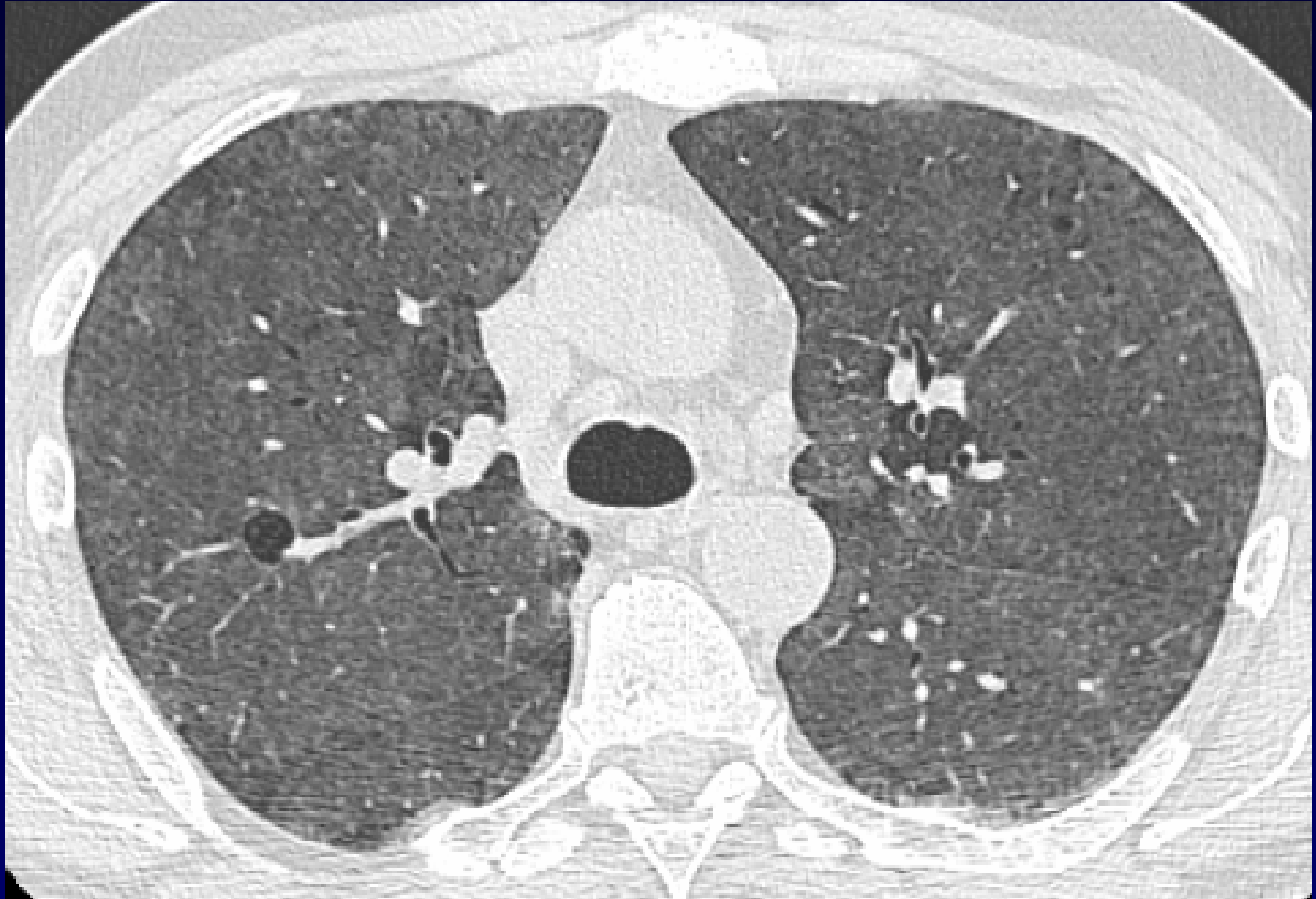
Homme de 53 ans

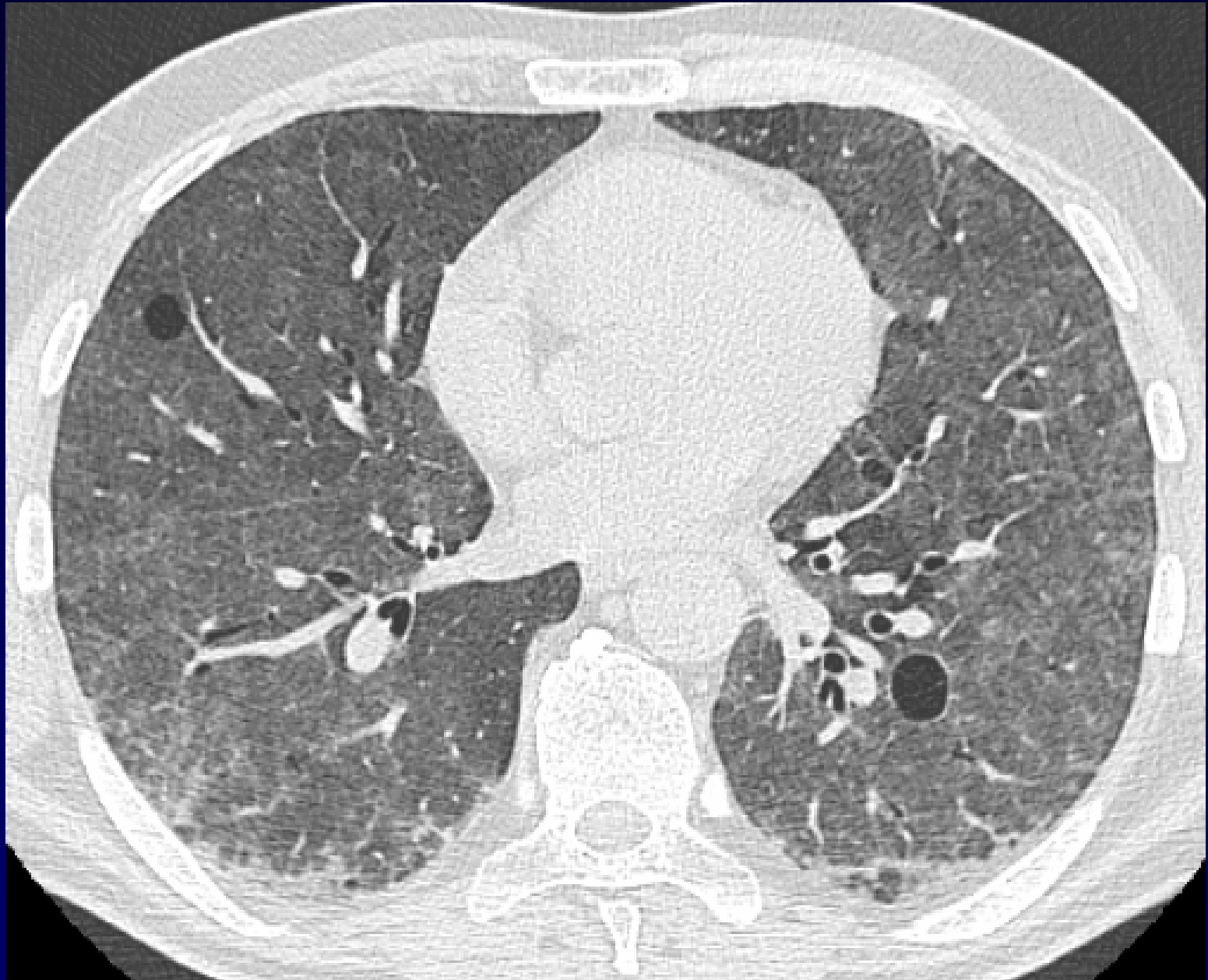
Agriculteur, non fumeur

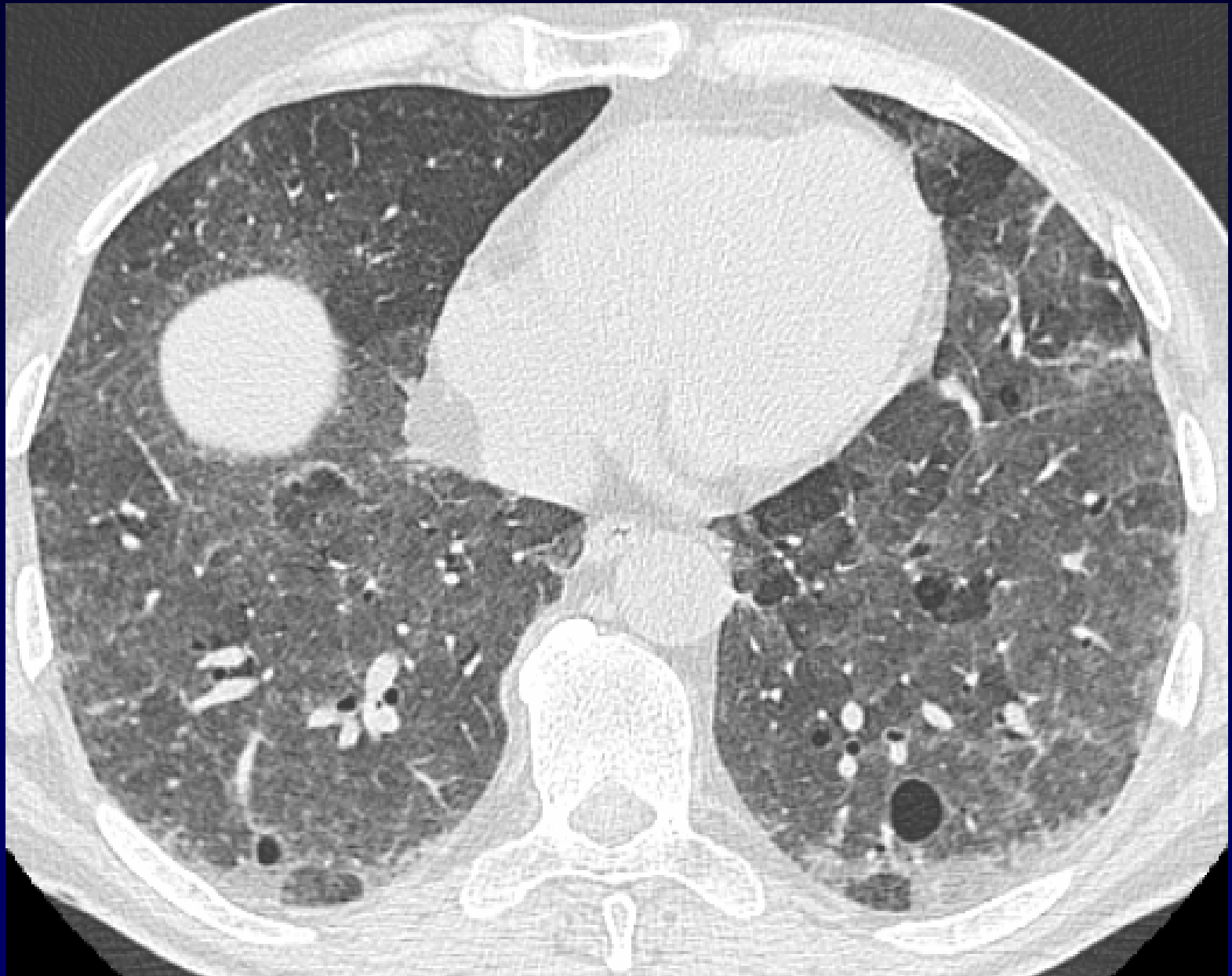
Dyspnée au moindre effort

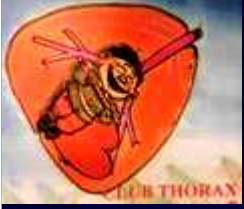

Scout View









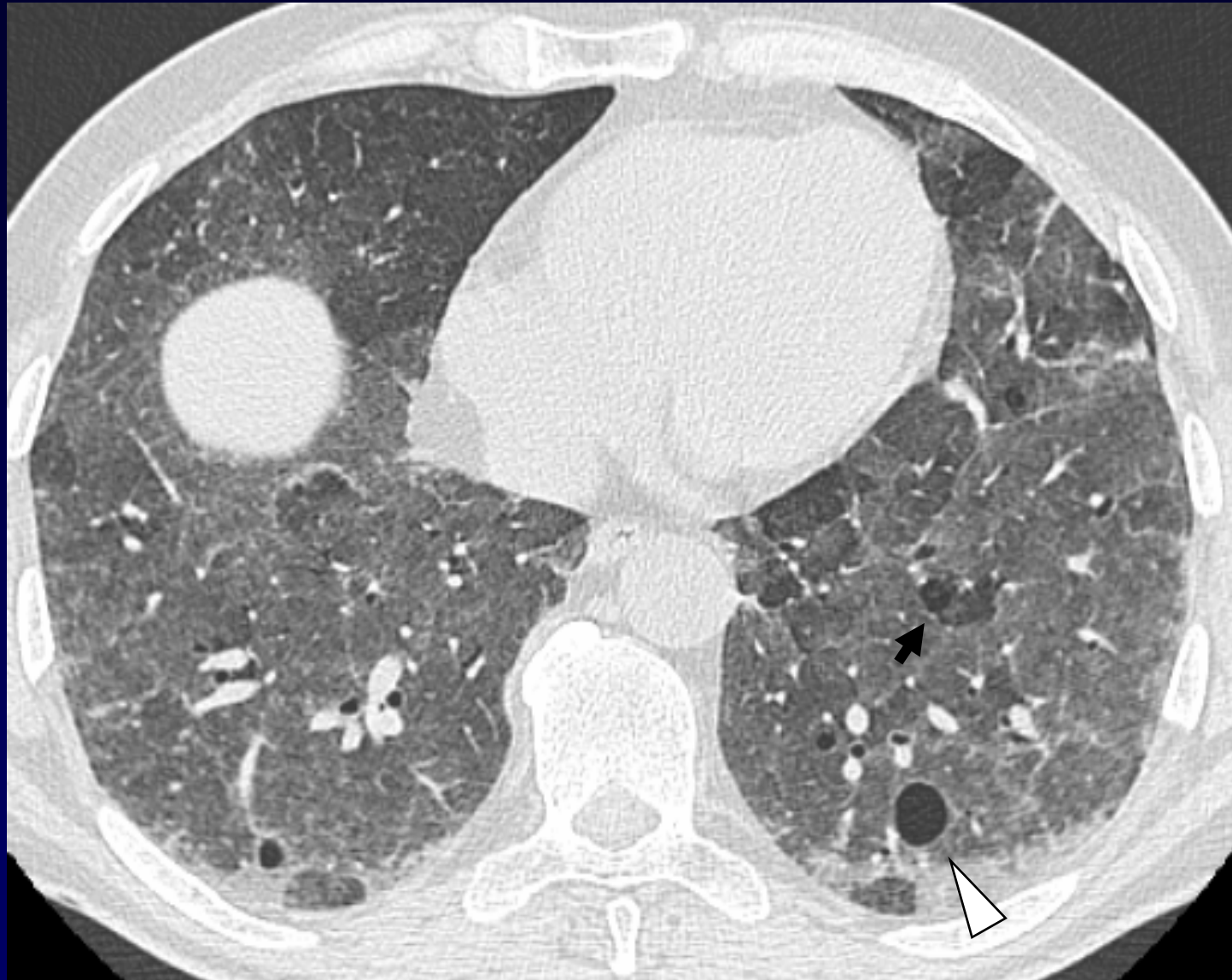
Diagnostic ?



Diagnostic

Pneumopathie d'hypersensibilité (PHS)

Poumon de fermier



**Micronodules centrolobulaires flous (sommation = verre dépoli),
trappage des bases (flèche) et kystes (tête de flèche)**

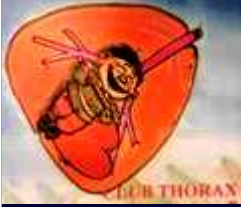

Discussion : Kystes et PHS

Obstruction bronchiolaire

Bronchioles « soufflées » ?





Références

- Thomas C, Bizieux-Thaminy A, Gagnadoux F, et al. An unusual cause of pulmonary cysts. *Rev Mal Respir* 2005; 22(2 Pt 1) : 313-6.
- Hoshi S, Tamura A, Sasaki O, Kato A, et al. Case of chronic pigeon breeder's disease accompanied by pulmonary cysts. *Nihon Kokyuki Gakkai Zasshi* 2007; 45 : 766-71.
- Franquet T, Hansell DM, Senbanjo T, Remy-Jardin M, Müller NL. Lung cysts in subacute hypersensitivity pneumonitis. *J Comput Assist Tomogr* 2003; 27 : 475-8.