



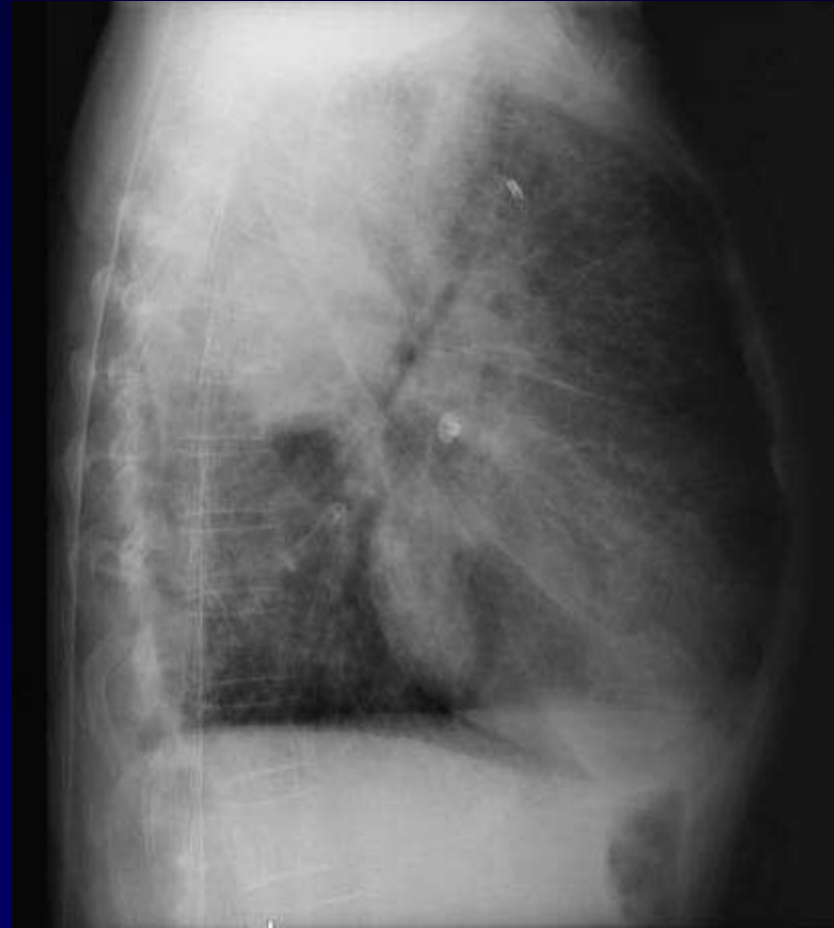
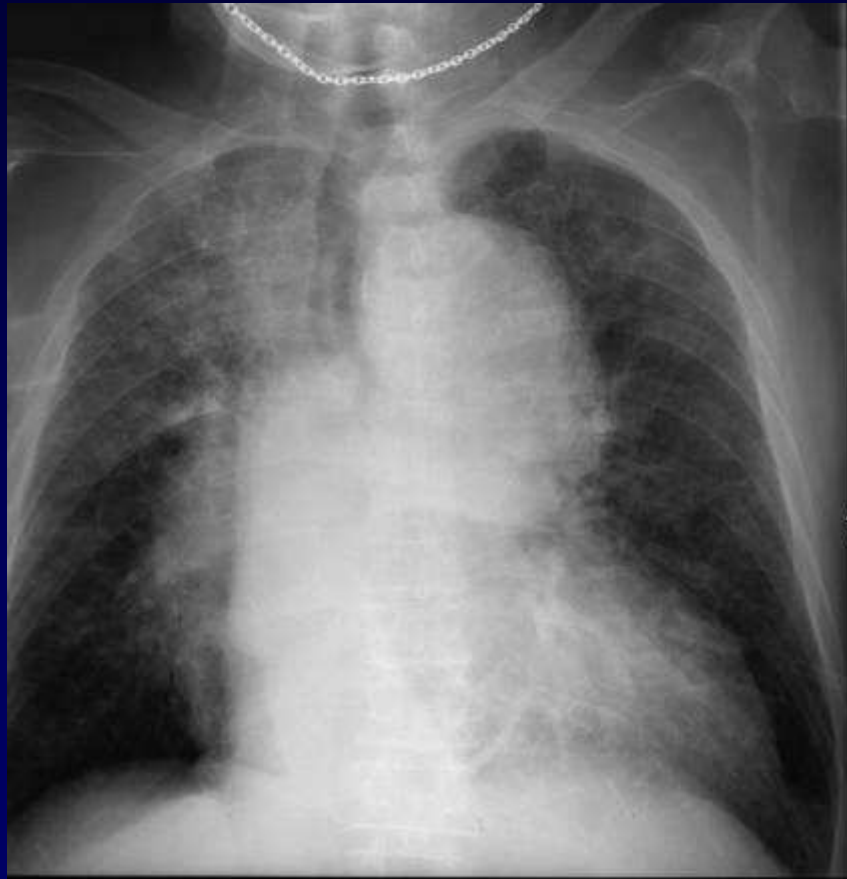Dossier 8

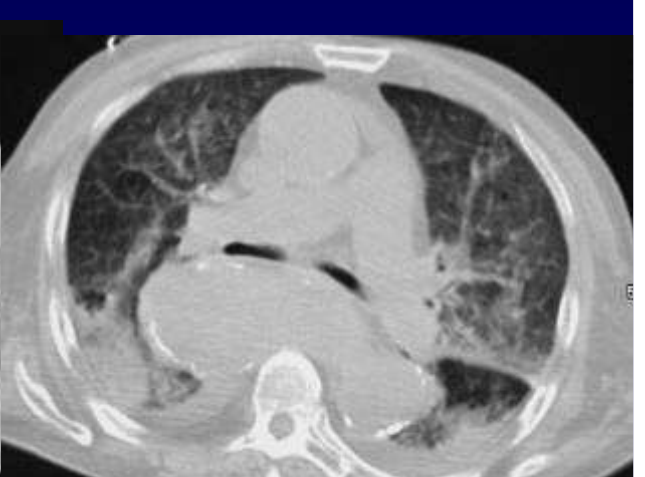
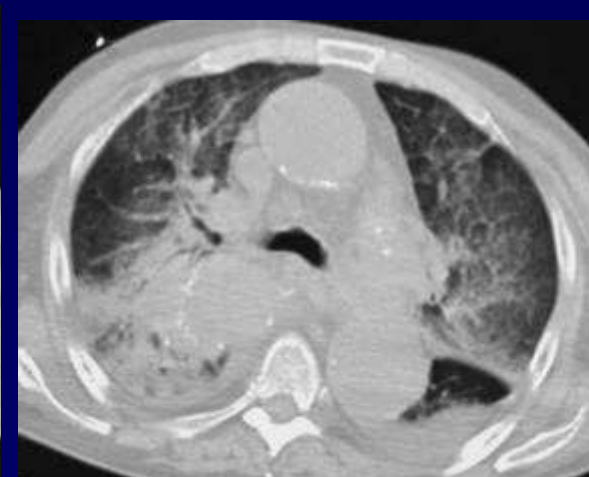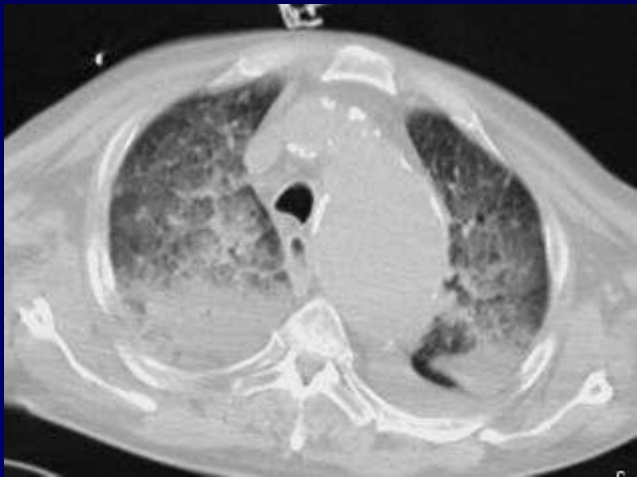
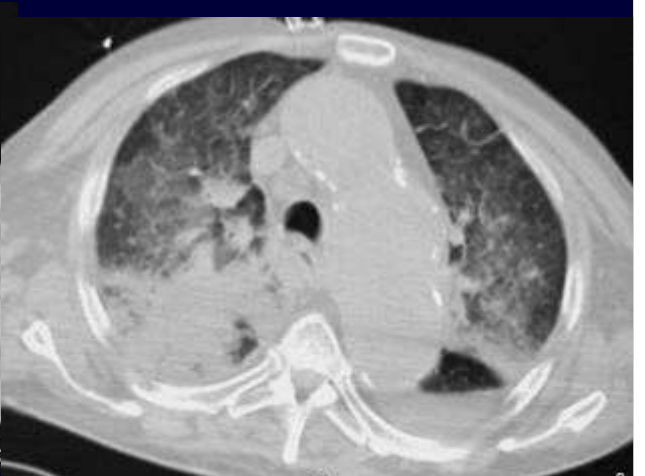
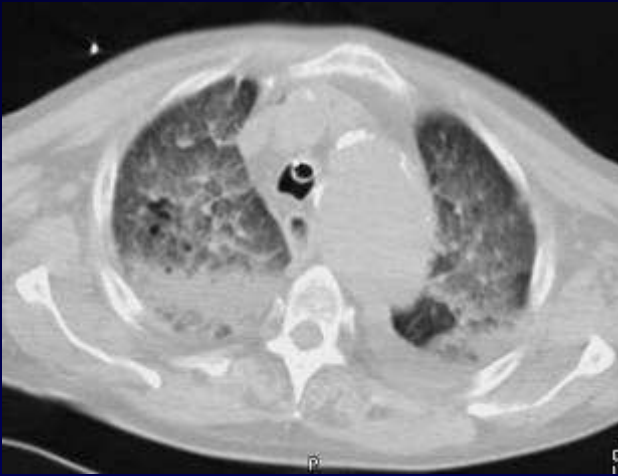
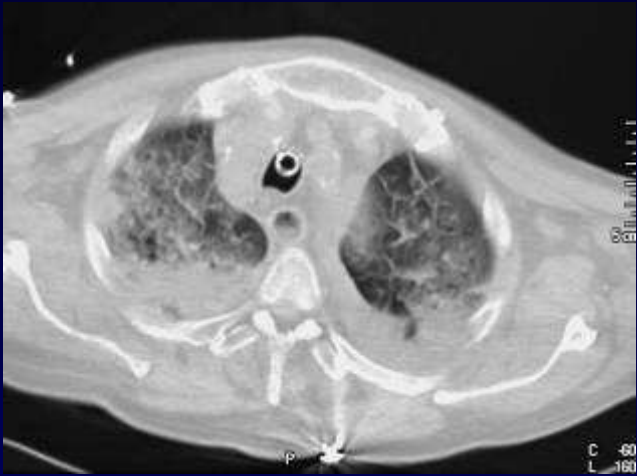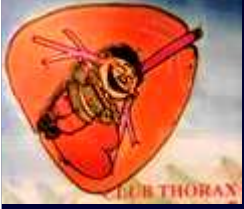L METGE

Homme de 78 ans

Hémoptysie de moyenne abondance

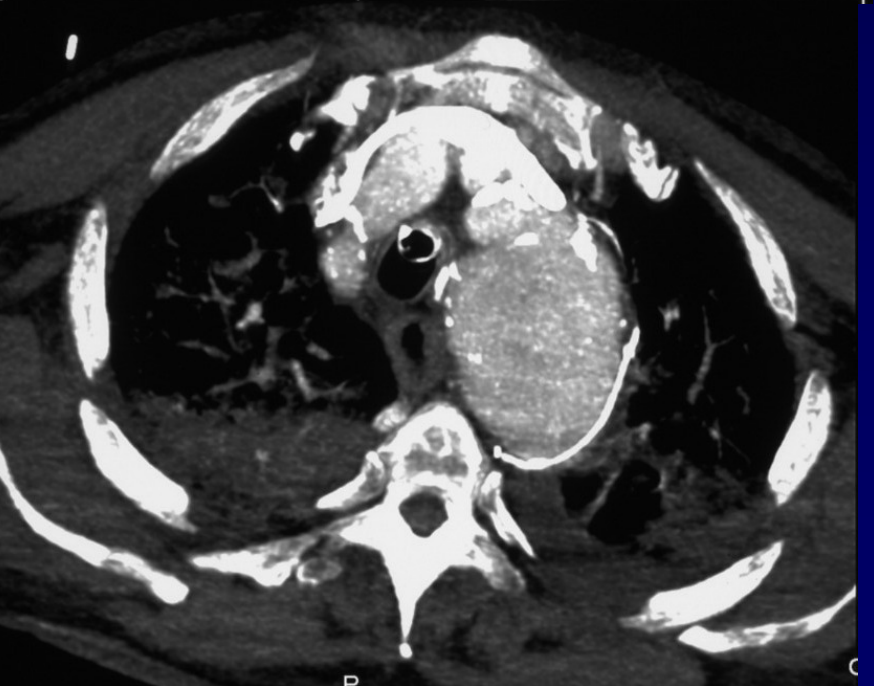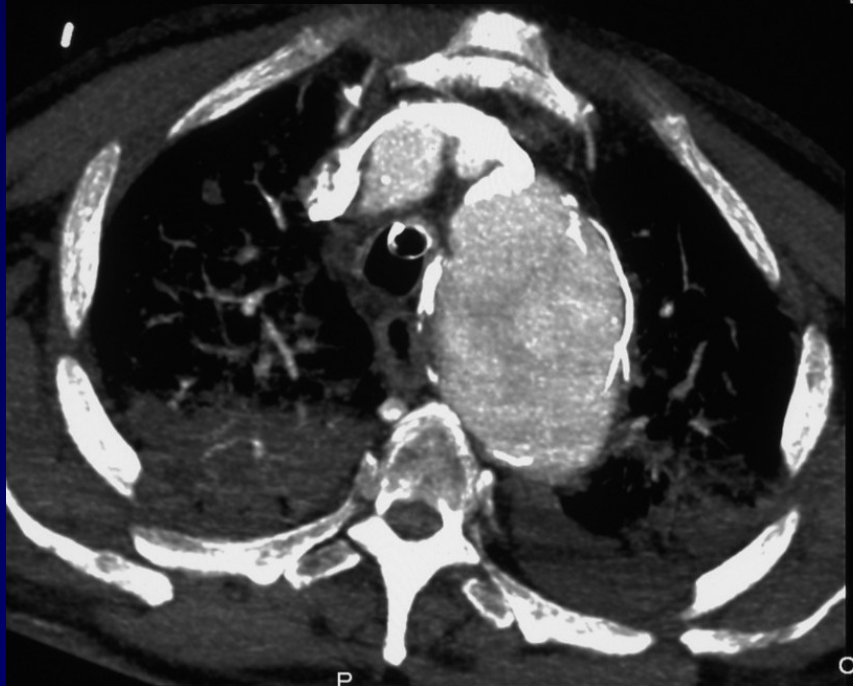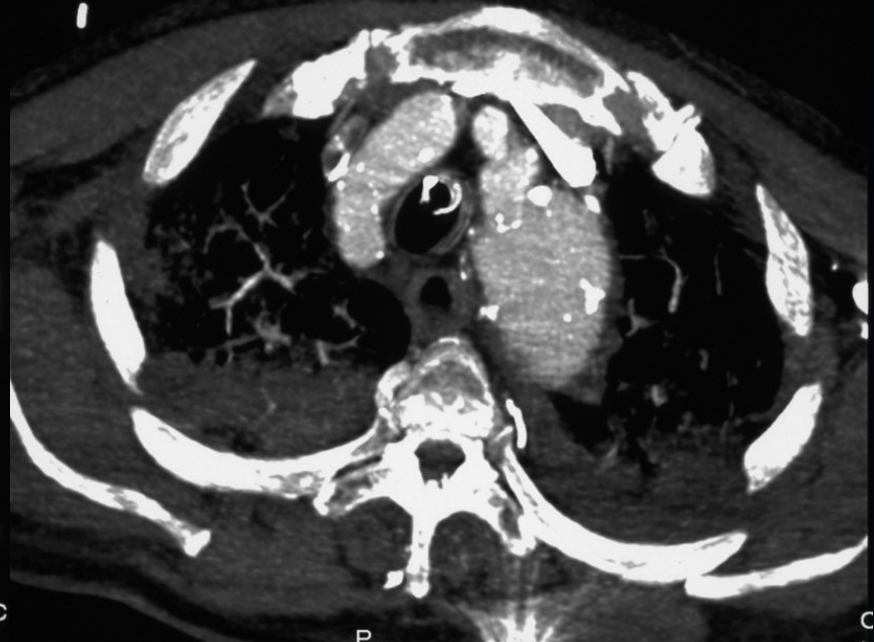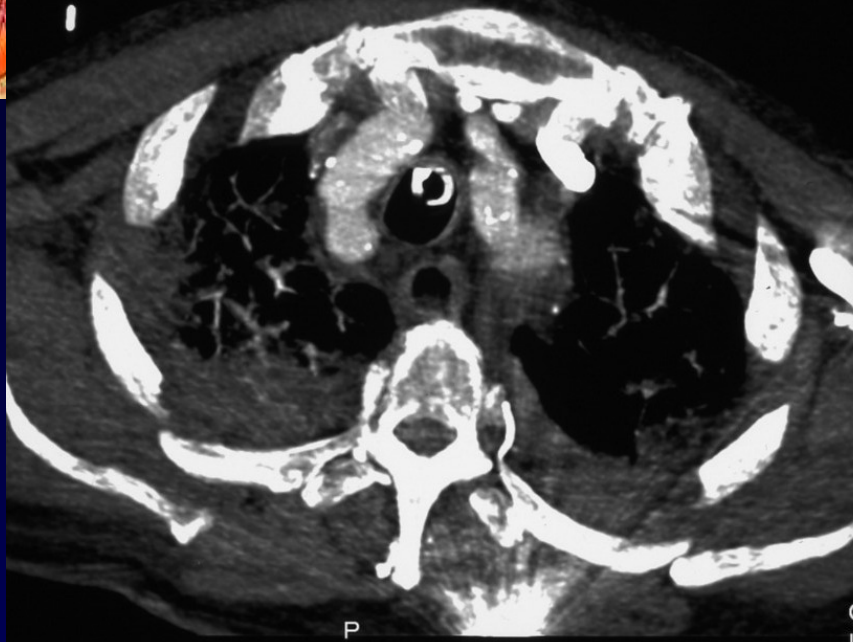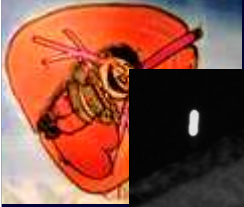Anévrysme de l'aorte abdominale connu

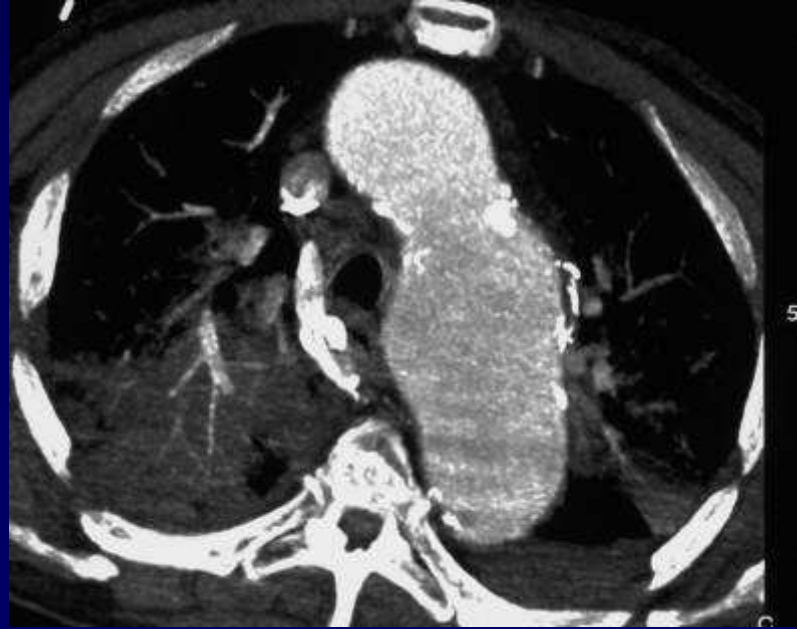
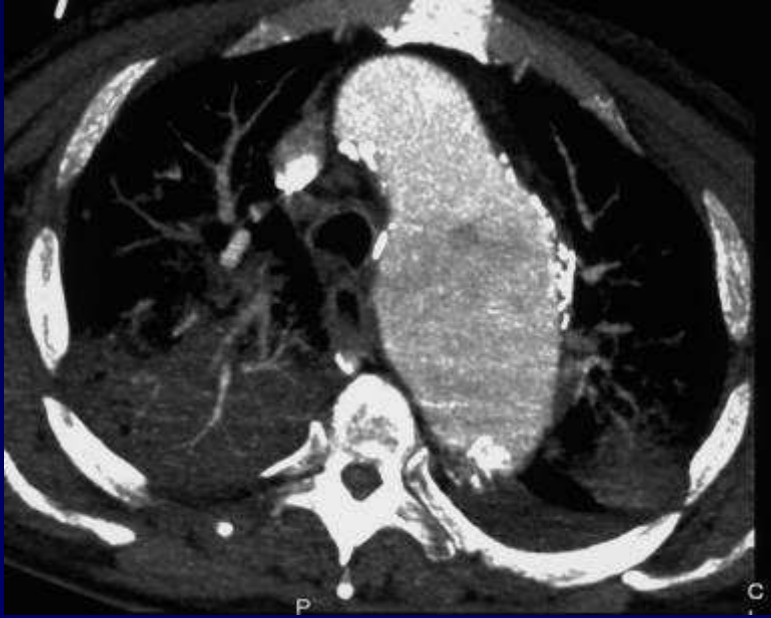
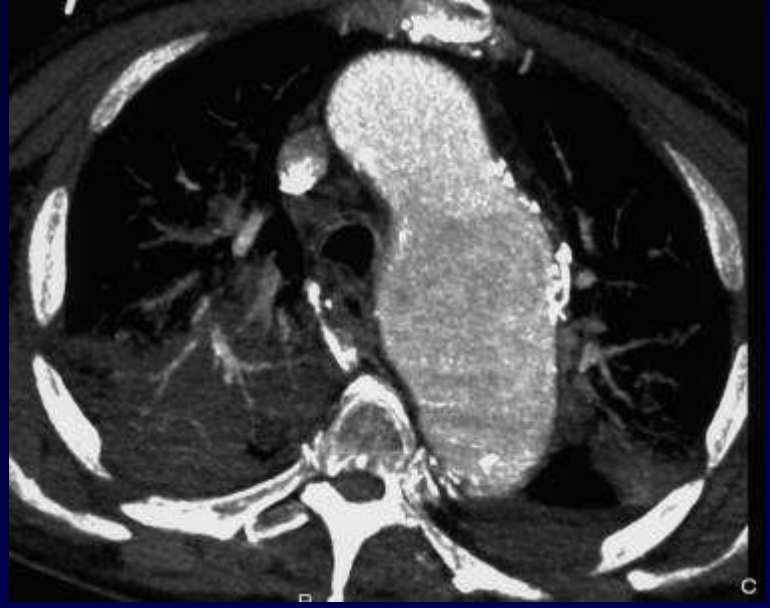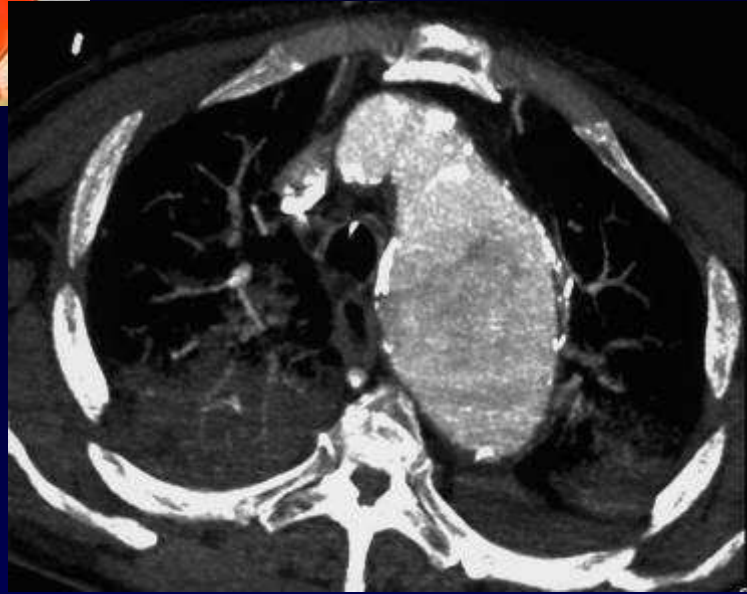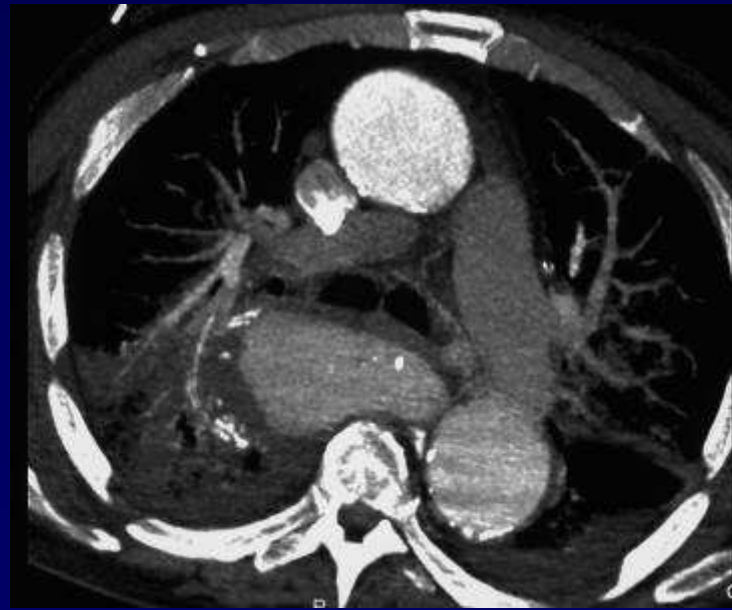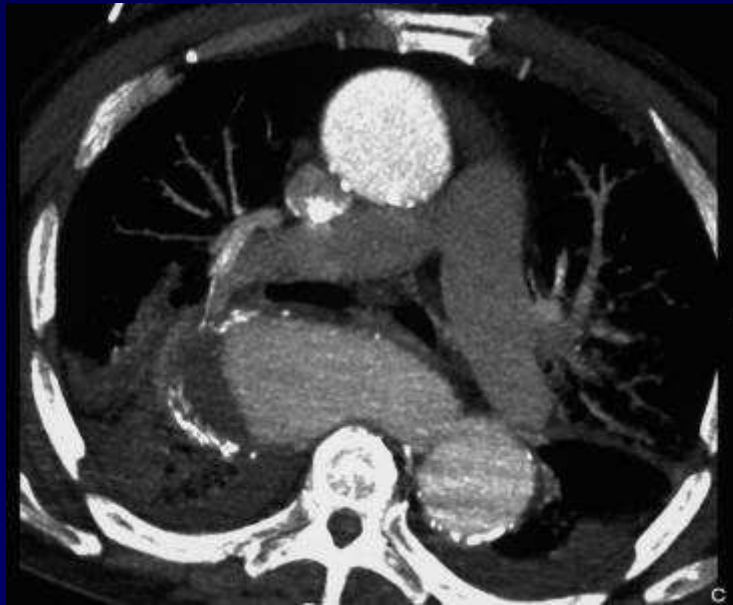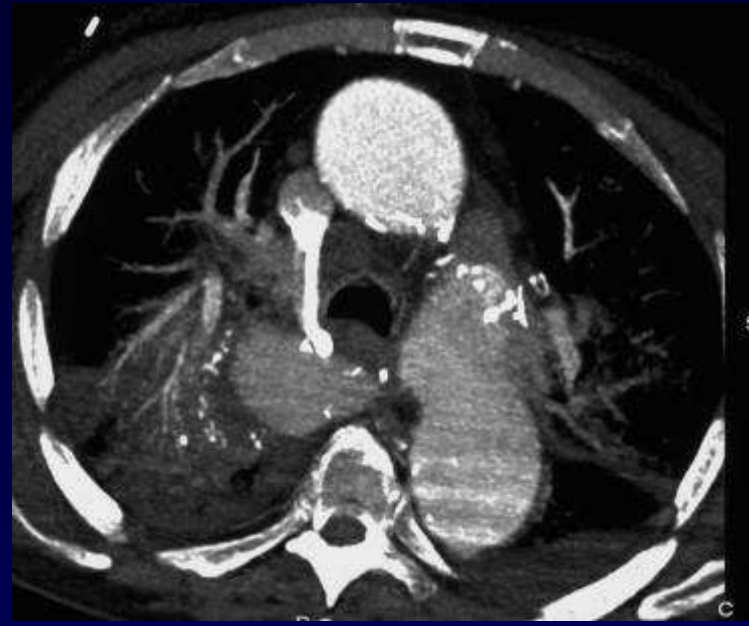
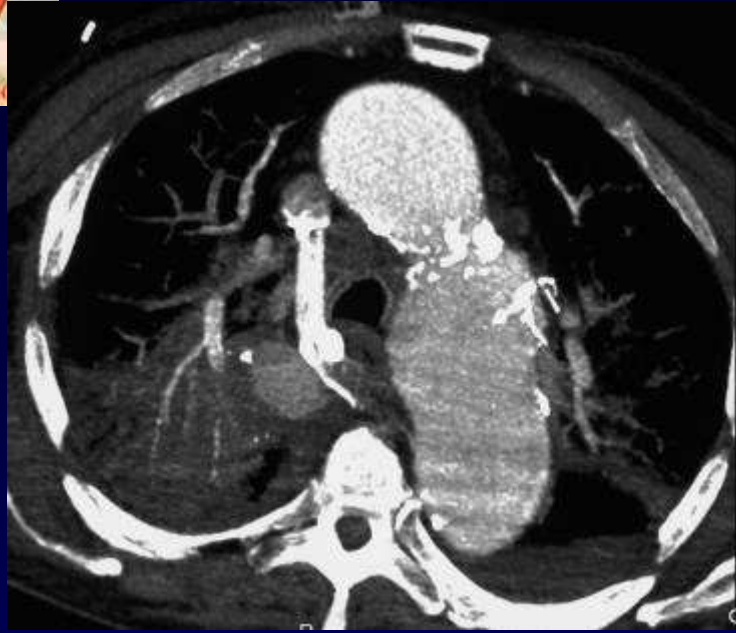


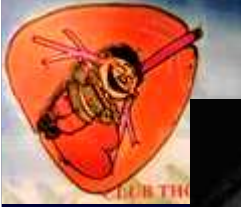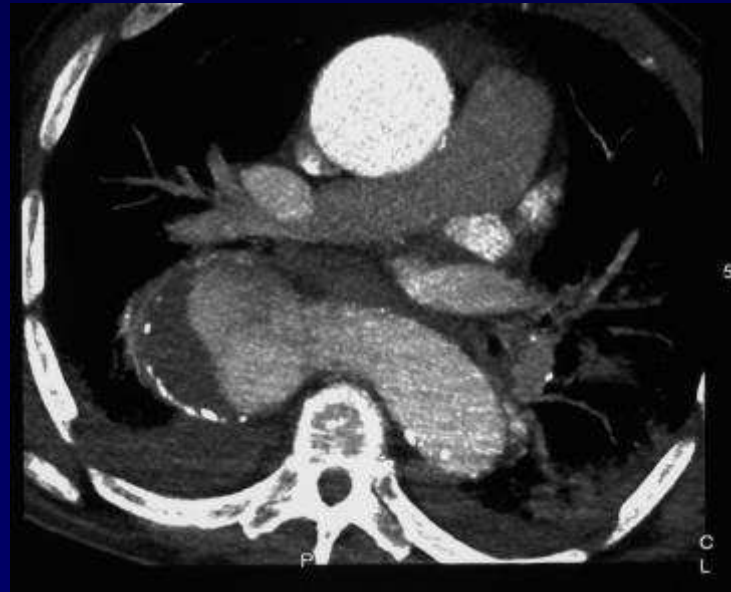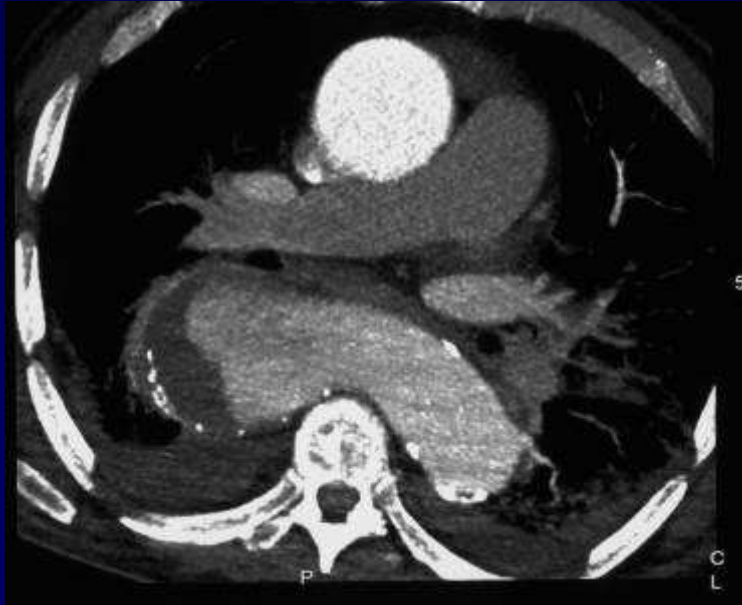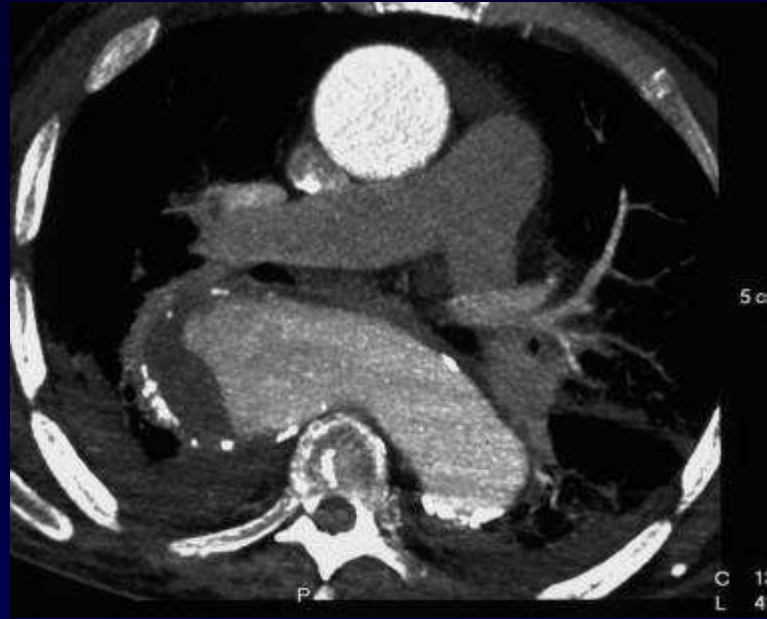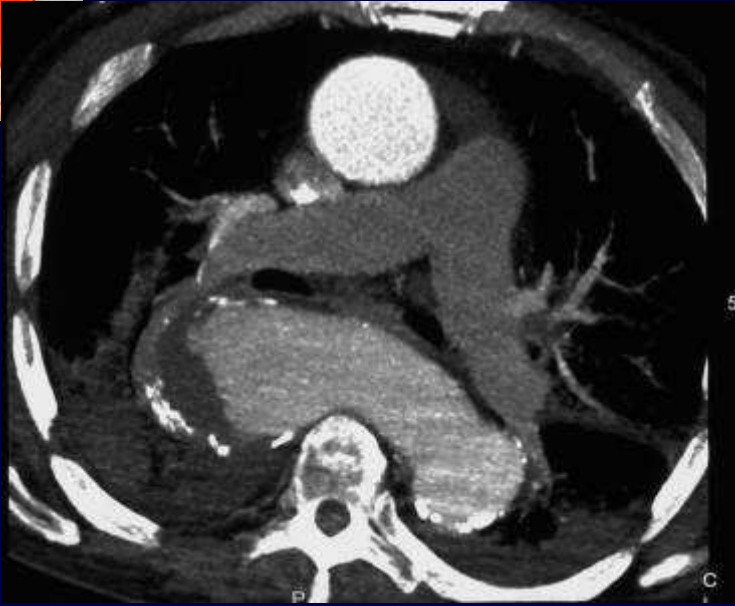


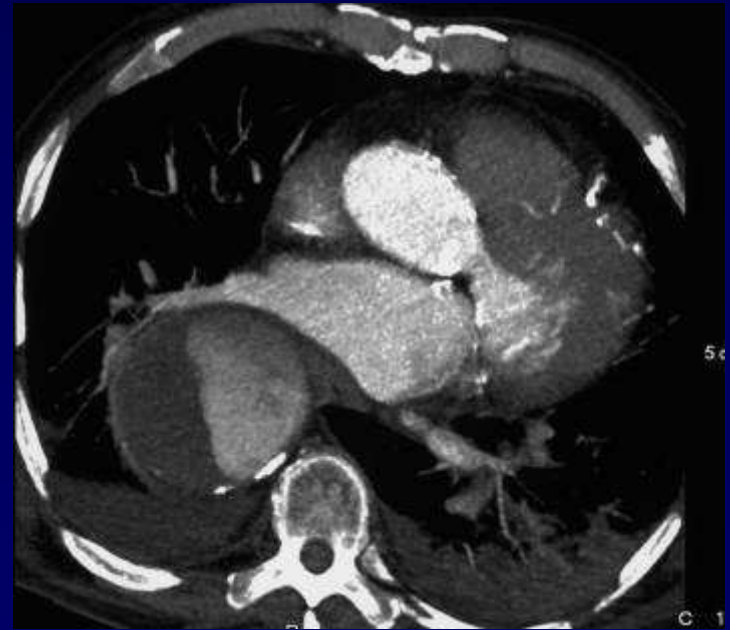
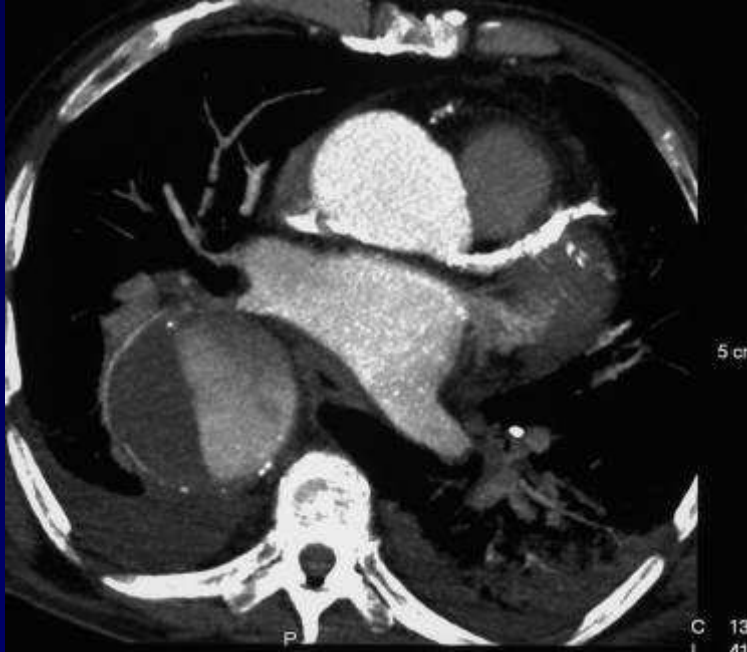
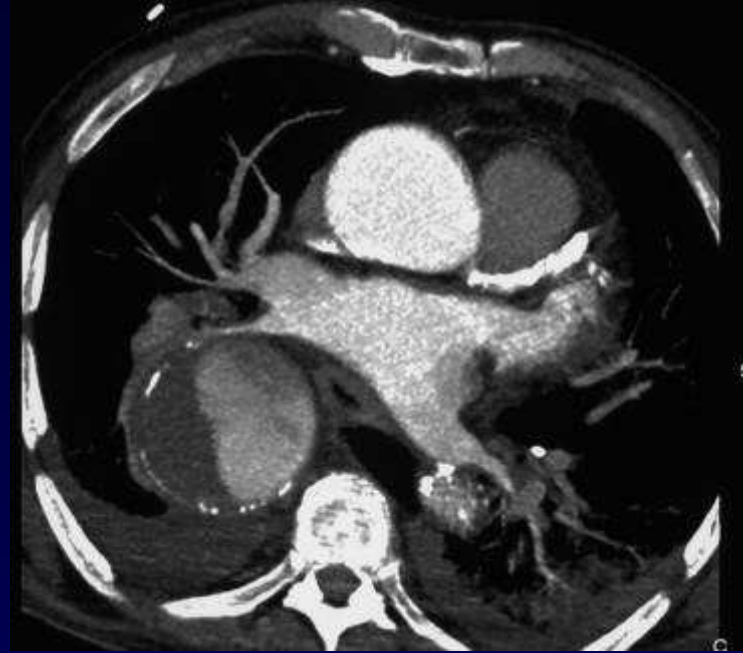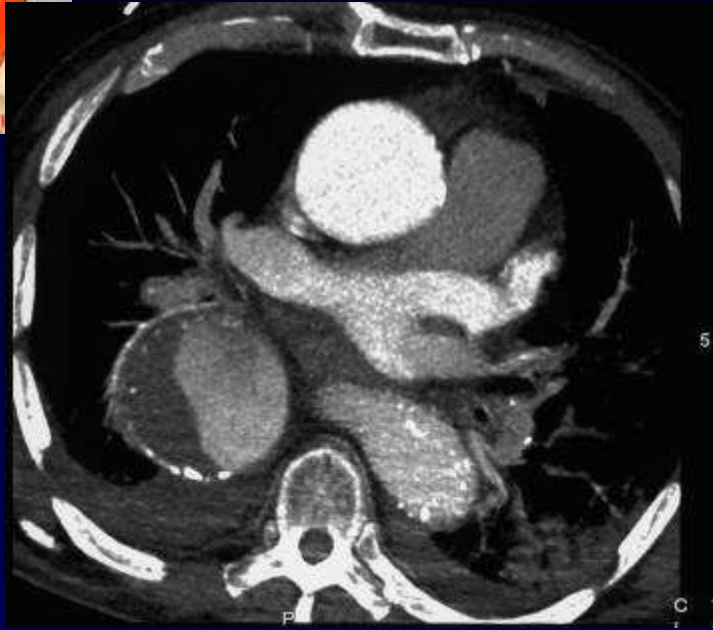
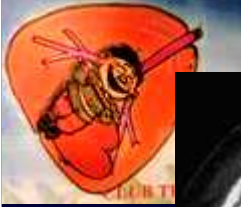Diagnostic ?

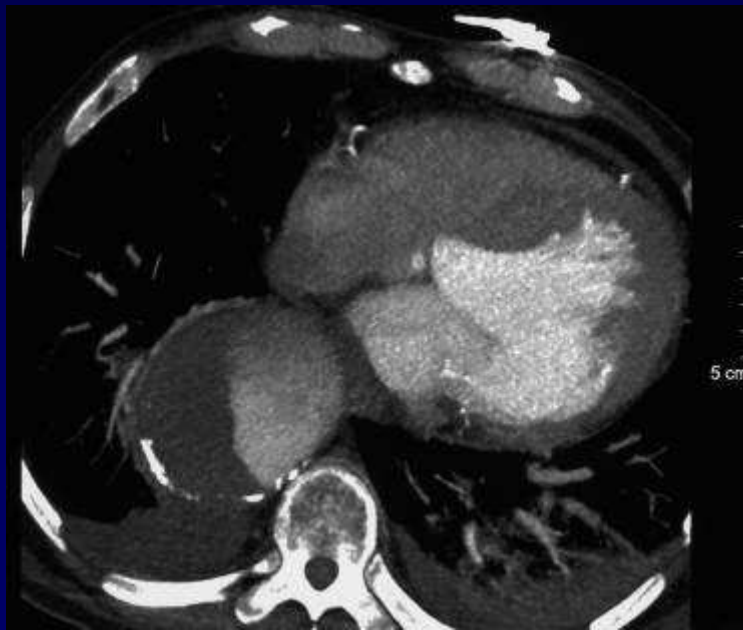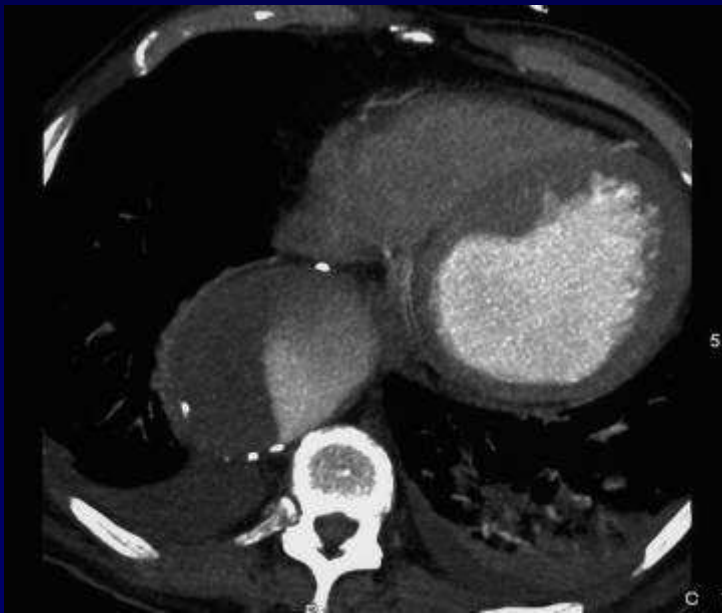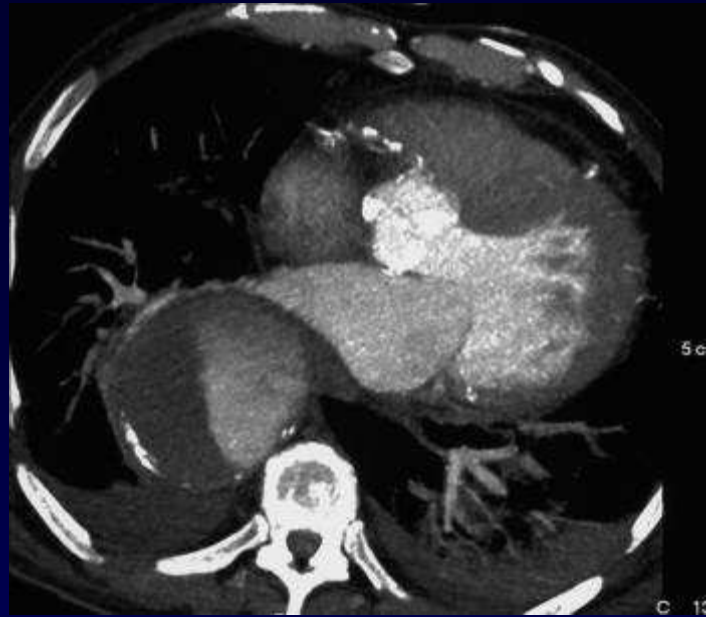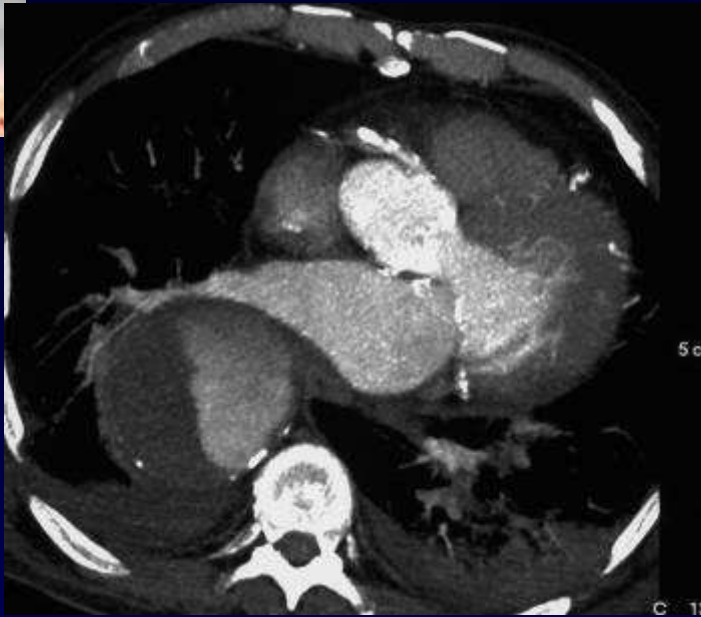





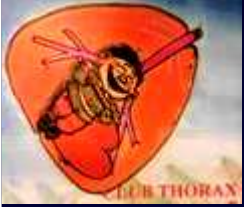








Diagnostic

Anévrisme de l'aorte thoracique



Evolution-Discussion-Point fort

Pas de visibilité de la zone d'hémoptysie
Anévrisme partiellement thrombosé sur l'aorte descendante