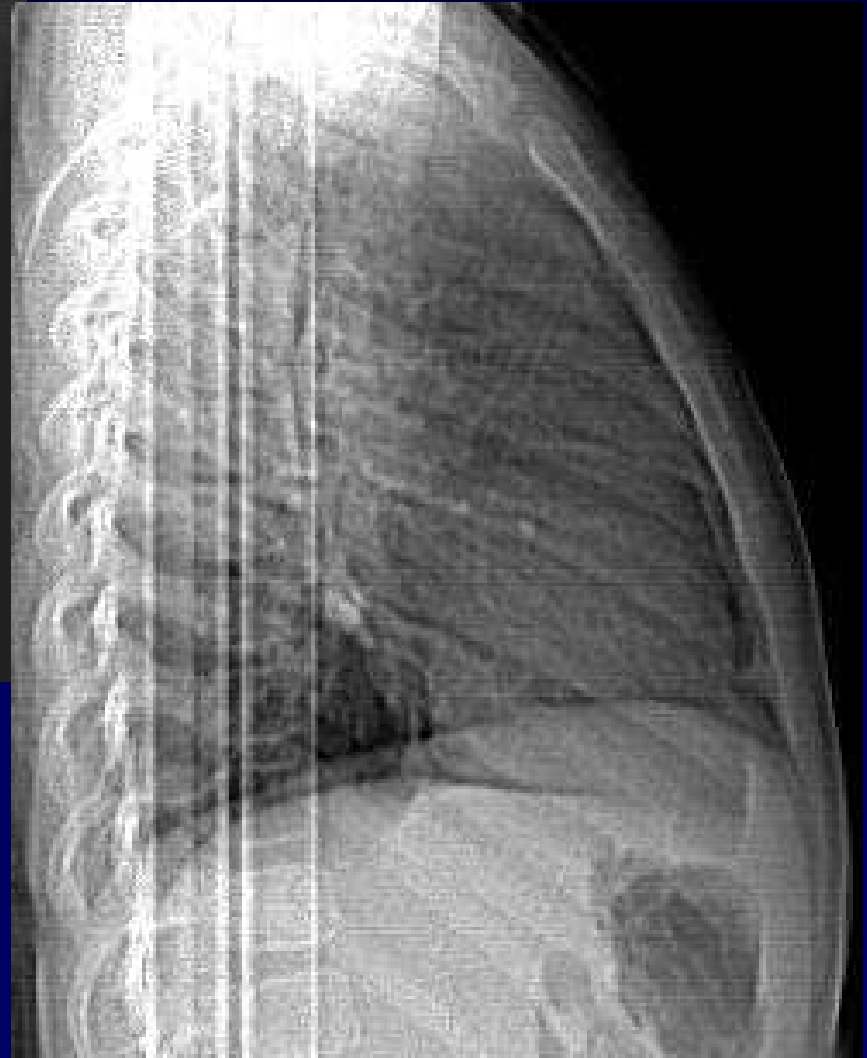
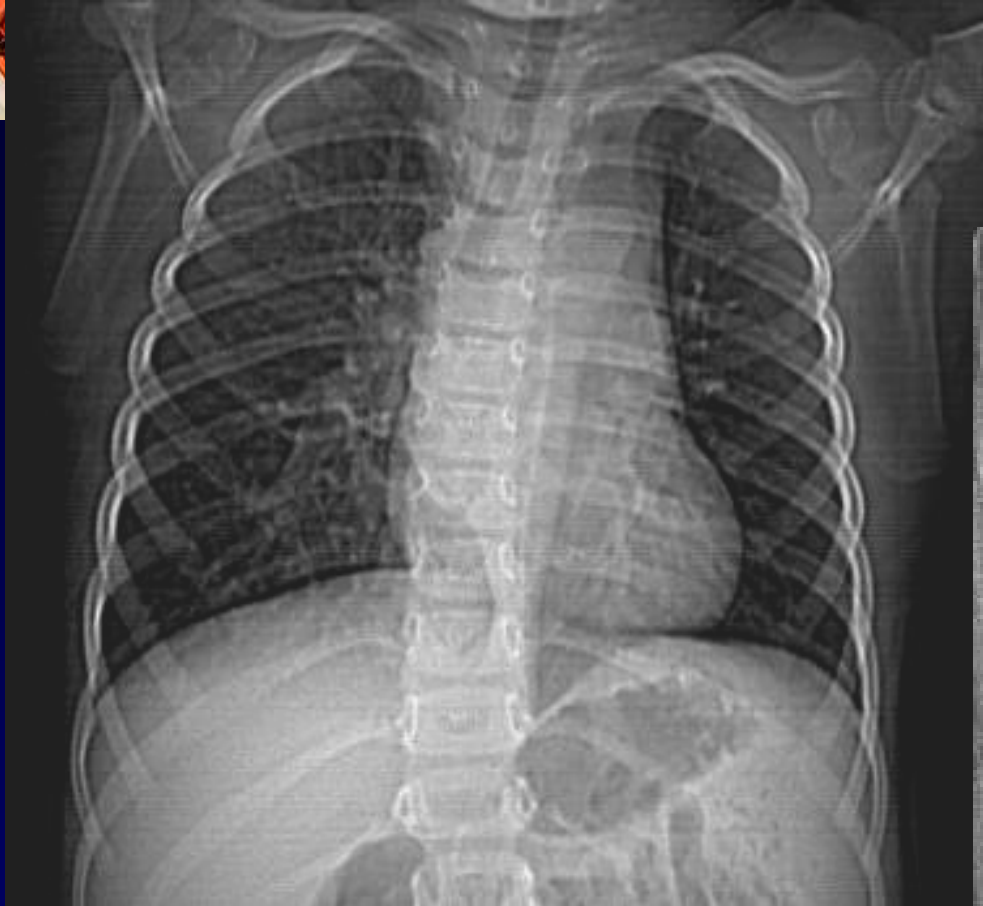
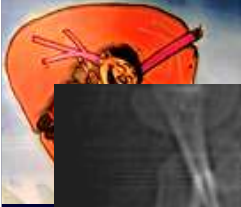
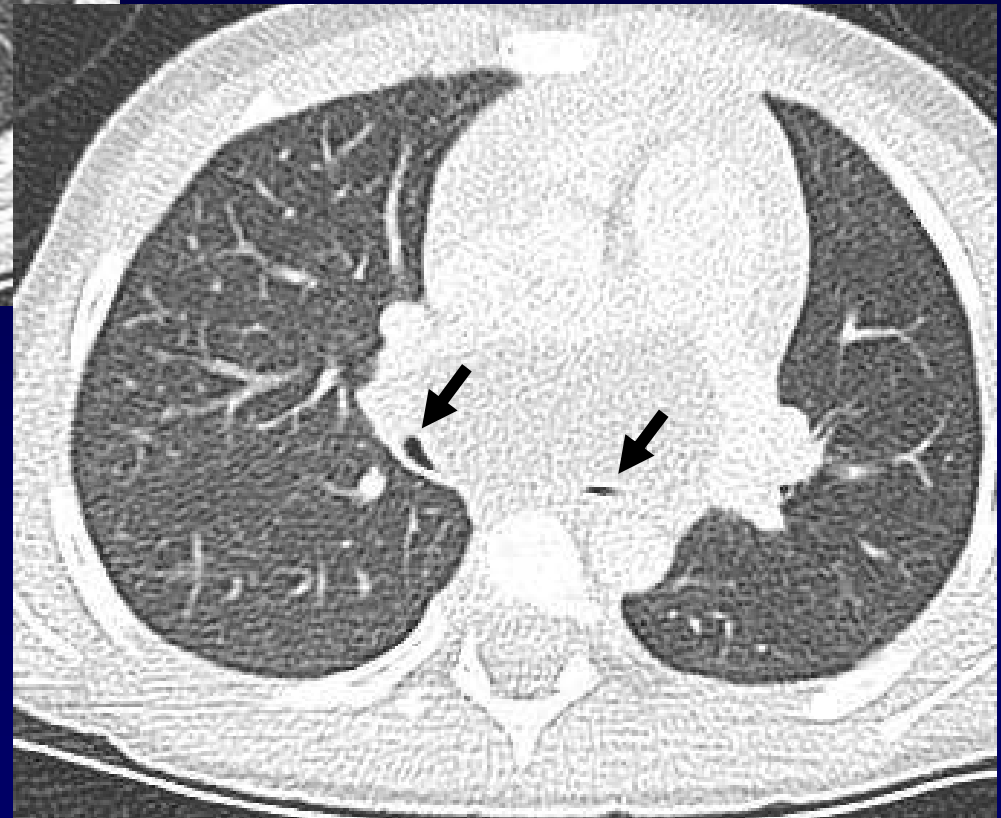
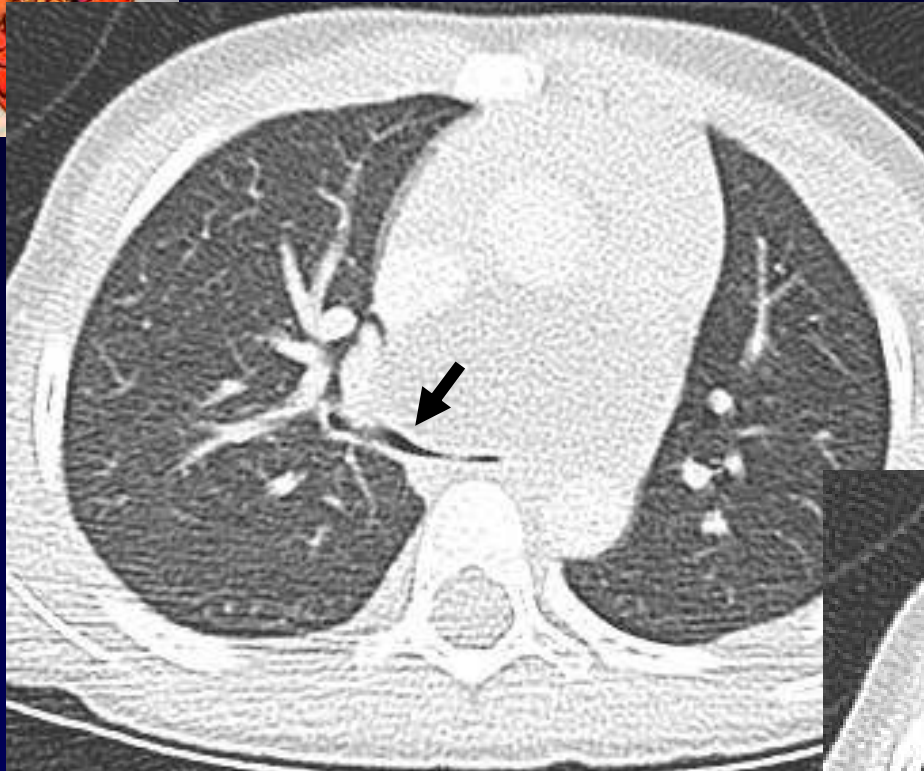



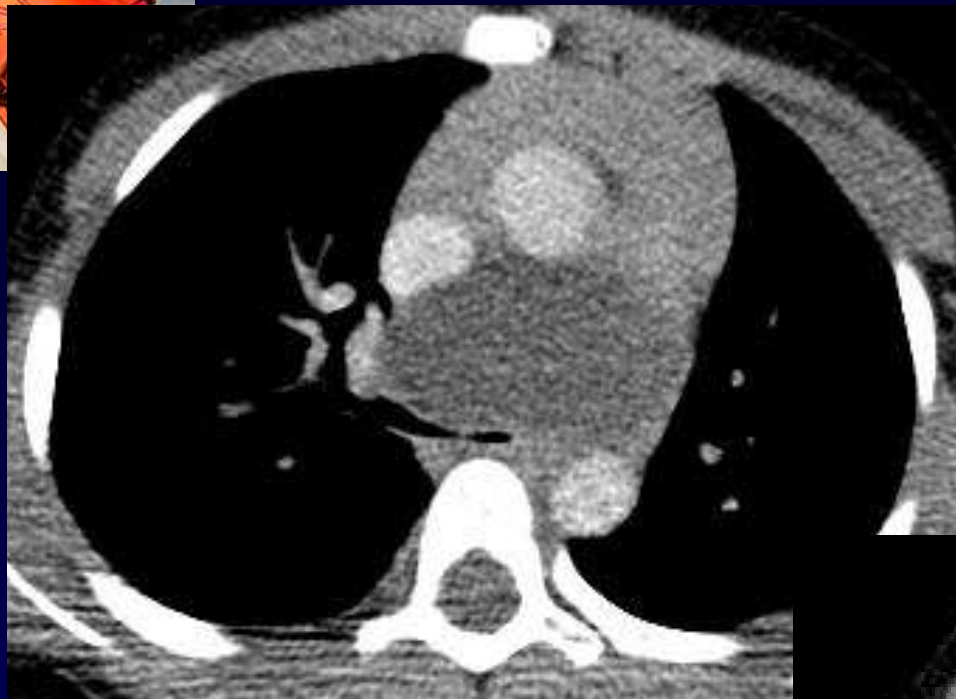
J.GIRON J.VIAL P.FAJADET

Fille de 3 ans

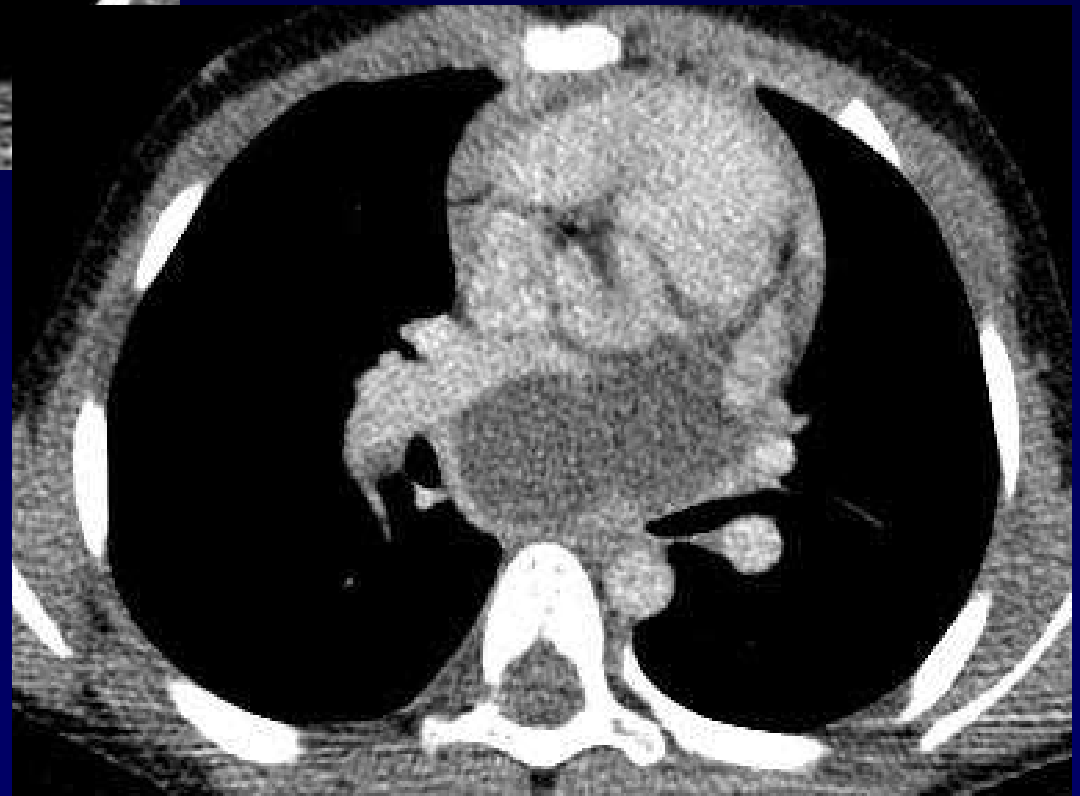Pneumopathies à répétition et à bascule

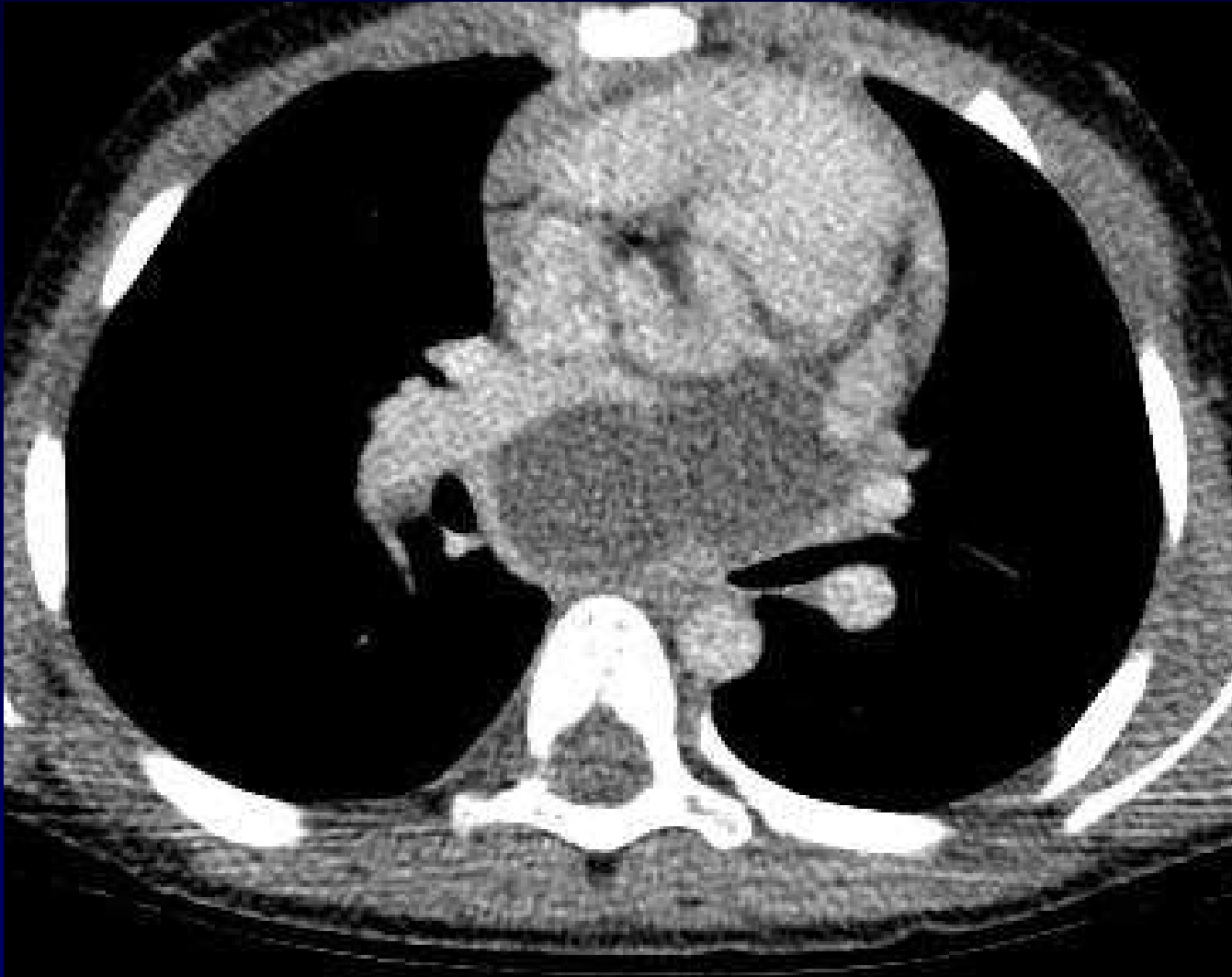





**Masse médiastinale
de 6 cm**





Densité : 40 UH



Diagnostic ?



Diagnostic

KYSTE BRONCHOGENIQUE
pré et sous carinaire

Compression bi - bronchique