

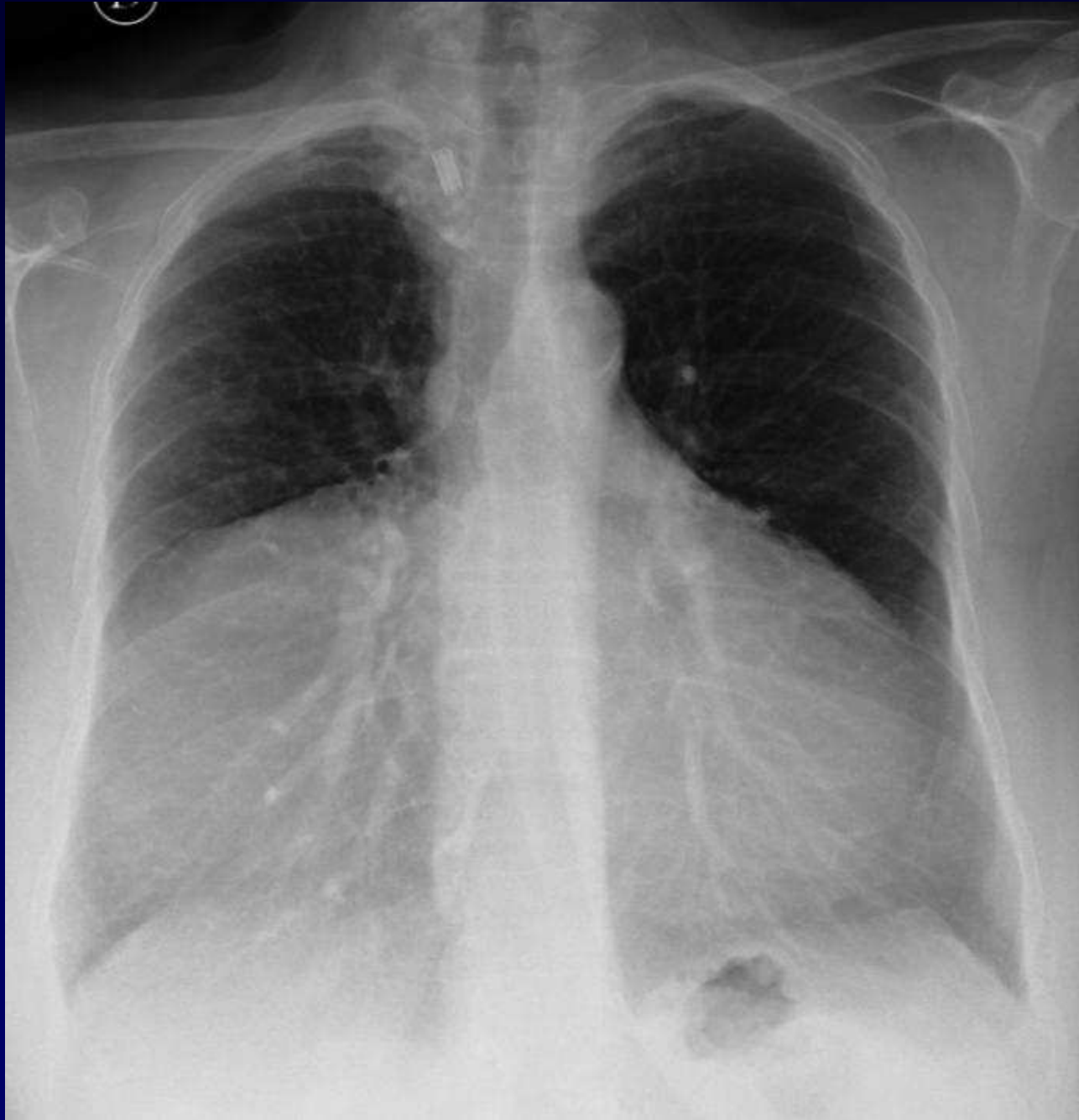
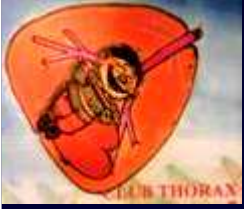
Dossier 2

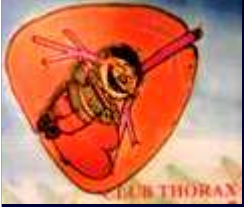A KHALIL

MF CARETTE

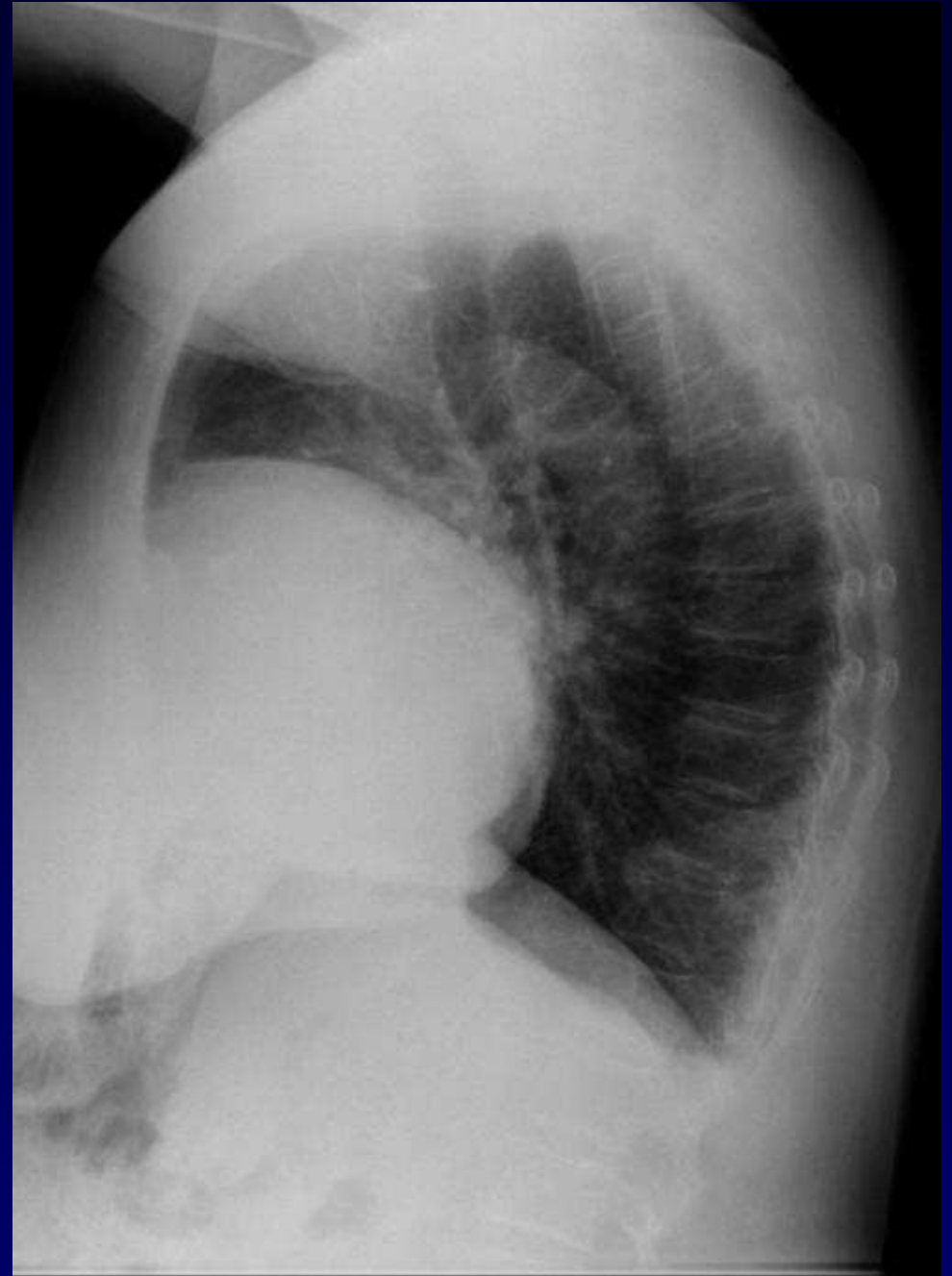
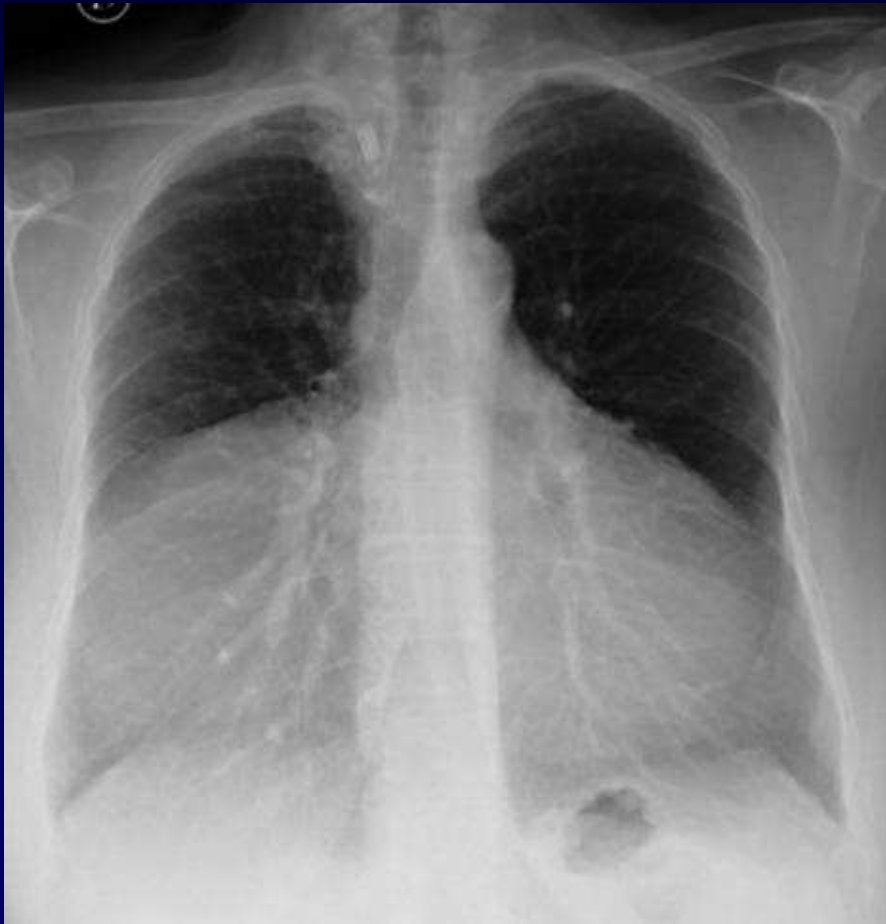Femme de 72 ans

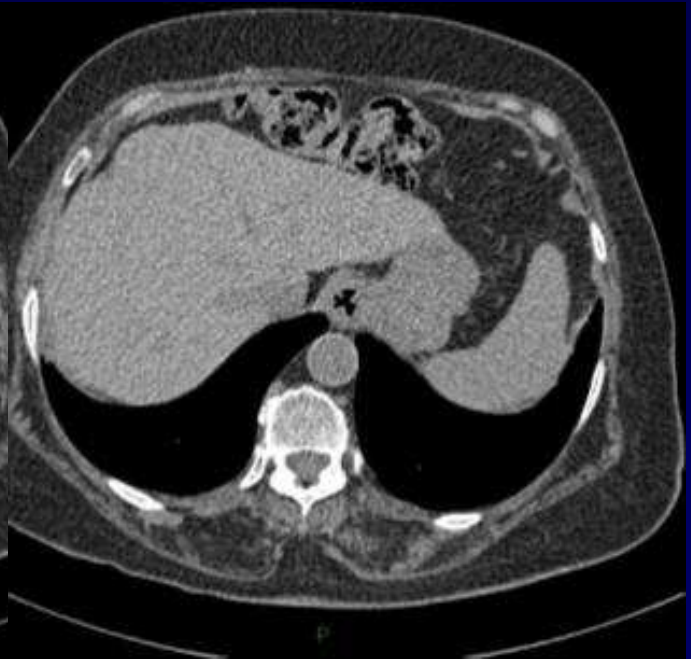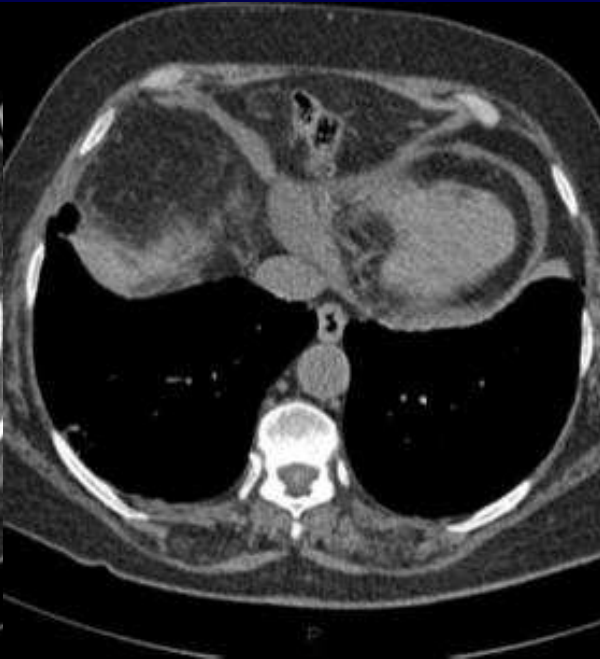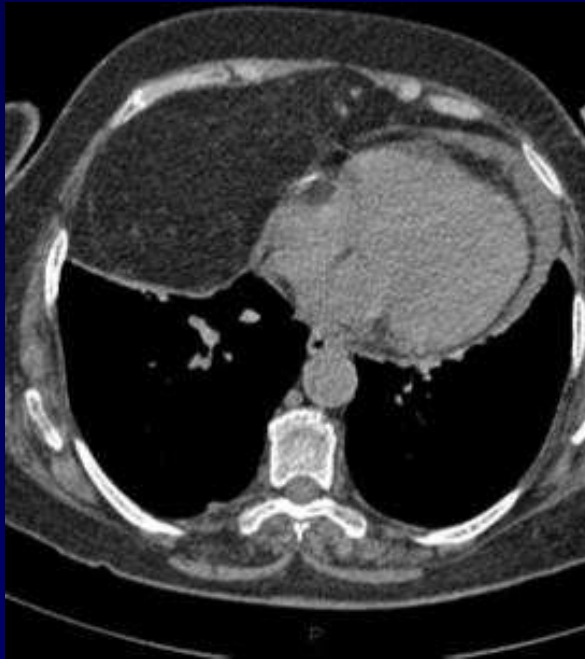
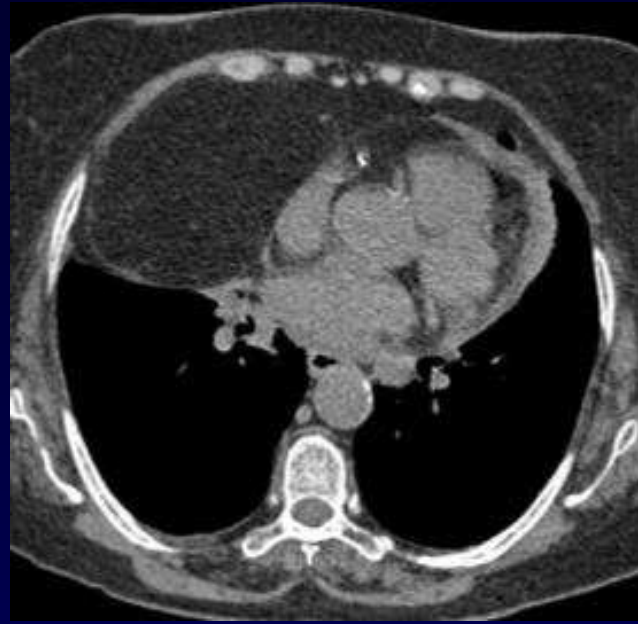
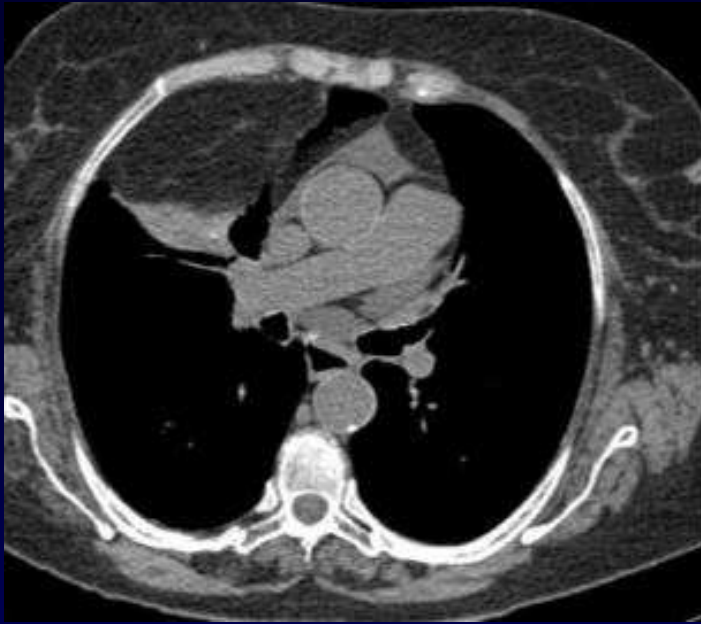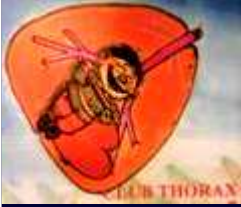Admise aux urgences pour malaise.

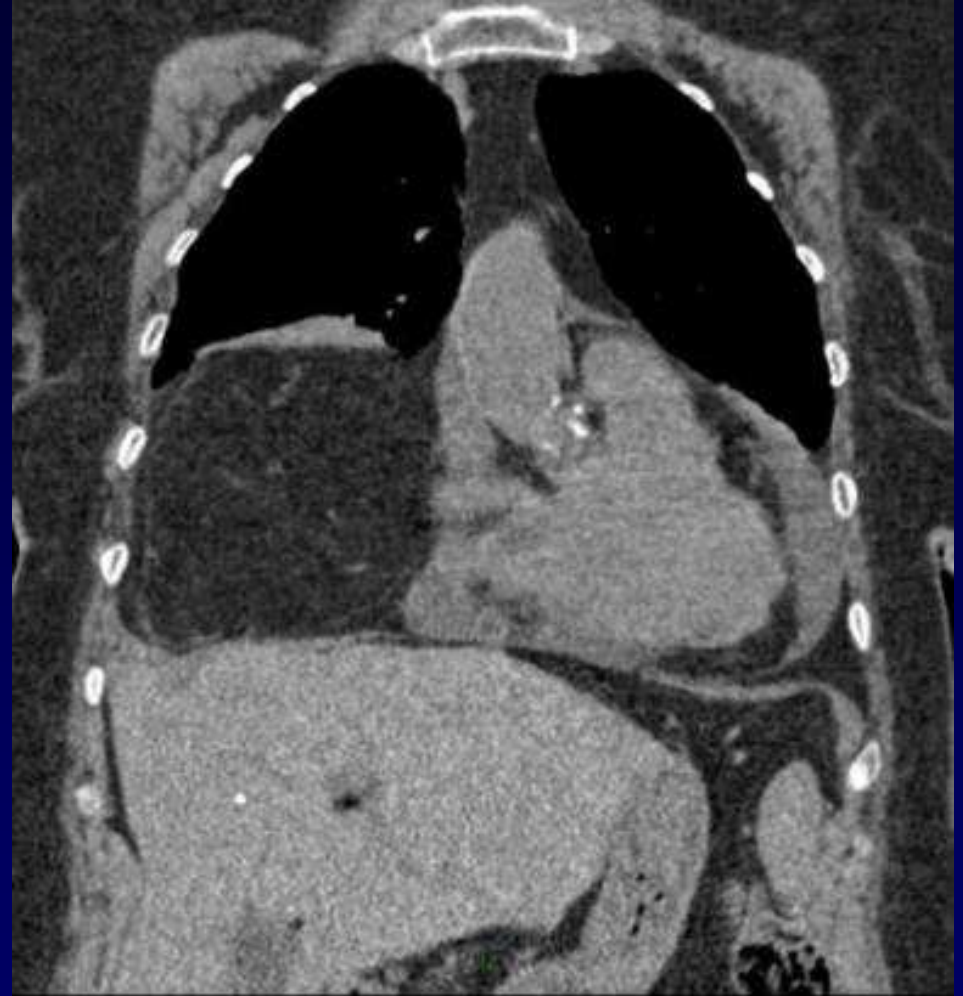
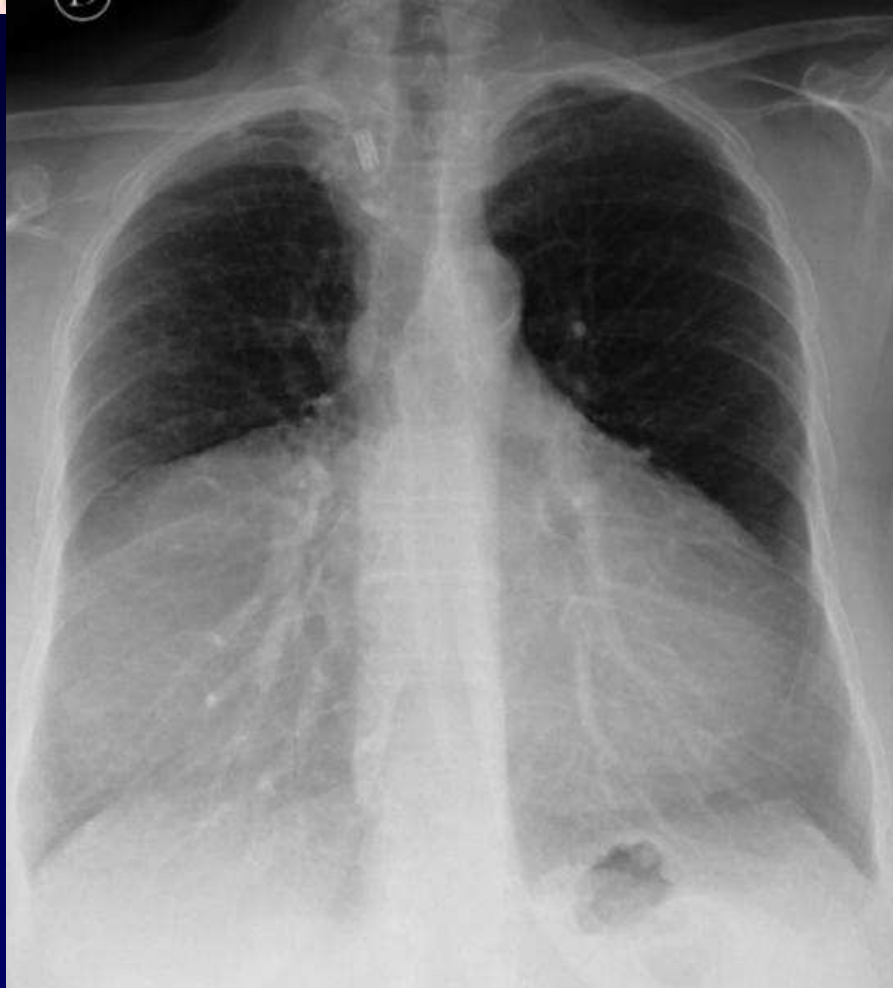
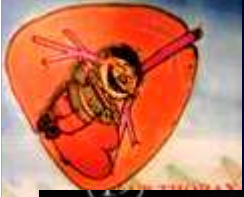
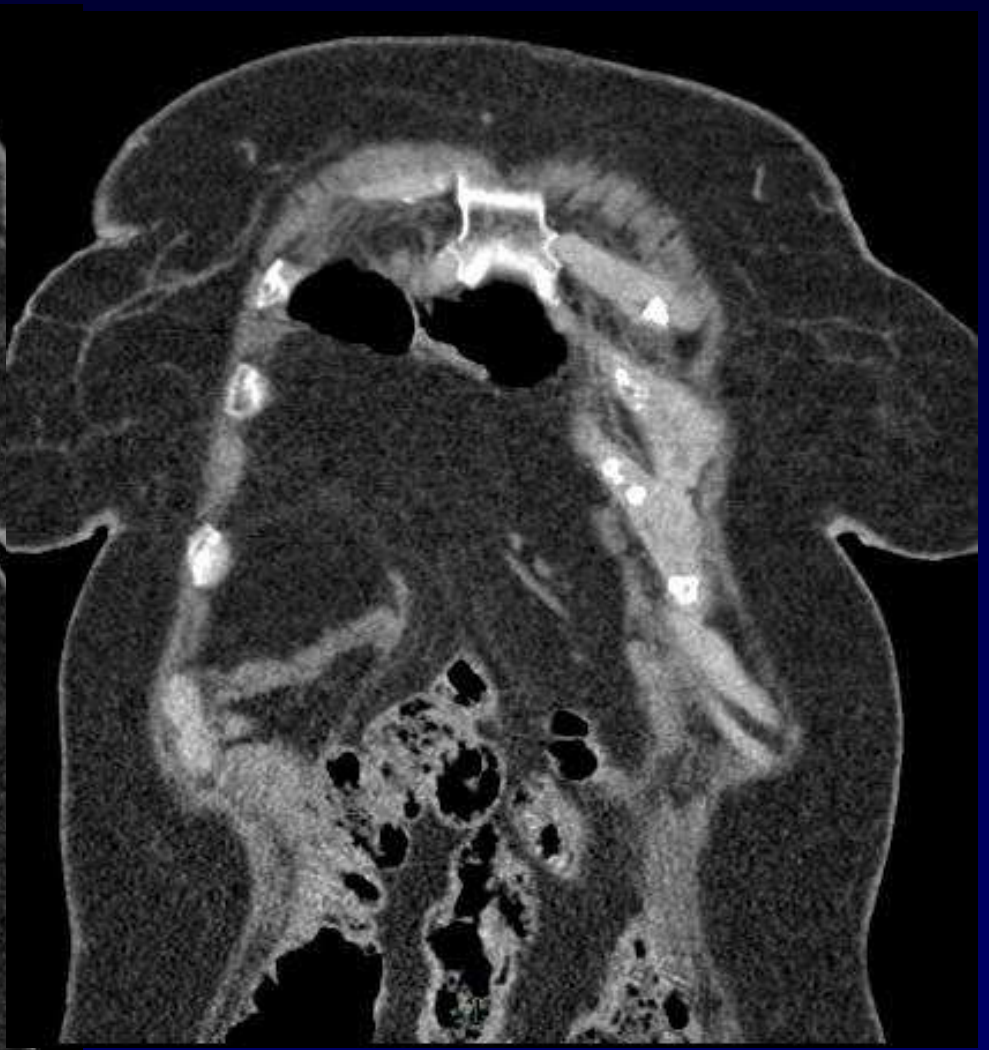
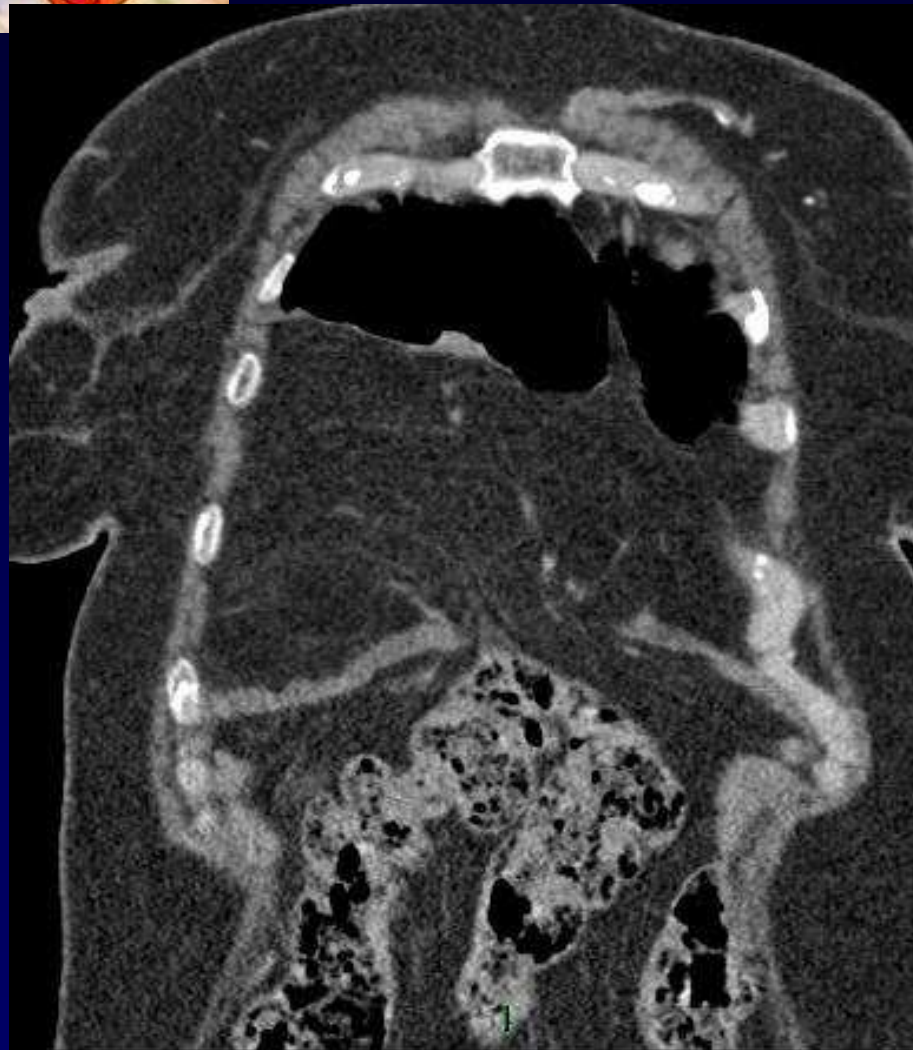


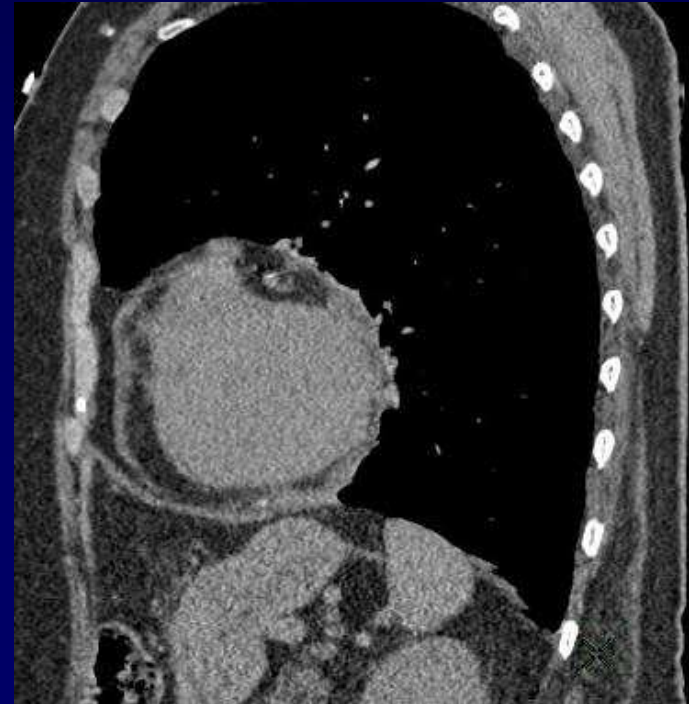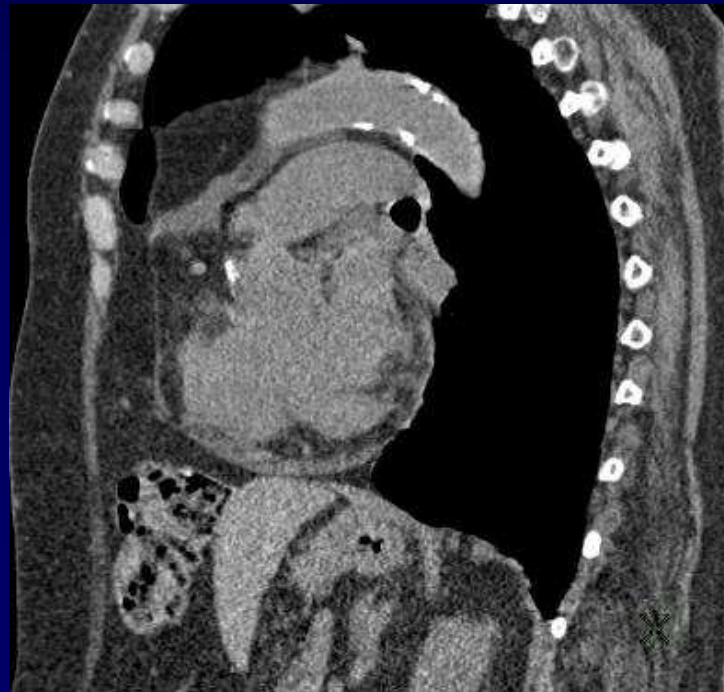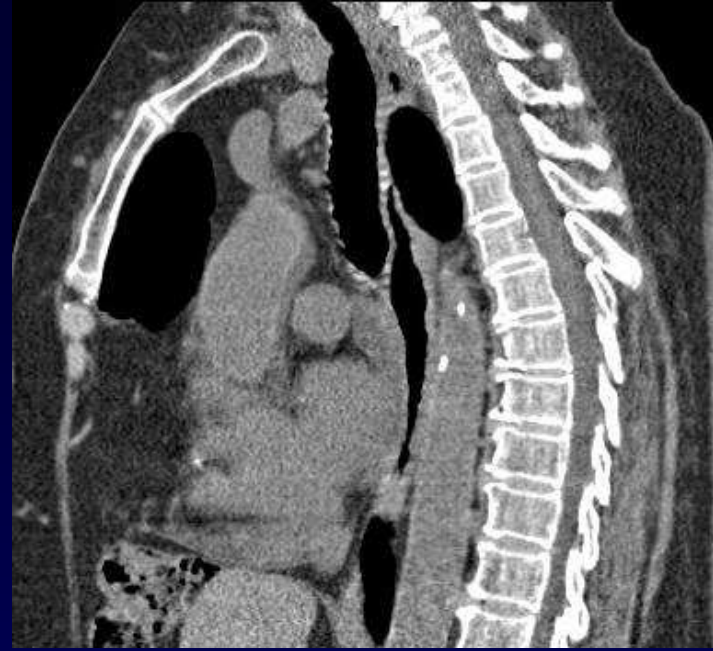
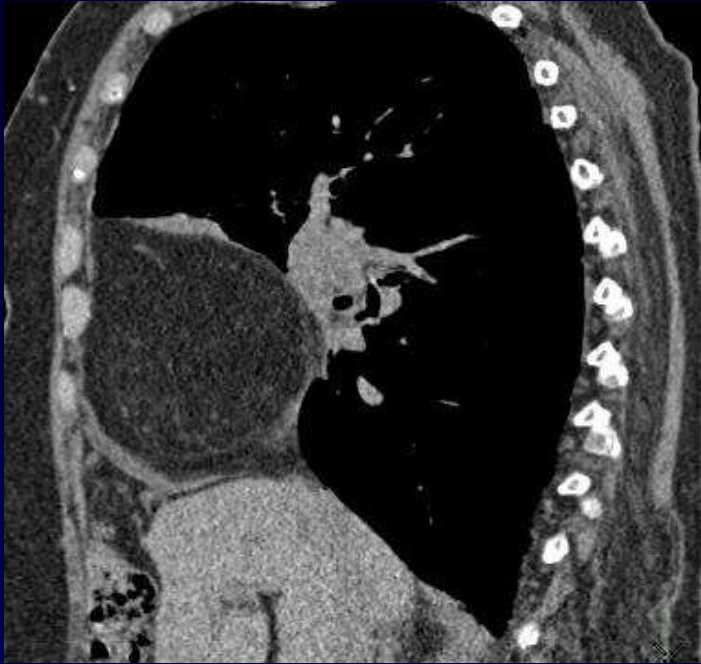Diagnostic ?

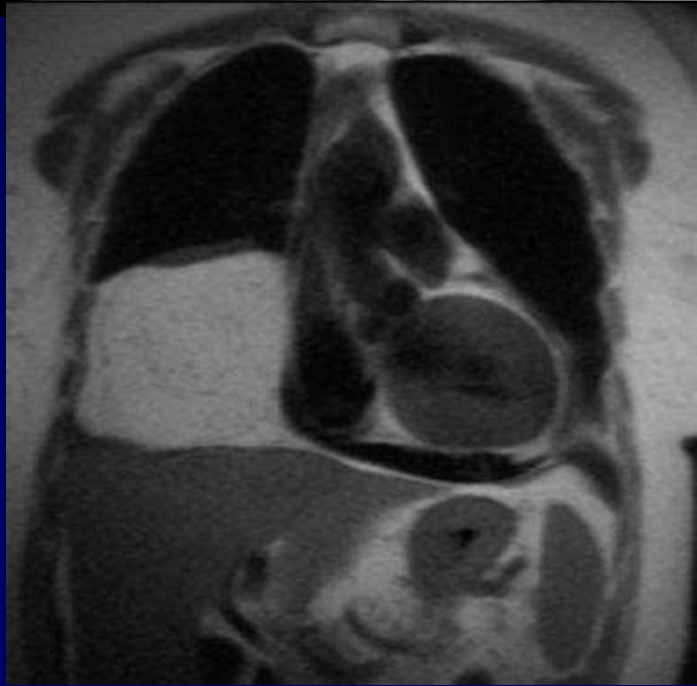
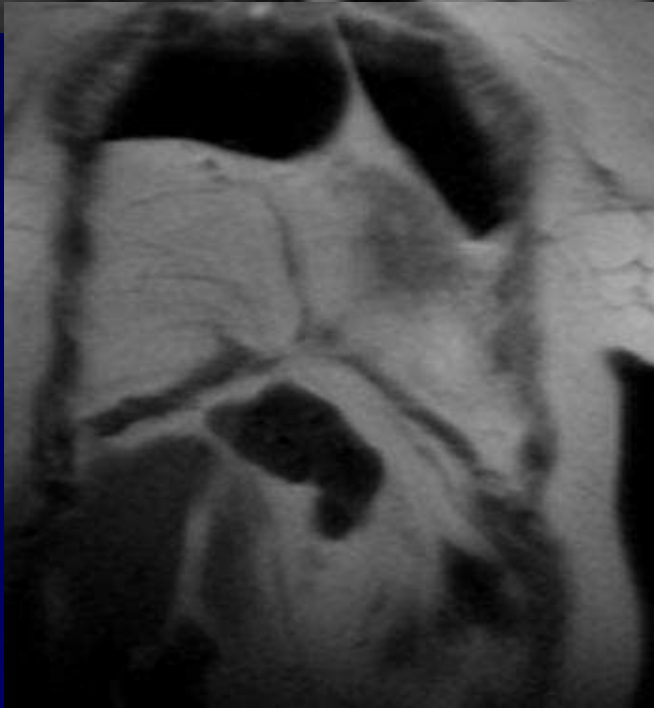
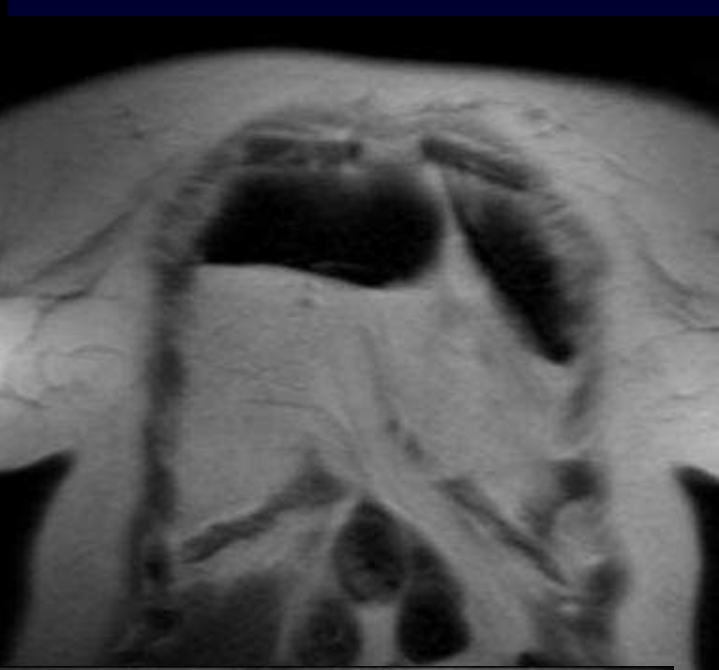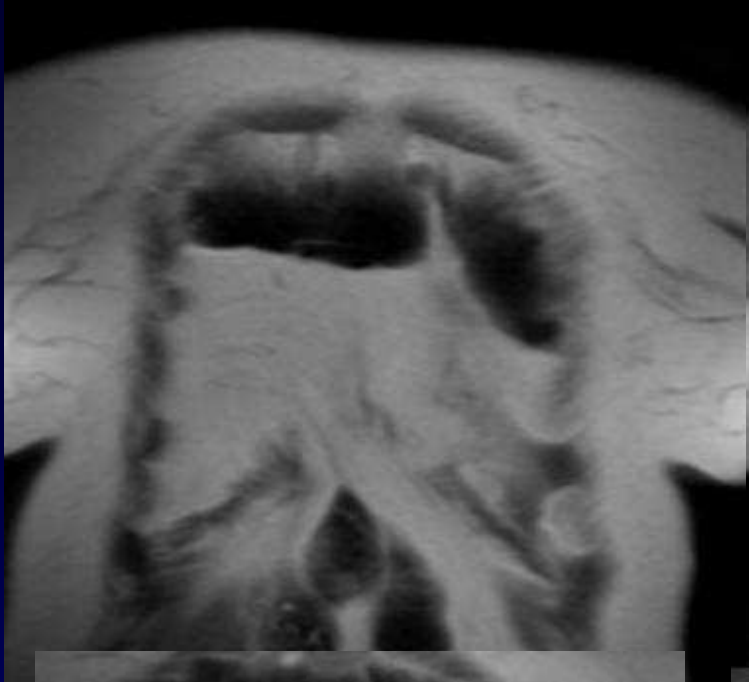














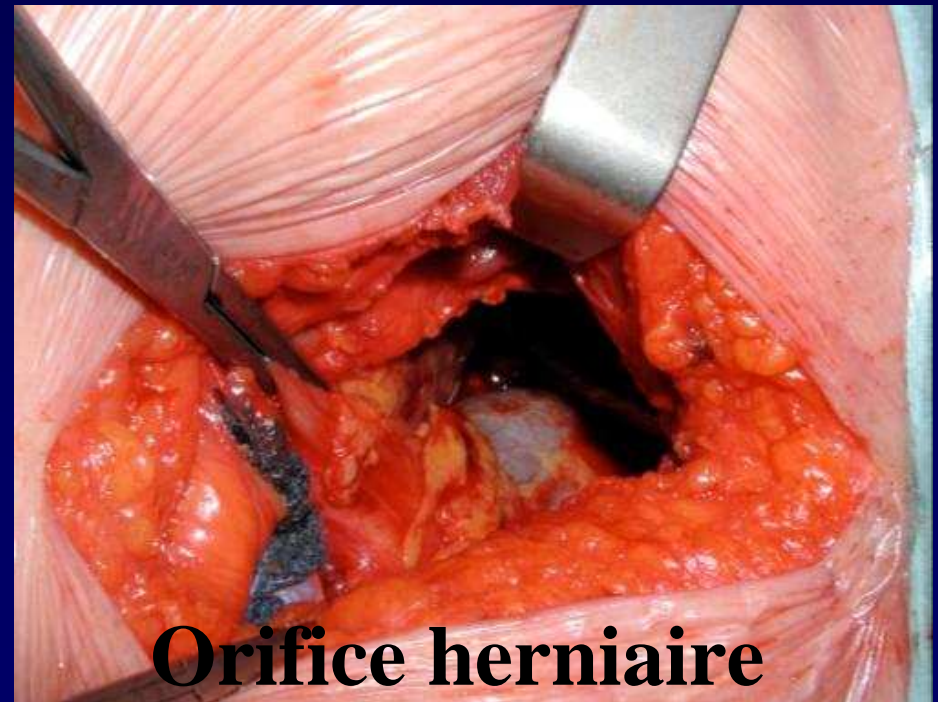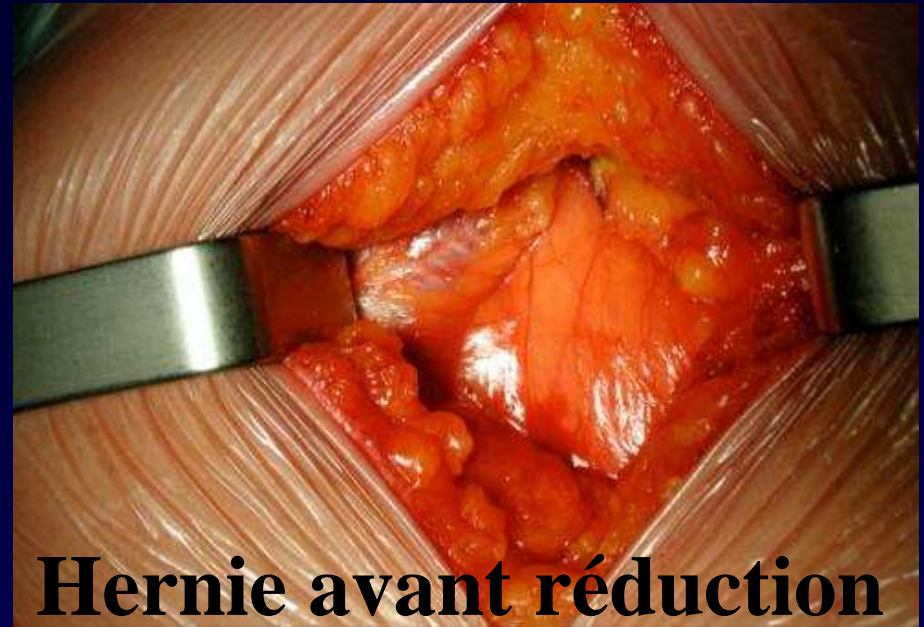
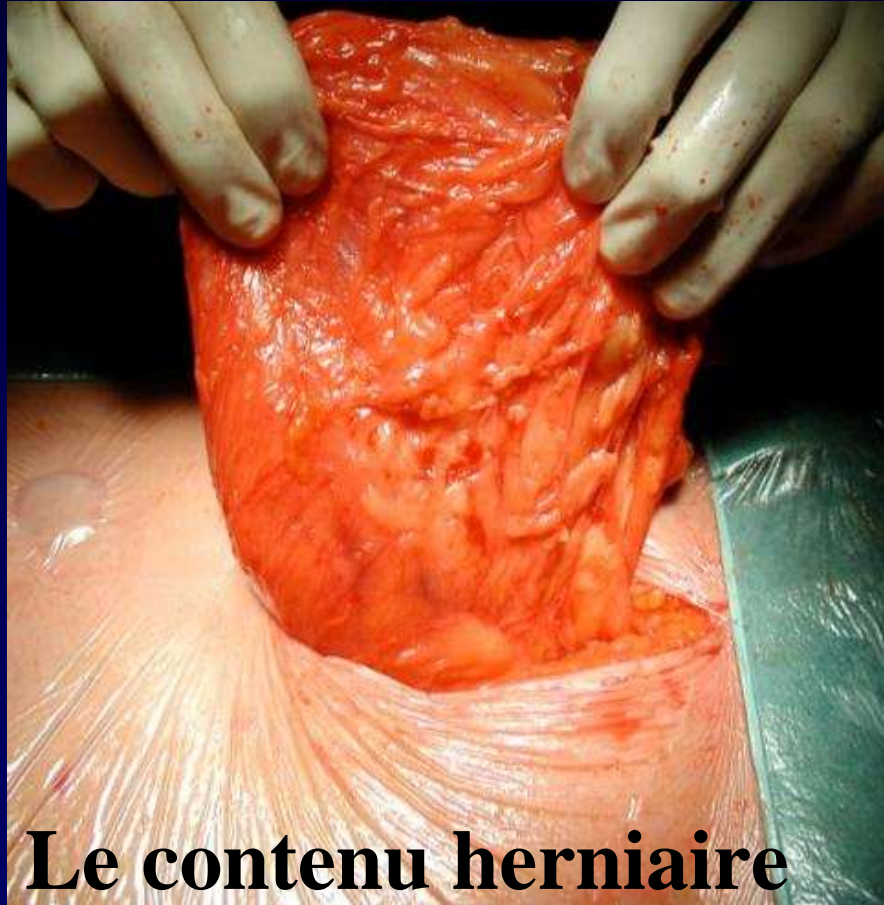Diagnostic

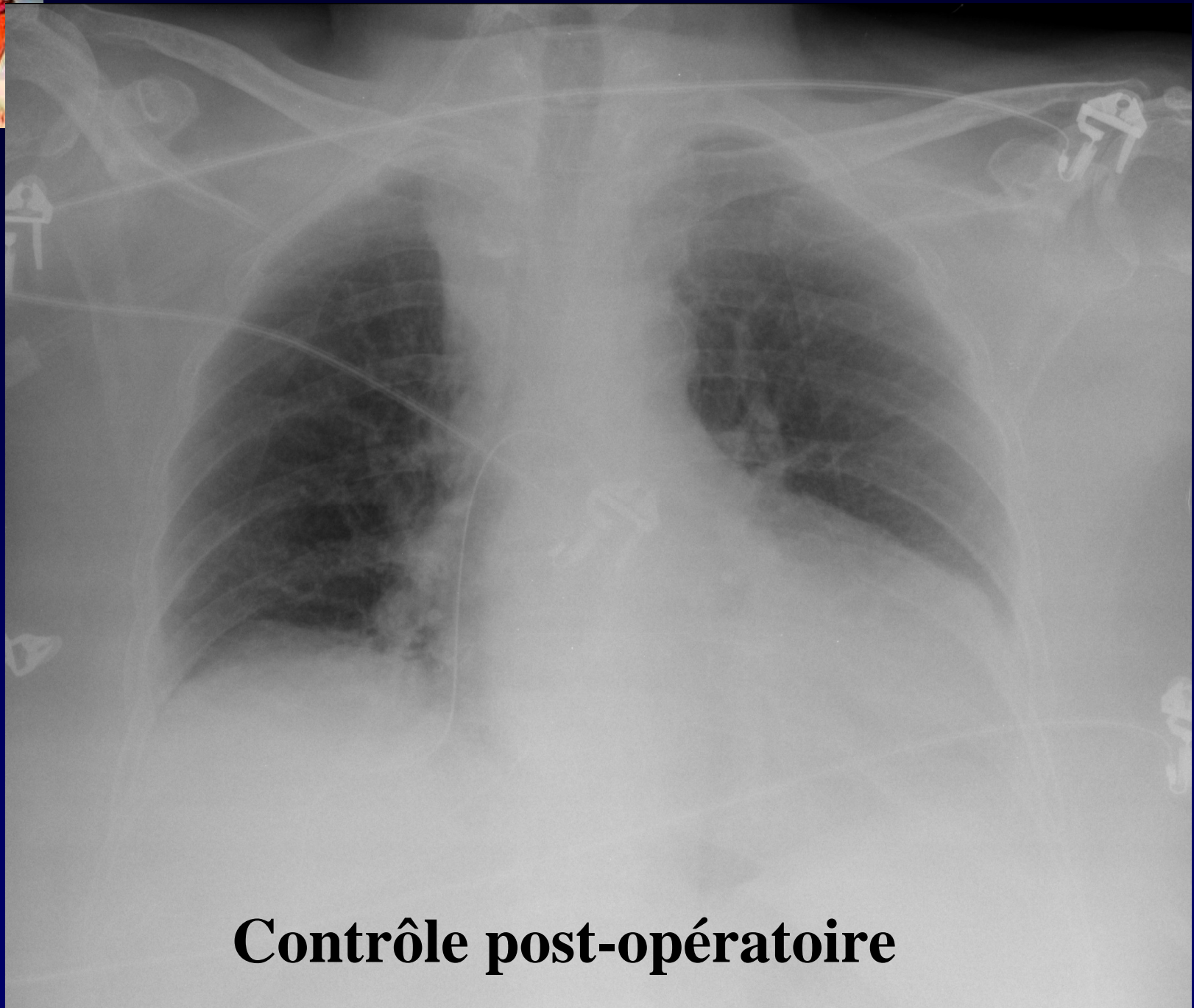
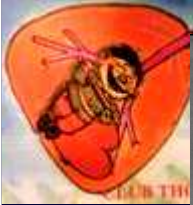**Hernie diaphragmatique
à travers la fente de Larrey**



Traitement

Réduction chirurgicale de la hernie





Contrôle post-opératoire