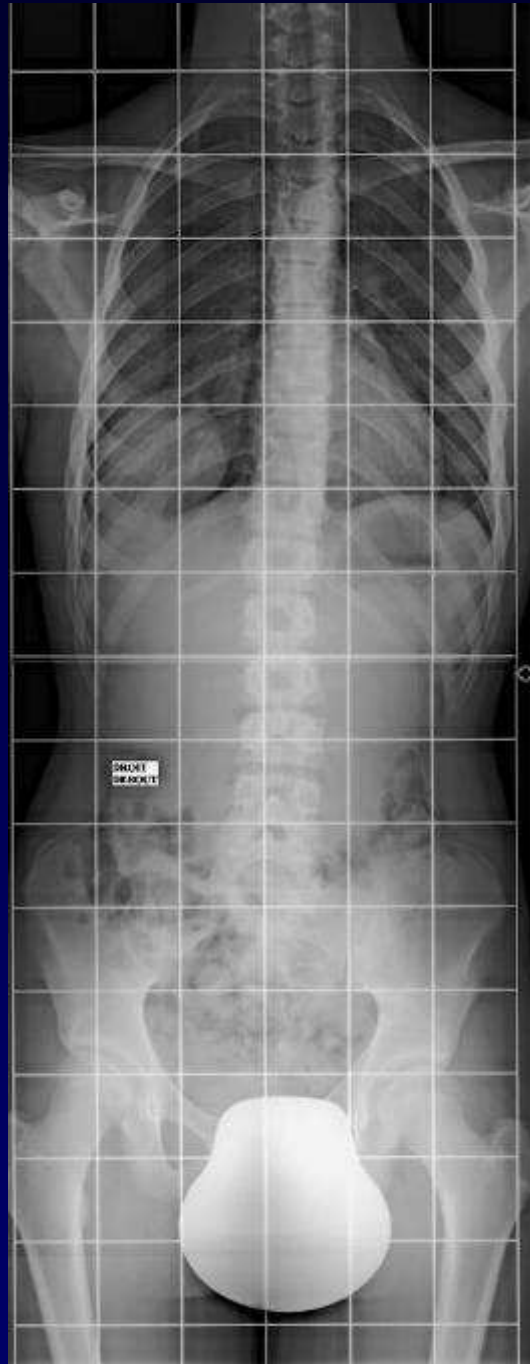


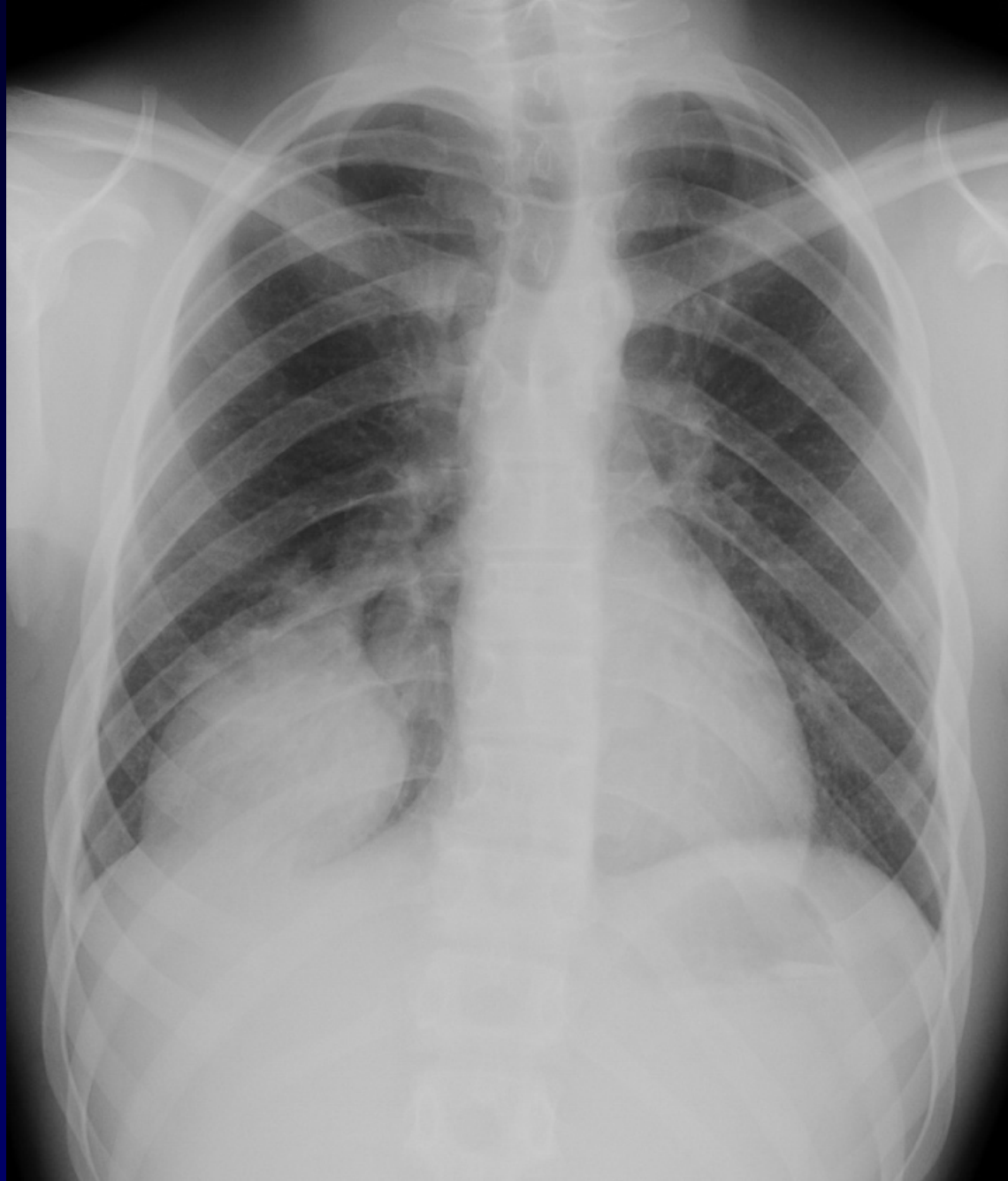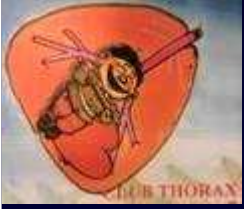Dossier 5

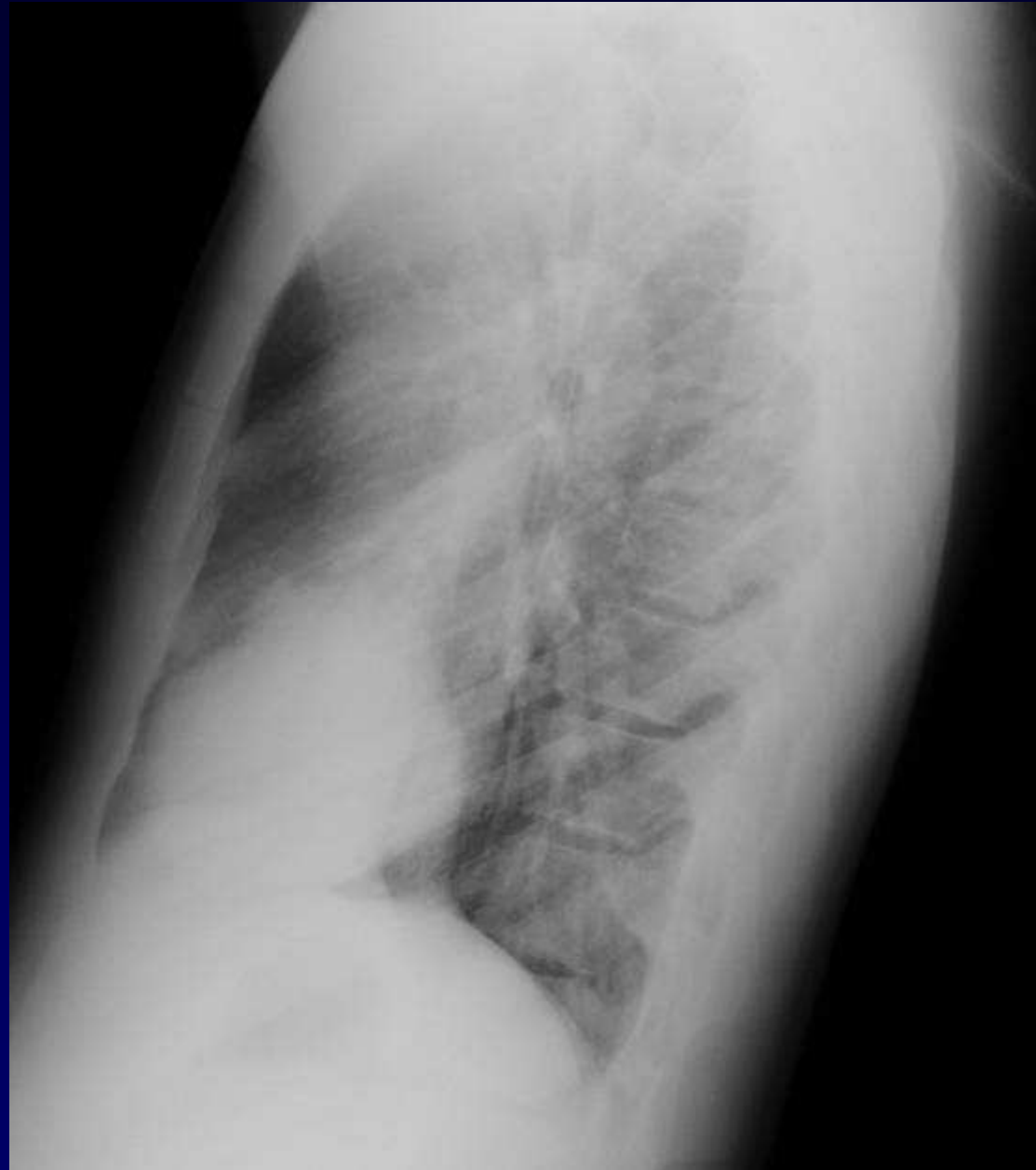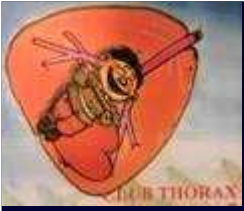Alexis LACOUT

Jeune homme de 17 ans

Bilan de scoliose

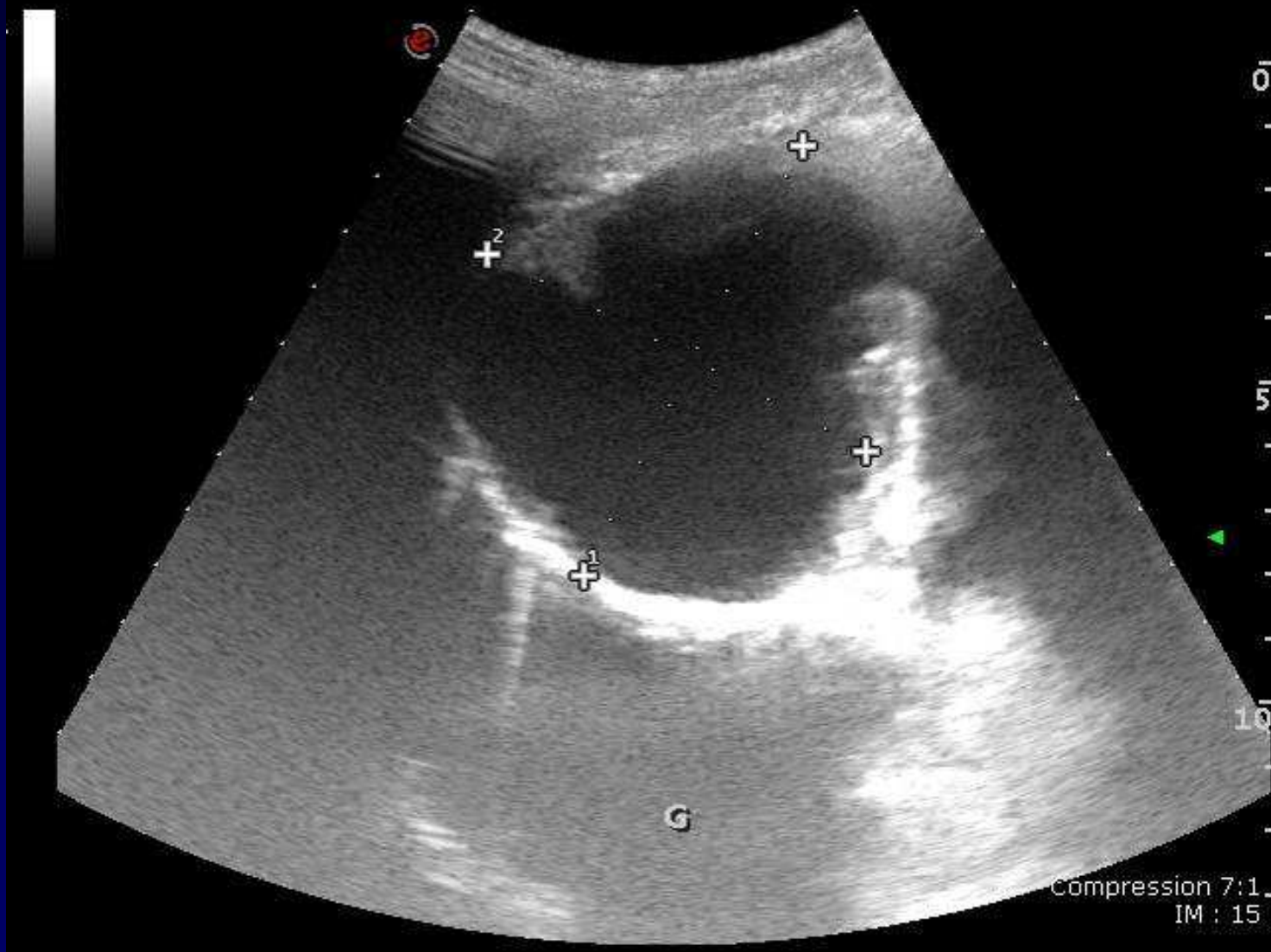




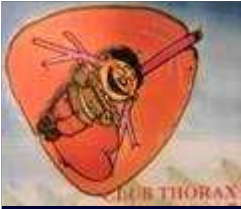



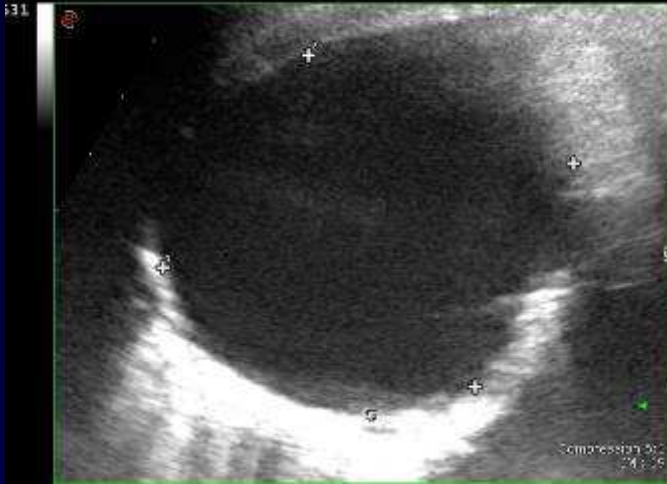
ES-M G ---
138mm XV C1
RC 12/0/1 PRS 6
ST 1 C 0



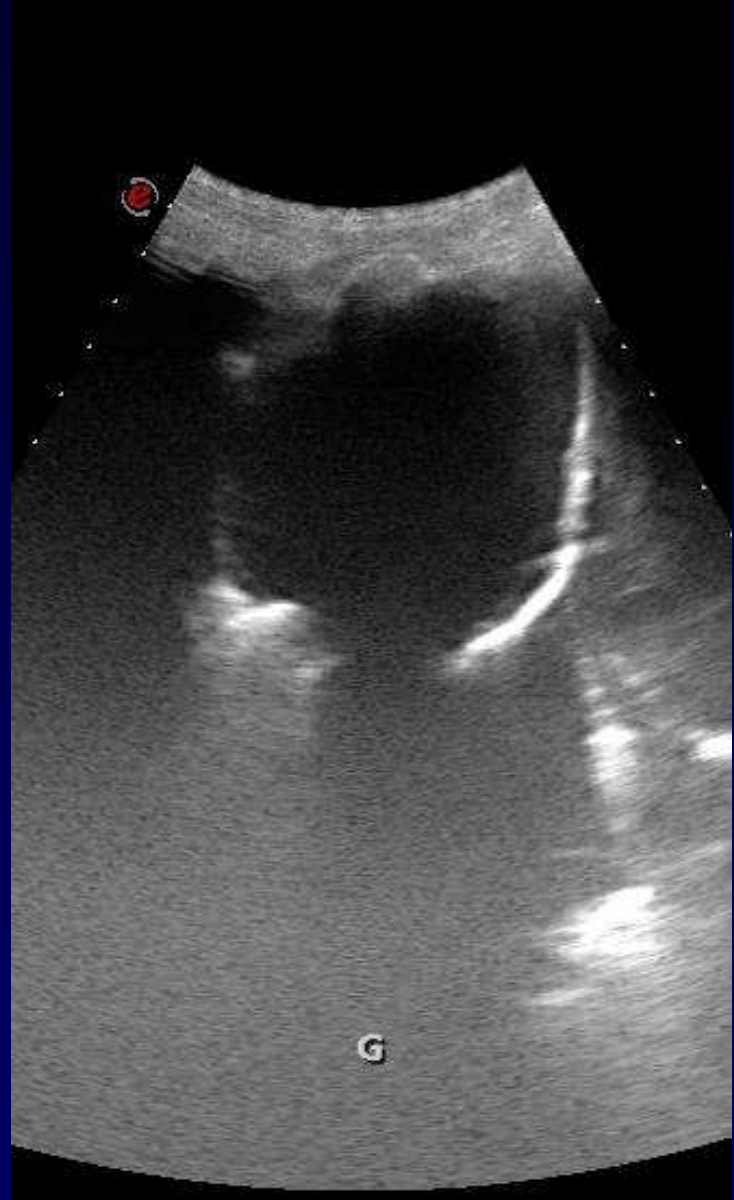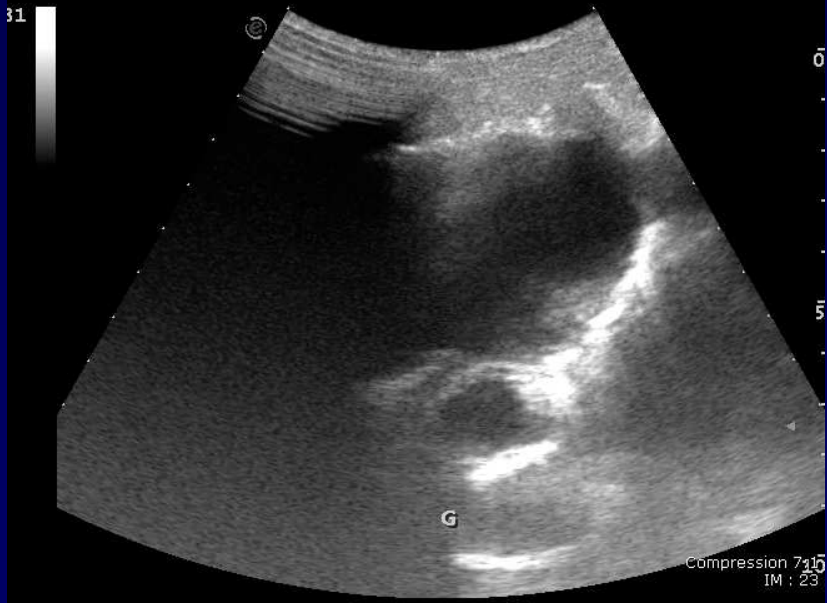
Compression 7:1
IM : 15



I RES-M G ---
P 108mm XV C1
PRC 12/0/1 PRS 6
PST 1 C 0

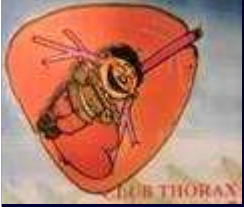

RES-M G ---
P 108mm XV C1
PRC 12/0/1 PRS 6
PST 1 C 0



Finally, the patient has exertional dyspnea

And right-sided thoracic pain

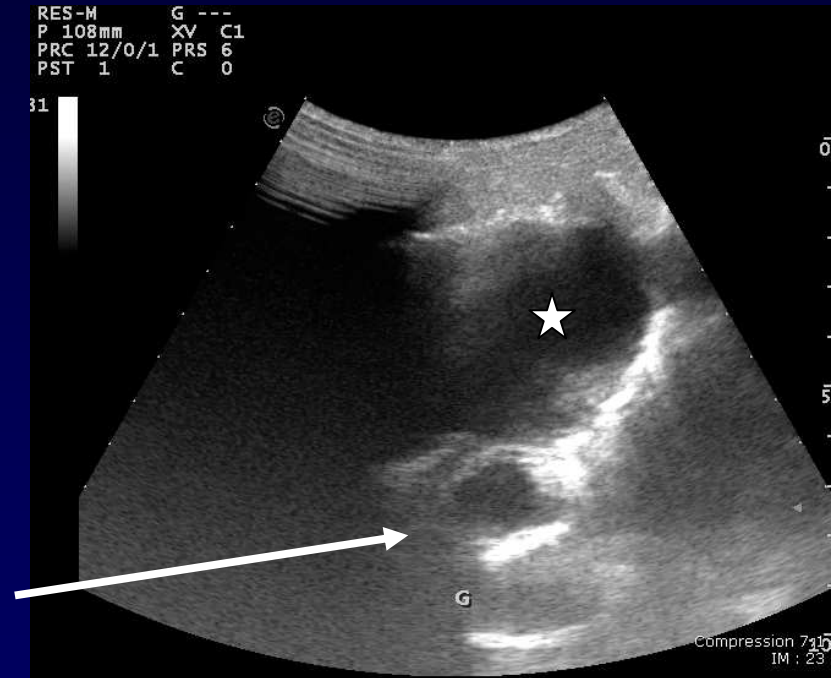
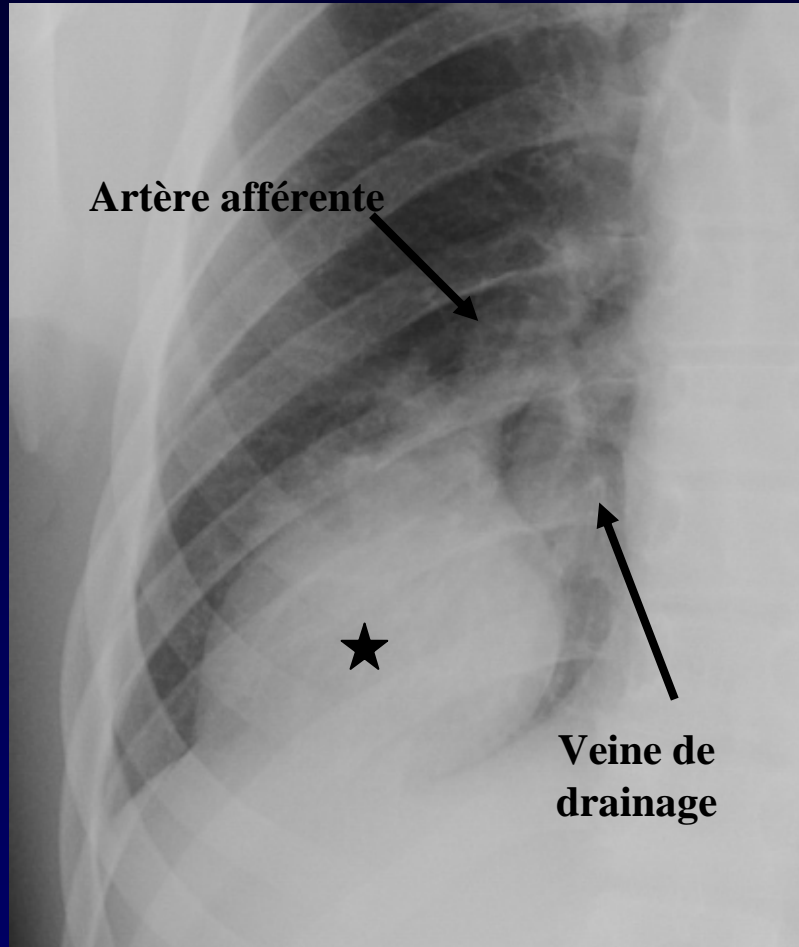
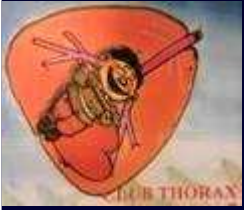


Diagnostic ?

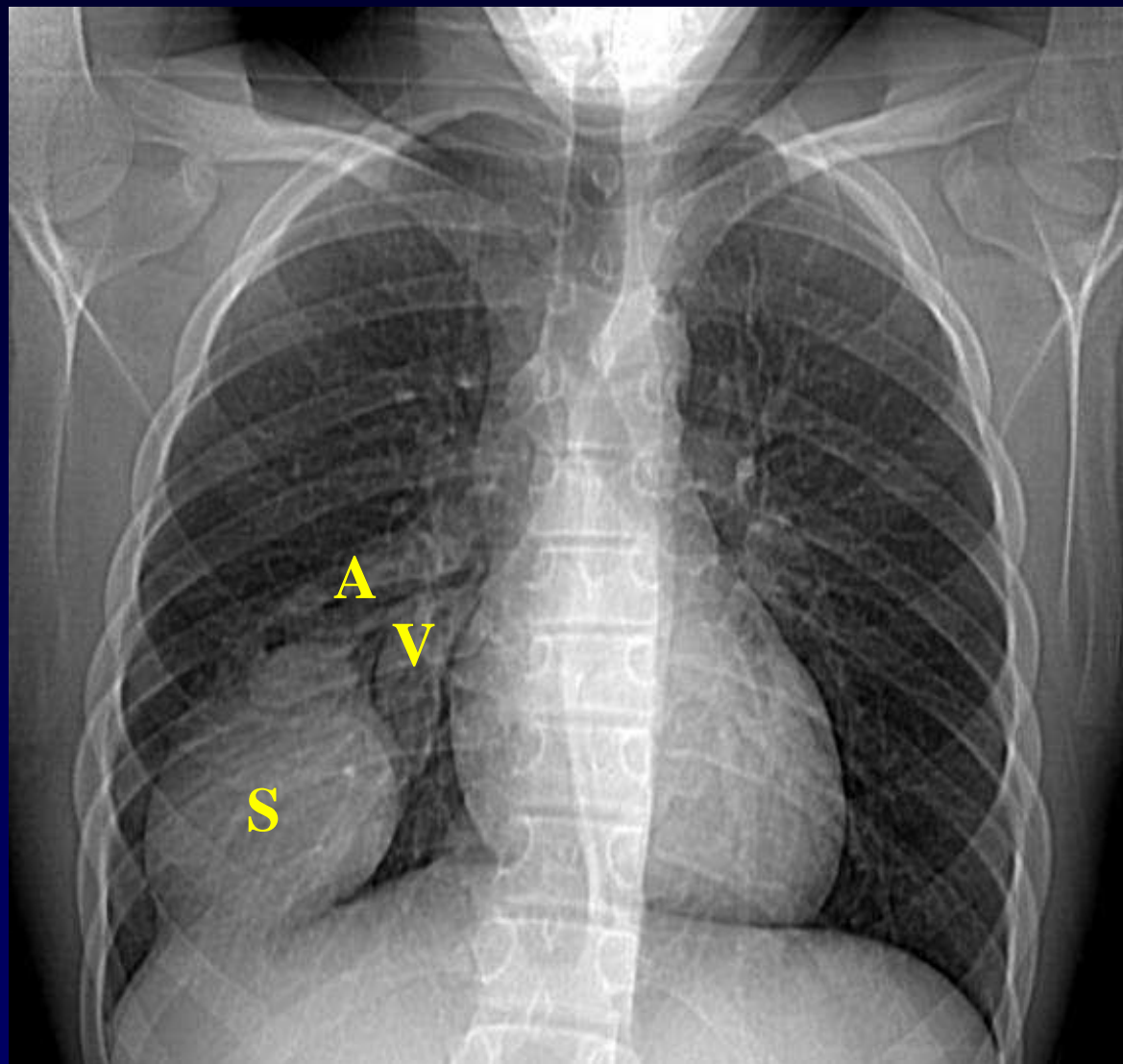


Diagnostic

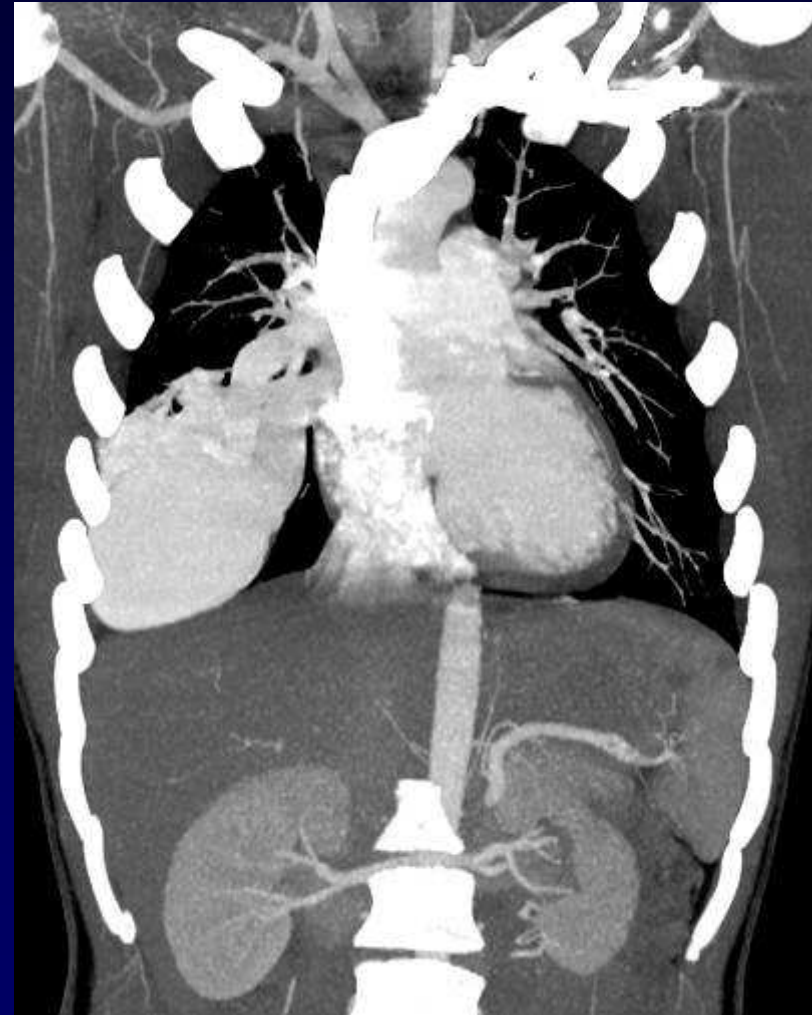
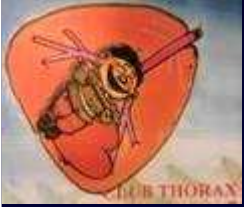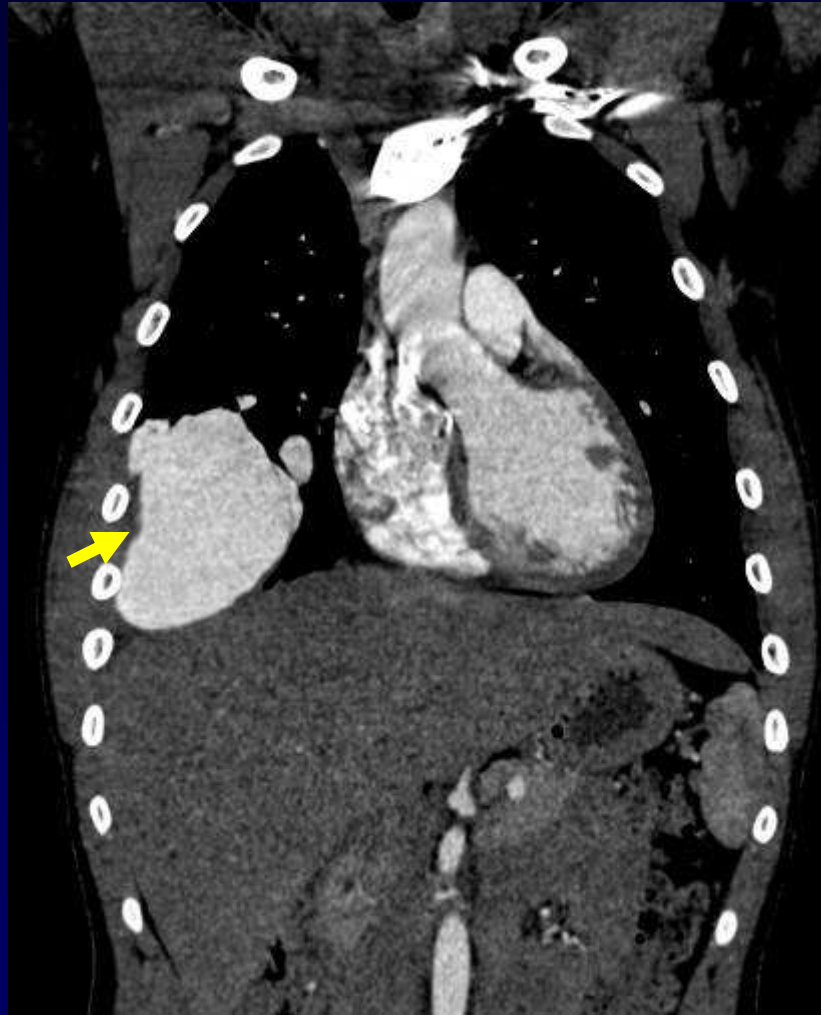
Malformation Artério-Veineuse Pulmonaire (MAVP)



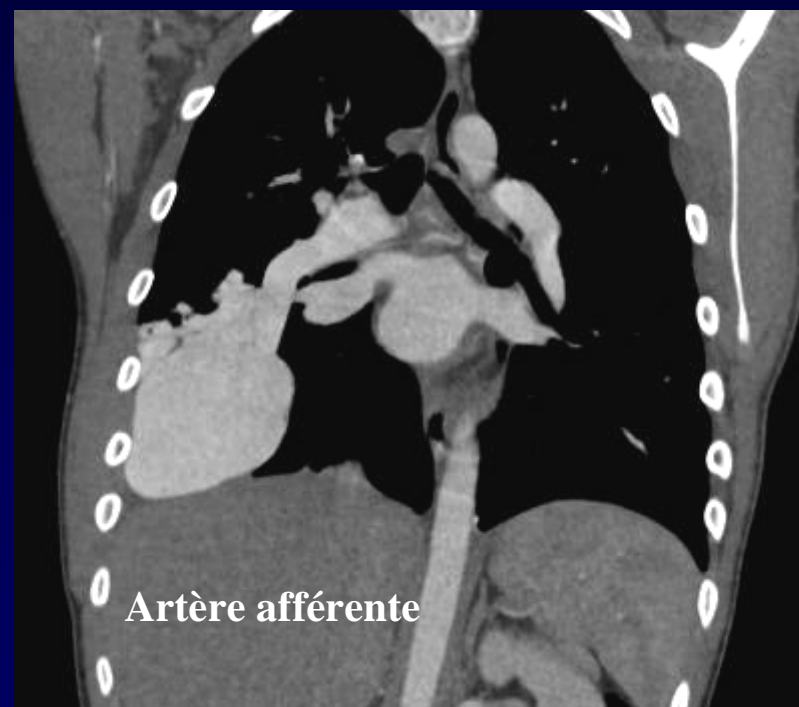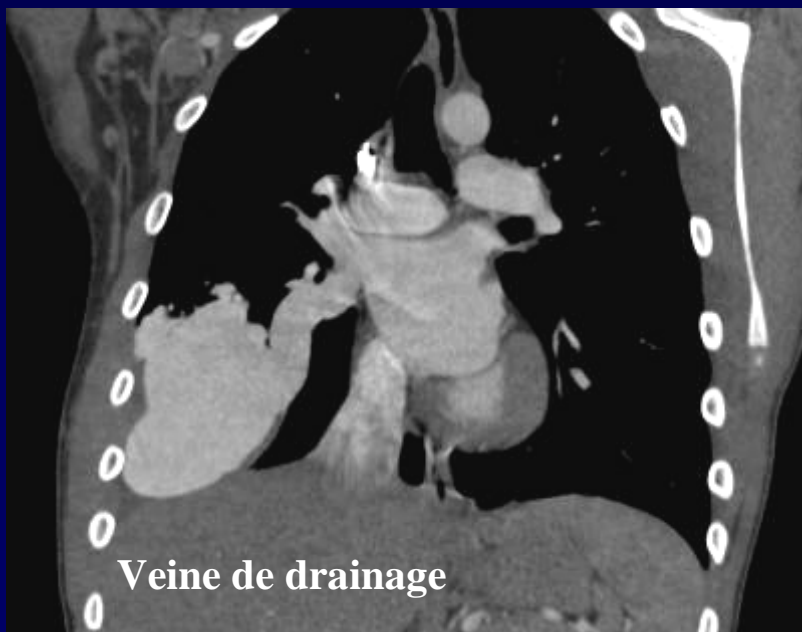
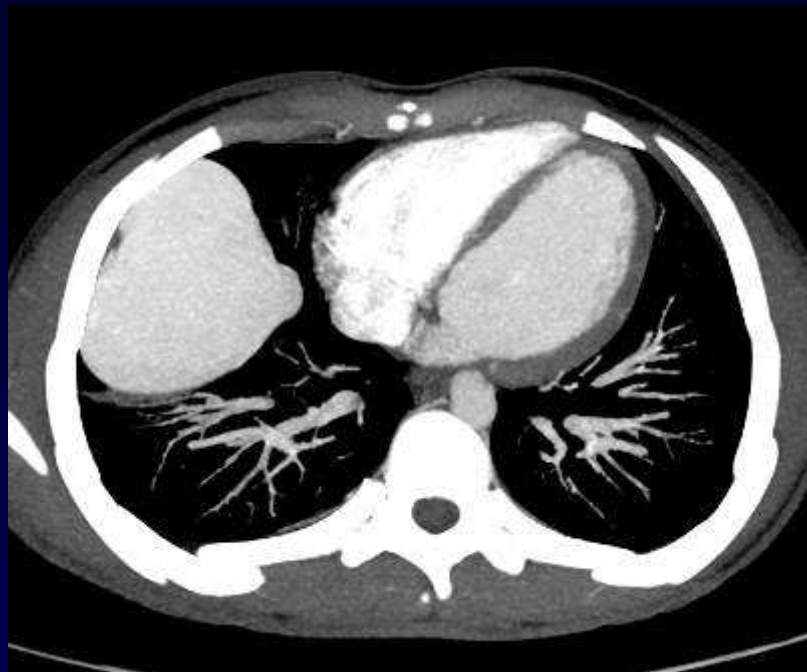
★ Sac anévrysmal

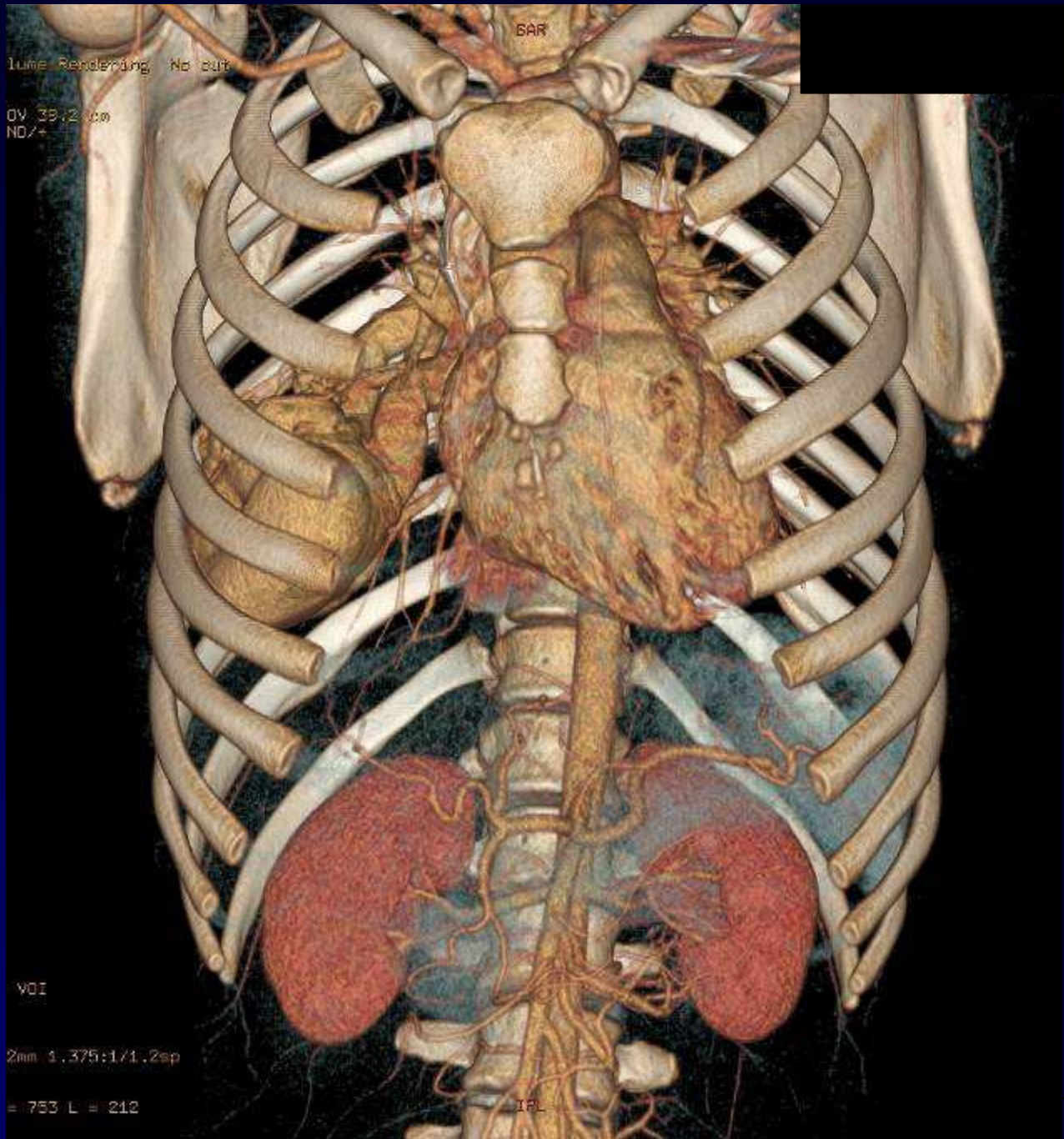


A = Artère ; V = Veine ; S = Sac



➔ Caillots dans le sac anévrismal





lume Rendering No cut

OV 39.2 cm
NO/4

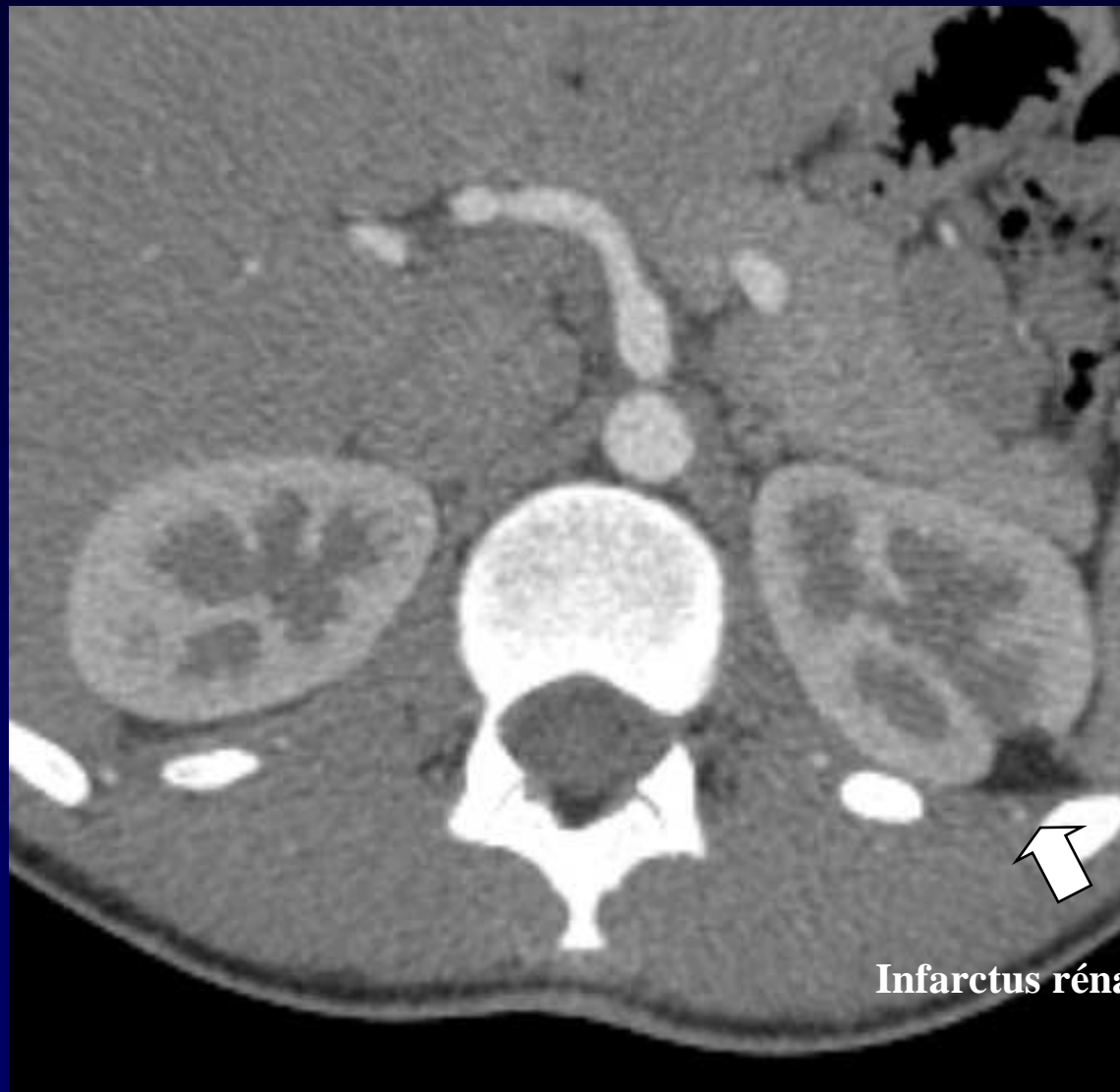SAR

VOI

2mm 1.375:171.2sp

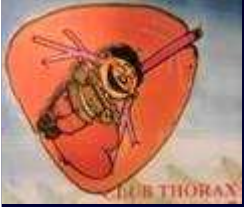
= 753 L = 212

IPL



Infarctus rénal

Probable séquelle d'embolie paradoxale



Hb : 22g

Pas d'argument pour une maladie de Rendu Osler

Décision thérapeutique : lobectomie moyenne

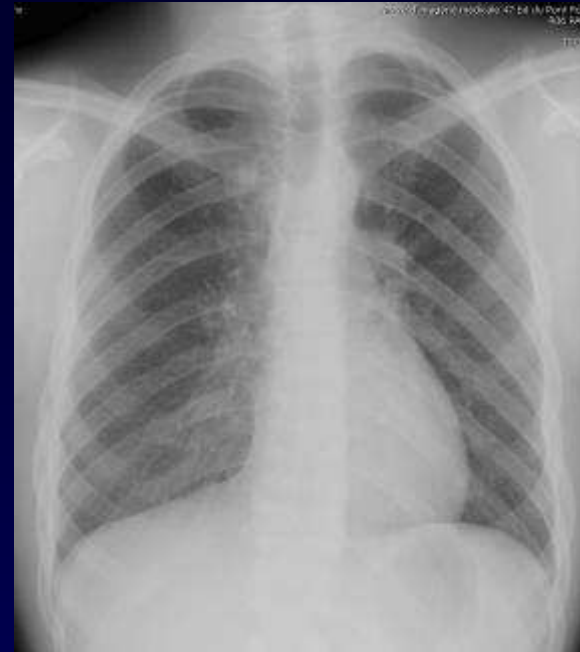Chirurgie en raison de la taille de la fistule et du jeune âge du patient

Lobectomie moyenne

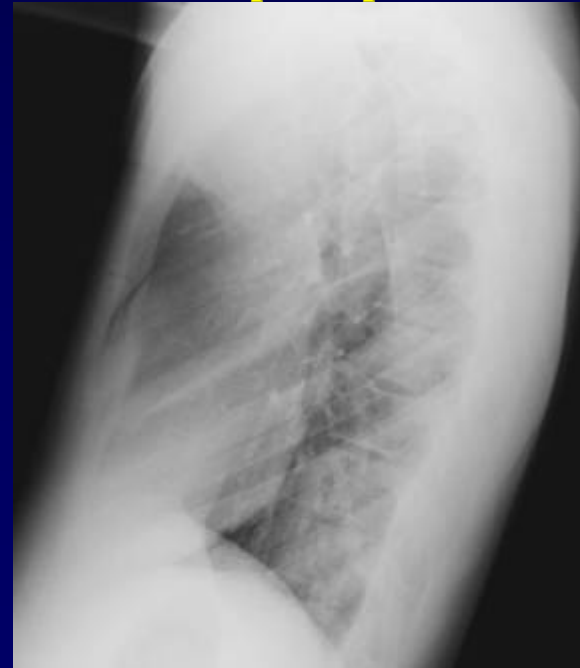
Fistule en pré-rupture (douleurs)

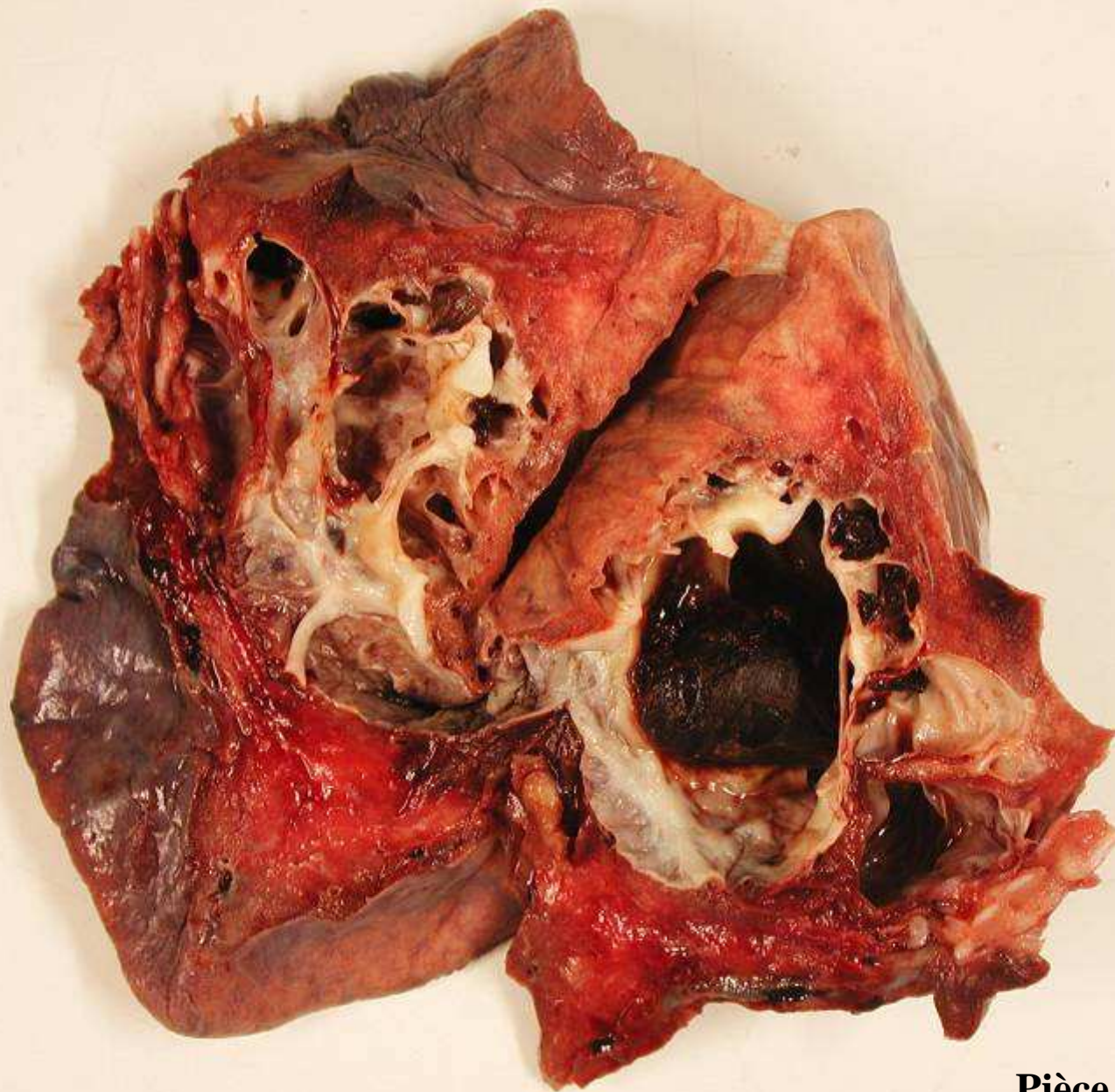
Caillots +++

Bonne évolution post-opératoire



Contrôle post-opératoire





Pièce opératoire