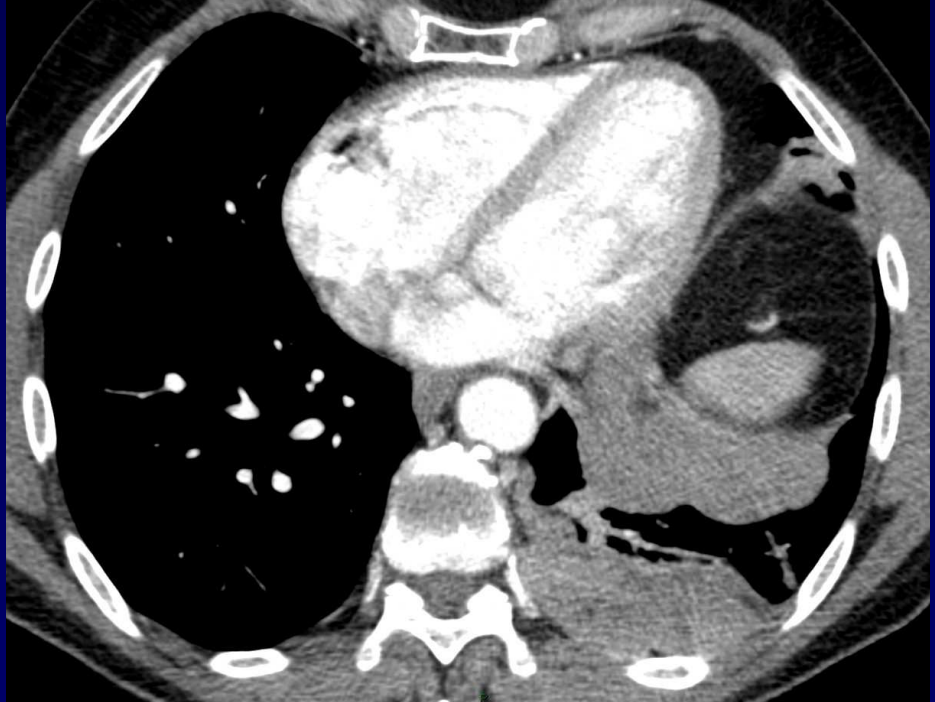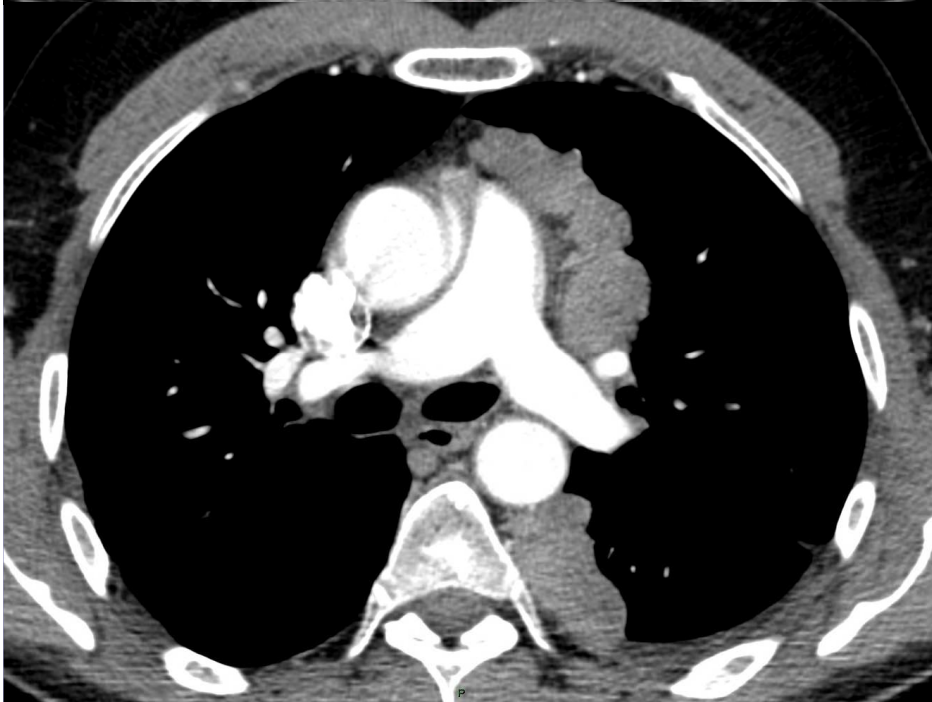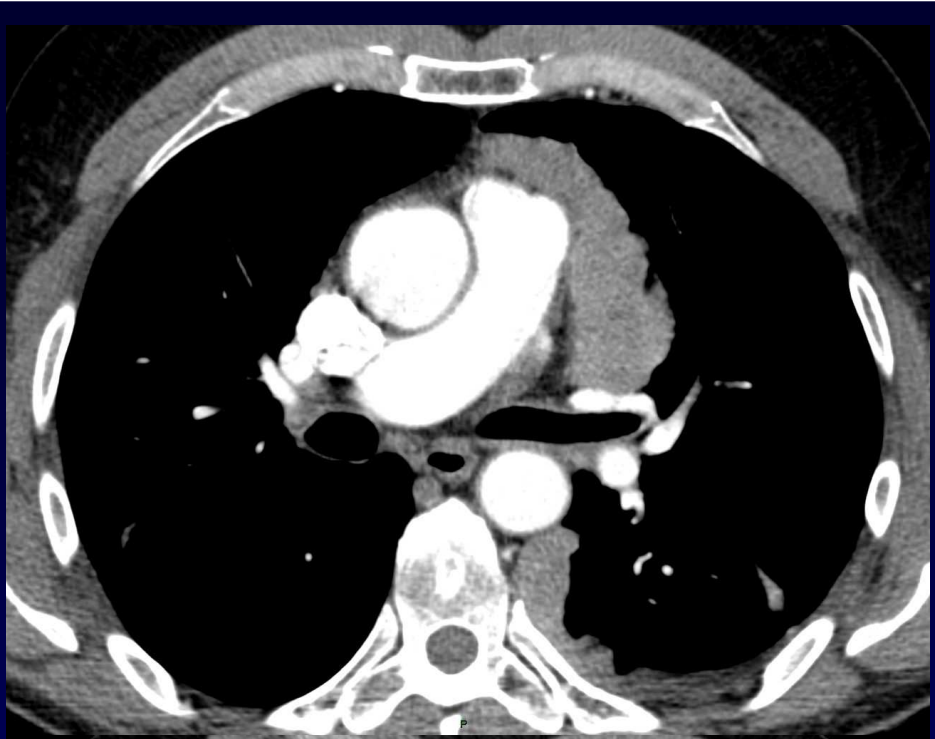
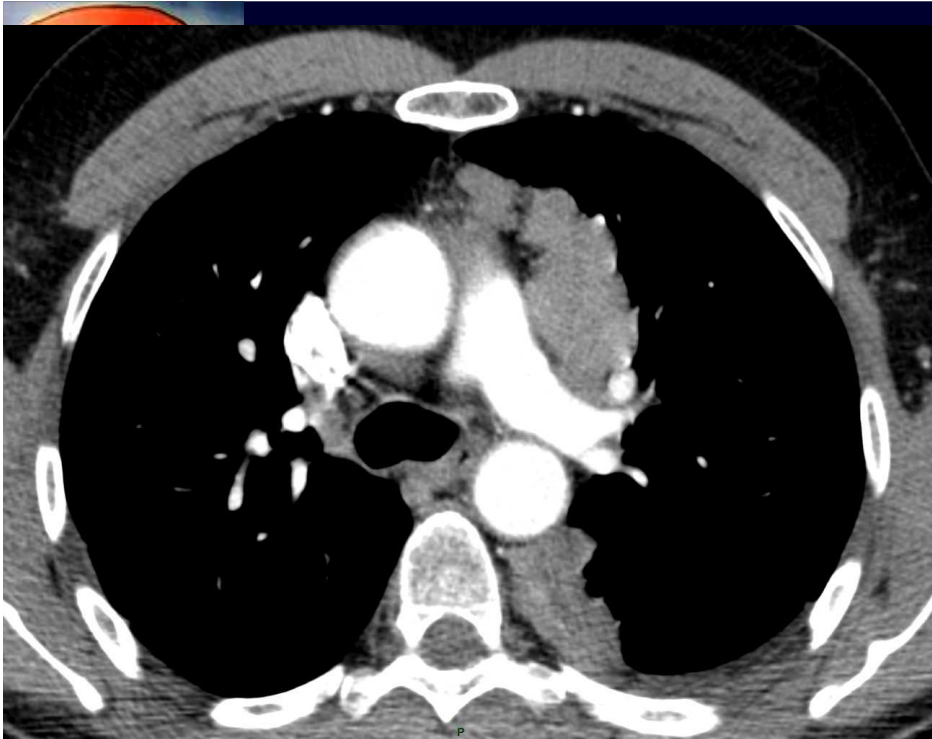




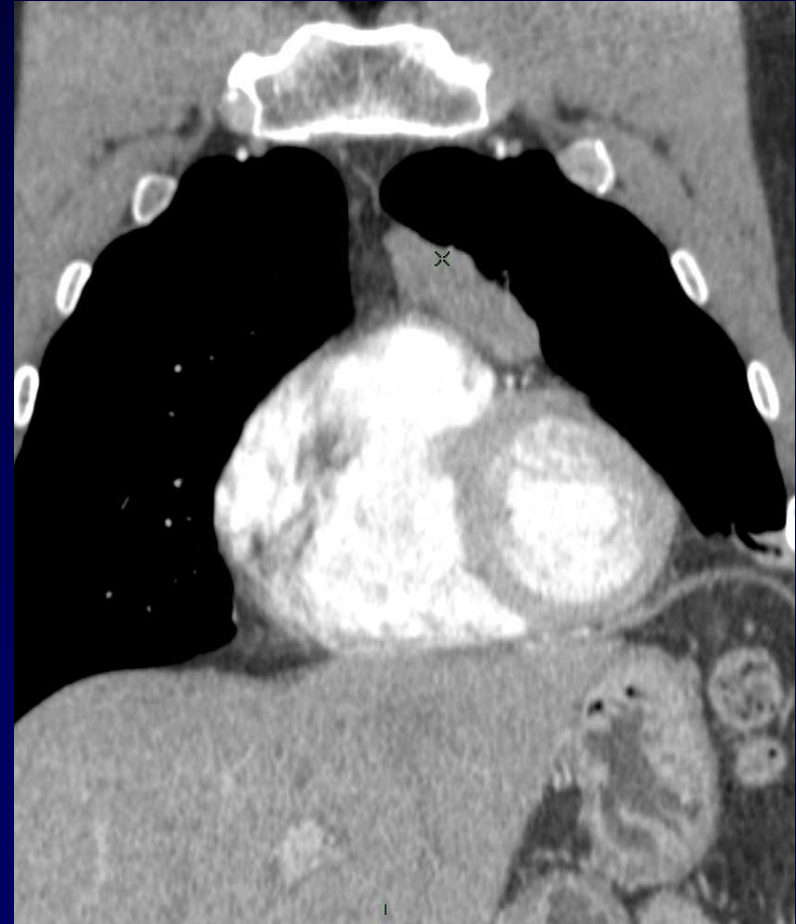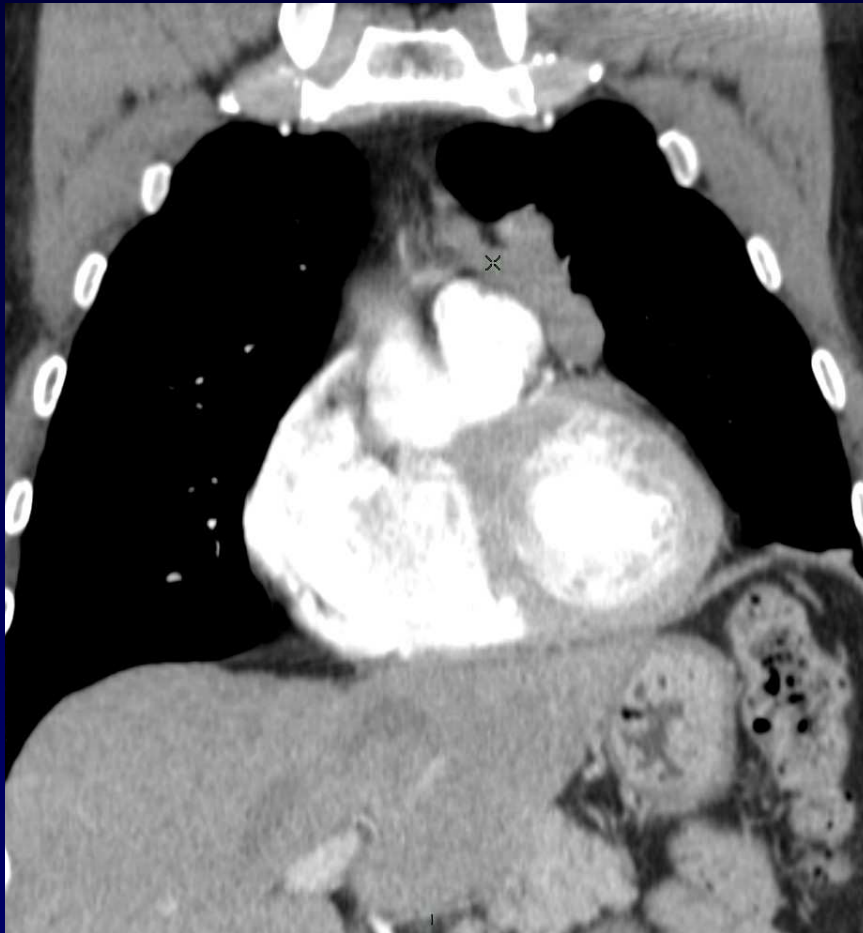Dossier 10

MP Debray

**Homme de 60 ans
Douleurs thoraciques**







Diagnostic ?



Diagnostic

Thymome invasif, métastatique à la plèvre