

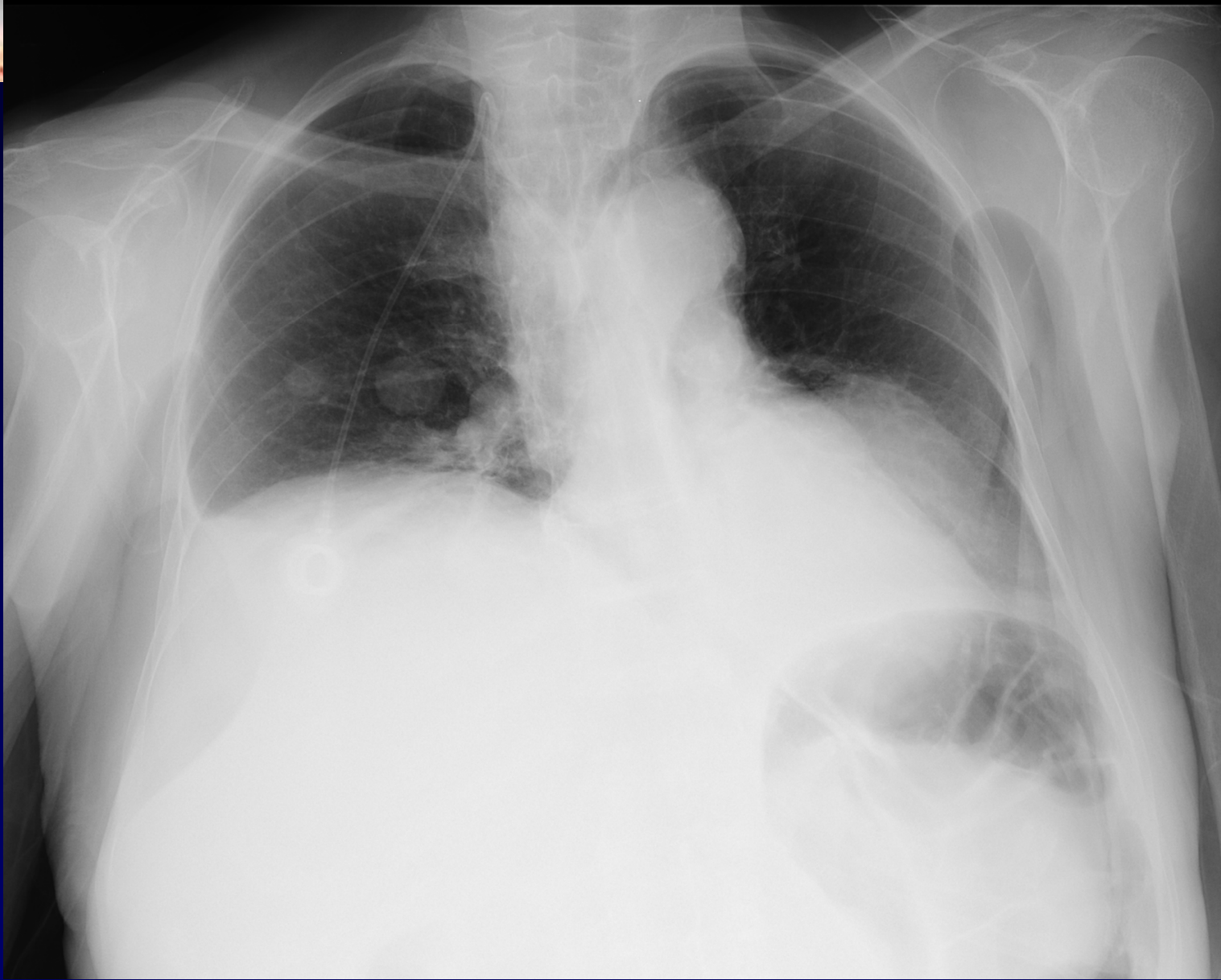


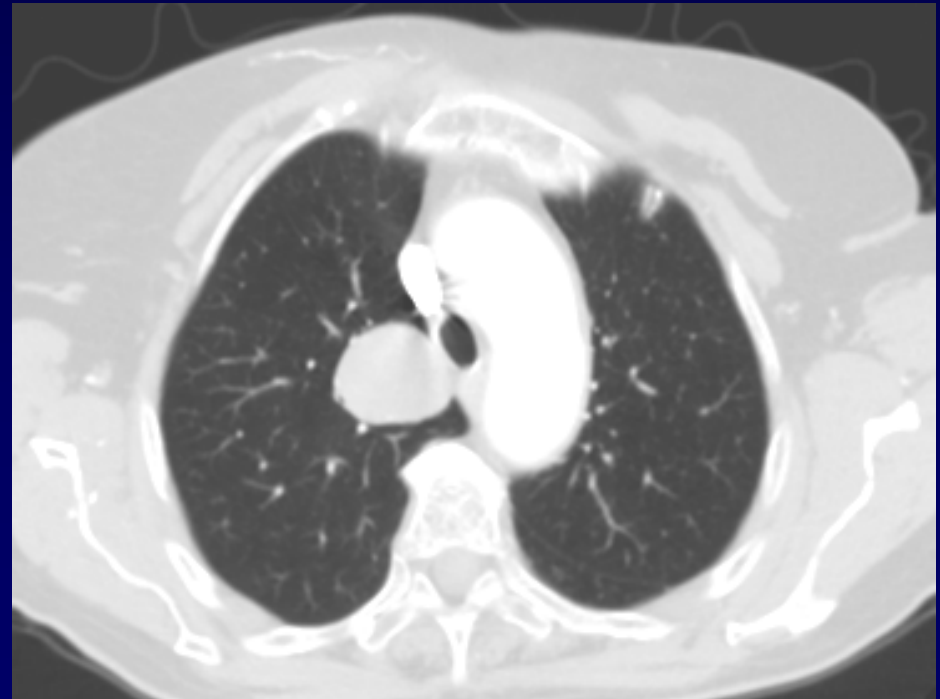
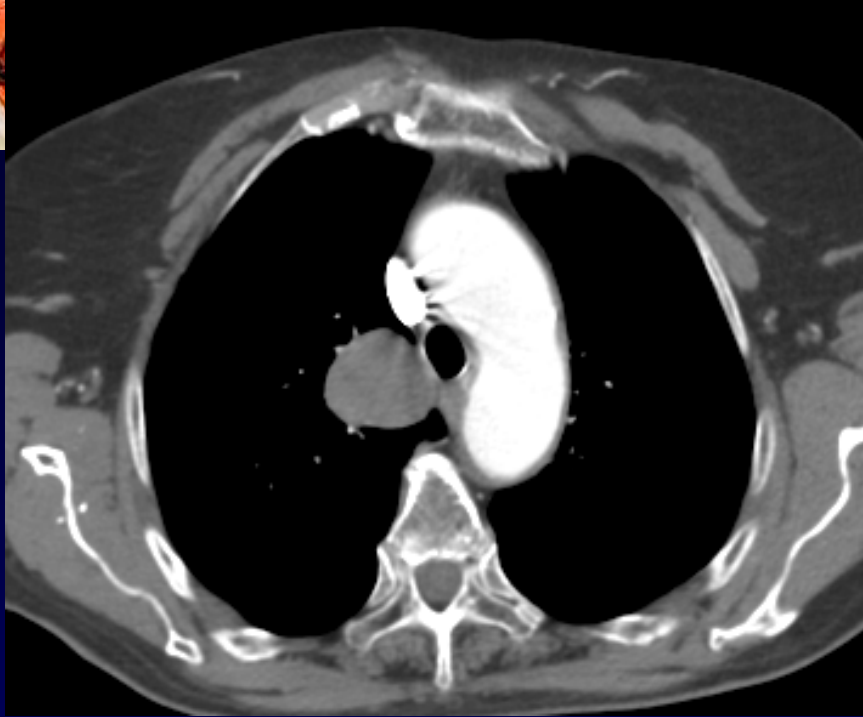
Dossier 14

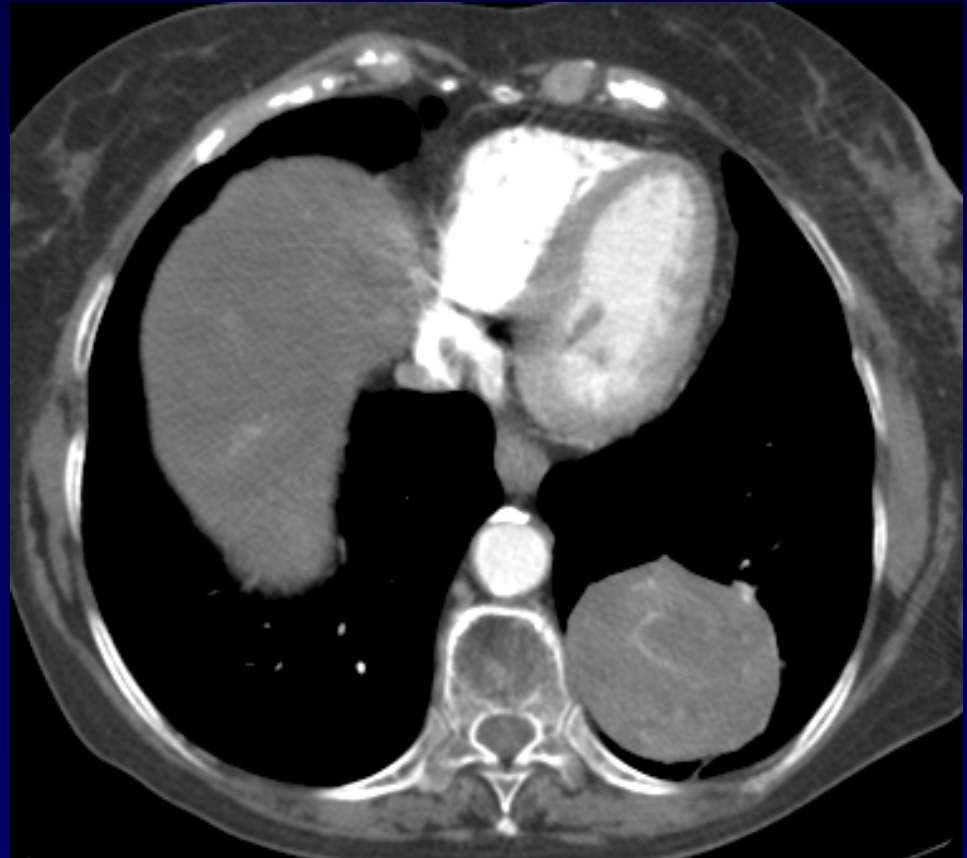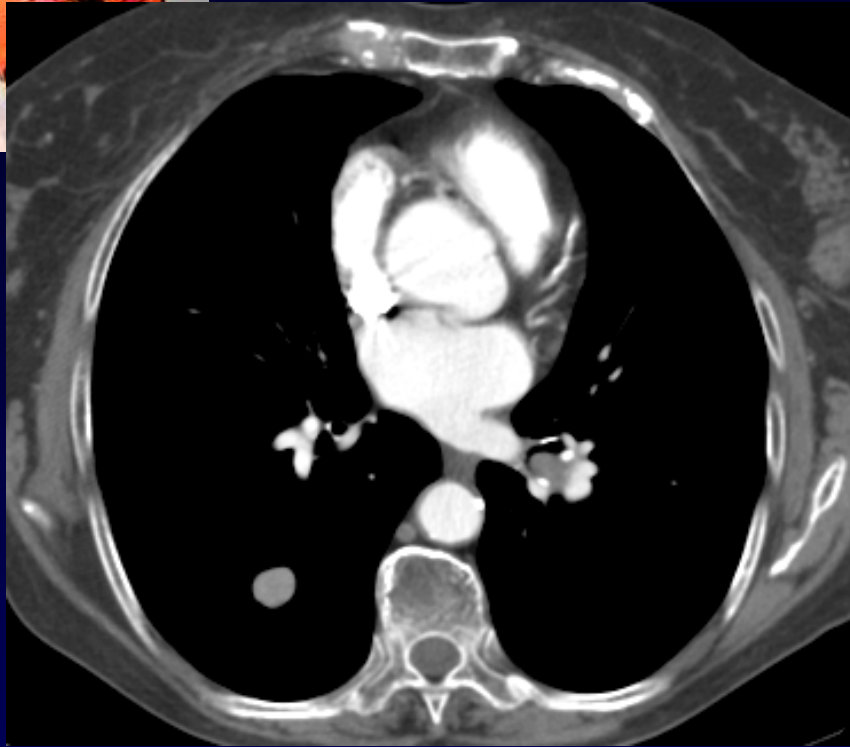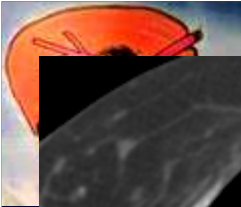
**M EL HAJJAM
P LACOMBE**

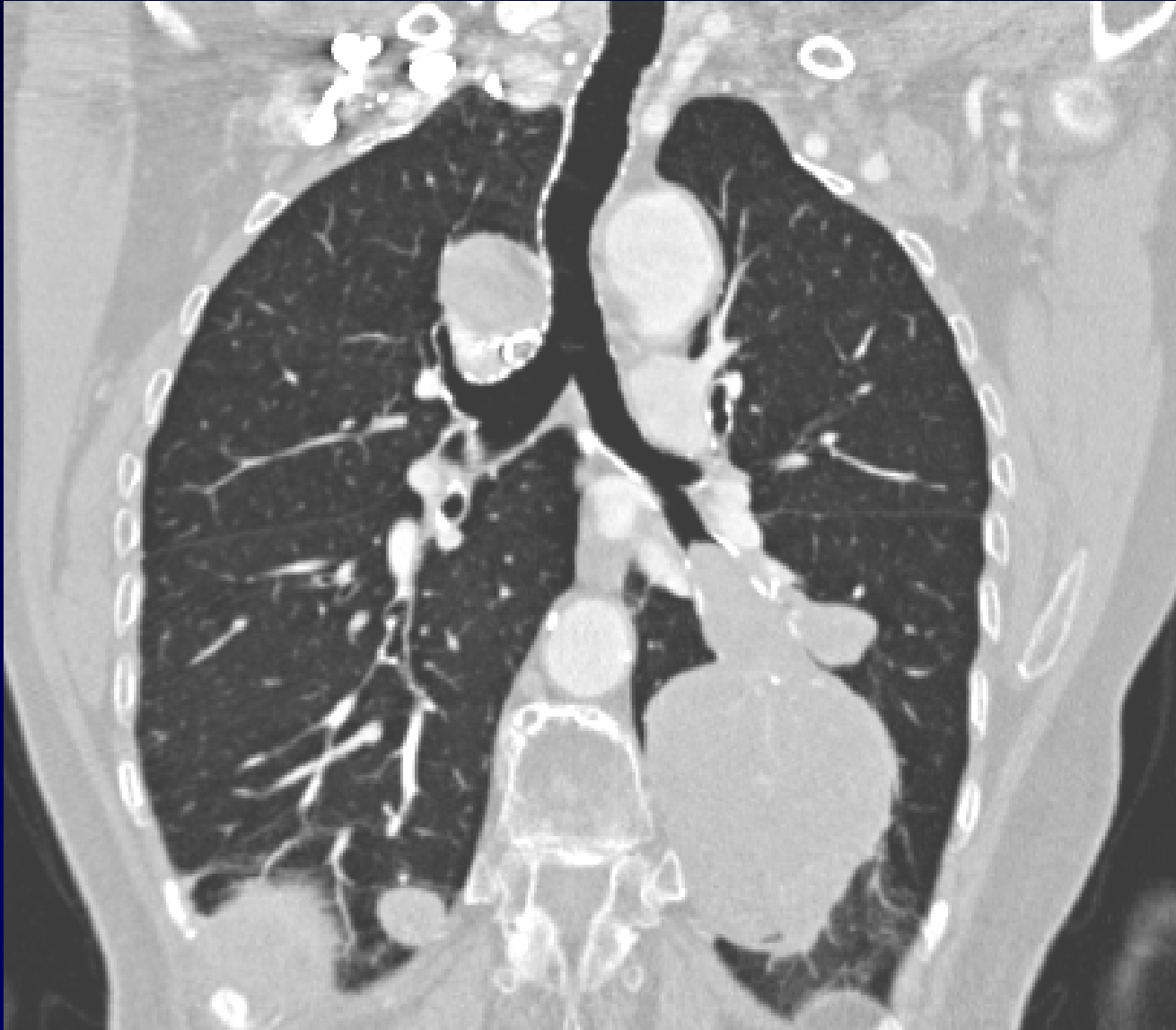
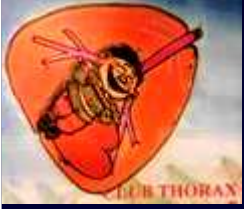Femme de 77 ans

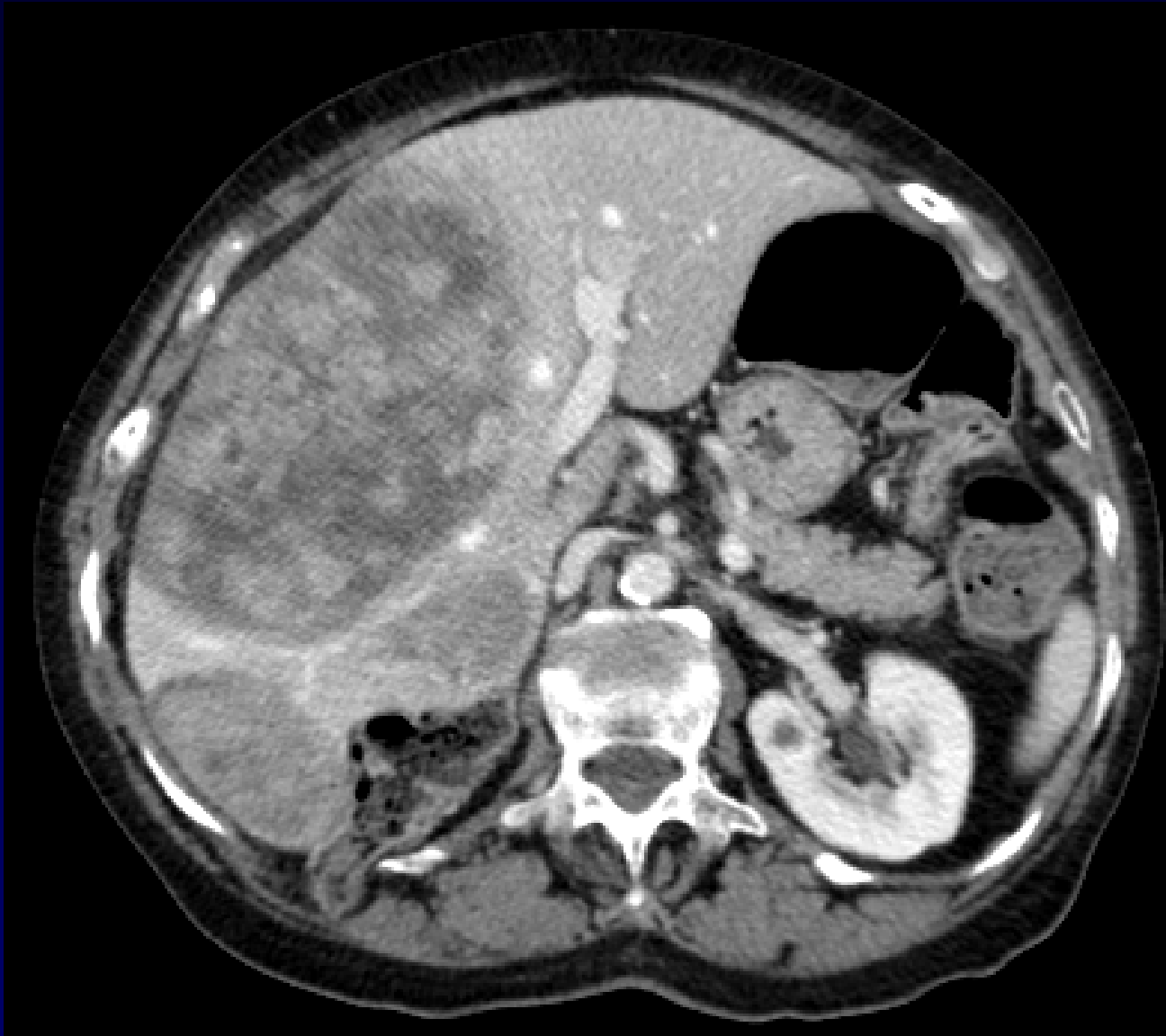Dyspnée - Altération de l'état général





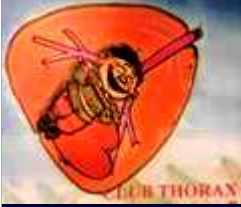







Diagnostic ?



Diagnostic

**Métastases pulmonaires et hépatiques
d'un **léiomyosarcome du rein droit**,
survenues 3 ans après une urétéro-néphrectomie
droite.**