

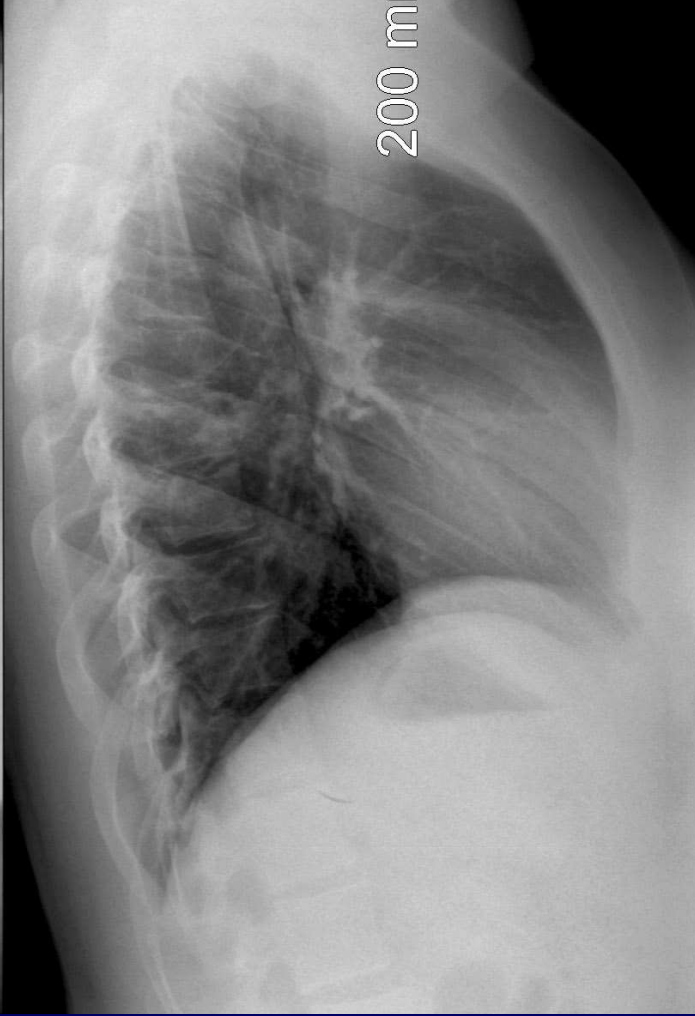
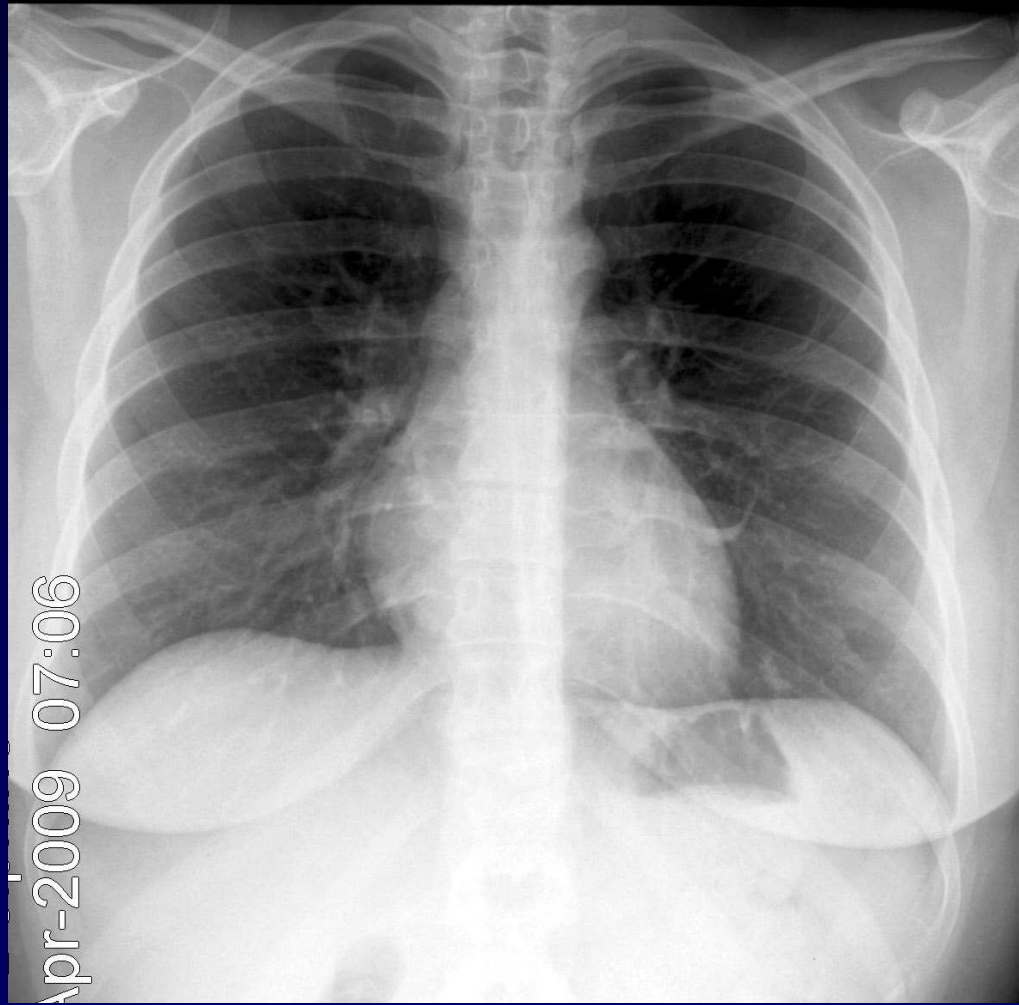


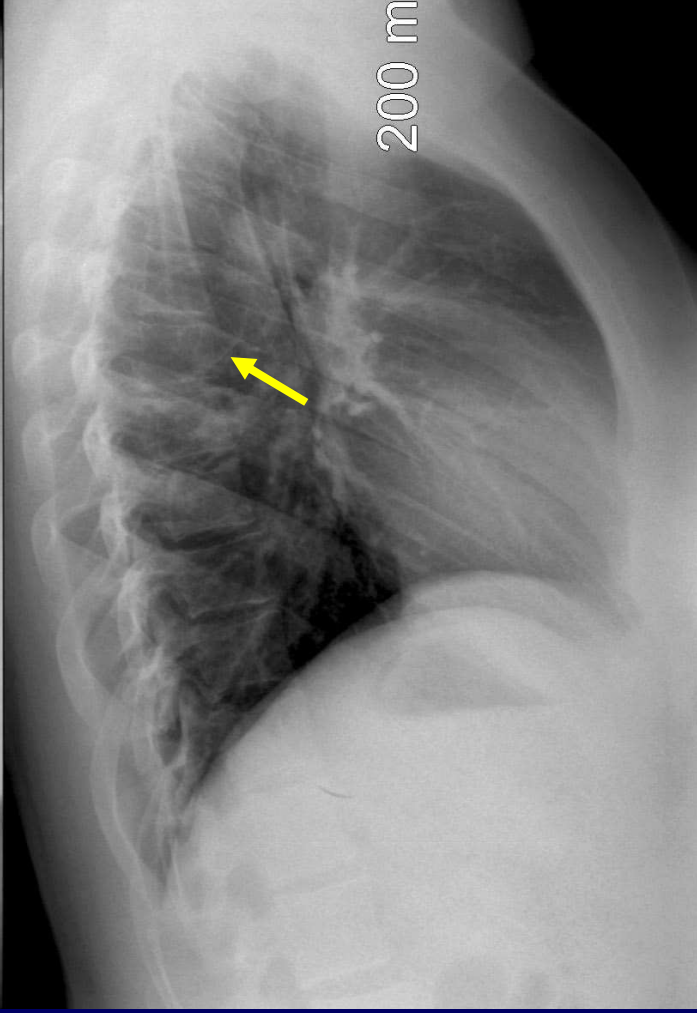
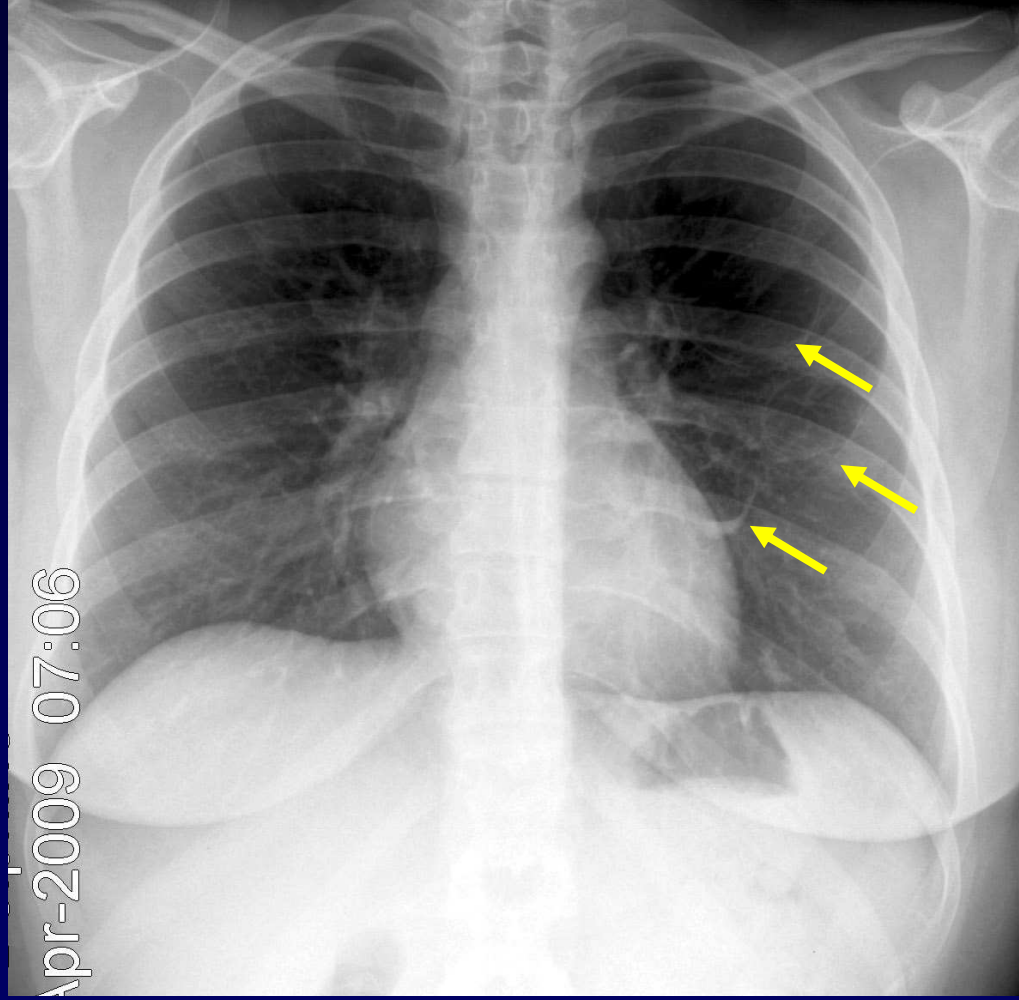
J.GIRON – P. FAJADET – J.BERJAUD

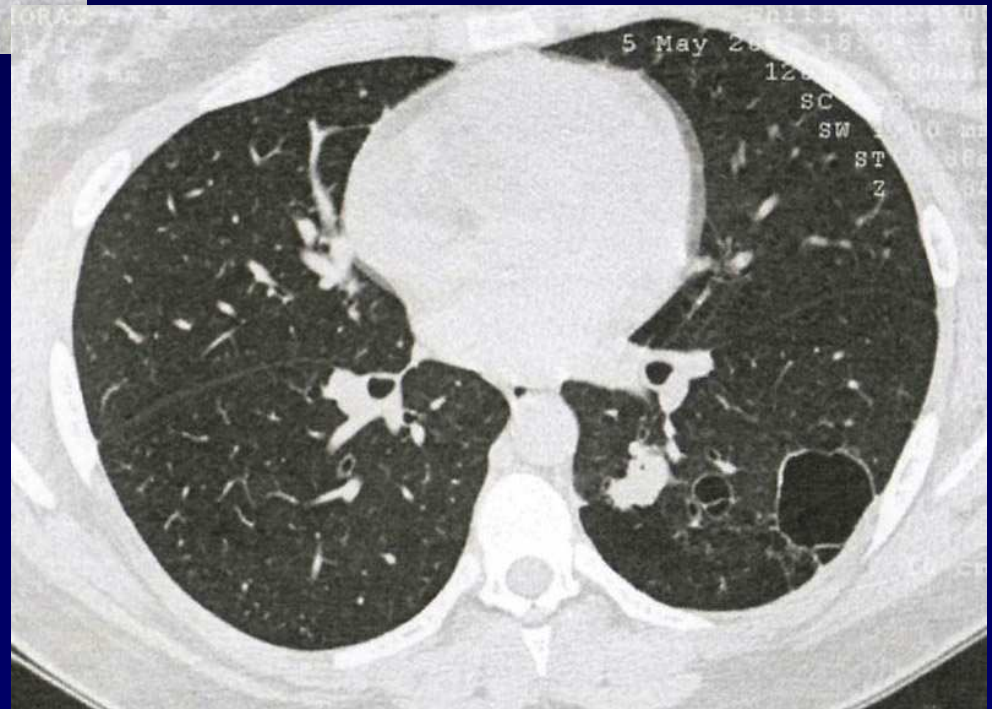
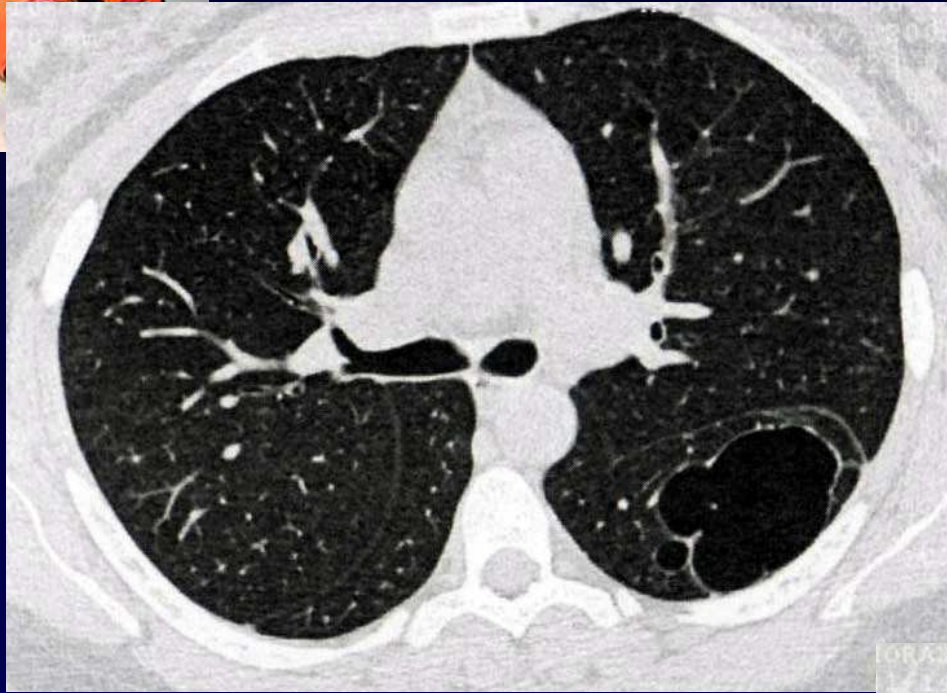
Femme de 19 ans

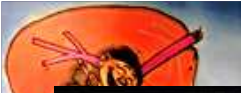Clinique :

- Fièvre et toux
- Point de côté gauche

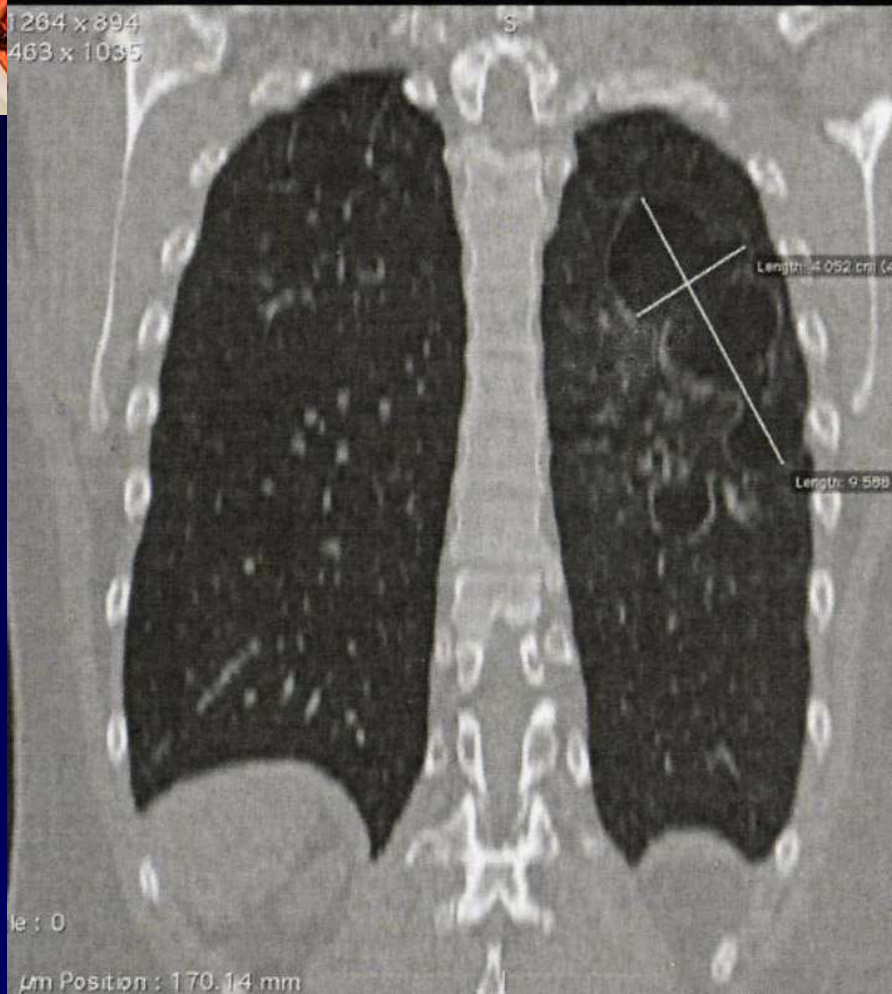




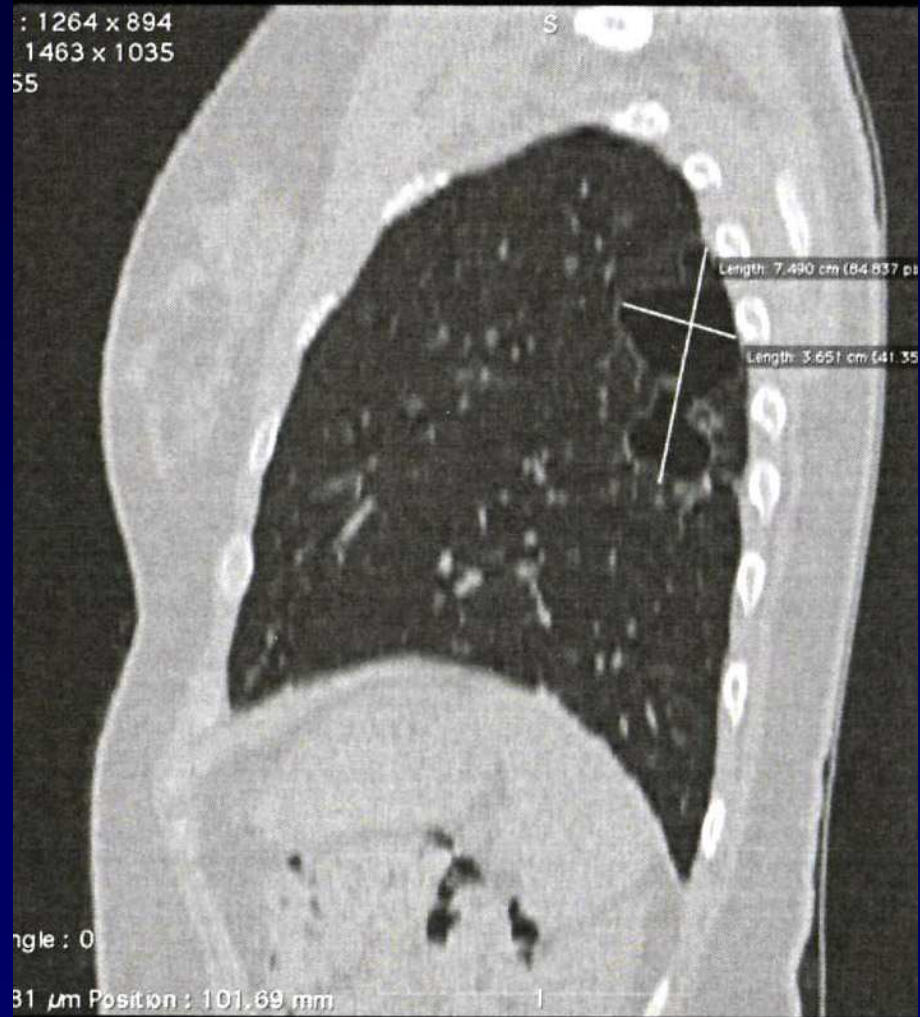


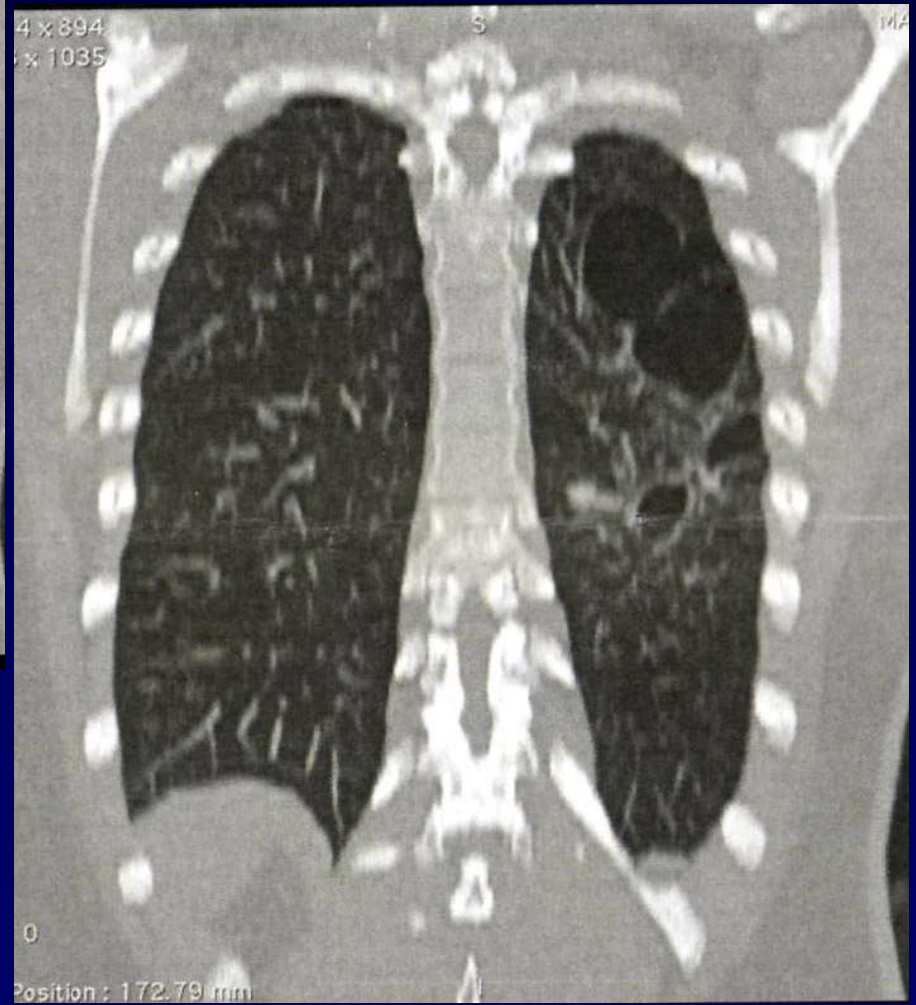
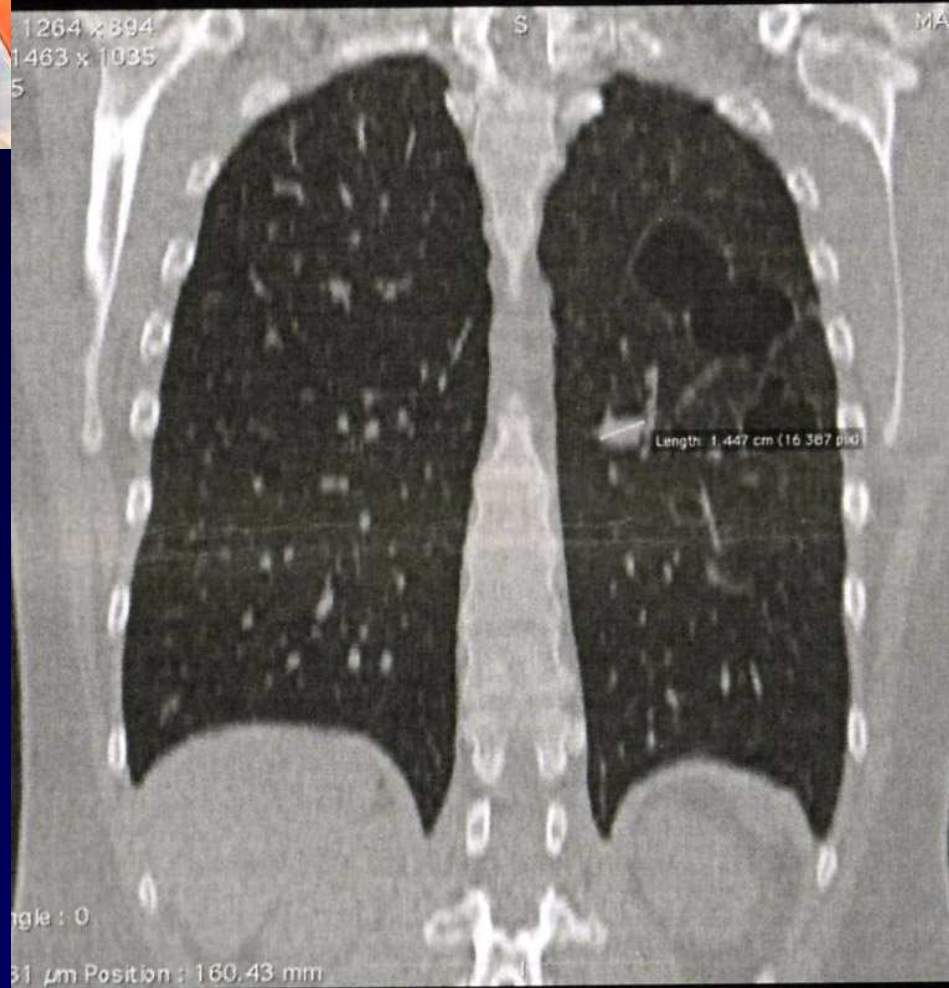


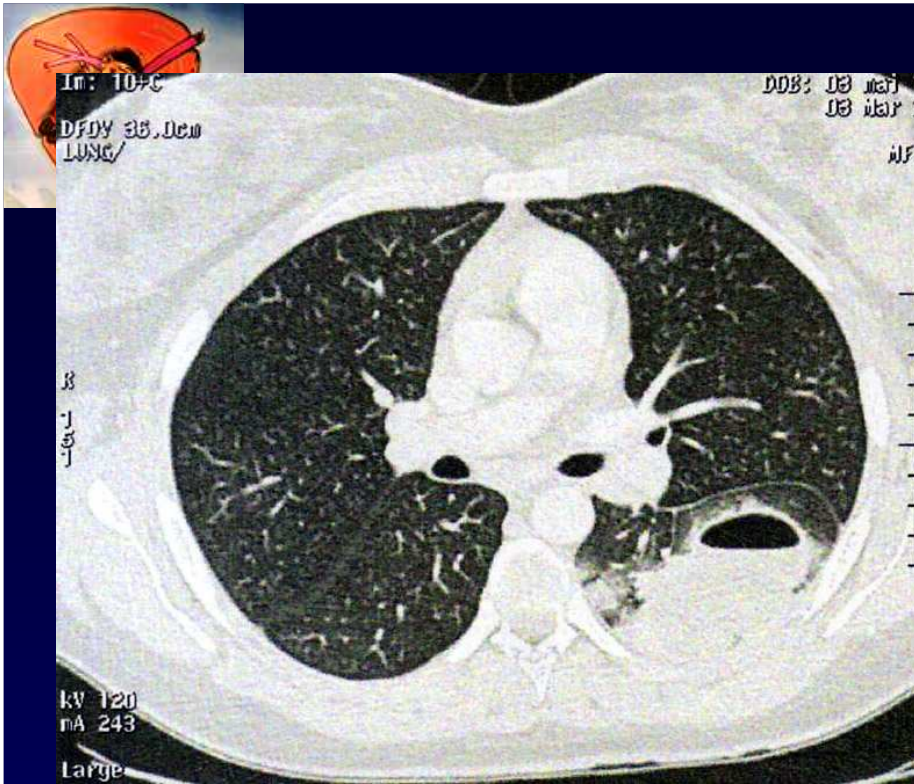
1264 x 894
1463 x 1035



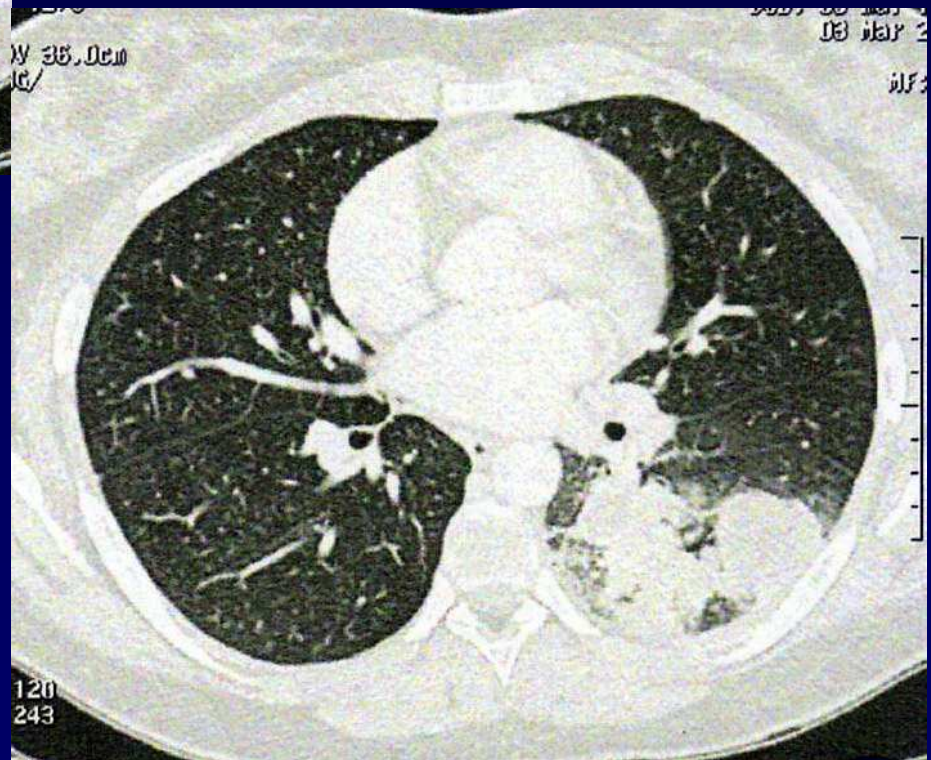
: 1264 x 894
1463 x 1035
55

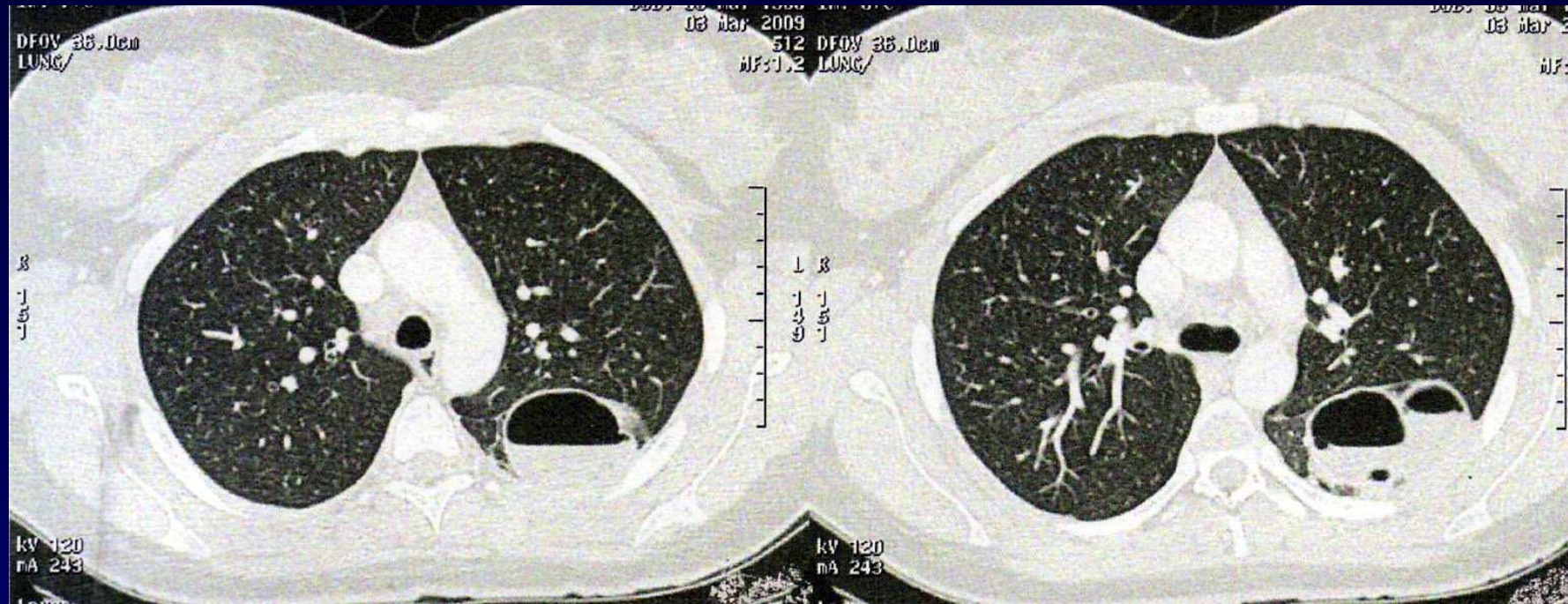






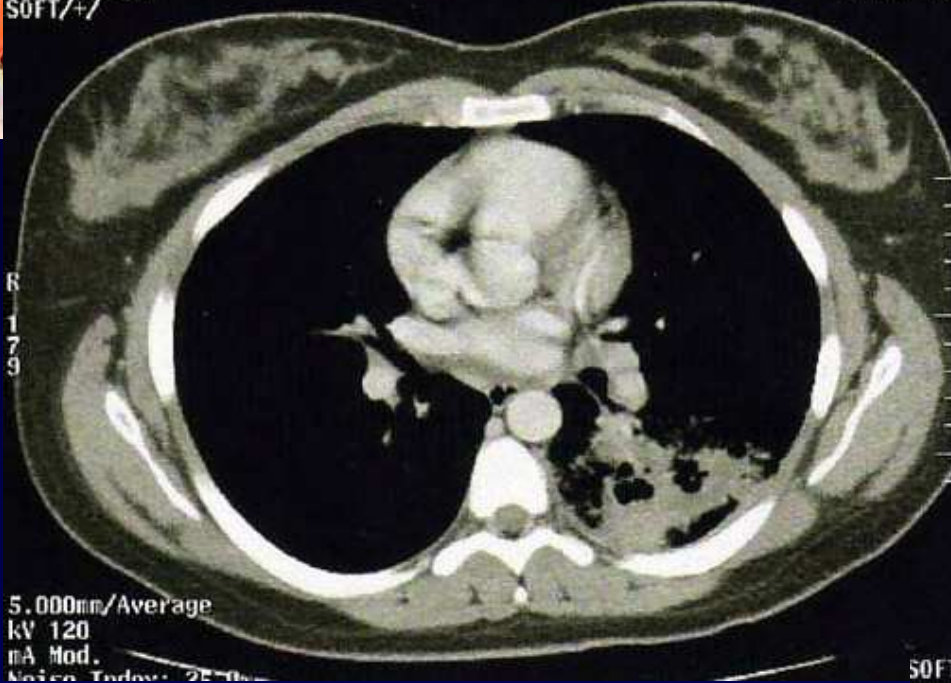
2 mois avant...



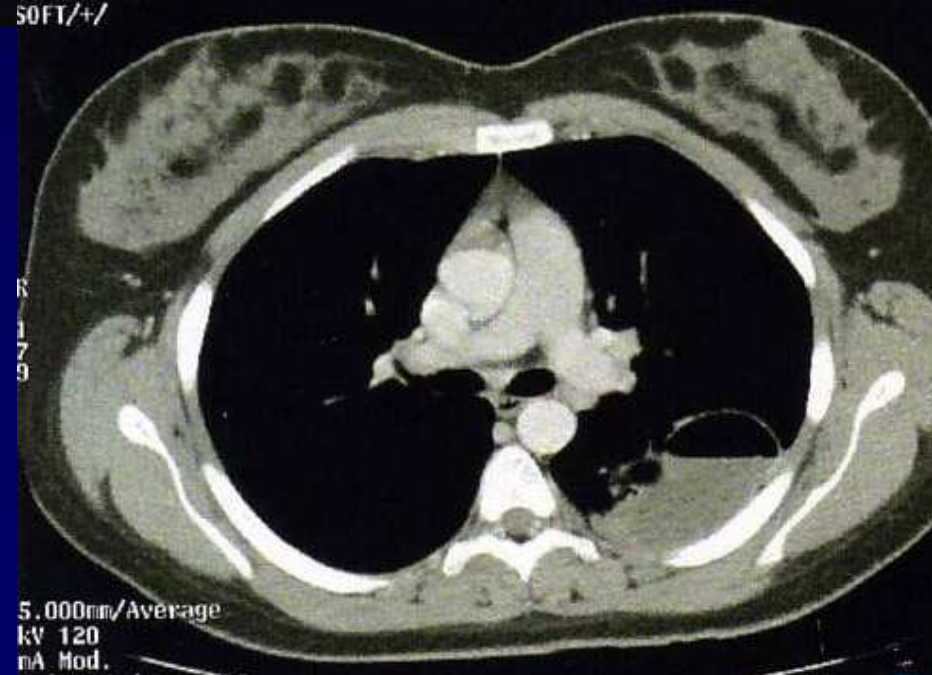


DFOV 36.0cm
SOFT/+/
R
179

03 mar 20



SOFT/+/
R
179





Diagnostic ?



Diagnostic

Lobectomie

**Malformation congénitale
adénomatoïde kystique**



Discussion

ATCD de pneumopathie au même endroit

Sujet jeune

Poumon congénital : **séquestration** , **atrésie bronchique**,
poumon adénomatoïde ...