



J-GIRON – PFAJADET- A -MODESTO

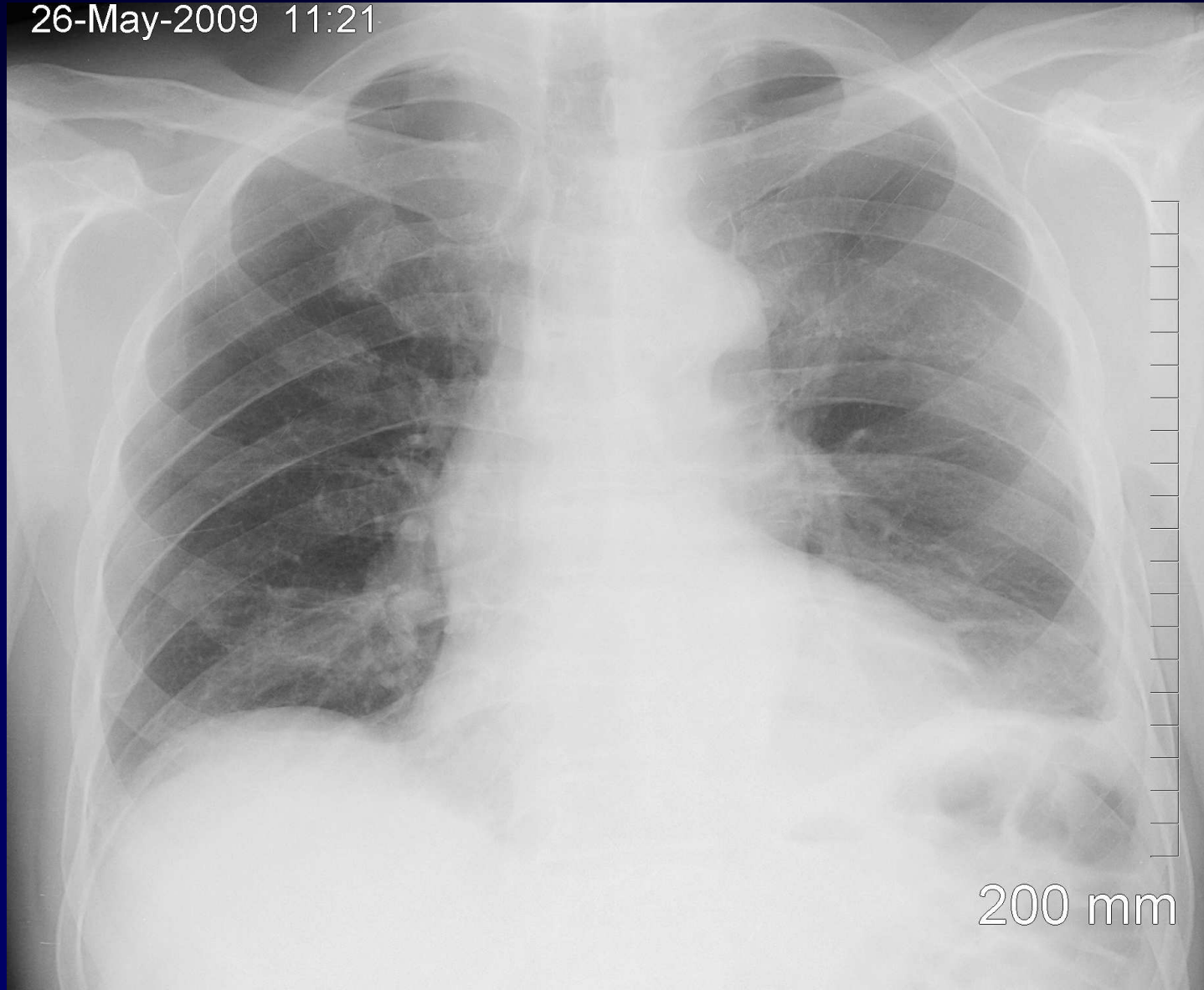
Homme de 74 ans

Clinique : Maladie connue depuis longtemps

Episode actuel



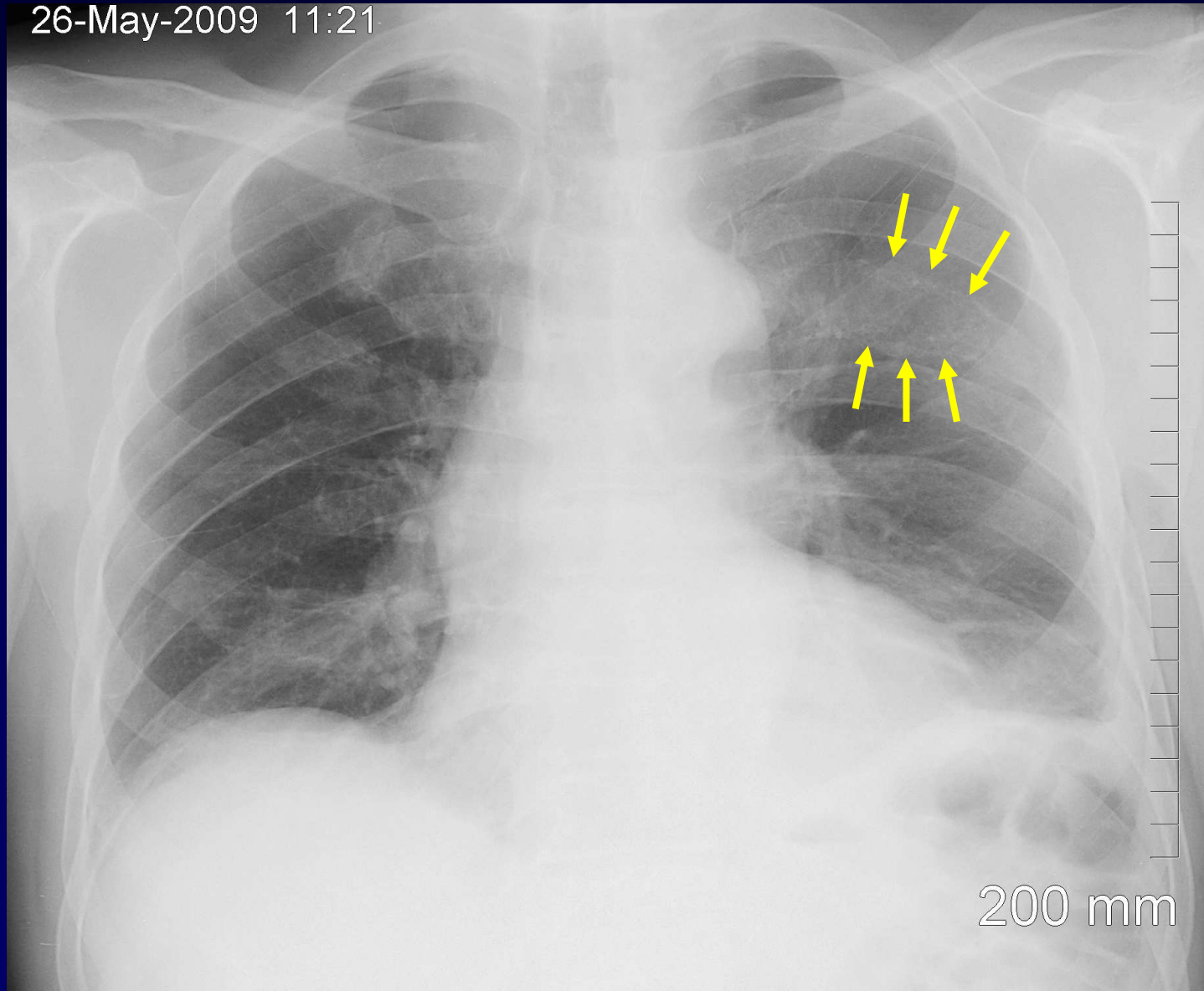
26-May-2009 11:21

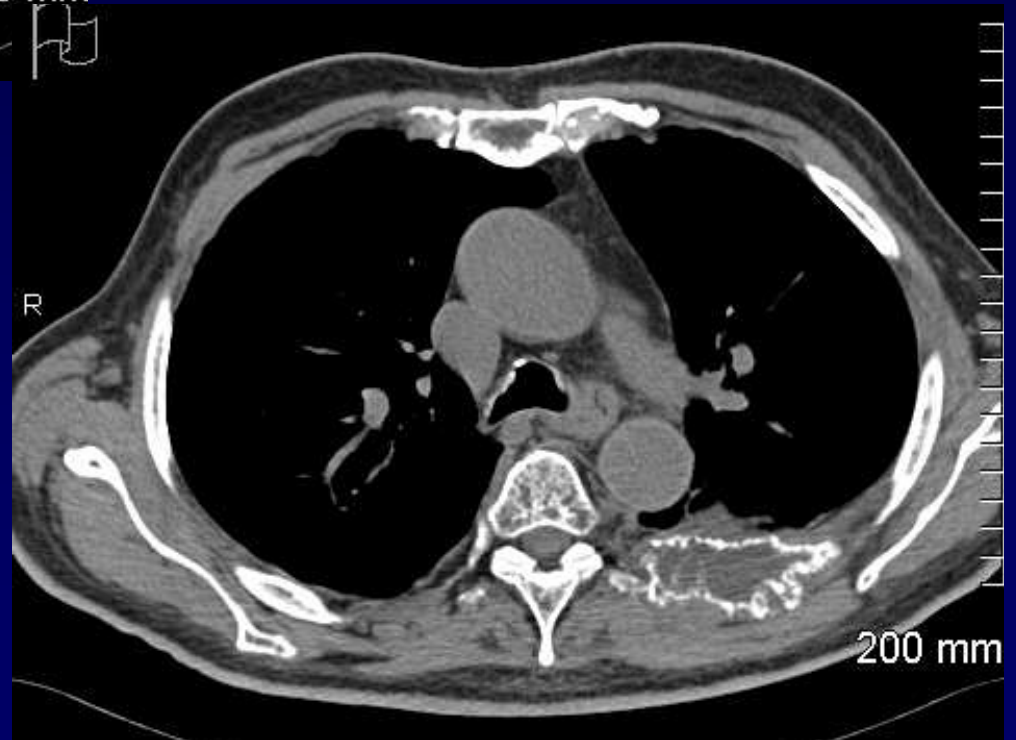
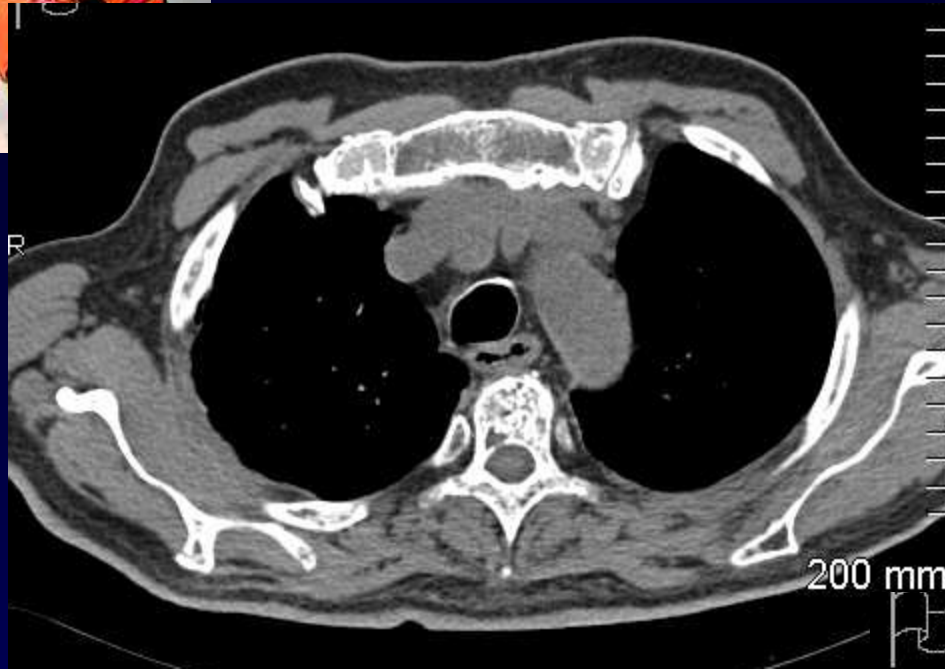
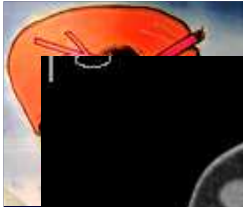
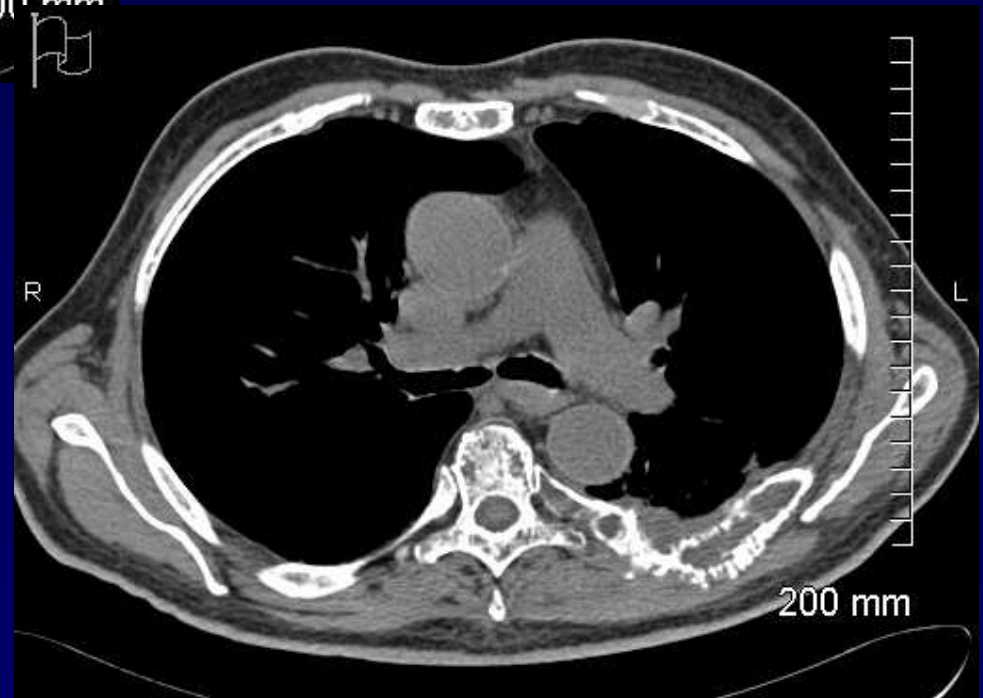
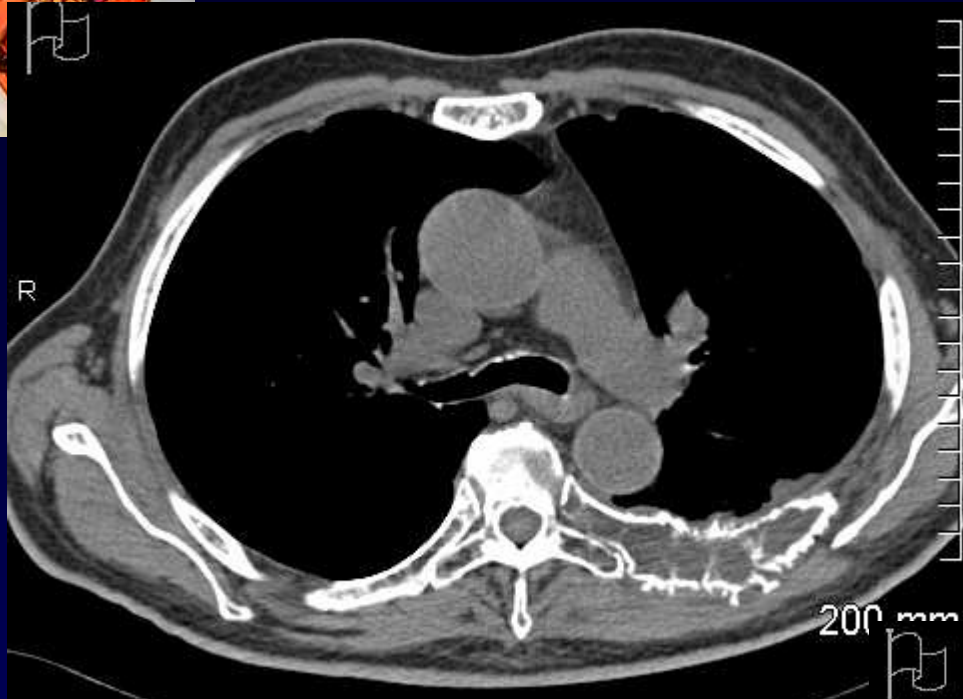200 mm

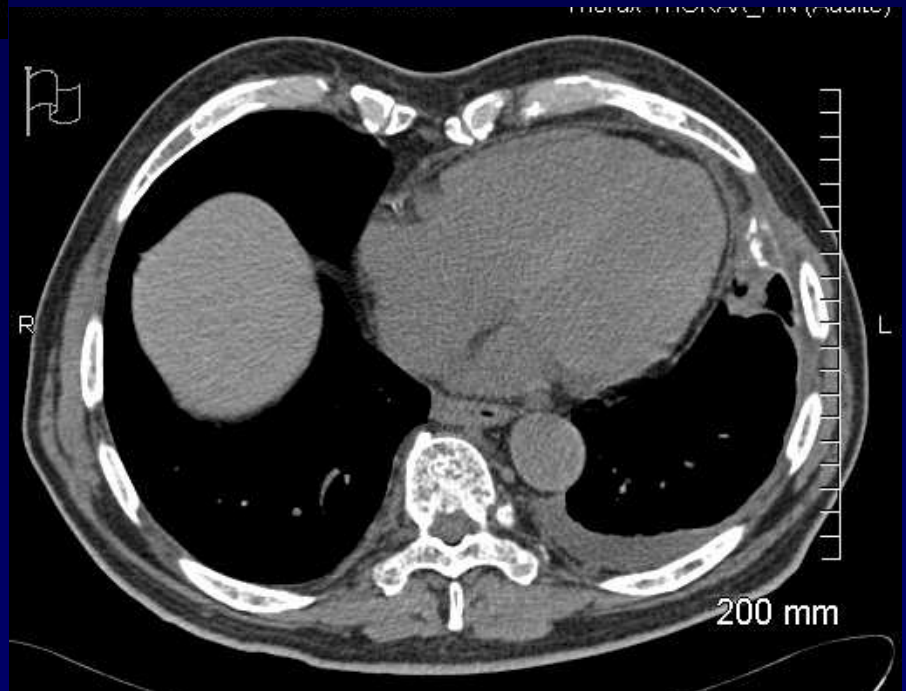
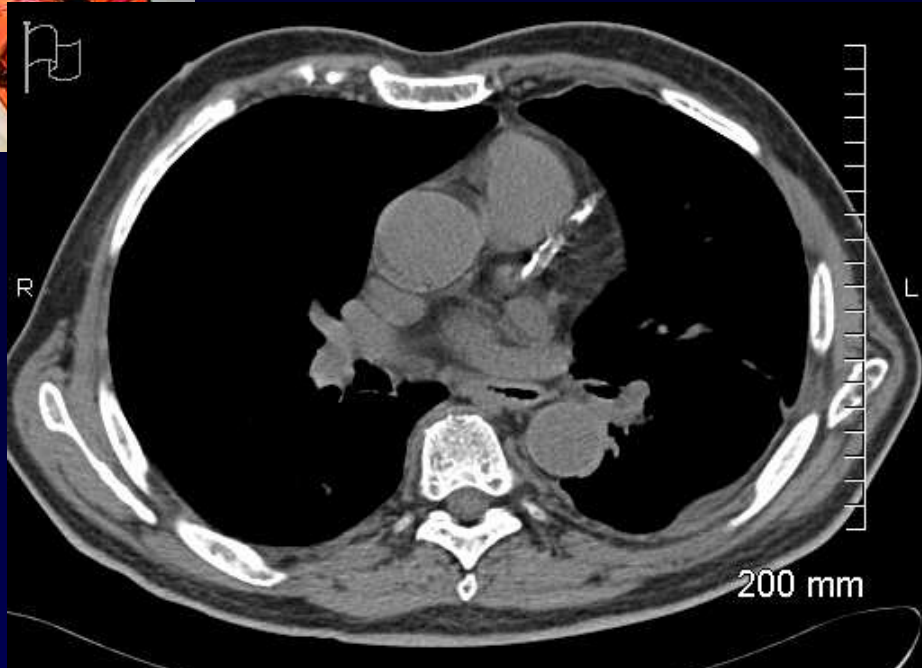


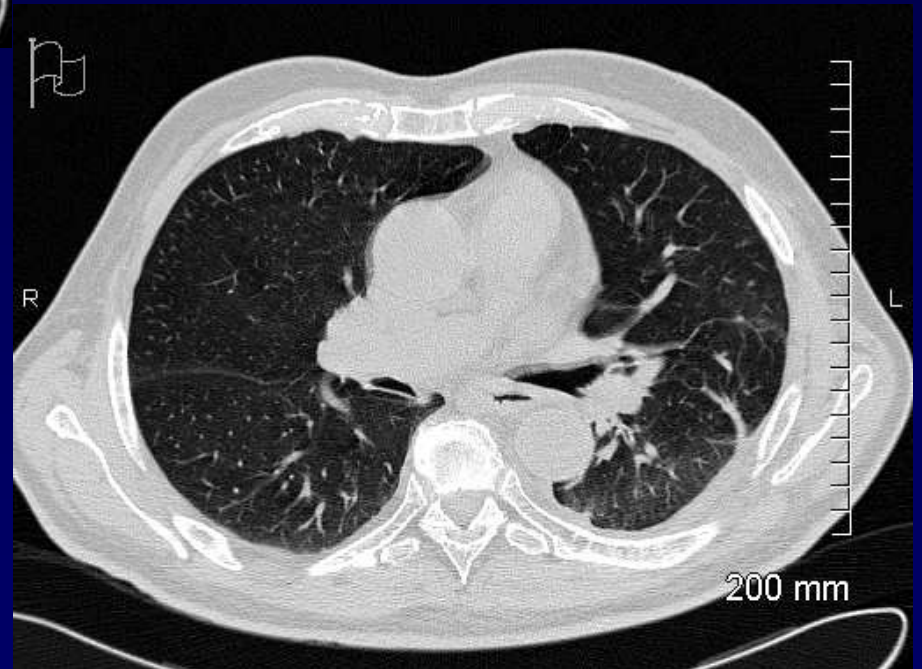
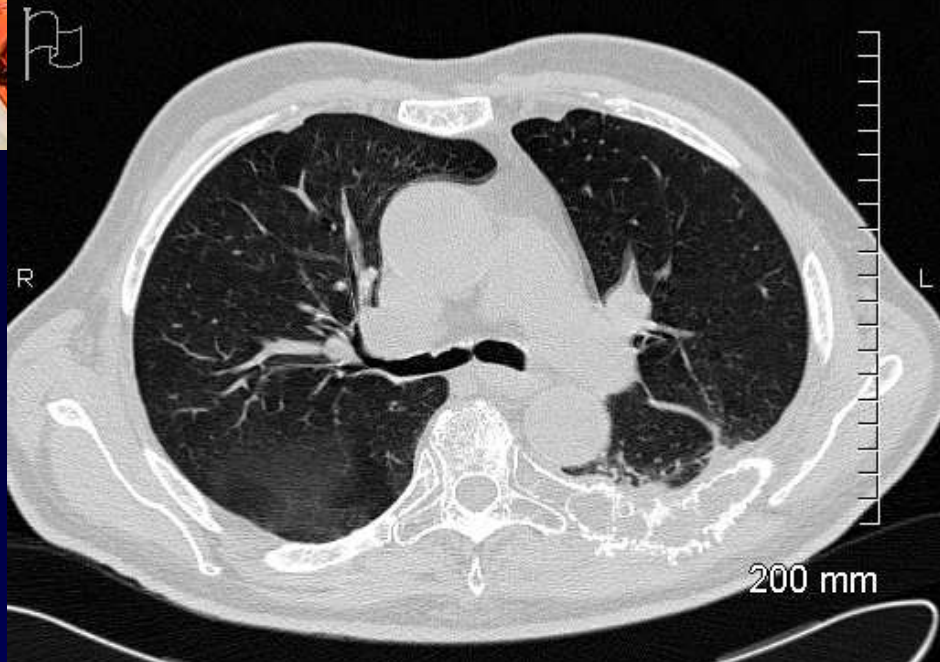

26-May-2009 11:21

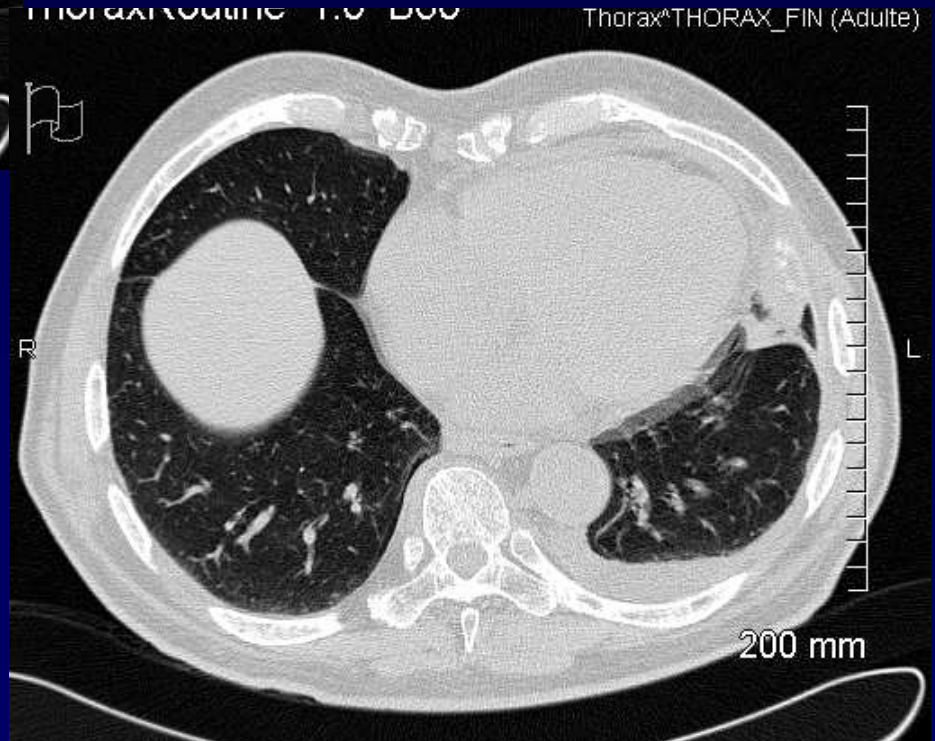
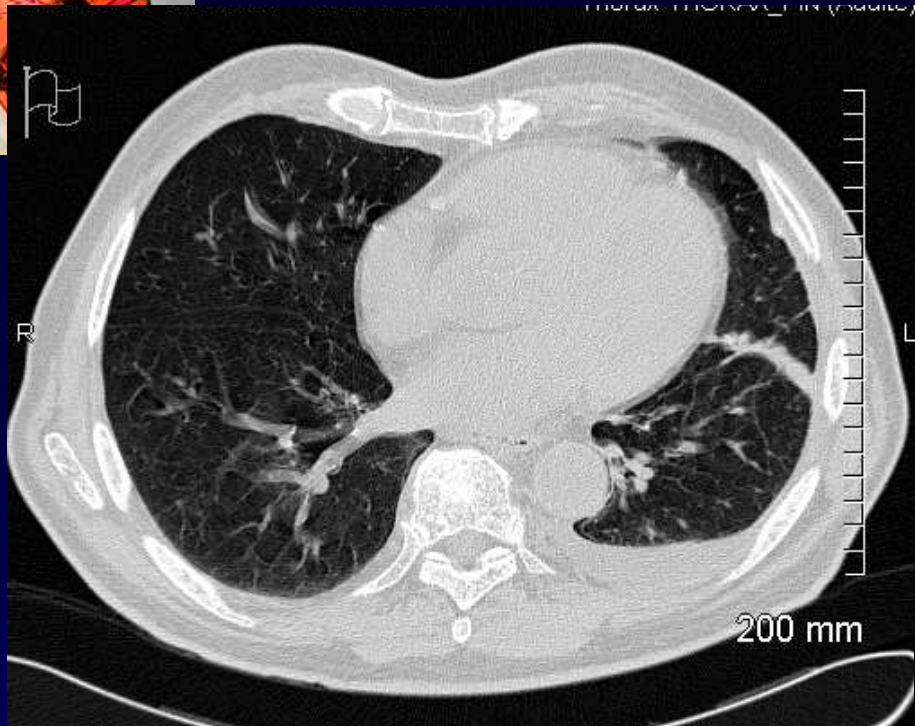







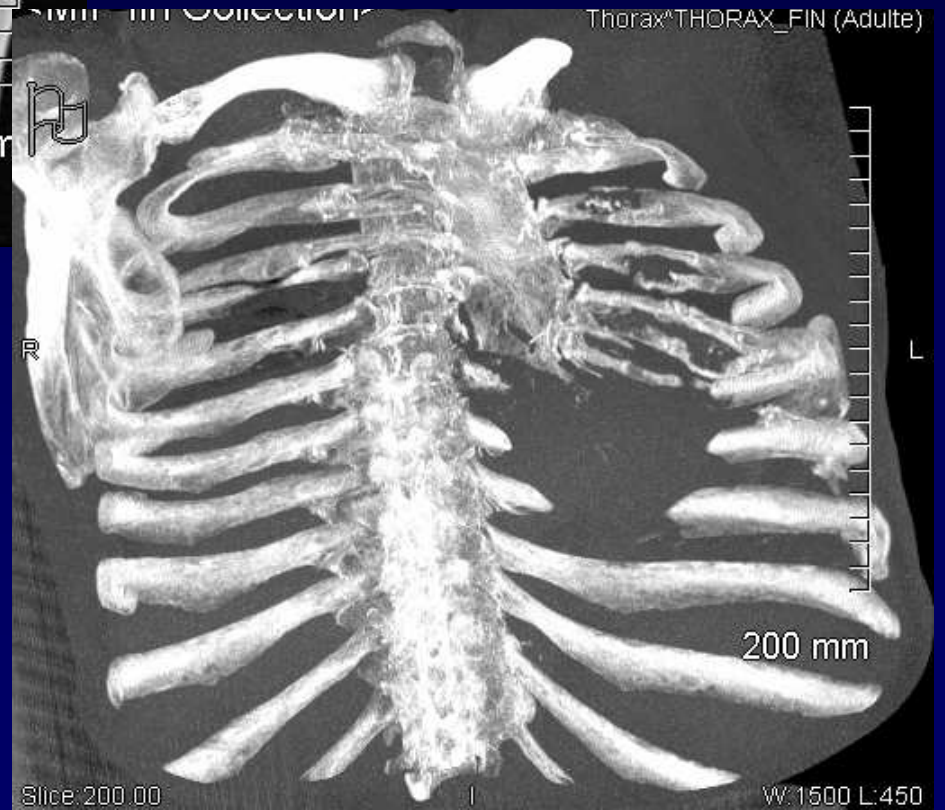
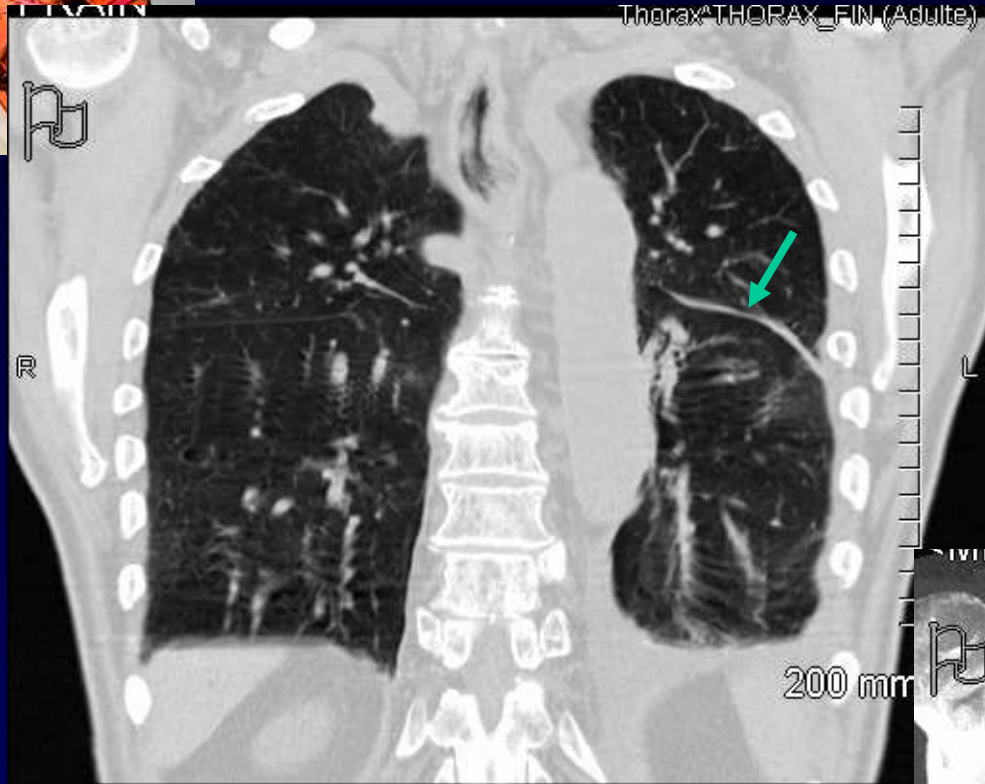








Diagnostic ?





Diagnostic

MYELOME MULTIPLE

COTES C5 C6 C7 ET AUTRES, RACHIS , SCAPULA...

**PLEURESIE MYELOMATEUSE
RECIDIVANTE TALQUEE**



Discussion

La pleurésie myélomateuse est rare, récidivante, nécessitant souvent un talcage.