

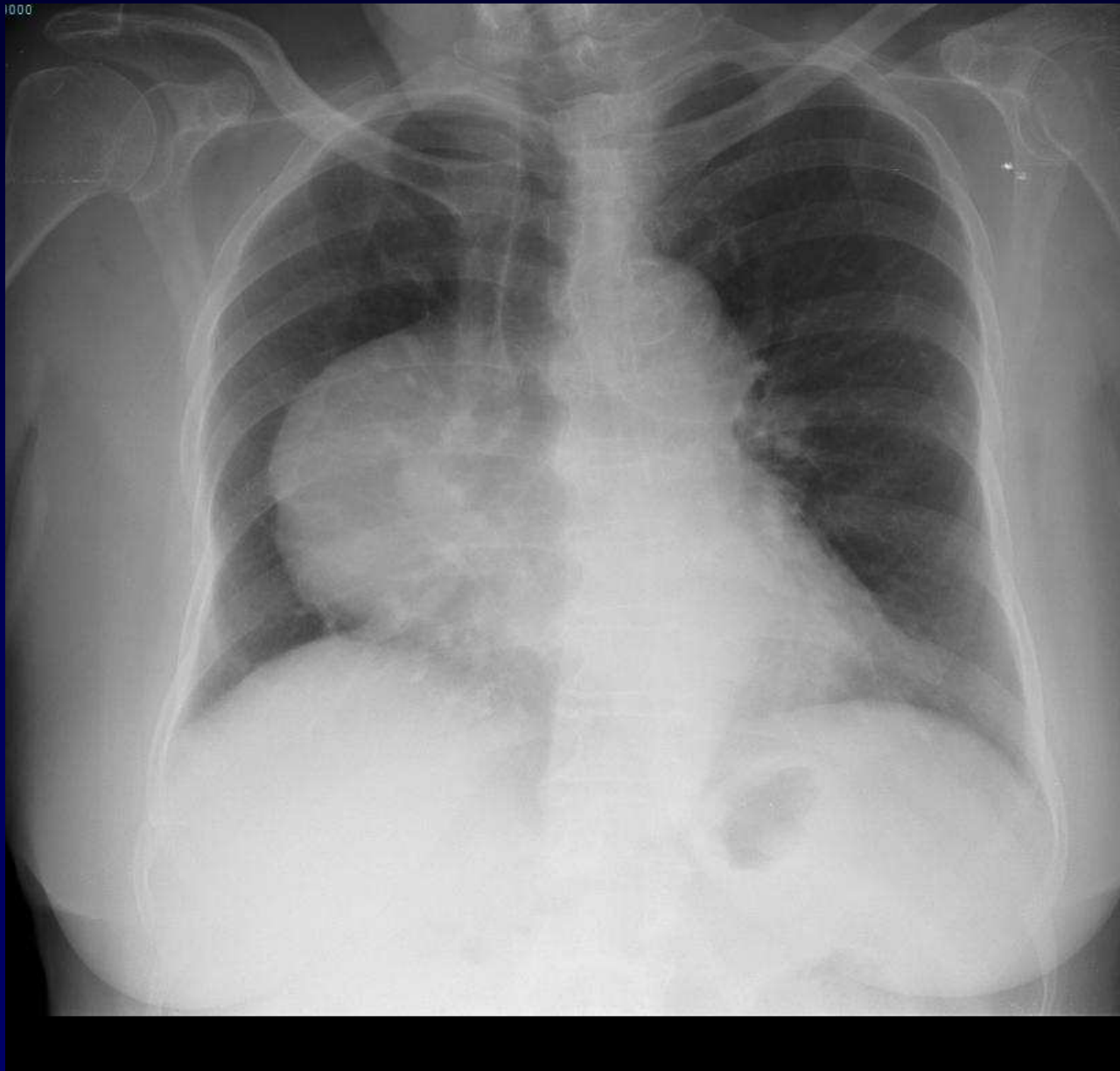


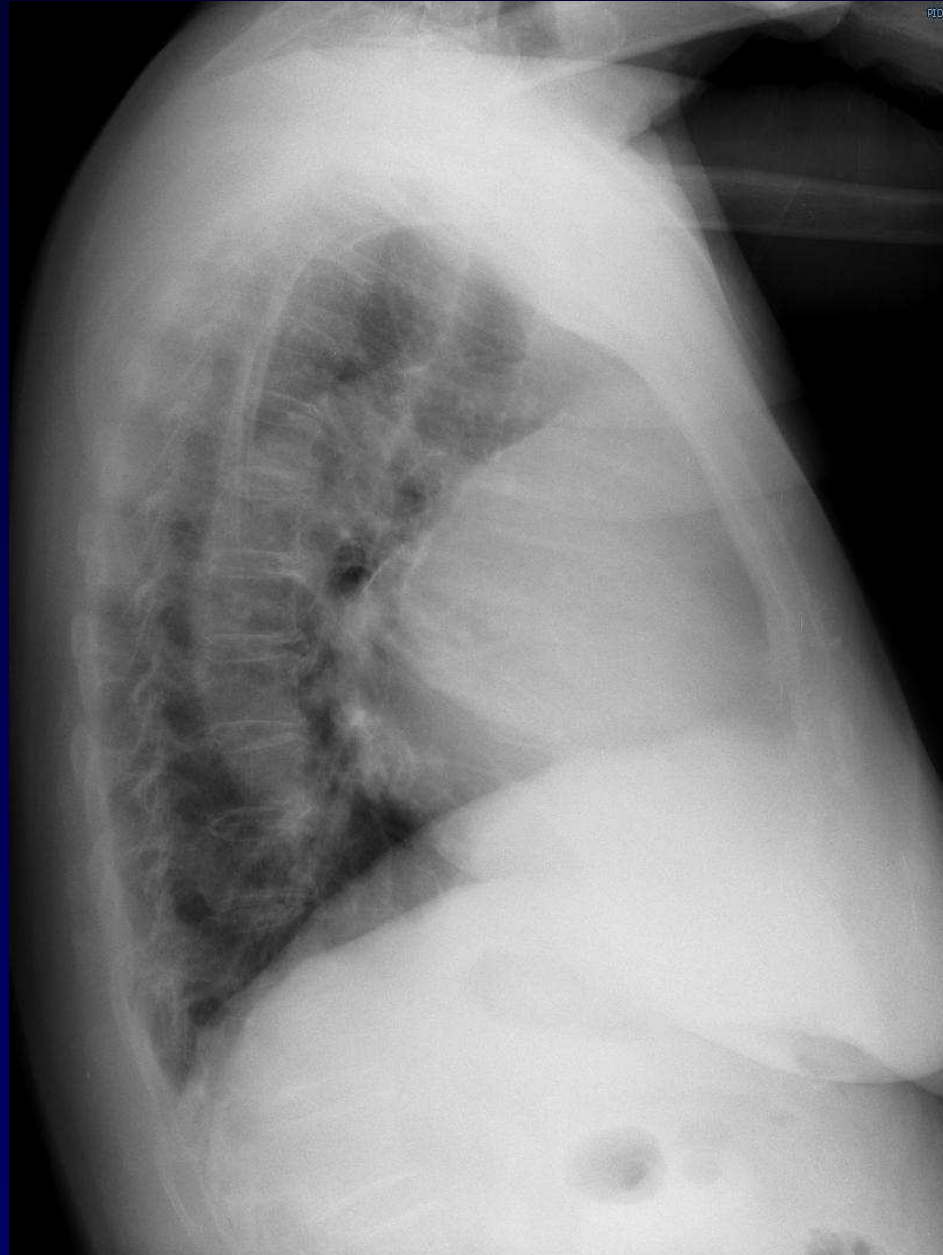
L Metge

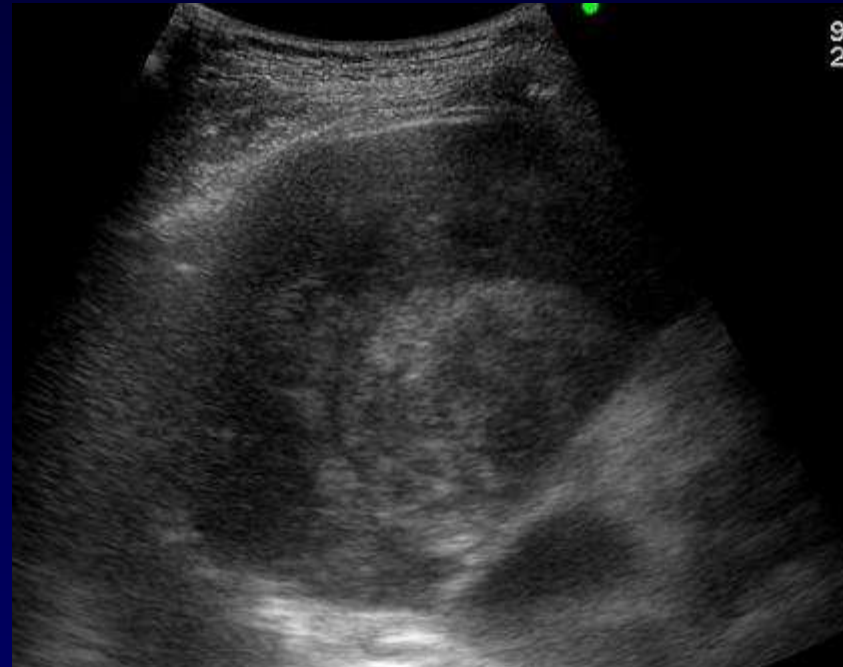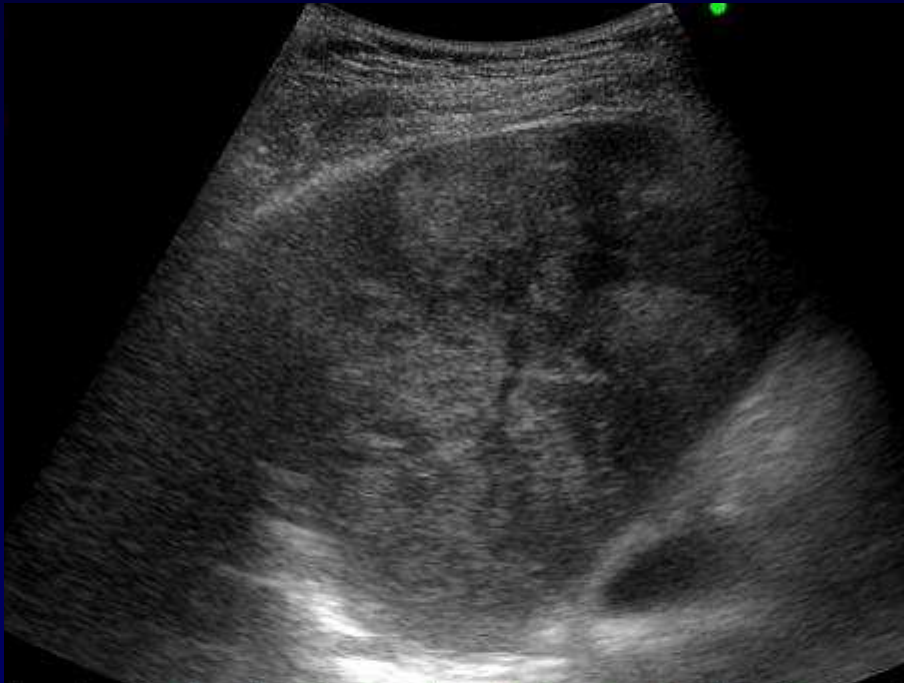Femme de 76 ans,

Malaise

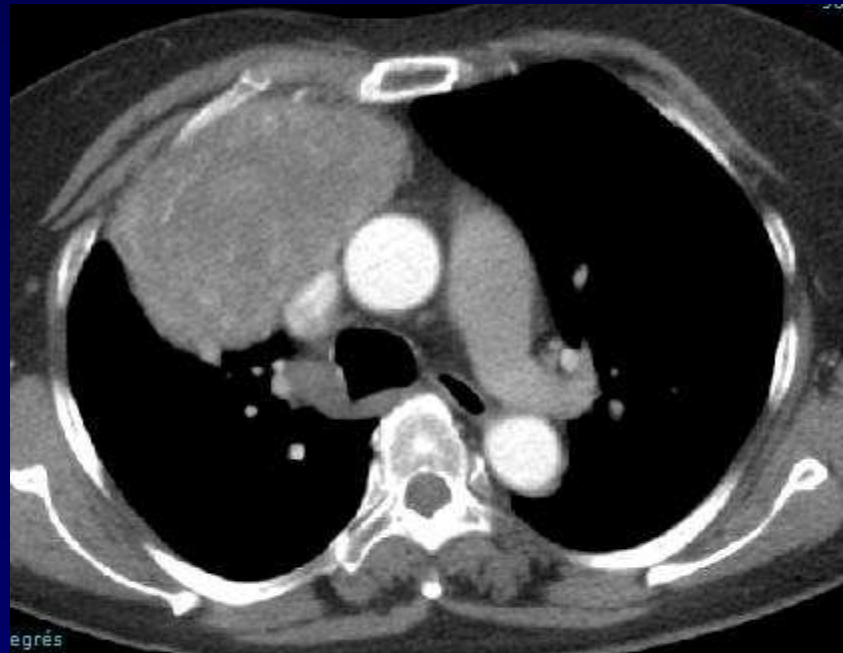
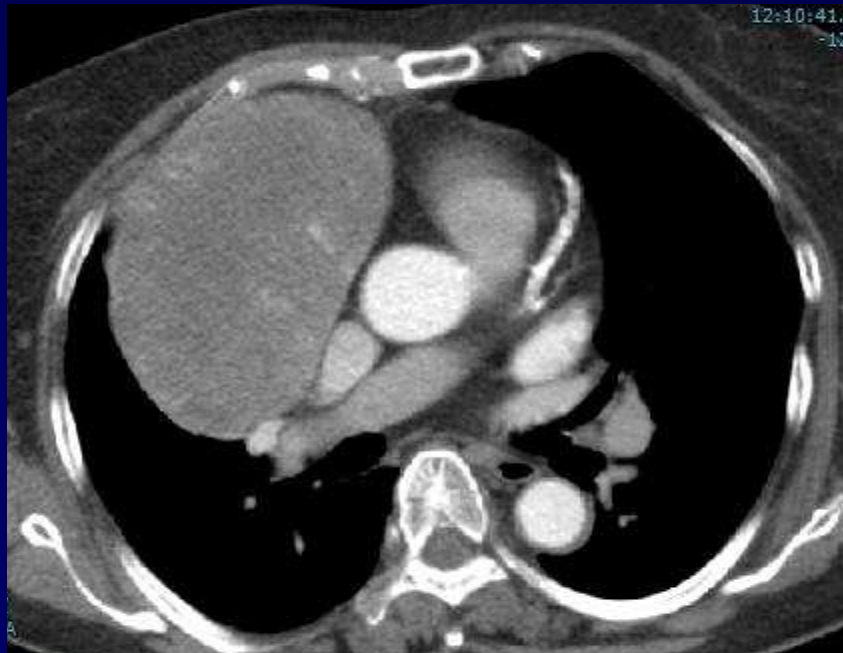
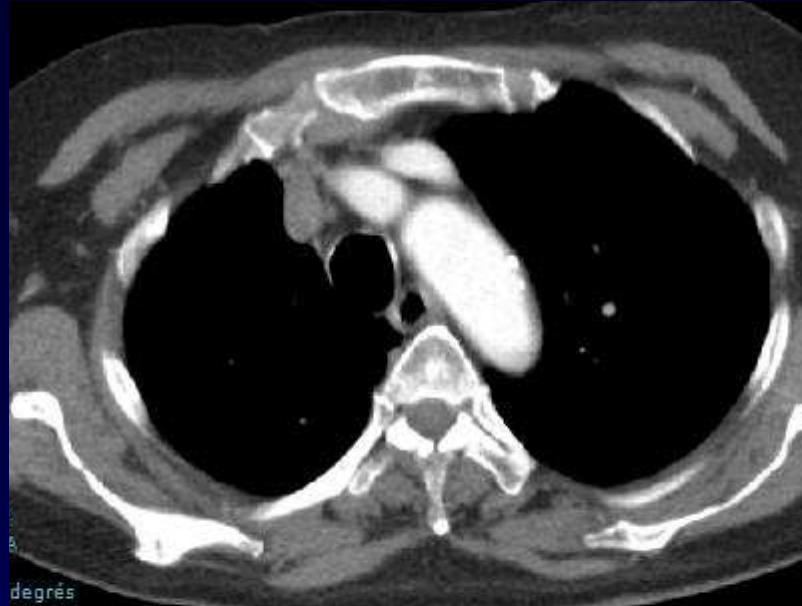
Décompensation de diabète

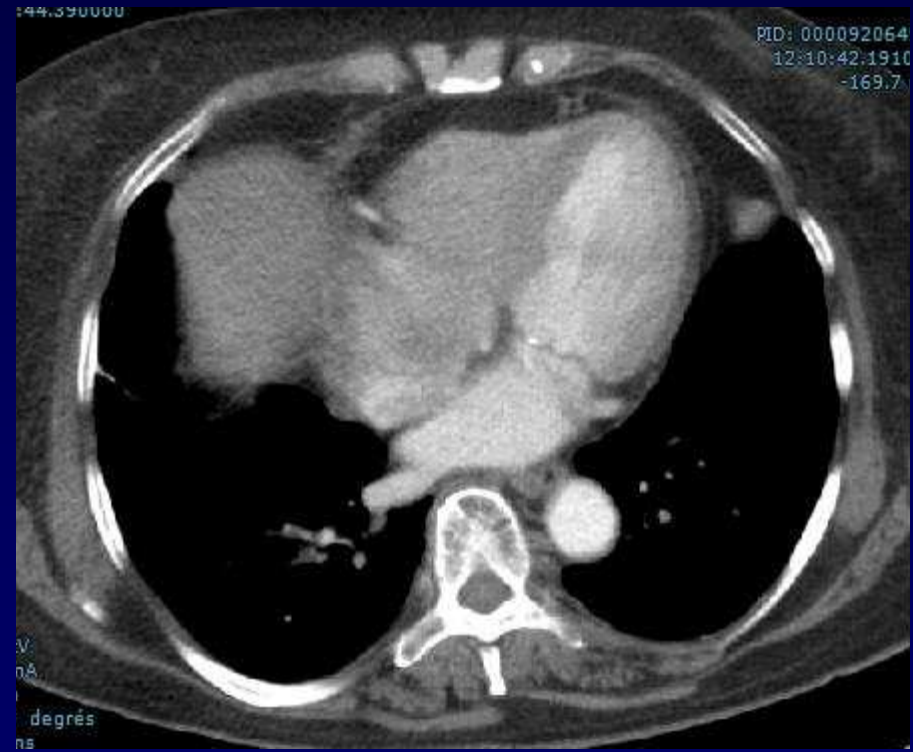
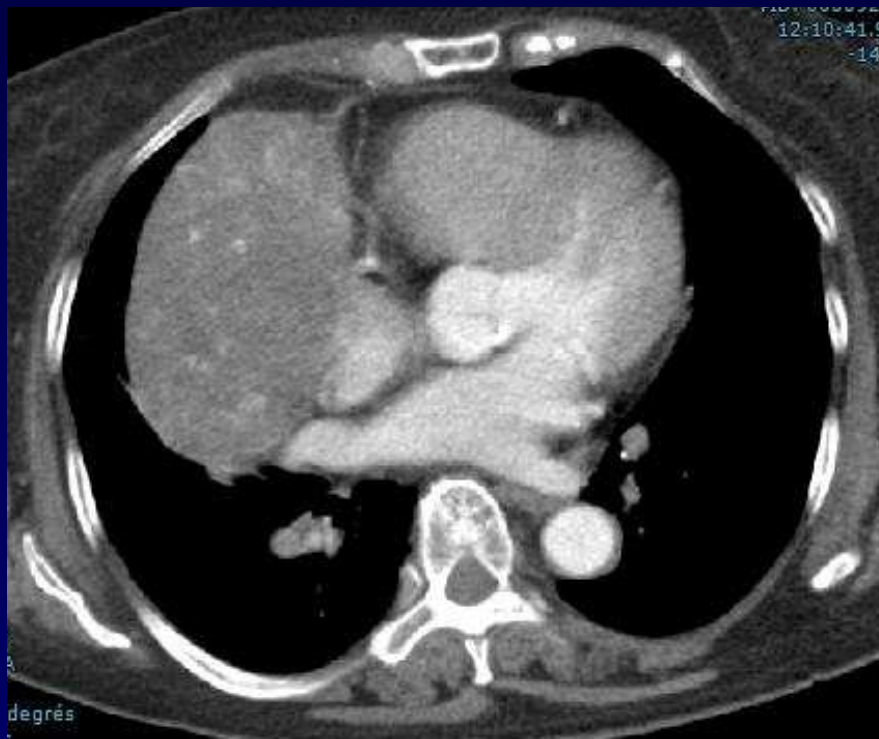


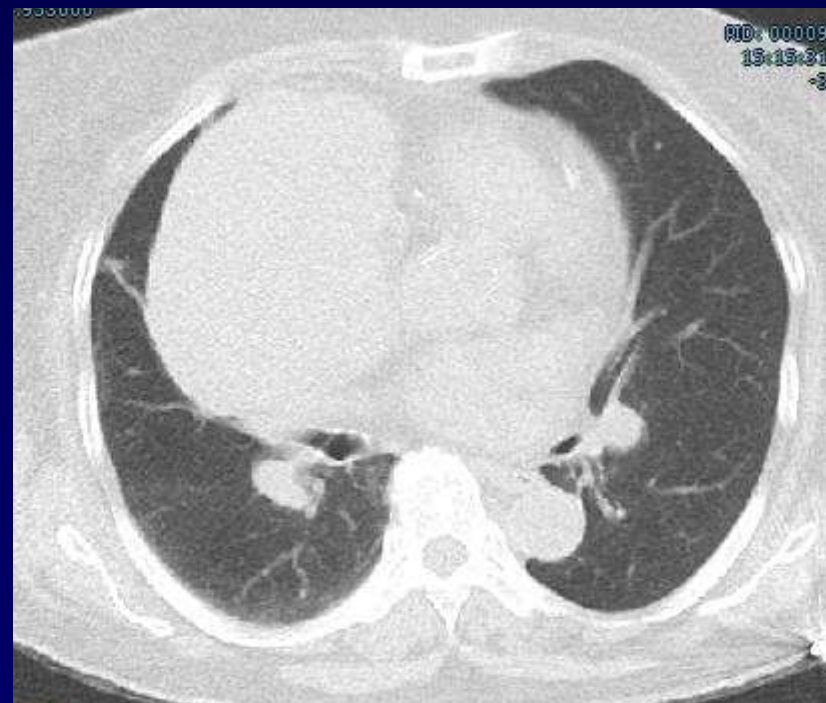
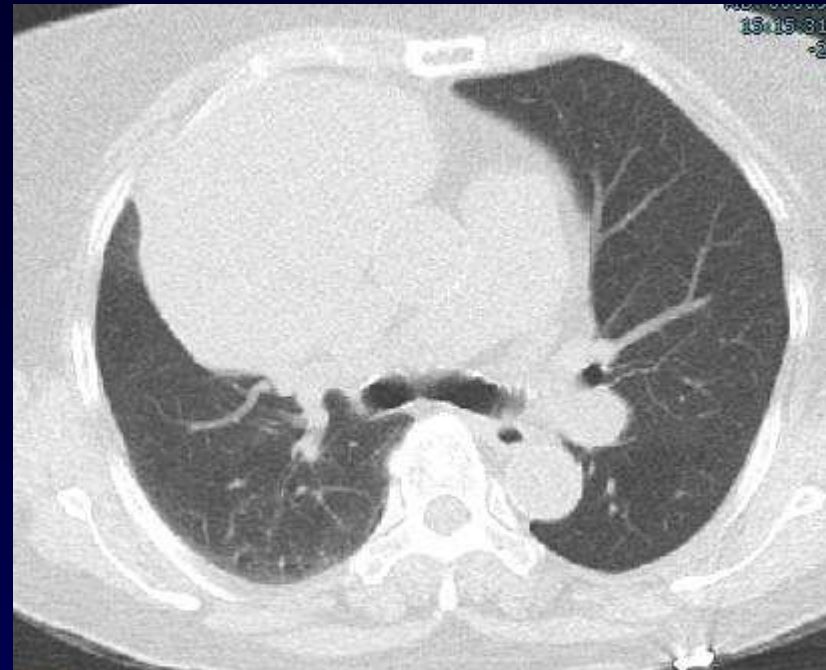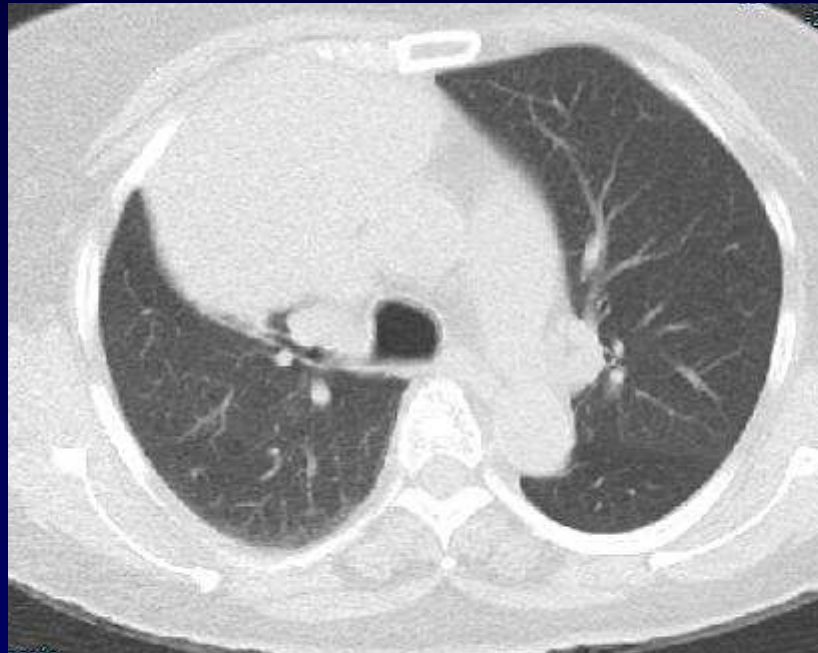




Echographie : Masse échogène hétérogène

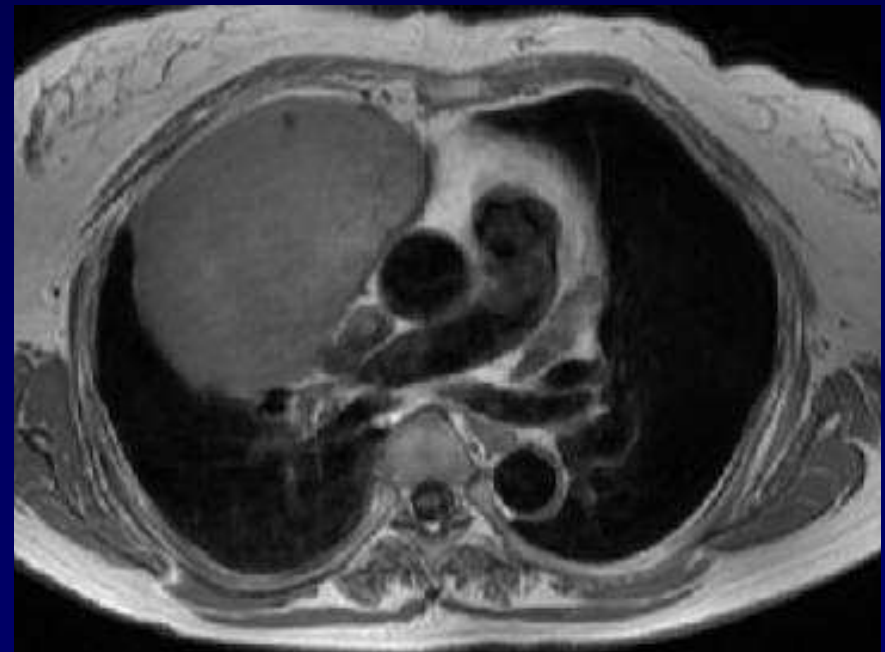
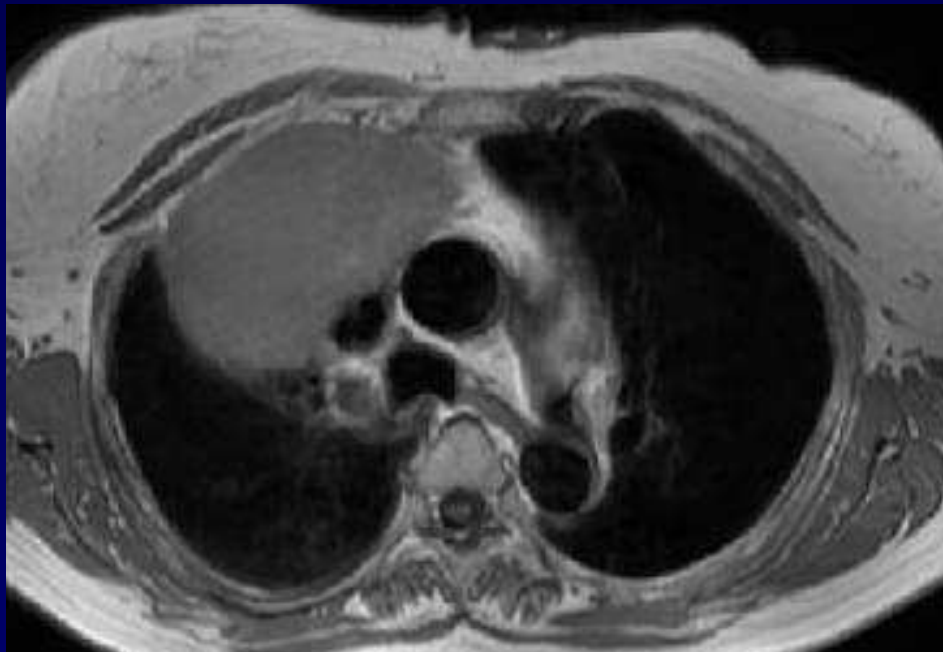
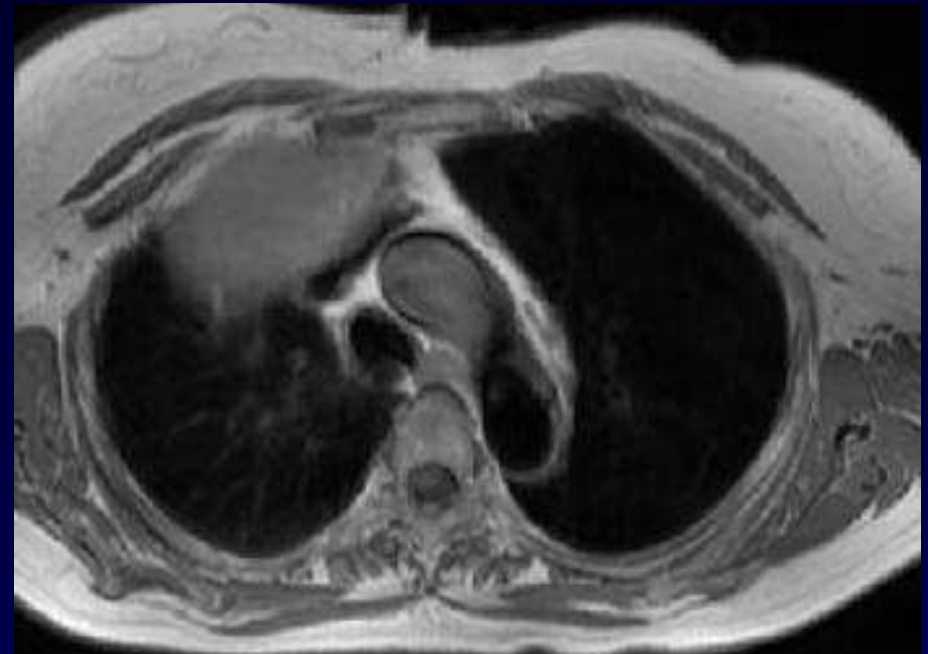




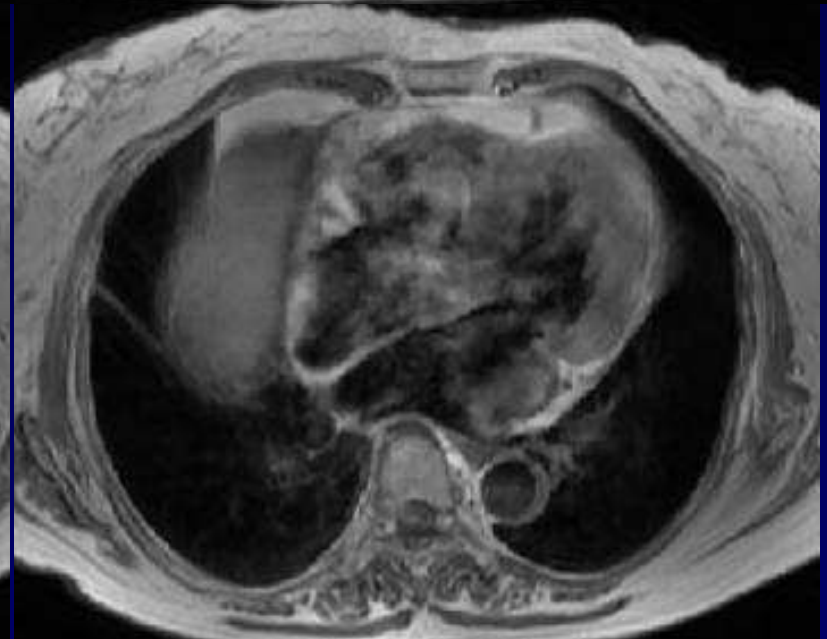
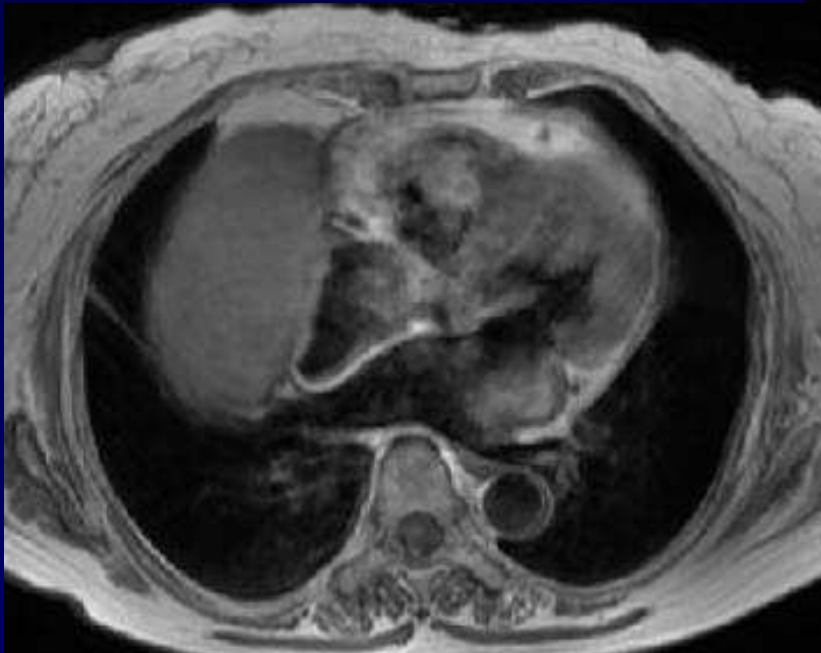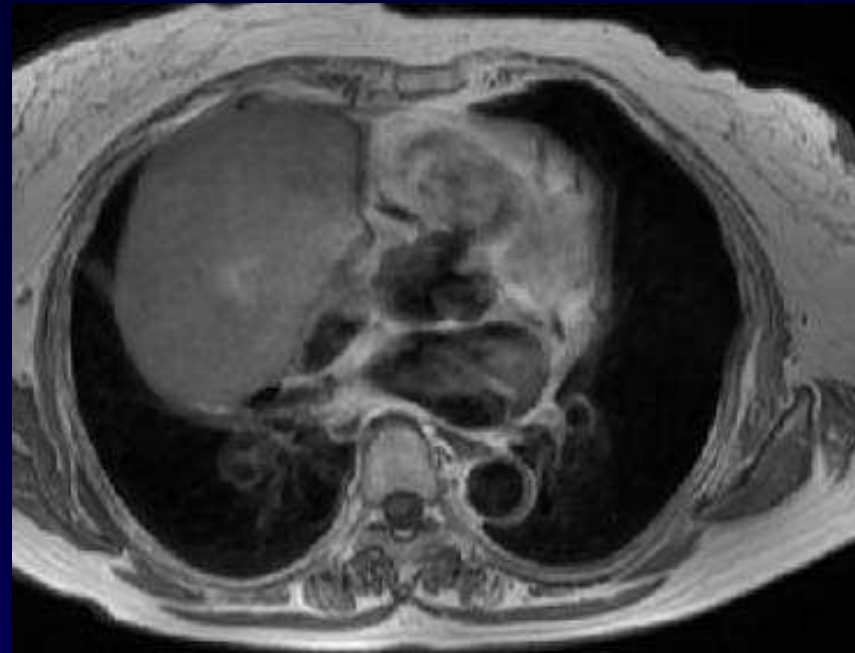


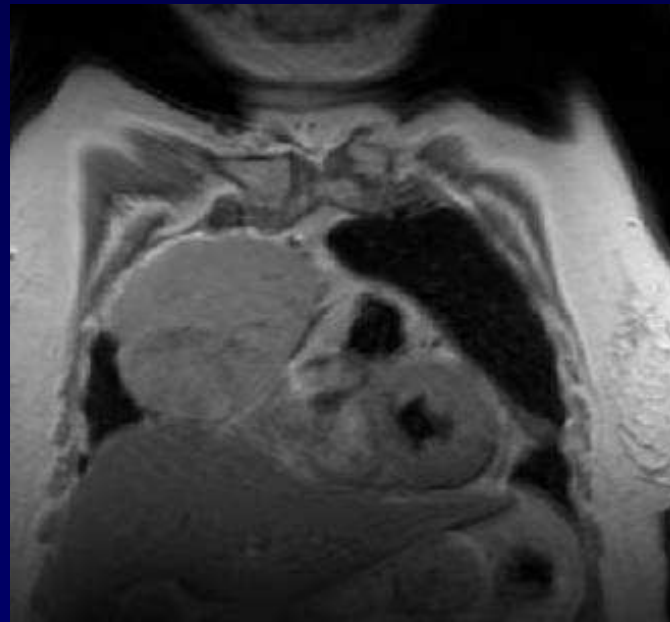
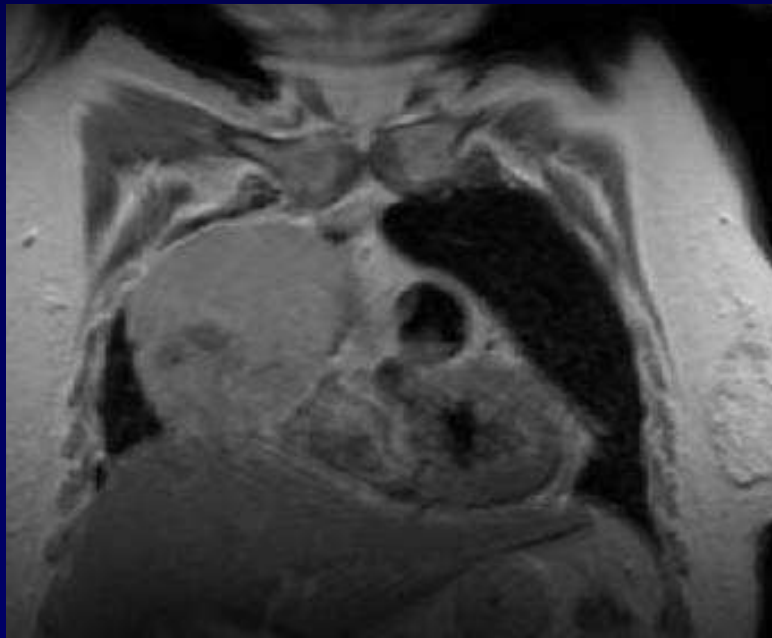
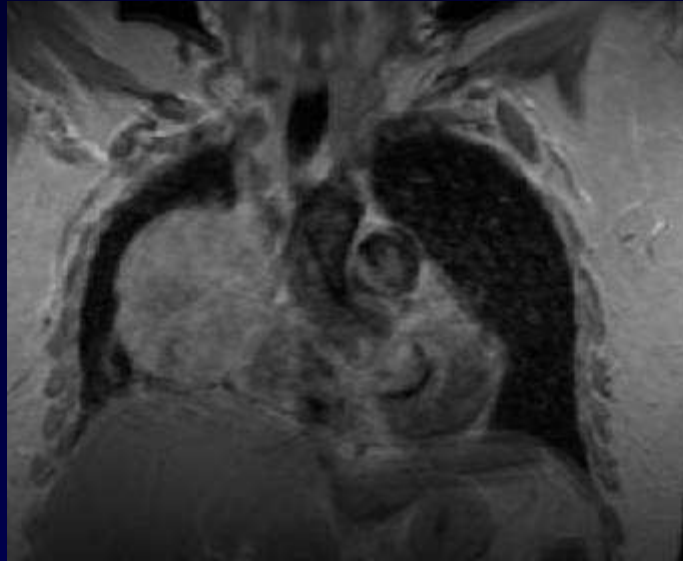
IRM / T1 ES

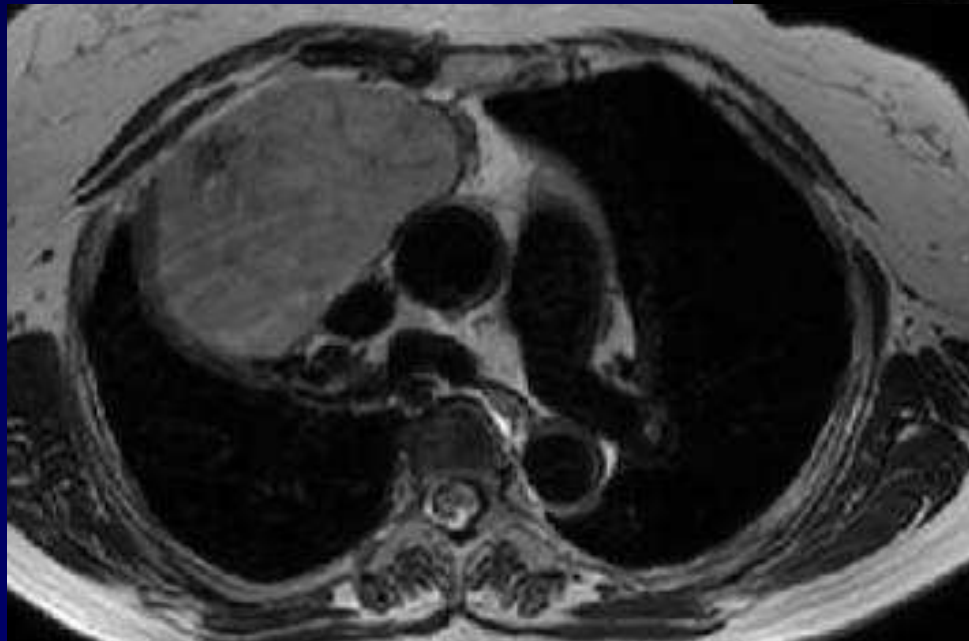
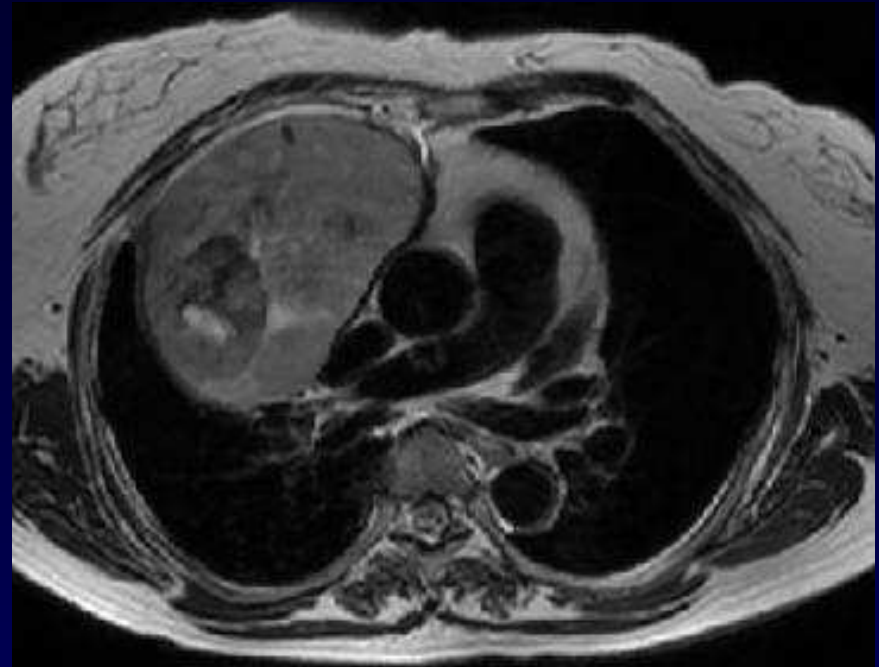
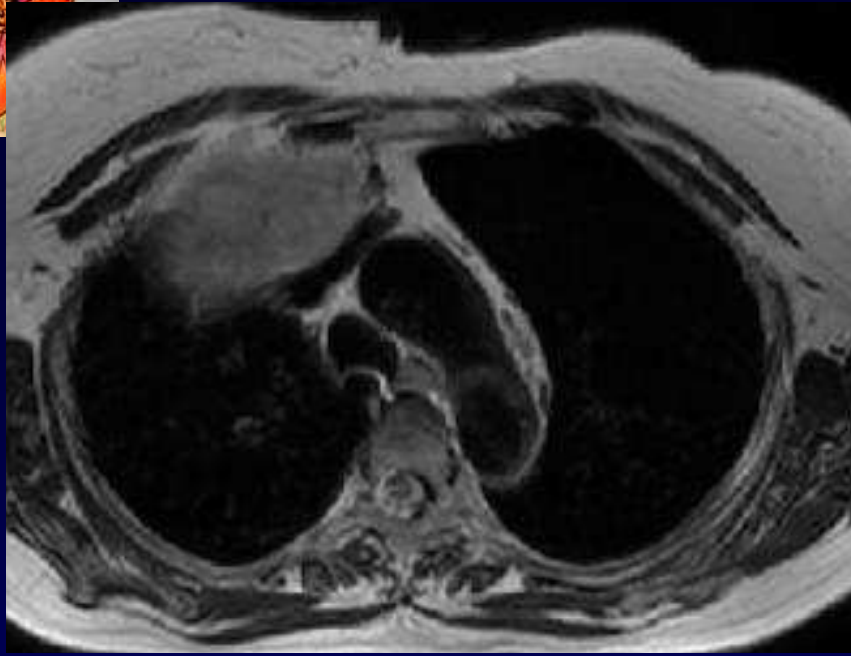
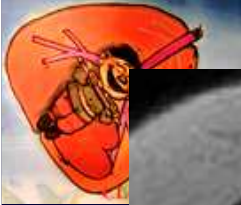



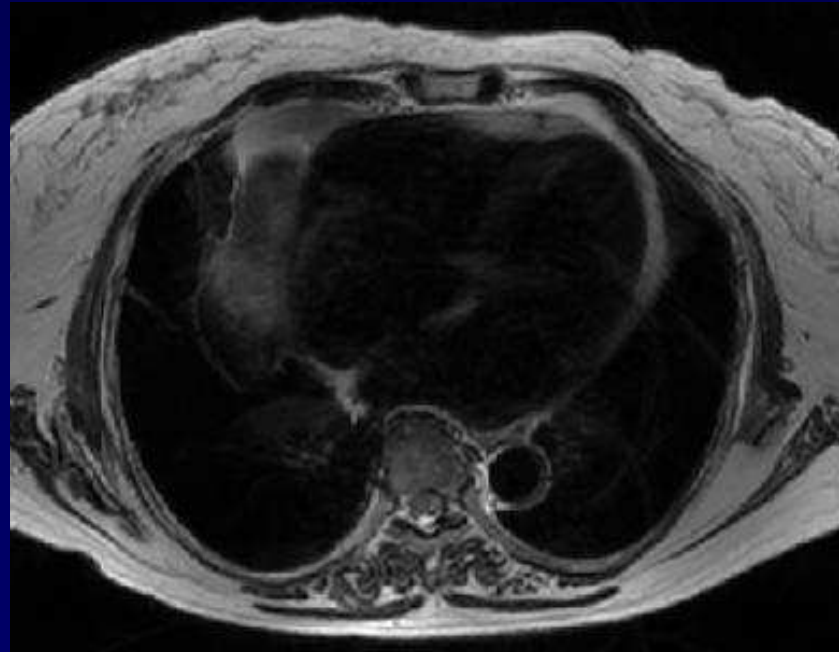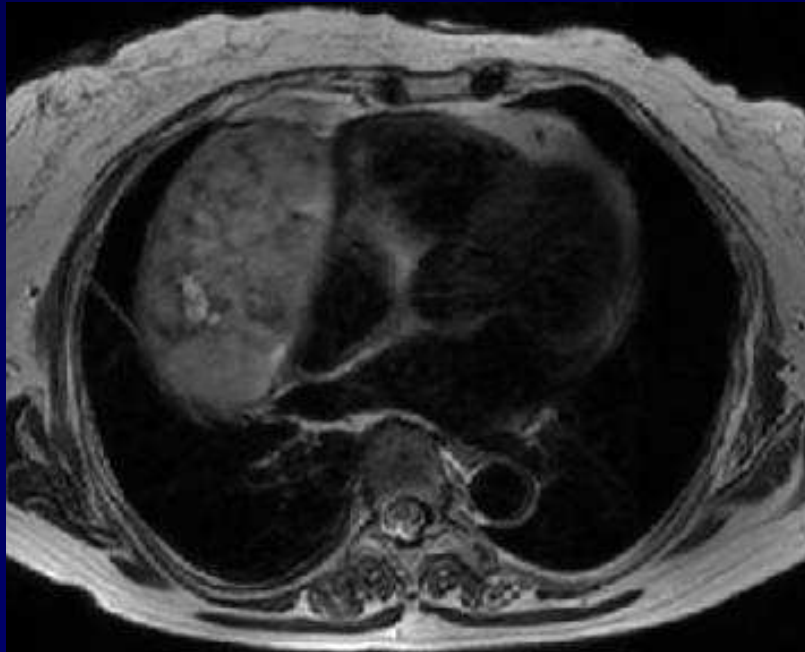
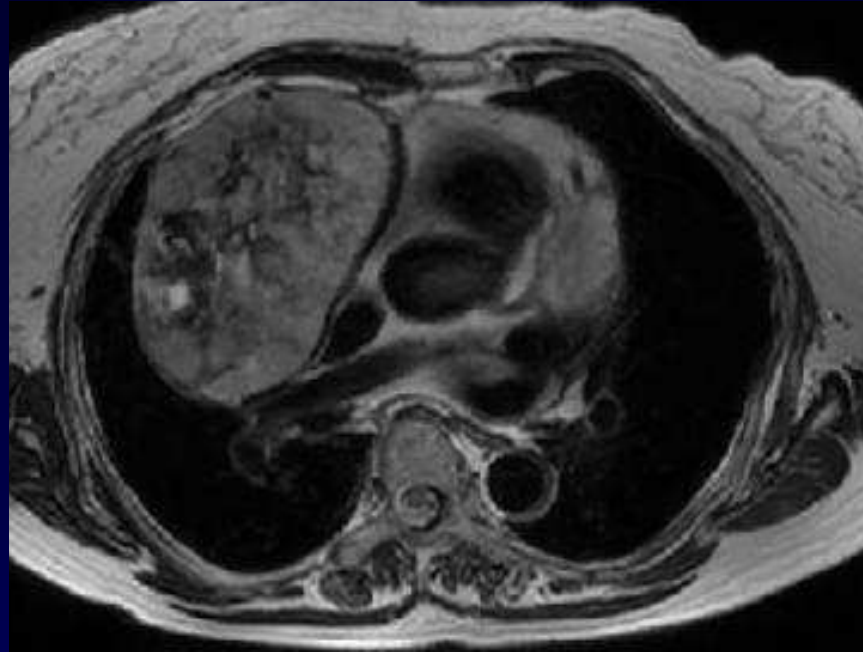
T1 ES







T2 ES





Diagnostic ?



Diagnostic

Thymome de révélation fortuite : masse du médiastin antérieur, hétérogène

Confirmation diagnostique par biopsie sous scanner

Imagerie complète pour bilan pré-chirurgical