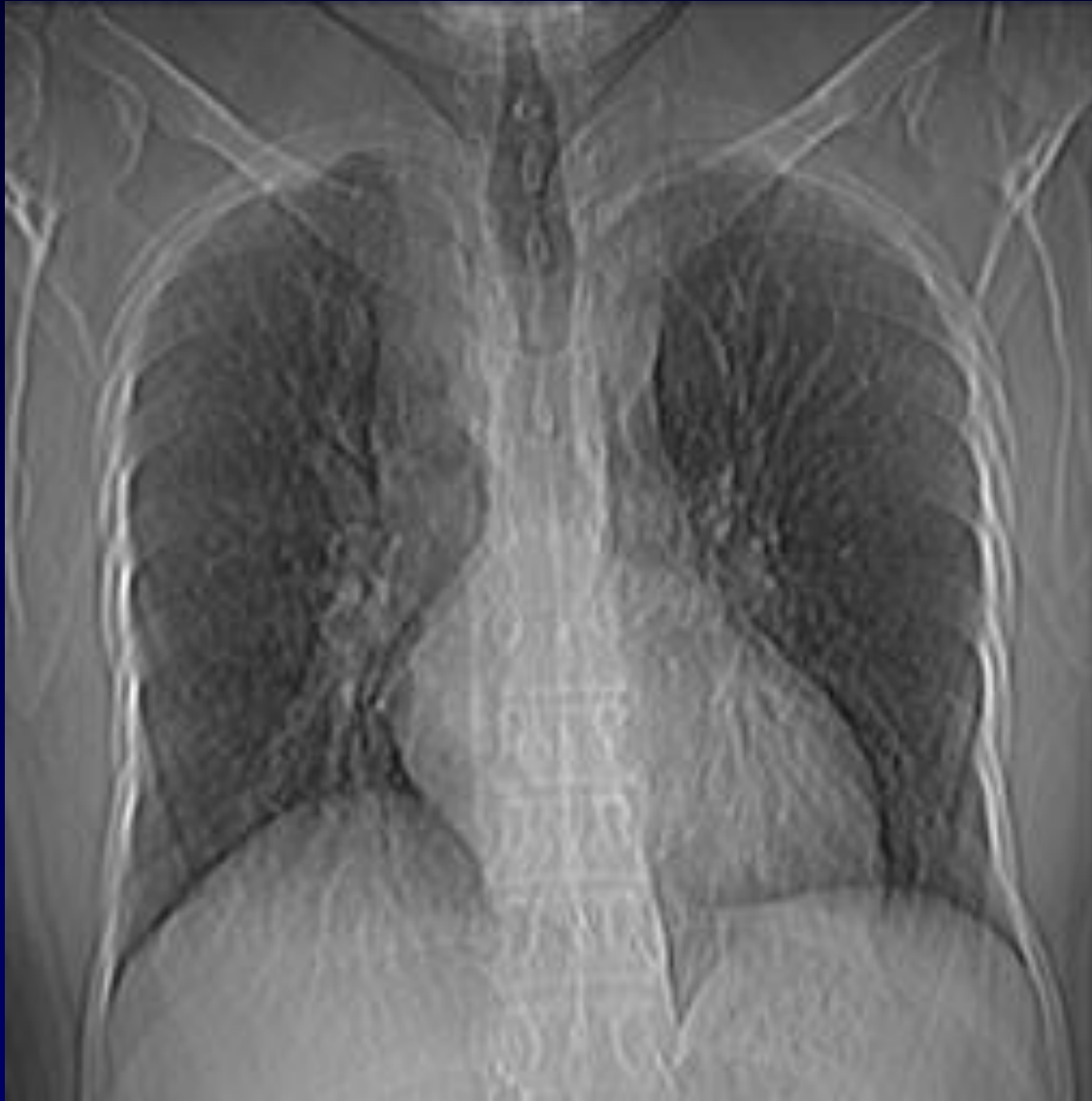



**M EL HAJJAM
P LACOMBE**

Homme de 53 ans

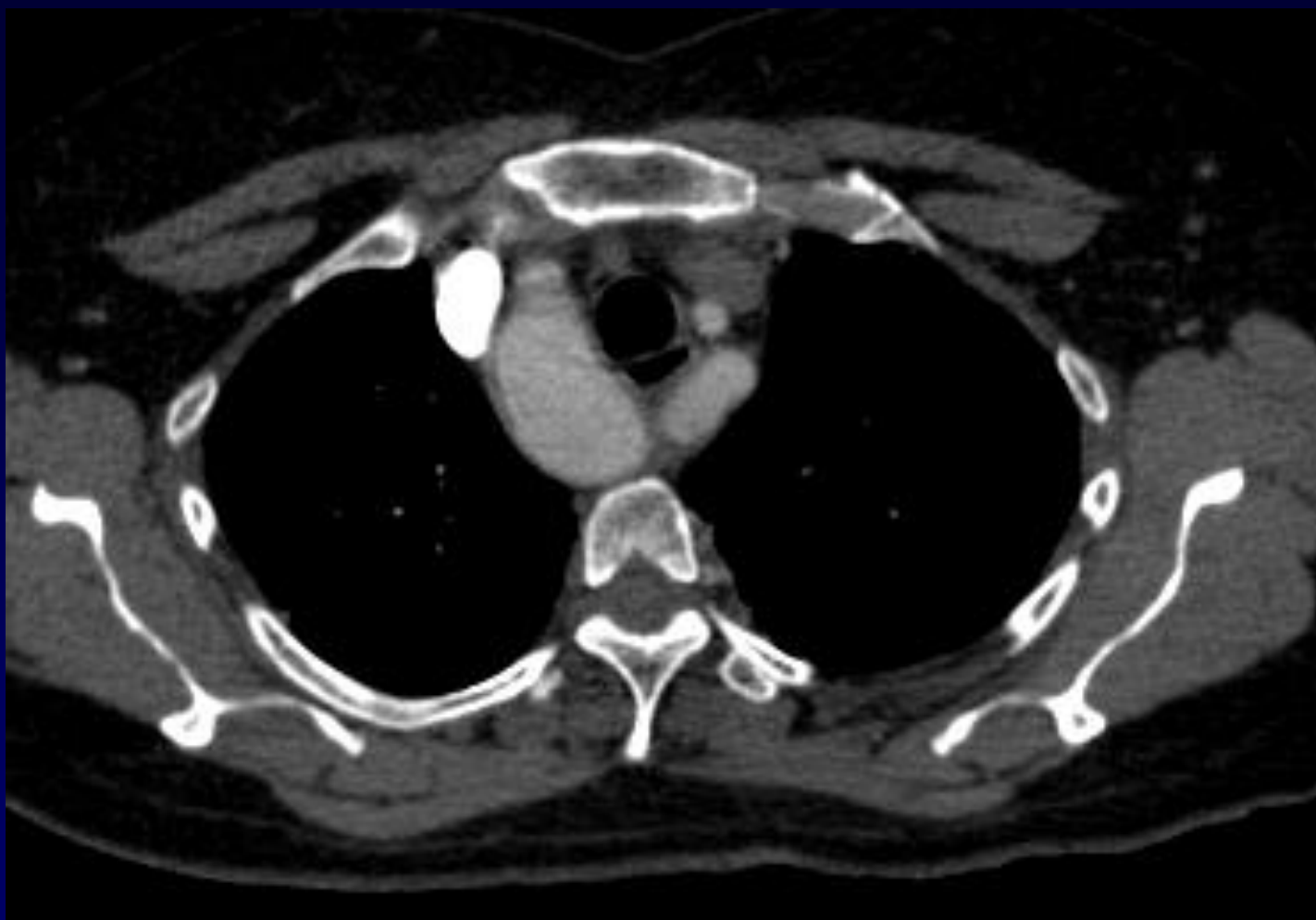Douleurs thoraciques.

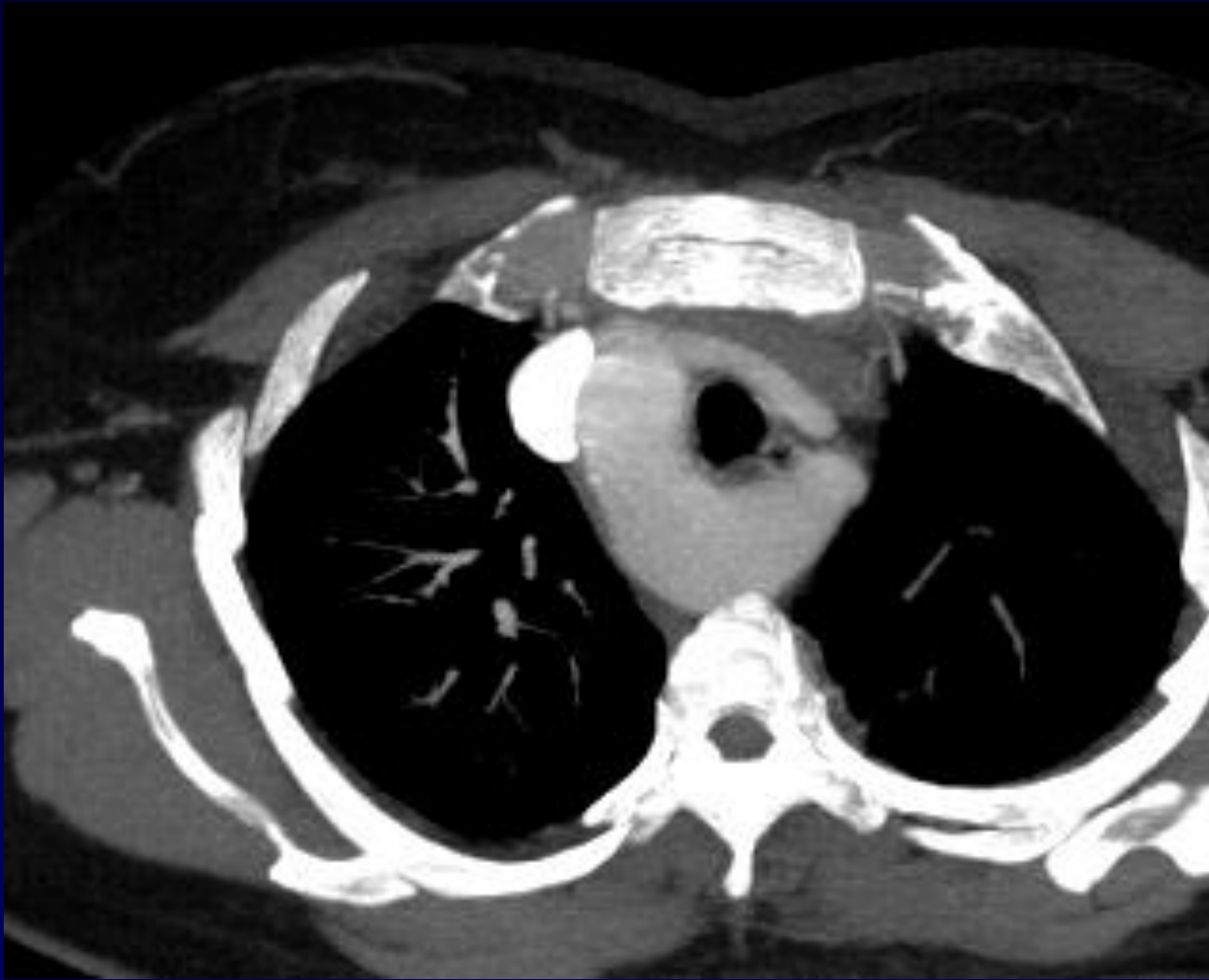
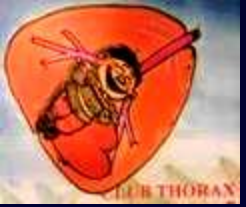

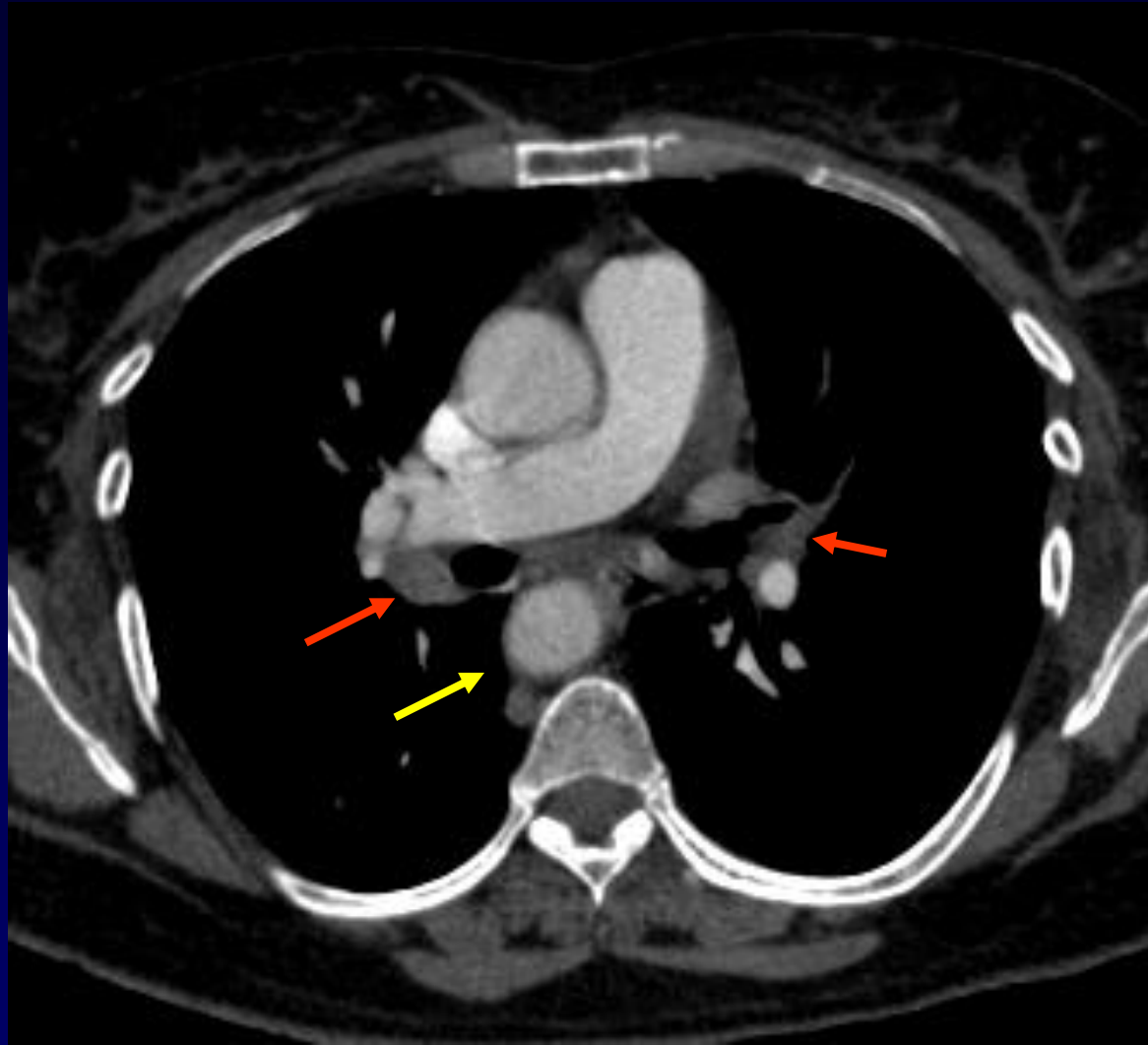
Scout view

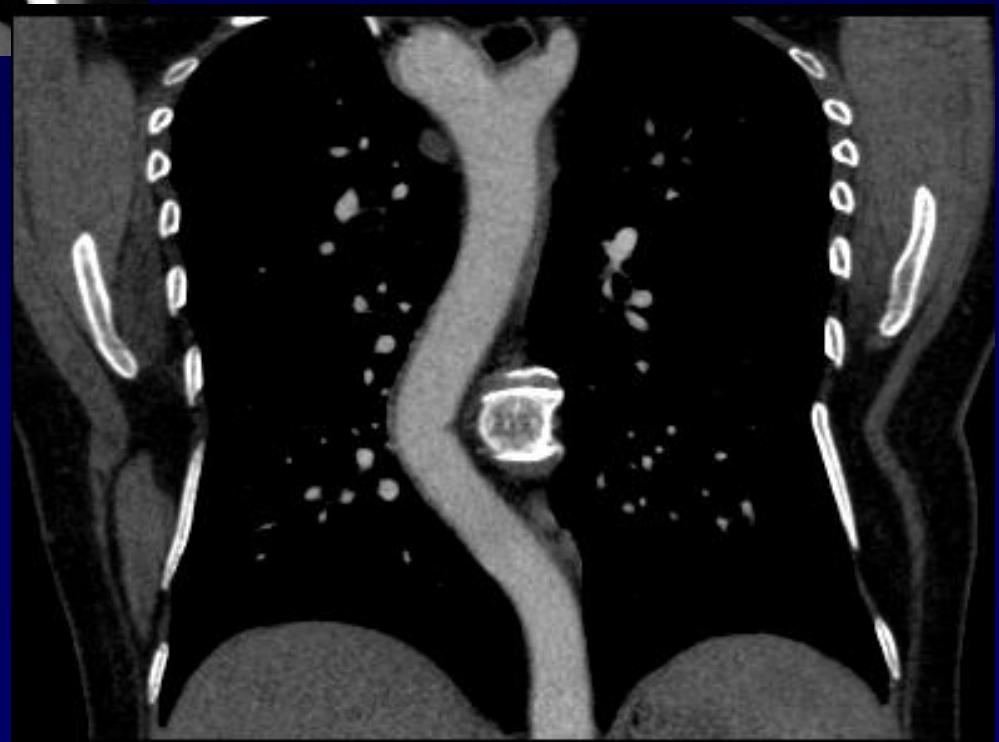
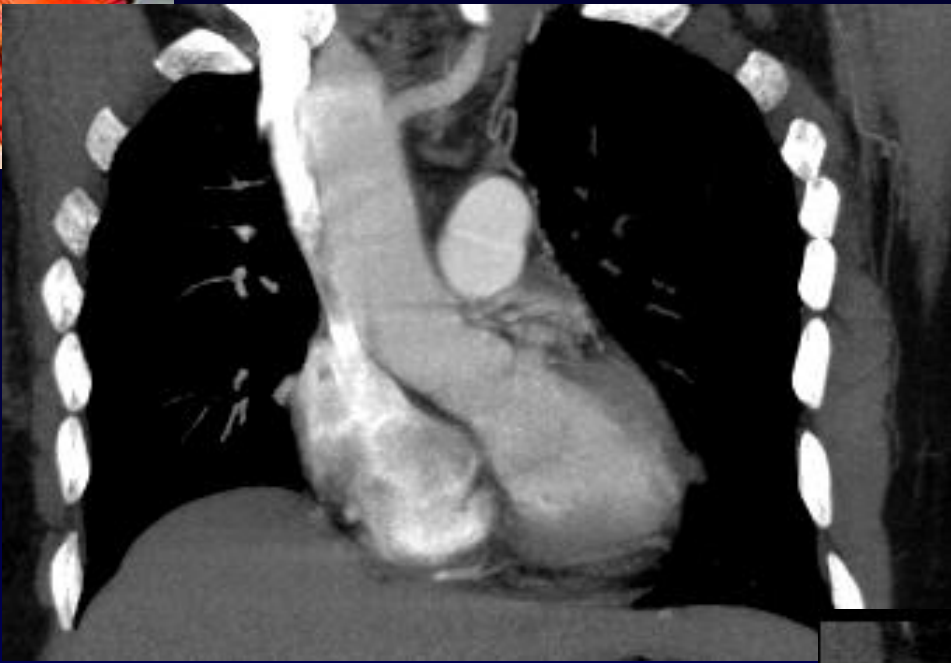
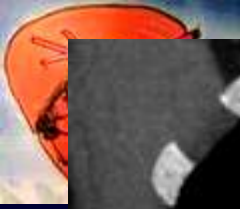

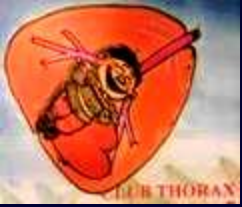Diagnostic ?











Diagnostic

Arc aortique droit avec artère sub-clavière gauche aberrante (flèche)

+ Sarcoidose

