

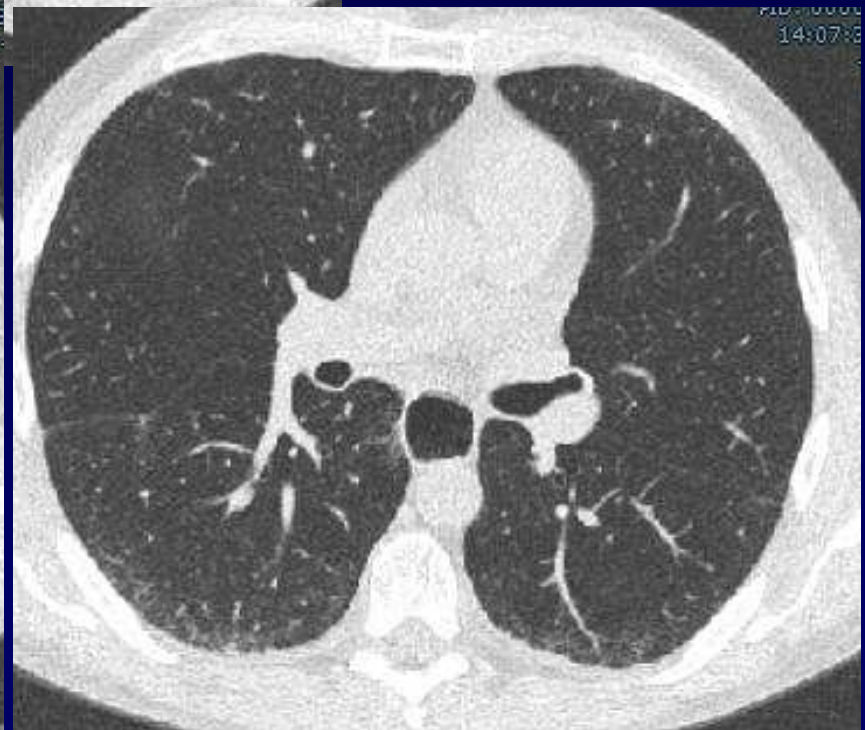
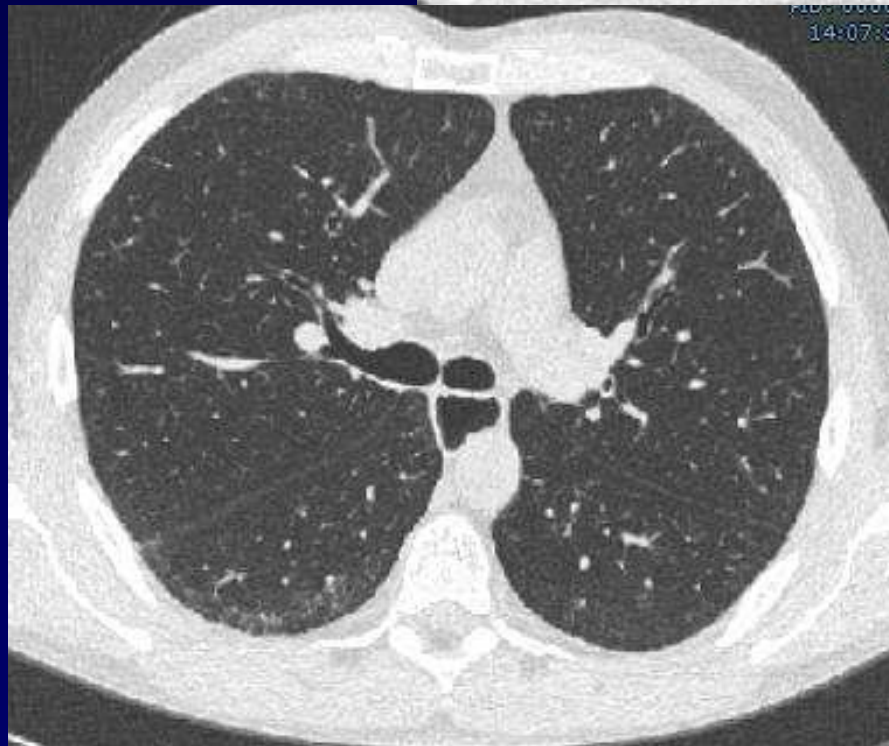
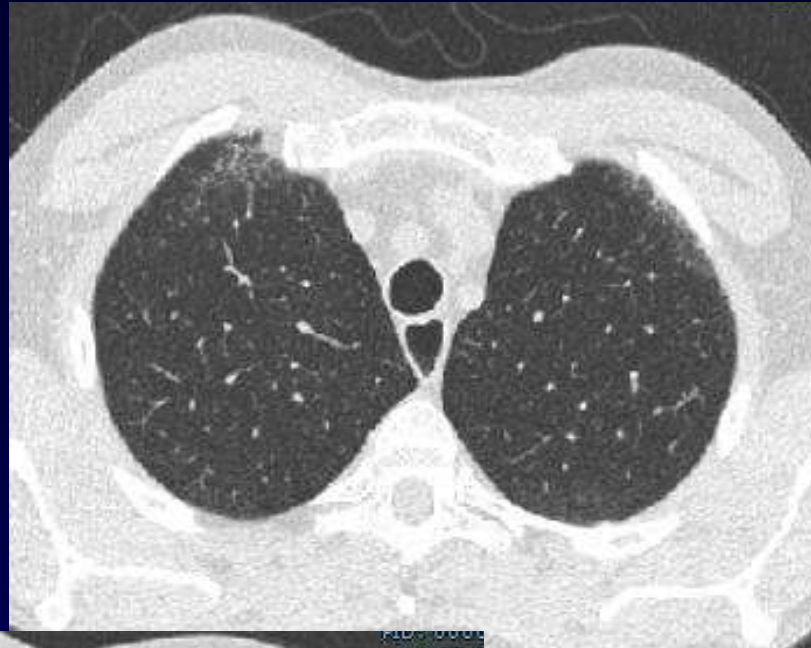

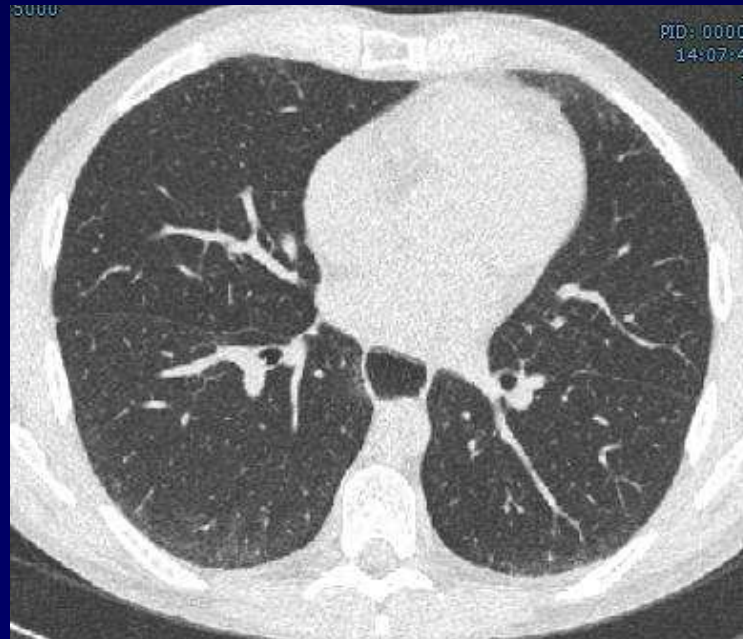
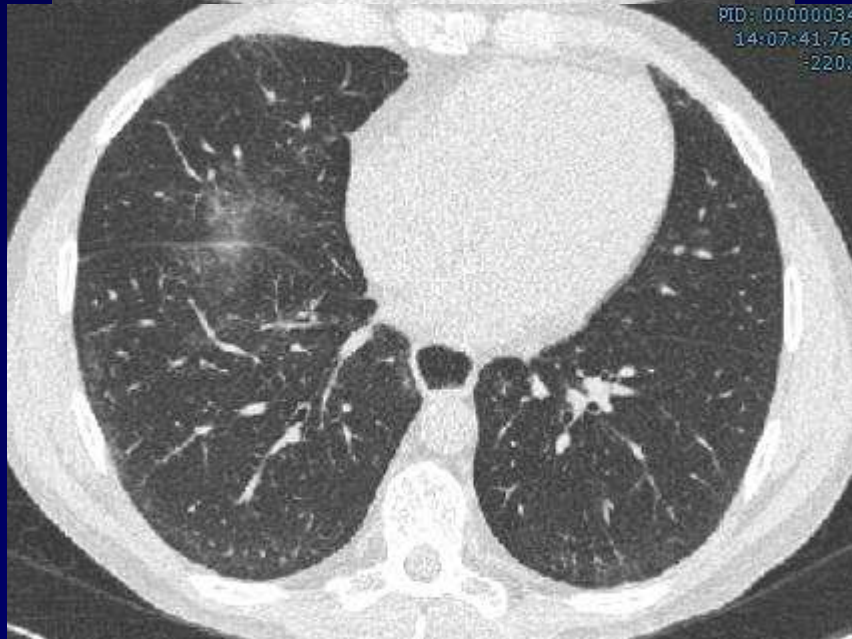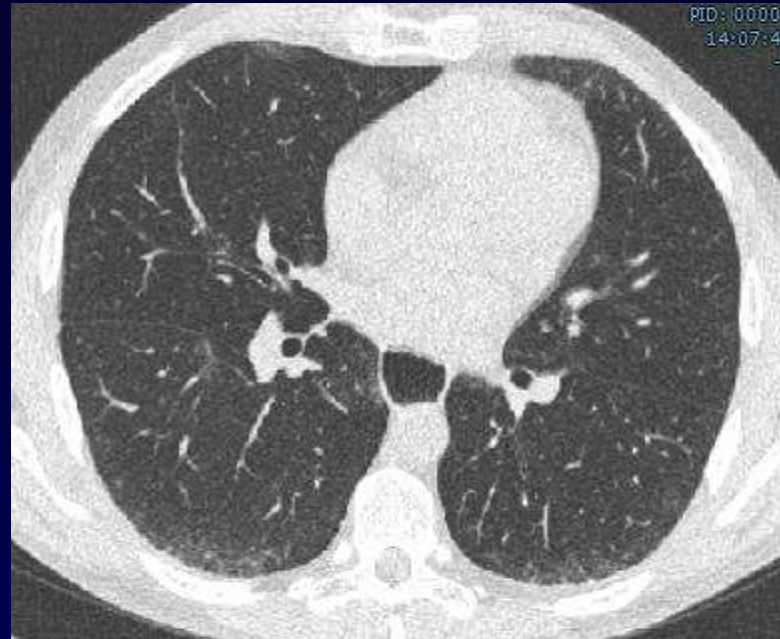
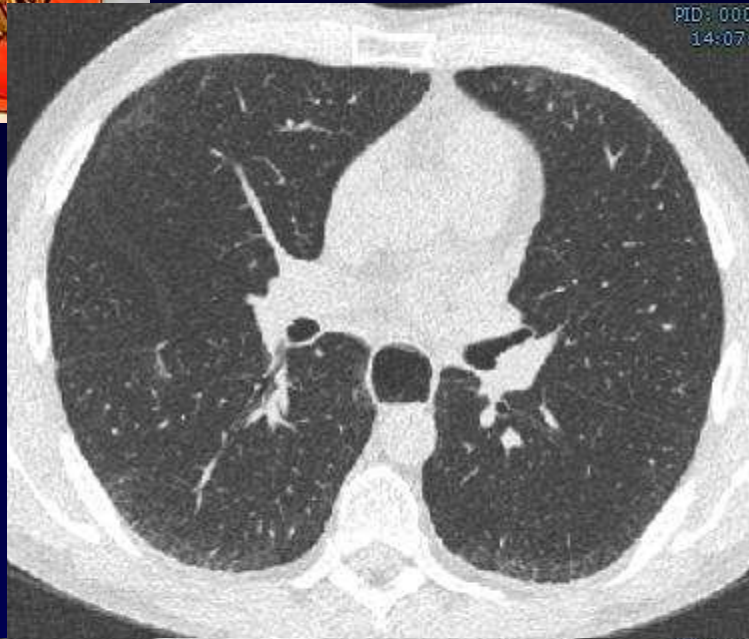

L Metge

Homme de 48 ans

Dyspnée

Suivi de maladie connue





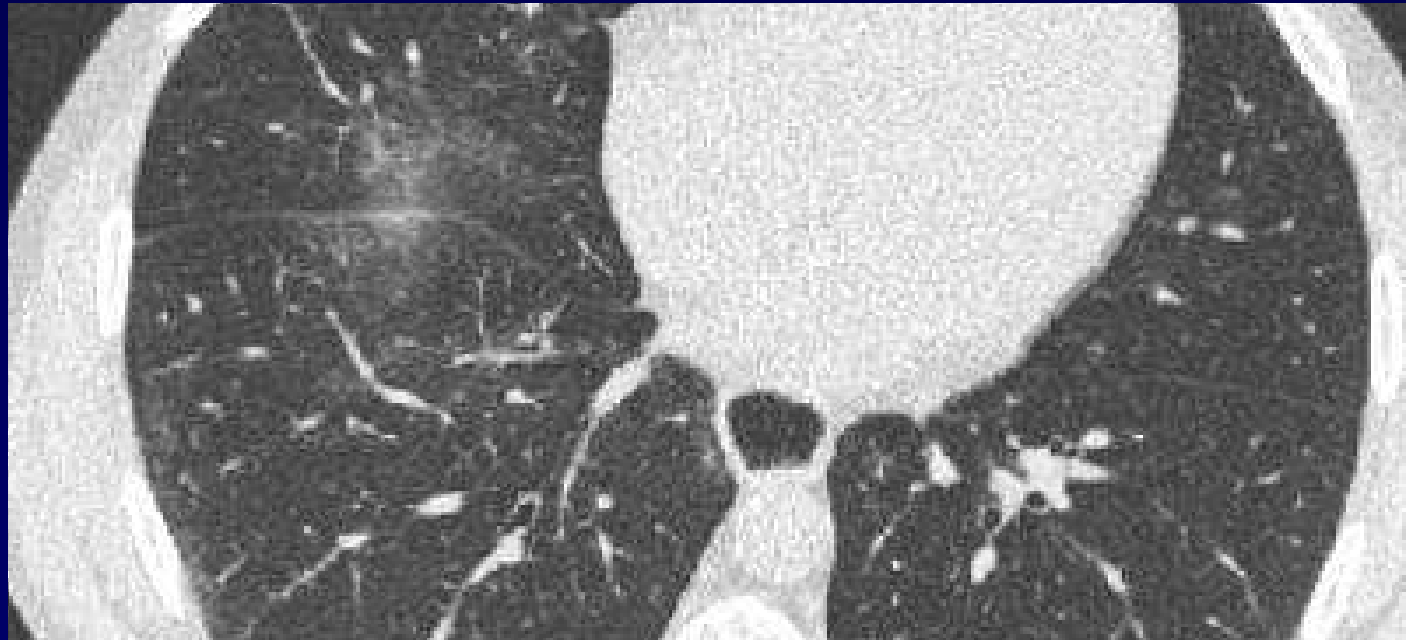
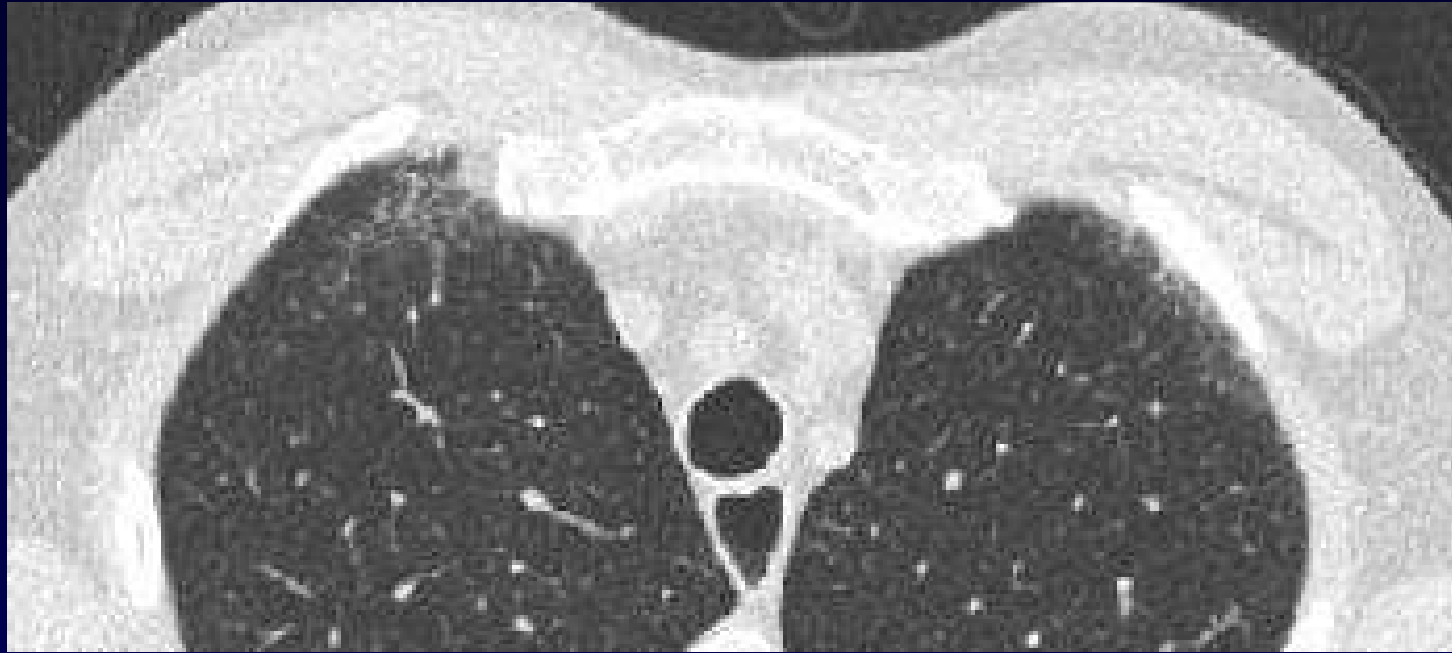

Diagnostic ?



Diagnostic

Sclérodermie systémique





Discussion

- Aspect de pneumopathie interstitielle avec fines réticulations intra-lobulaires
- Distorsion scissurale (fibrose)
- Dilatation oesophagienne

Ici, pas de signe d'hypertension artérielle pulmonaire (HTAP)