



M EL HAJJAM
P LACOMBE

Femme de 48 ans

Douleurs thoraciques droites

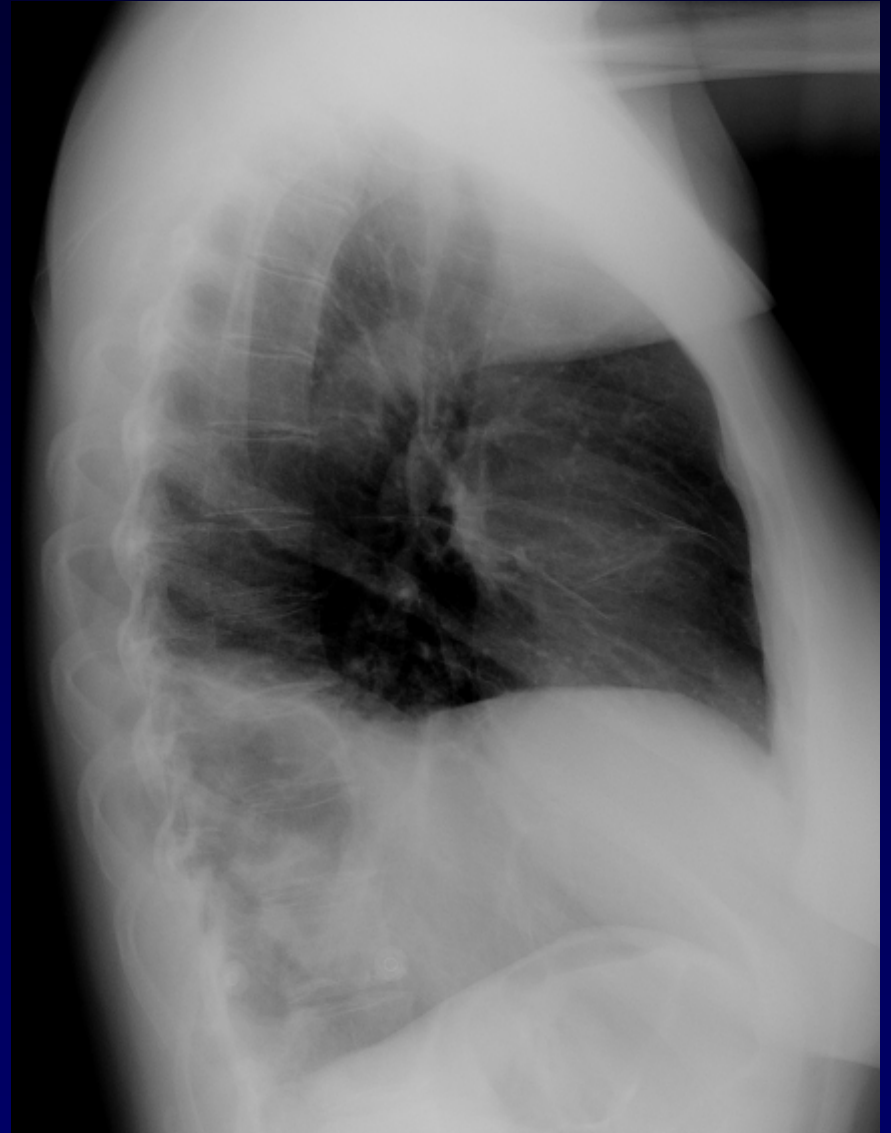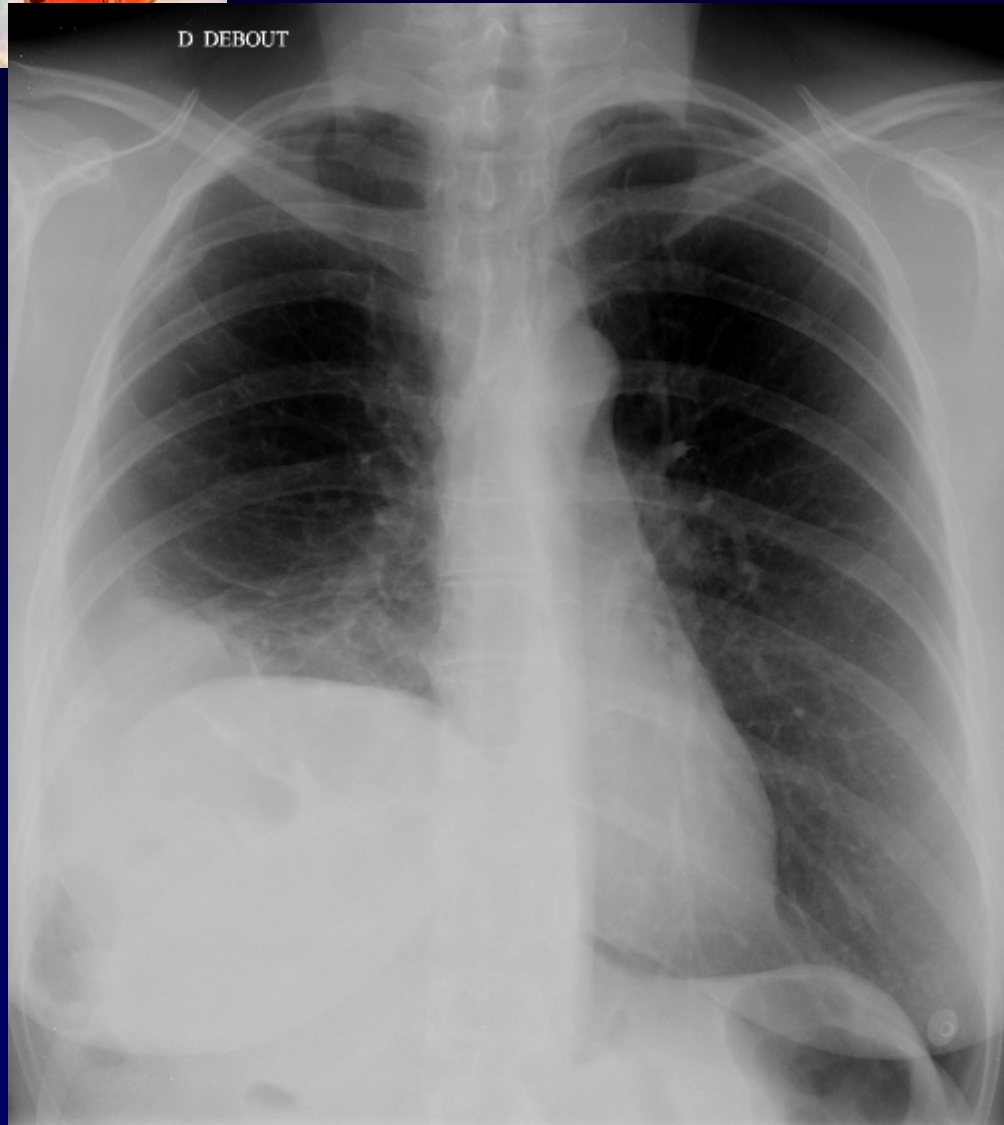
Fièvre

Hyperleucocytose

CRP élevée

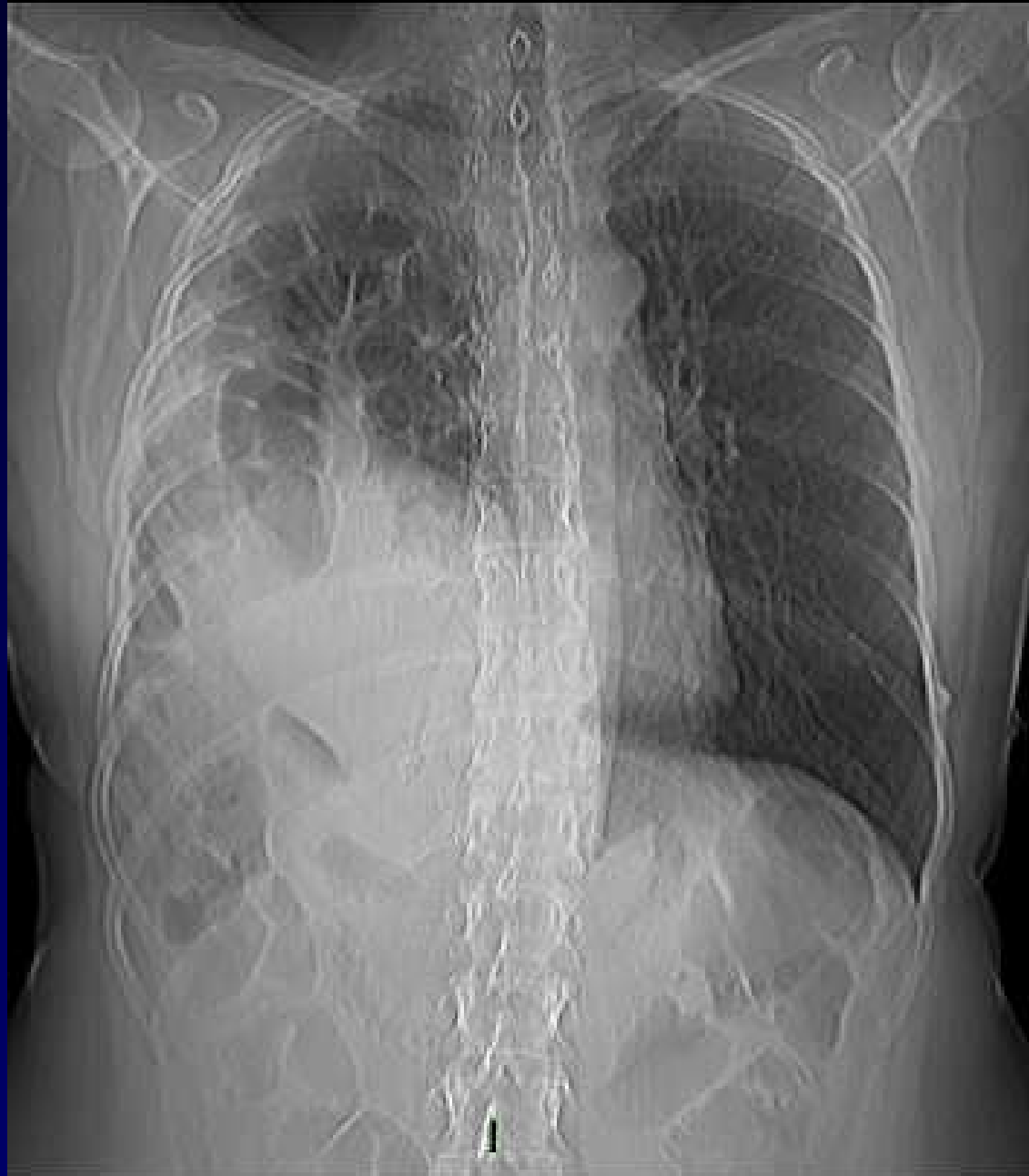
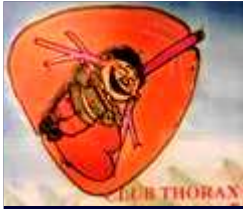
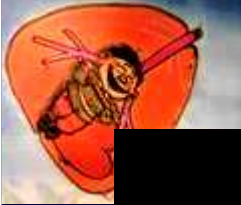
D DEBOUT



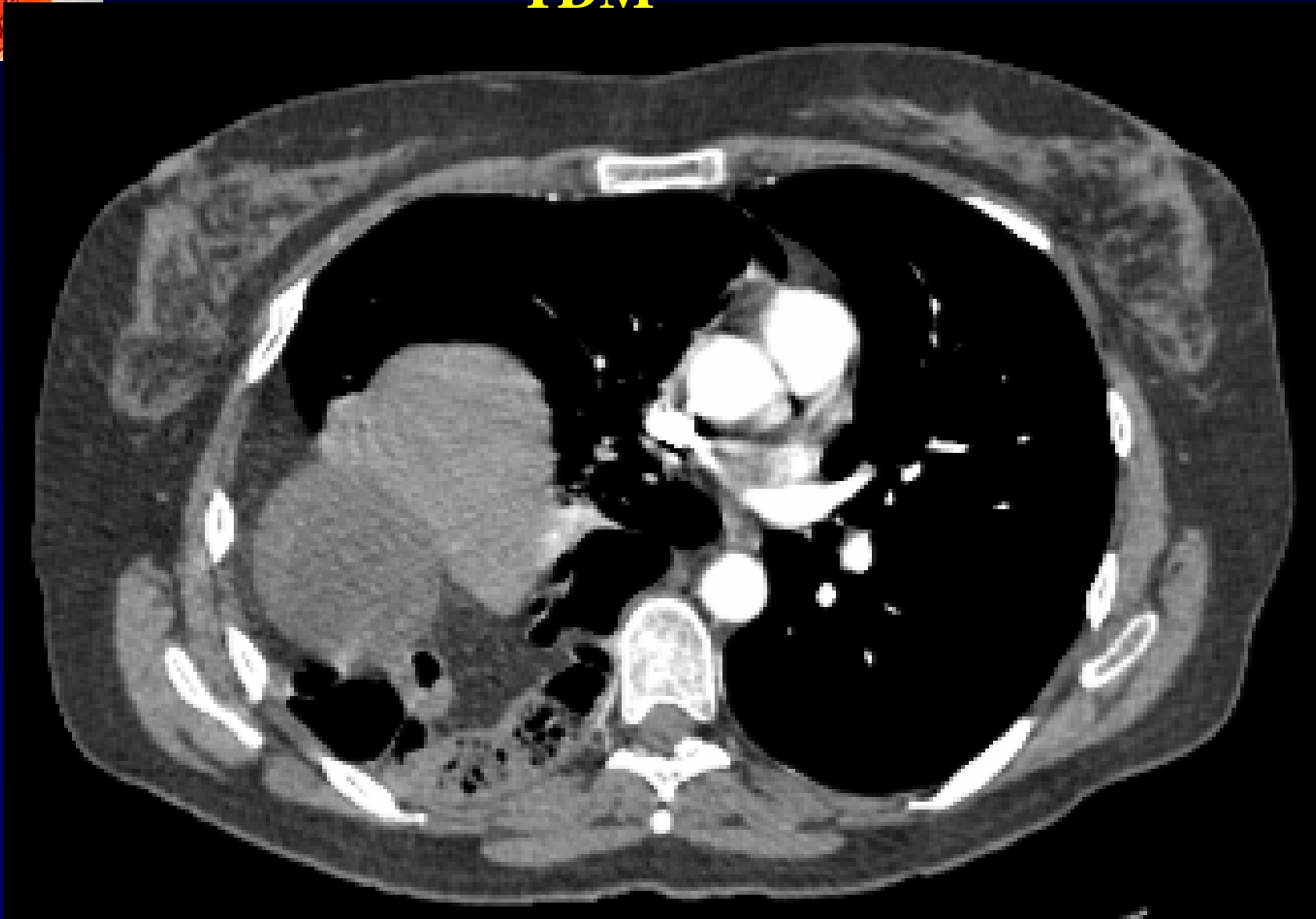


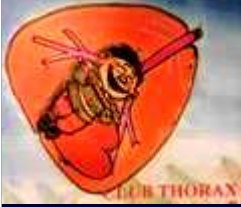Diagnostic ?



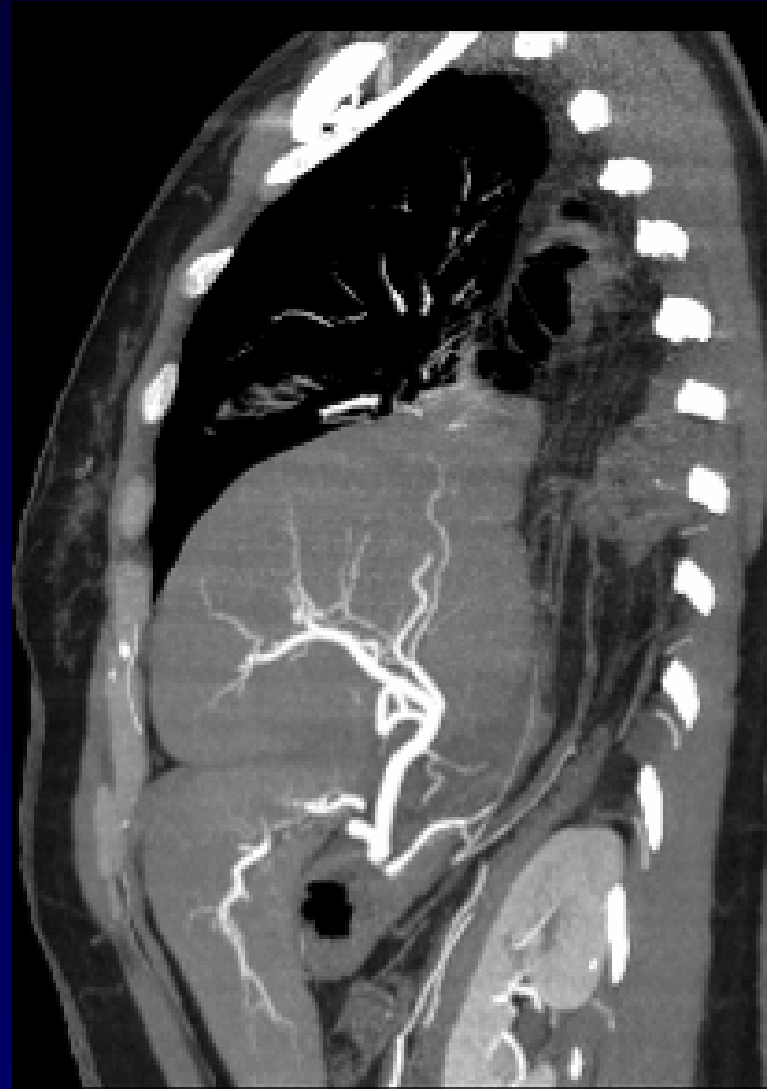
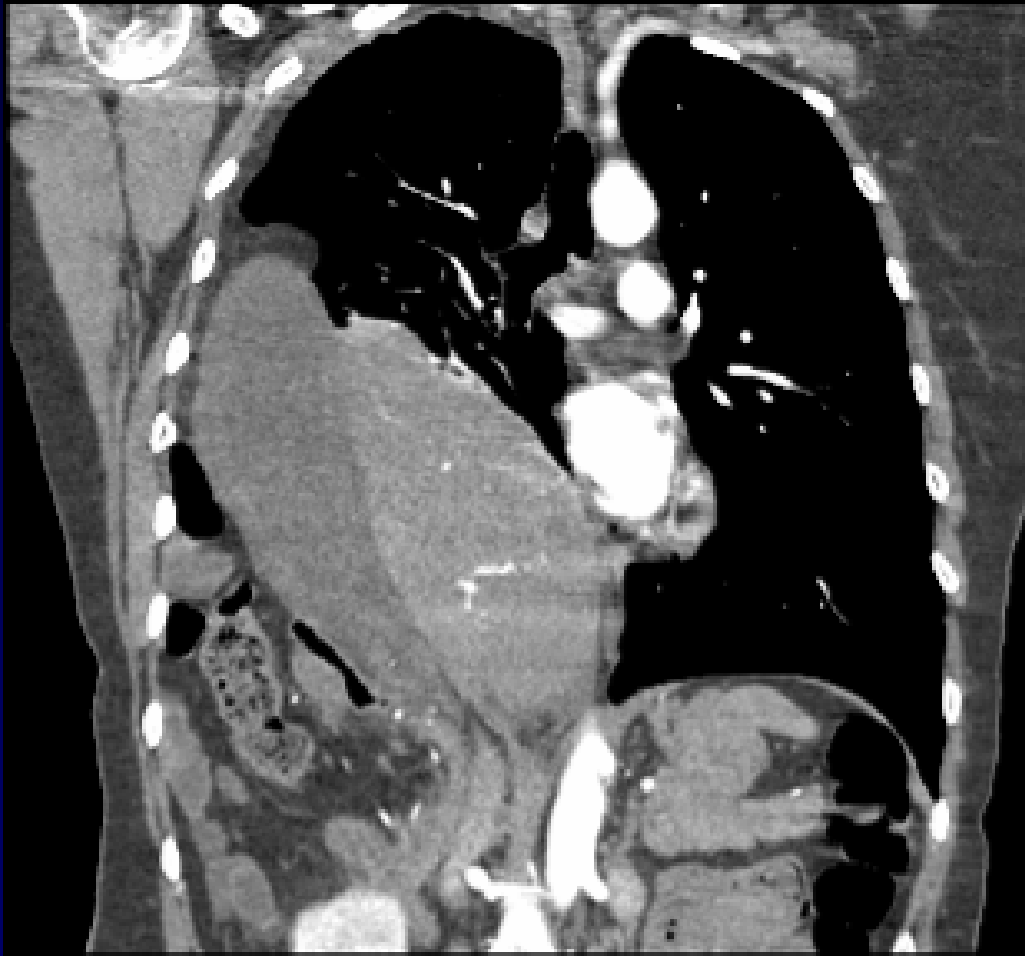
TDM



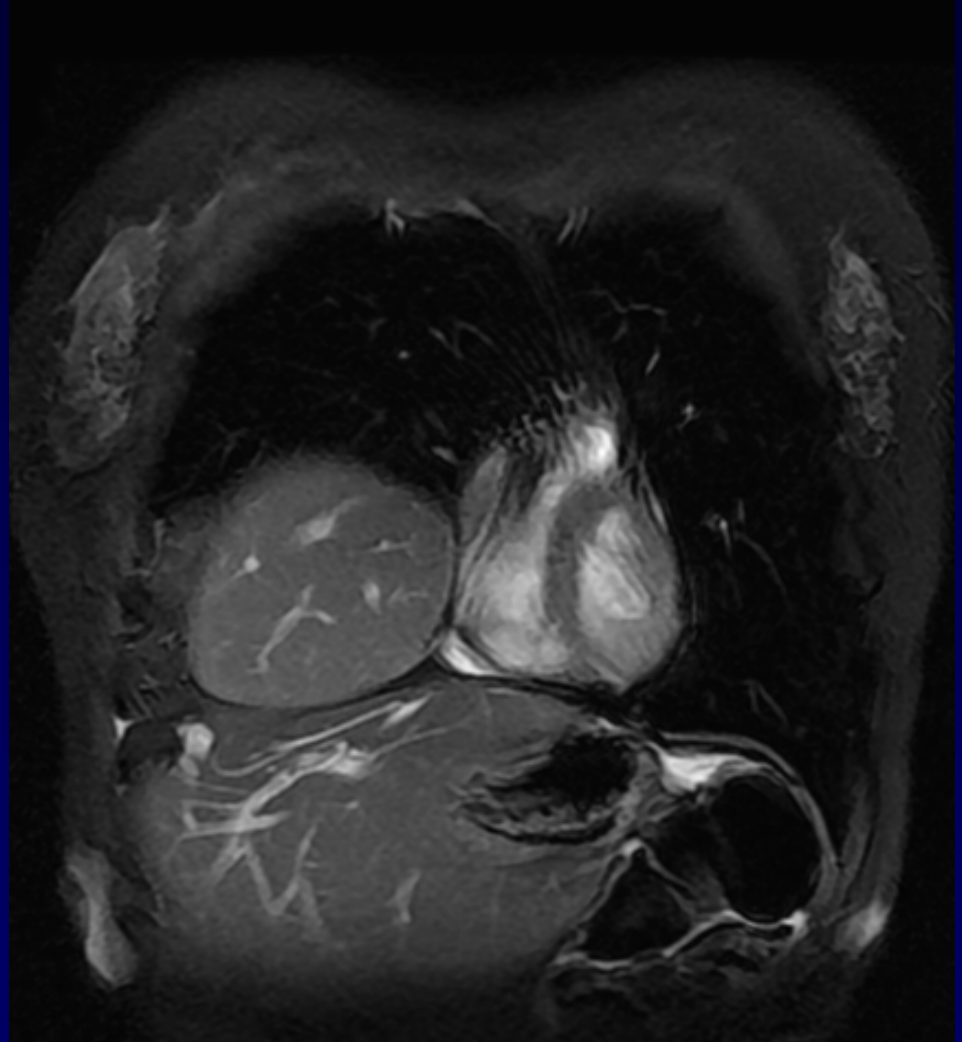
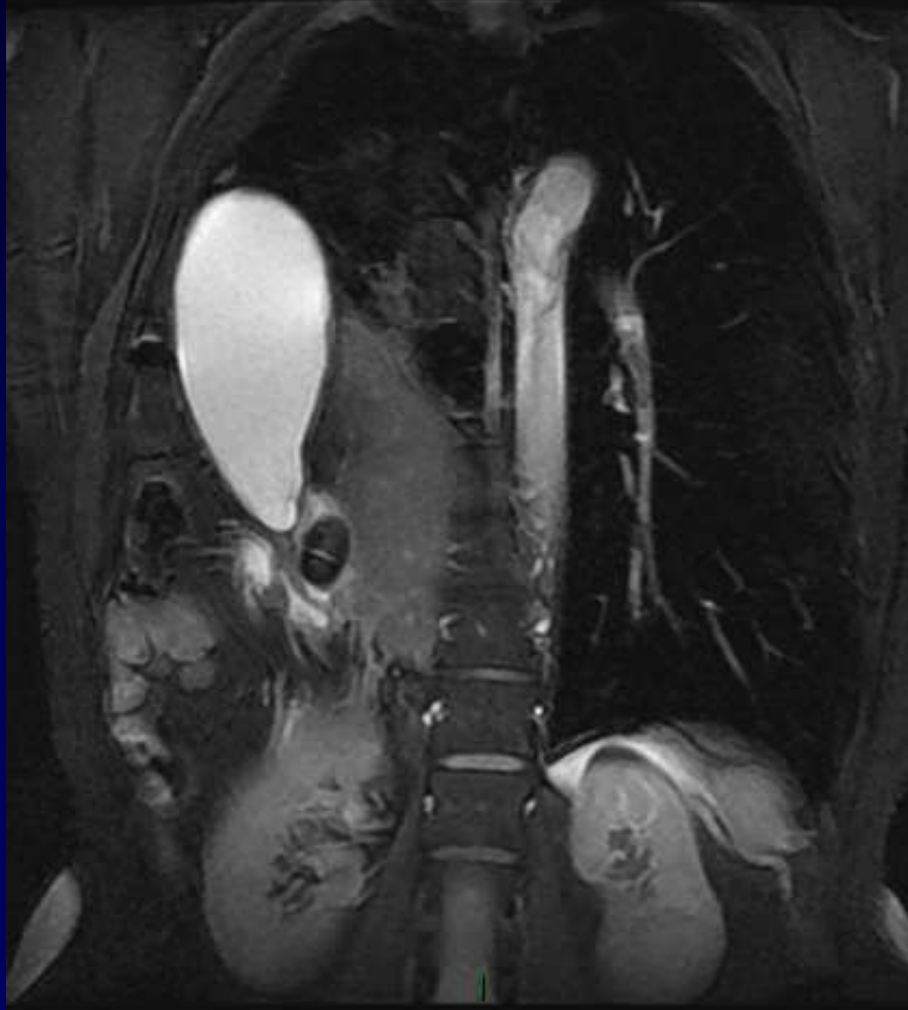


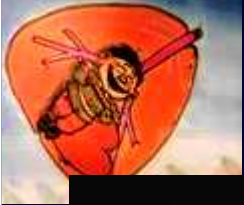
TDM



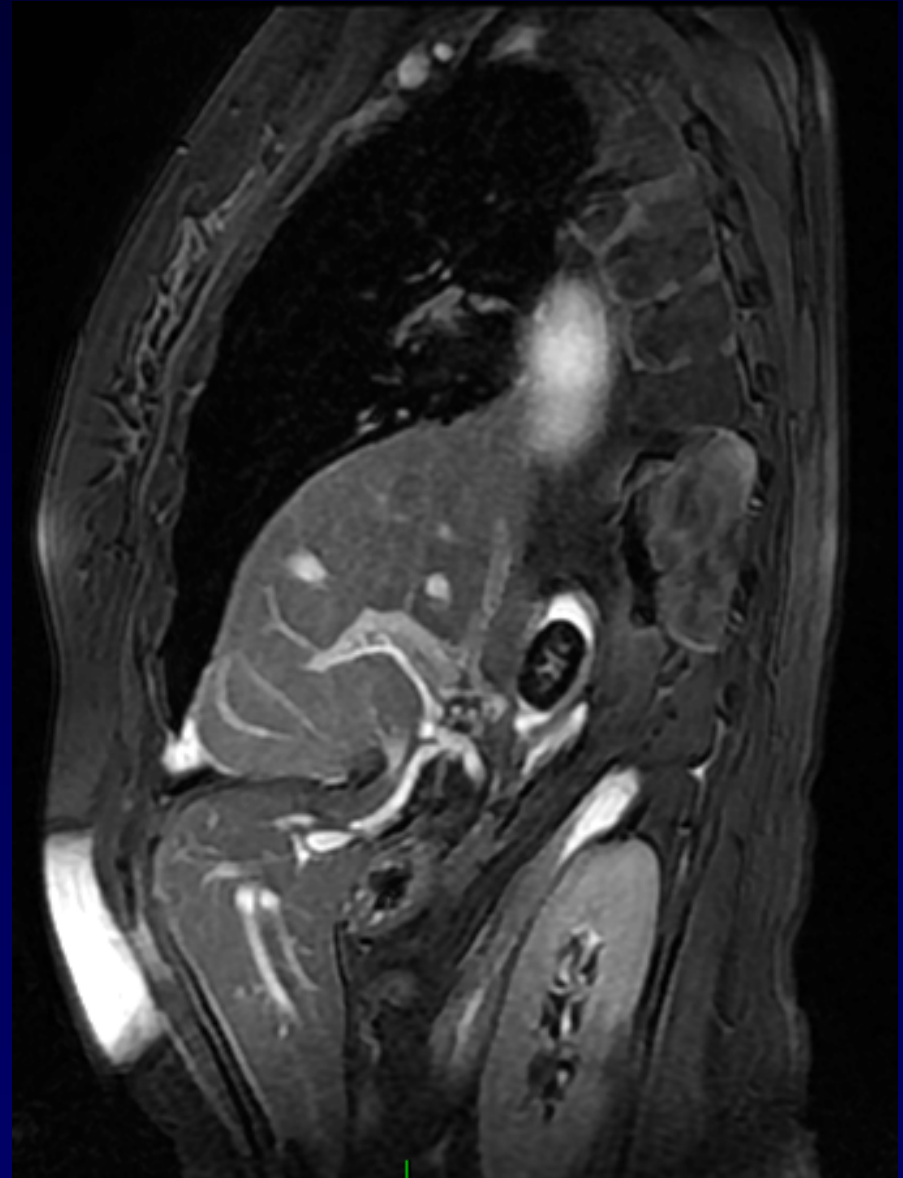
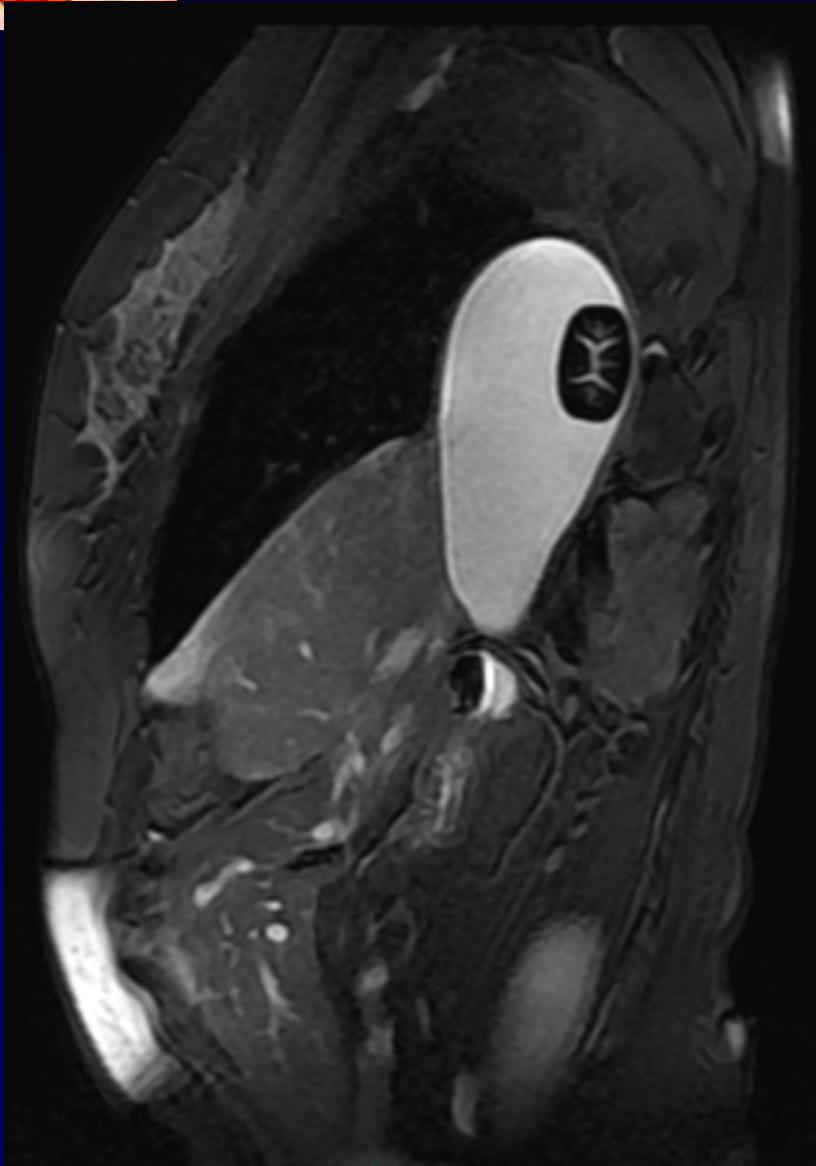


IRM Fiesta





IRM Fiesta





Diagnostic ?

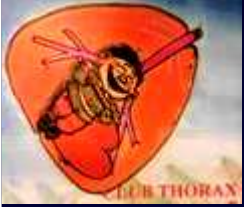

Diagnostic

Rupture diaphragmatique droite

Hydrochlécyste lithiasique intra-thoracique

ATCD d'AVP 13 ans auparavant (éjection du véhicule)



Traitement

Thoracotomie droite

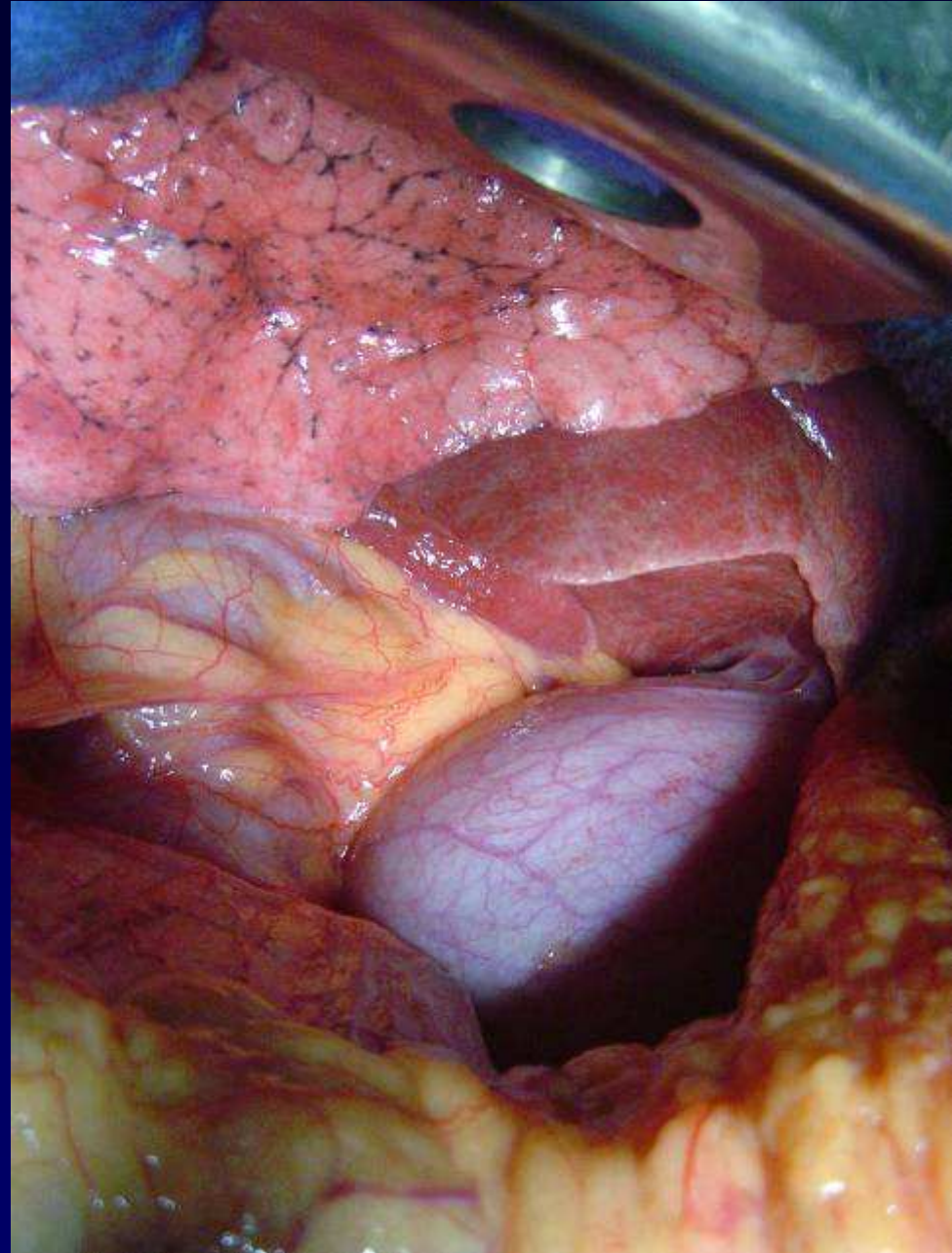Cholécystectomie

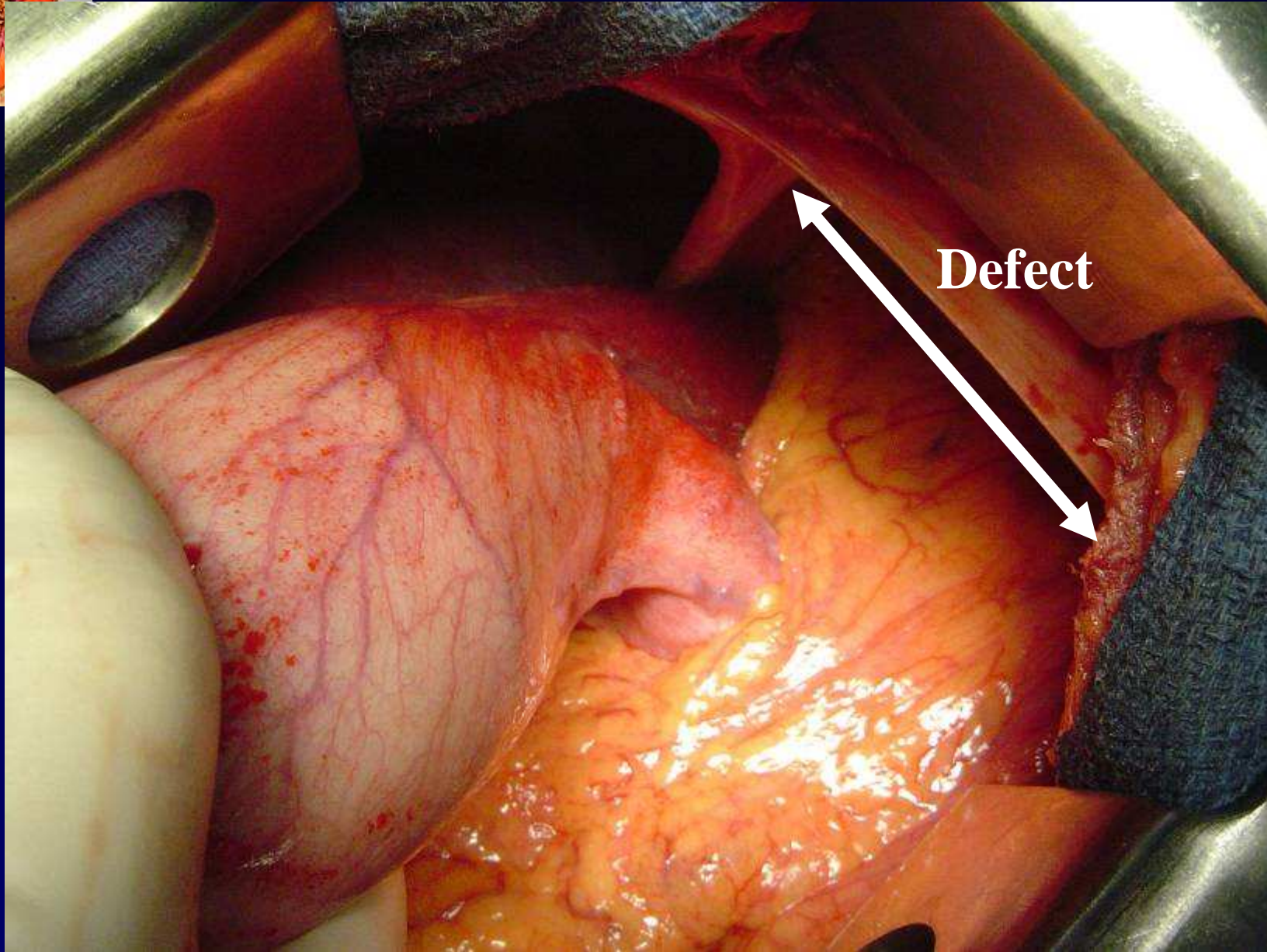
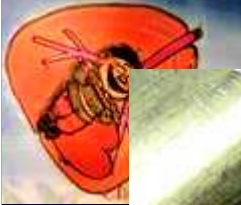
Réintégration facile du foie et du colon droit

Suture de la large brèche diaphragmatique + prothèse

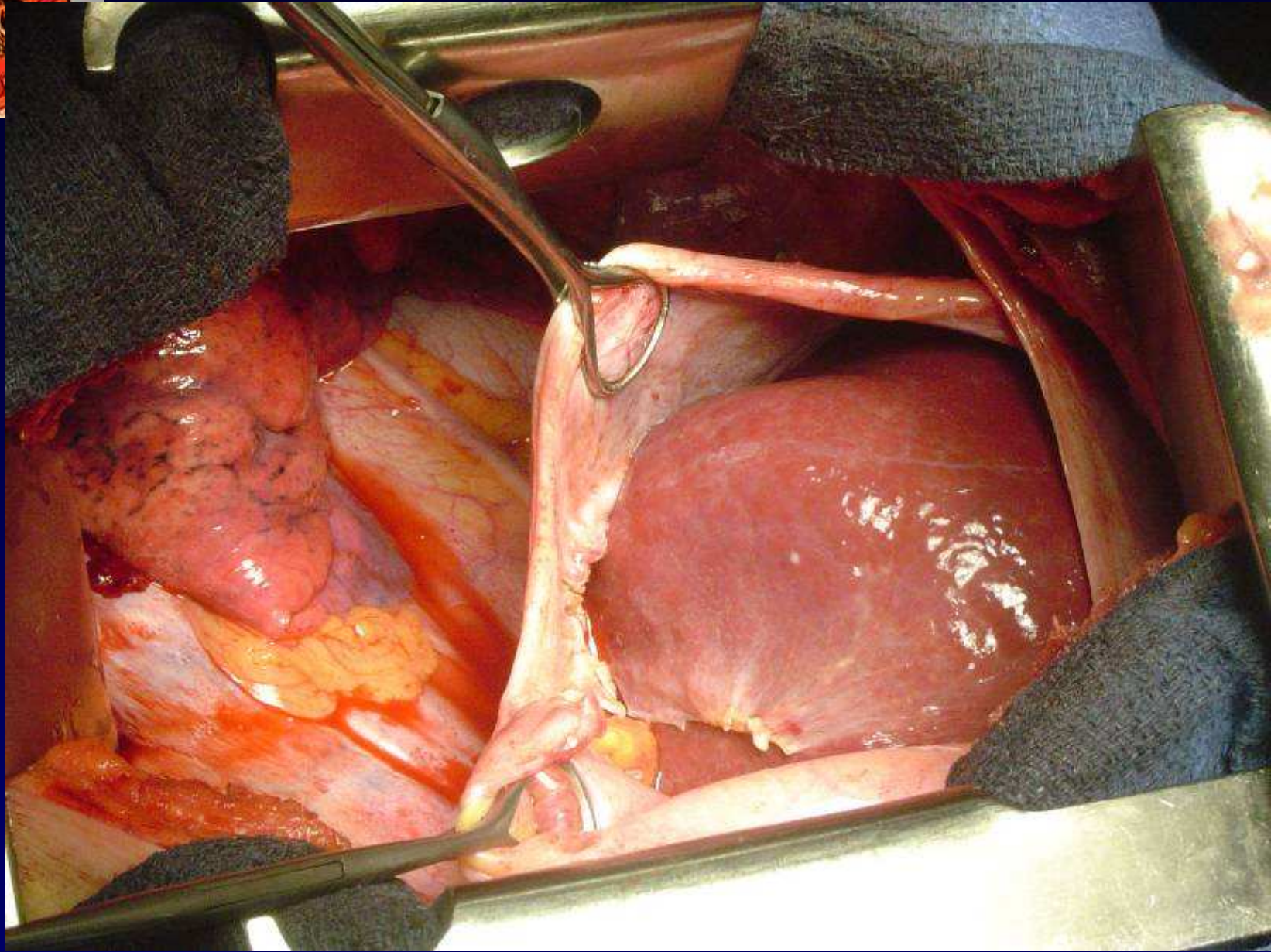
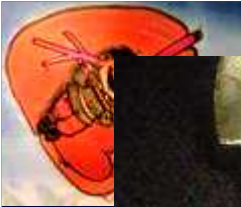


**Vue opératoire
Thoracotomie
7^{ème} espace droit**

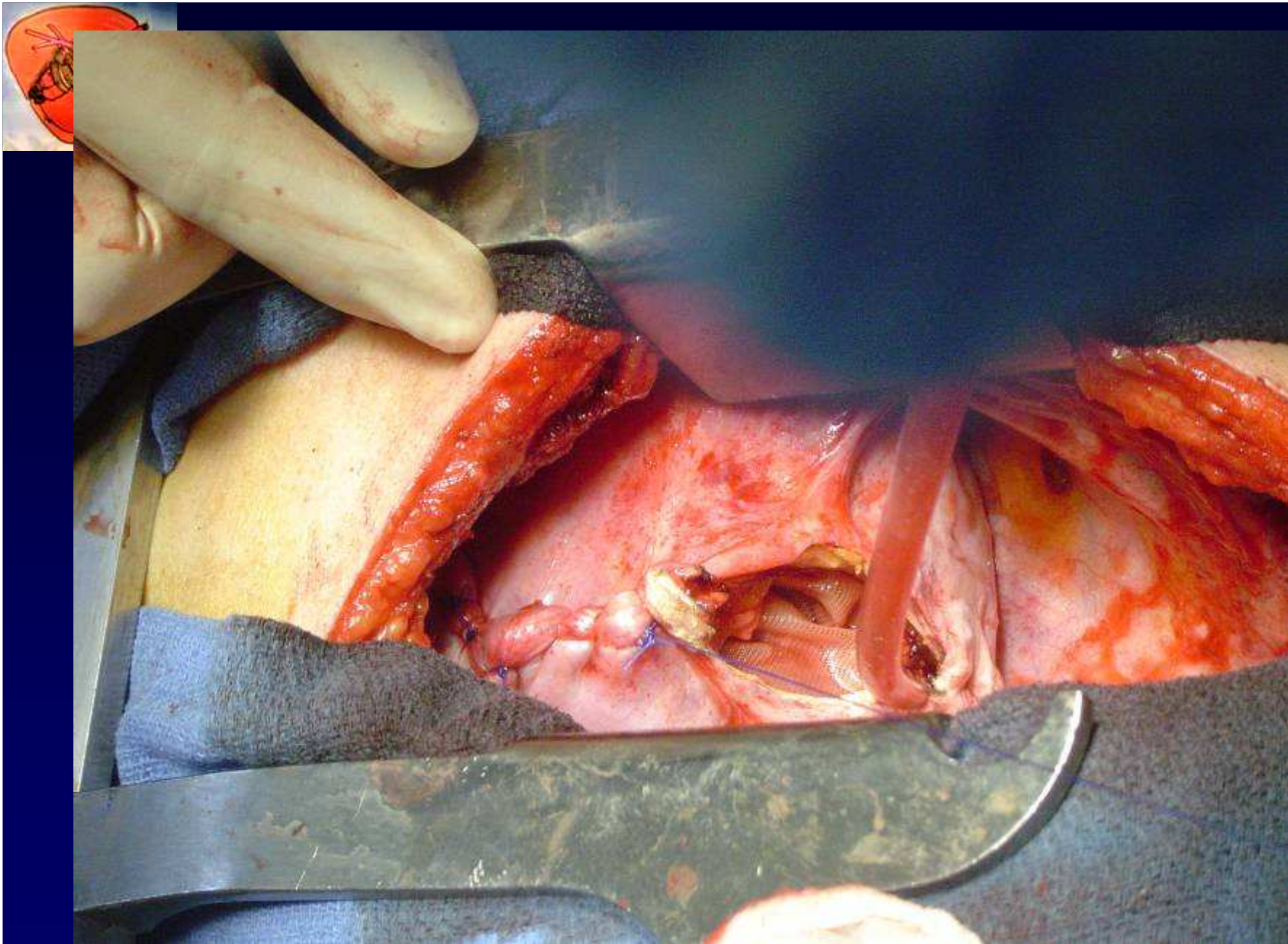




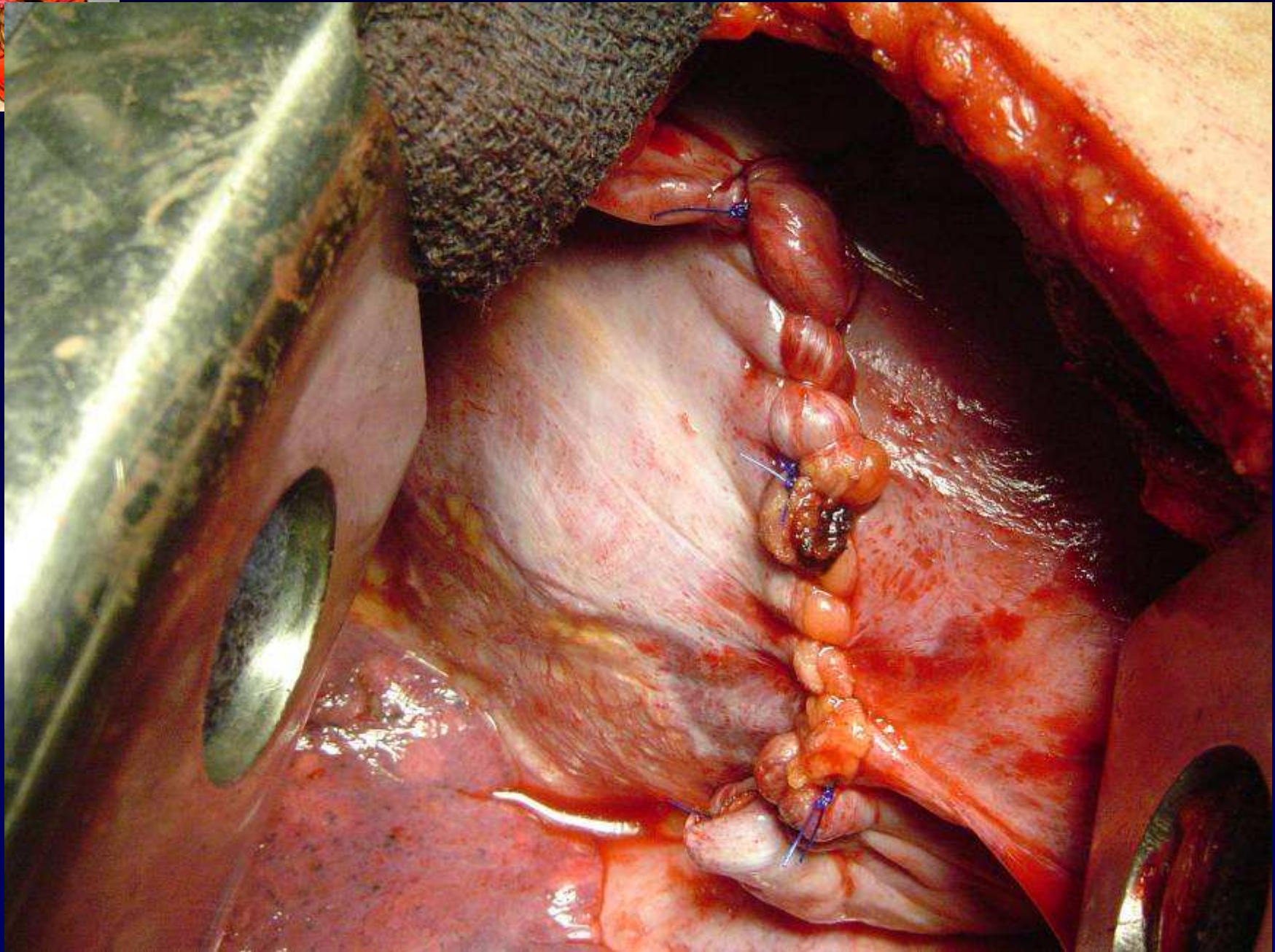
Cholécystectomie

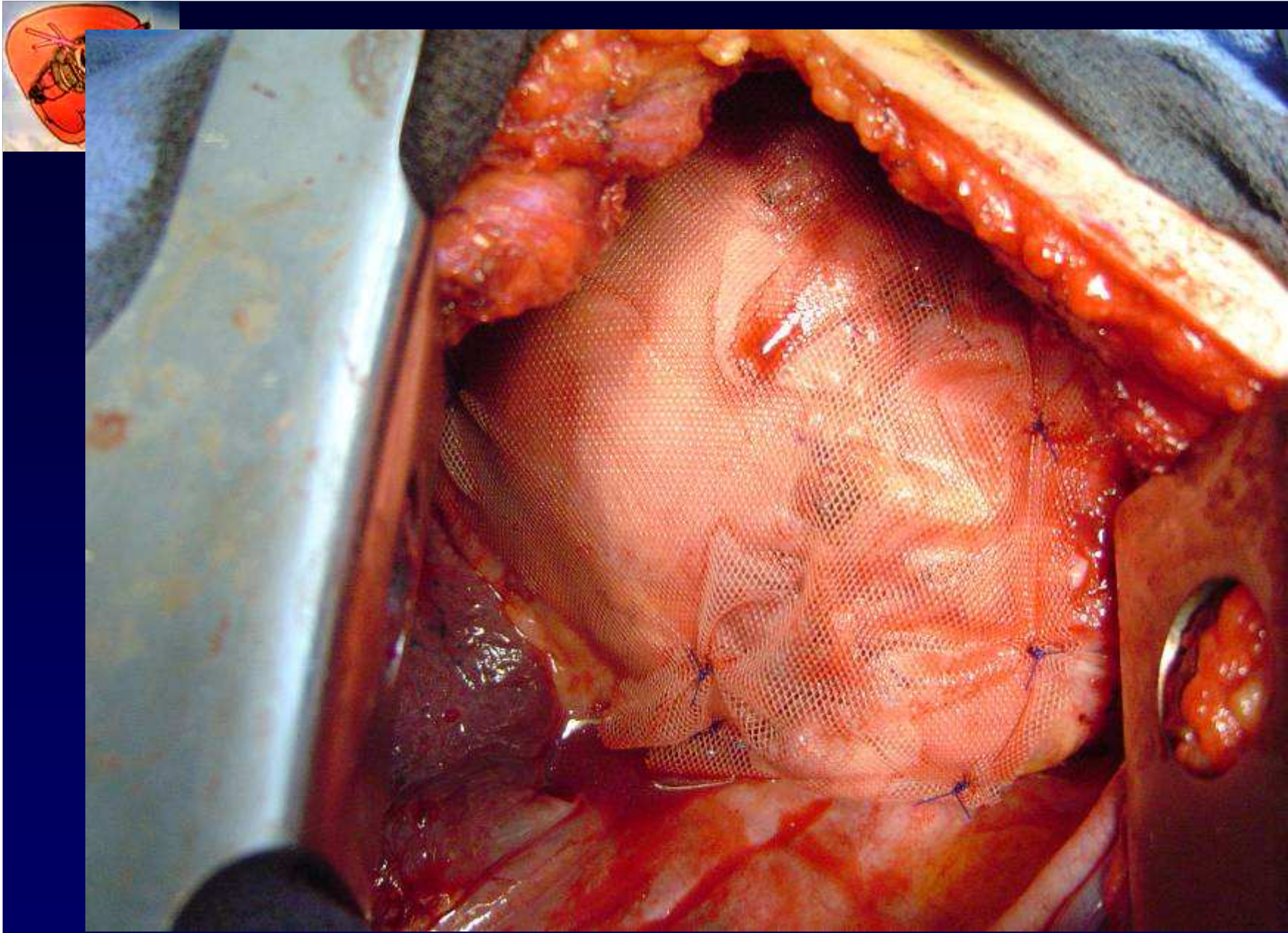


Réintégration du foie + colon



Suture du diaphragme

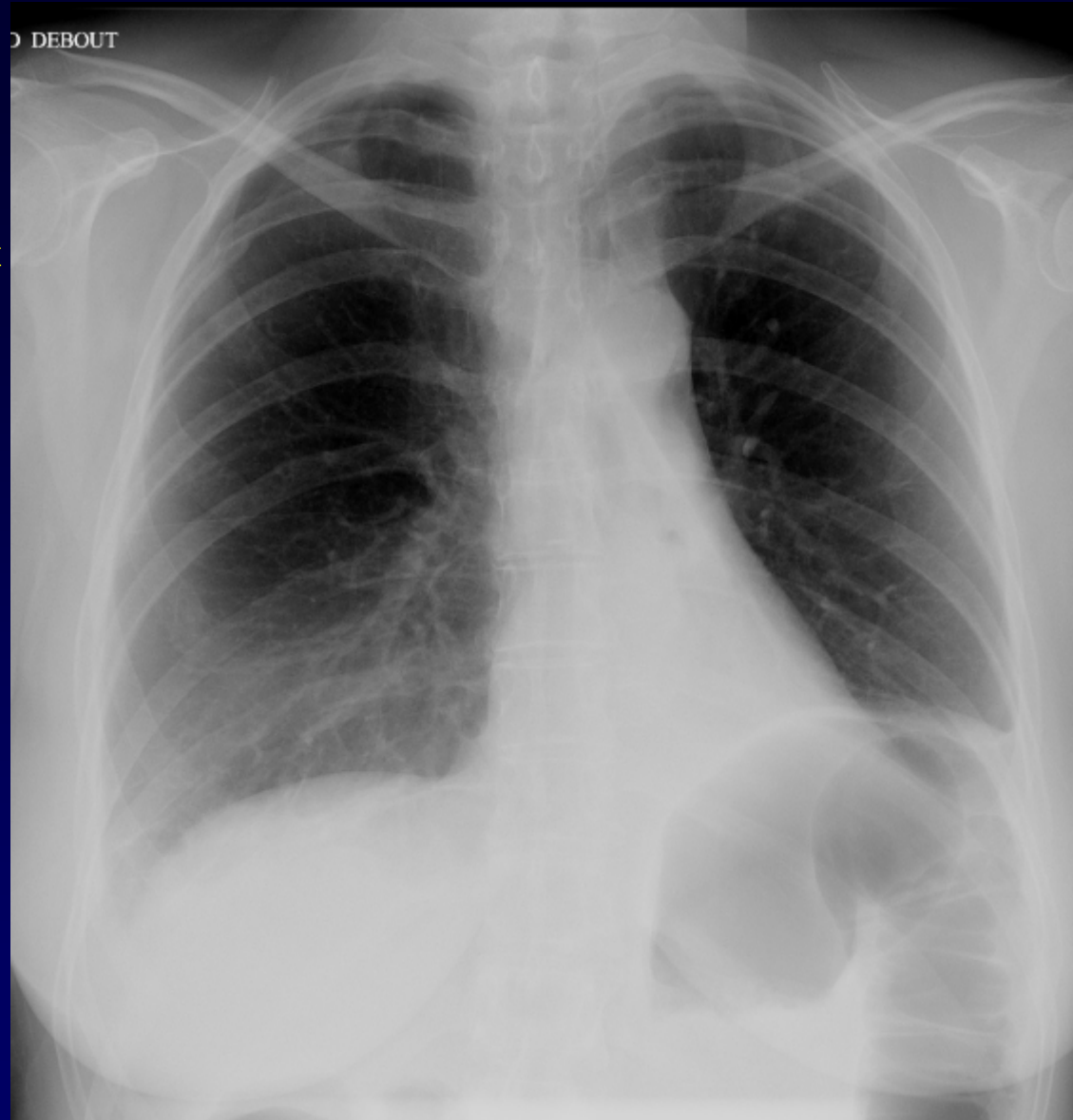




Renforcement par plaque de Vicryl



**Petit pneumothorax
résiduel**



Atélectasie LIG

Rx thorax de contrôle à J6