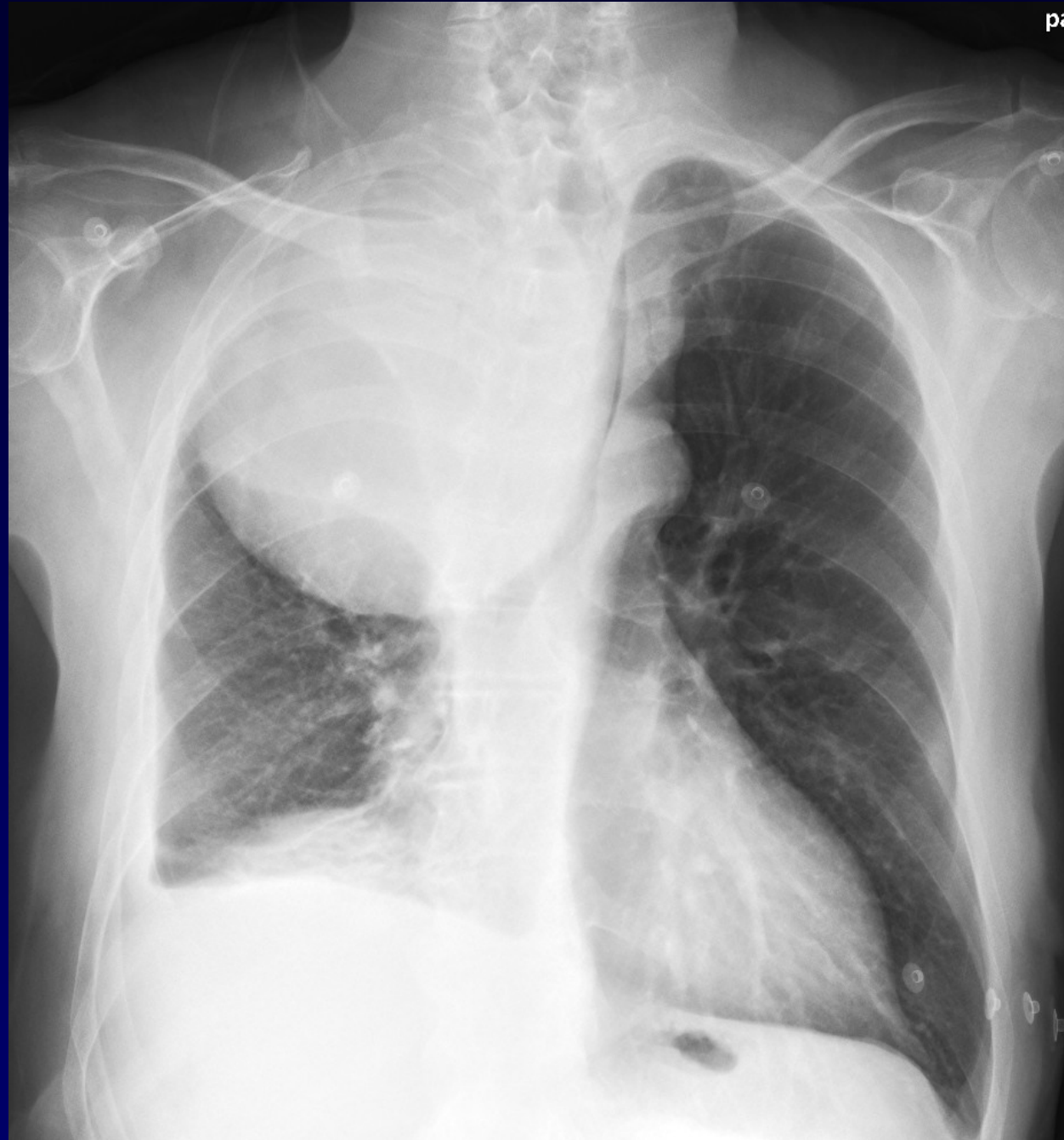

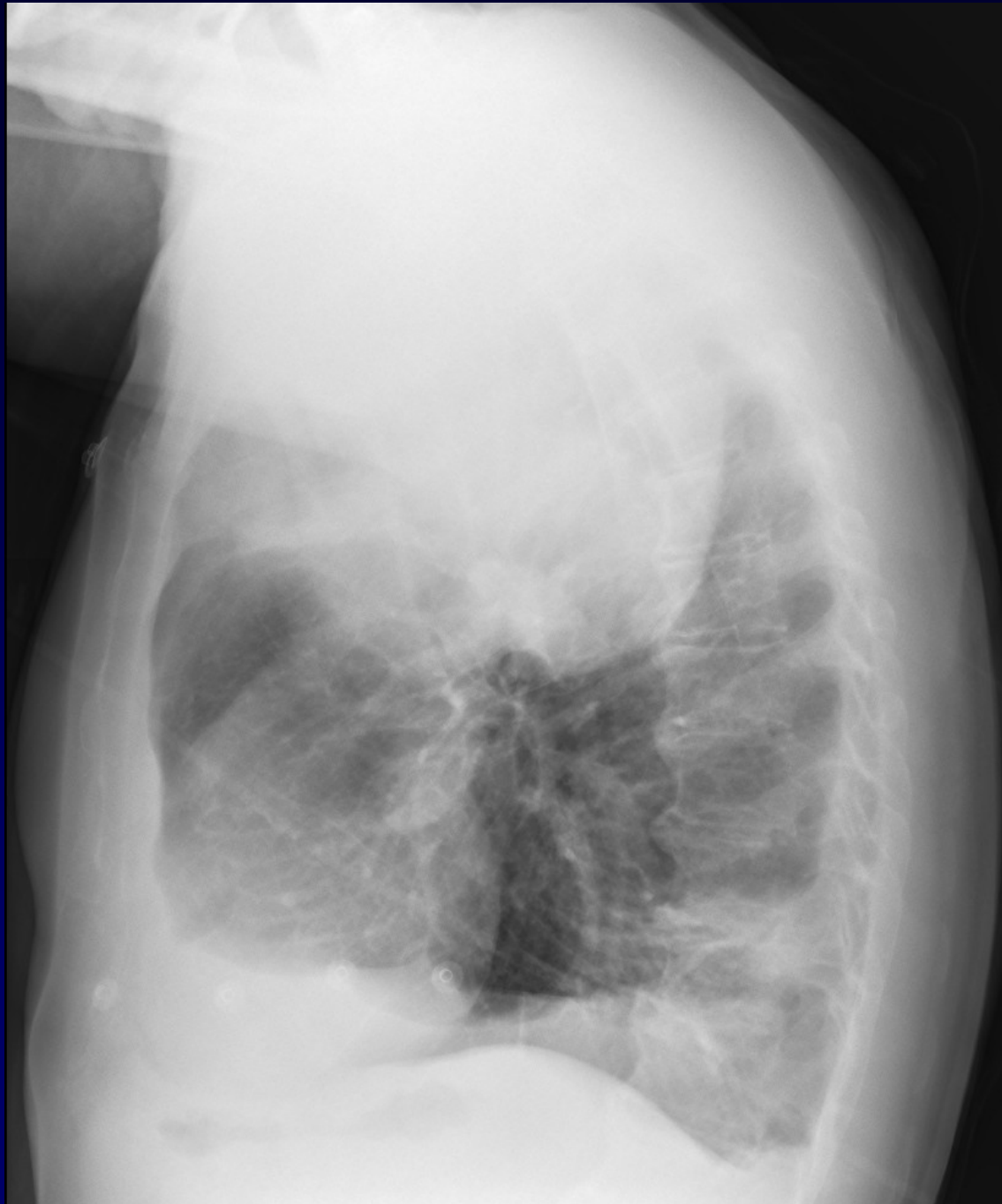


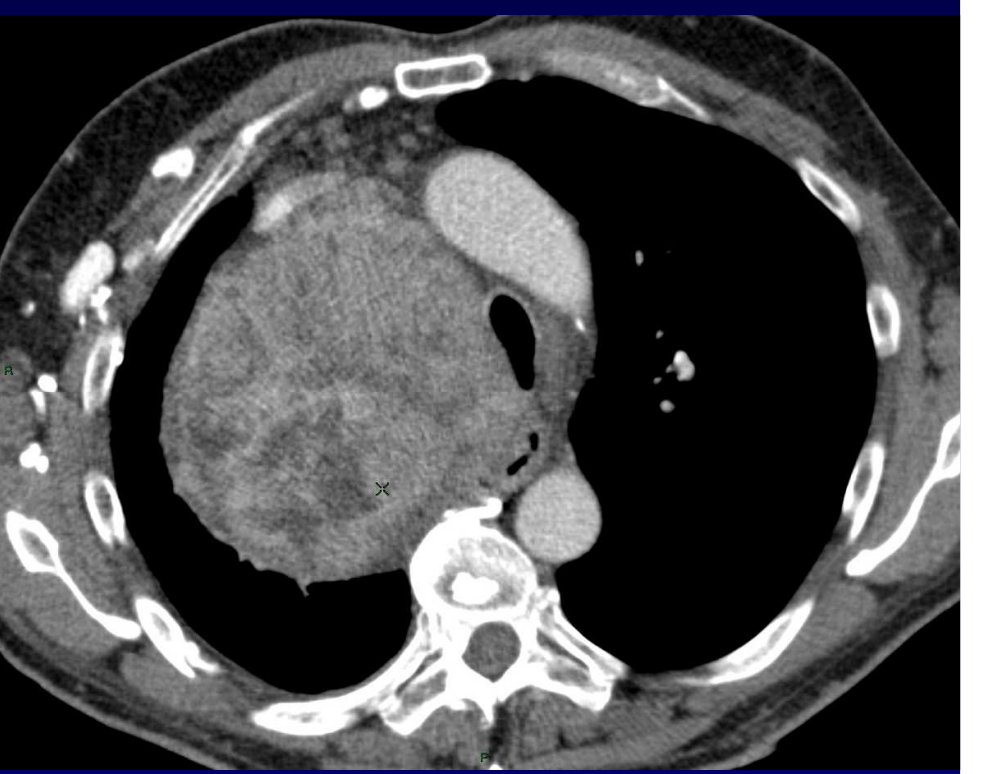
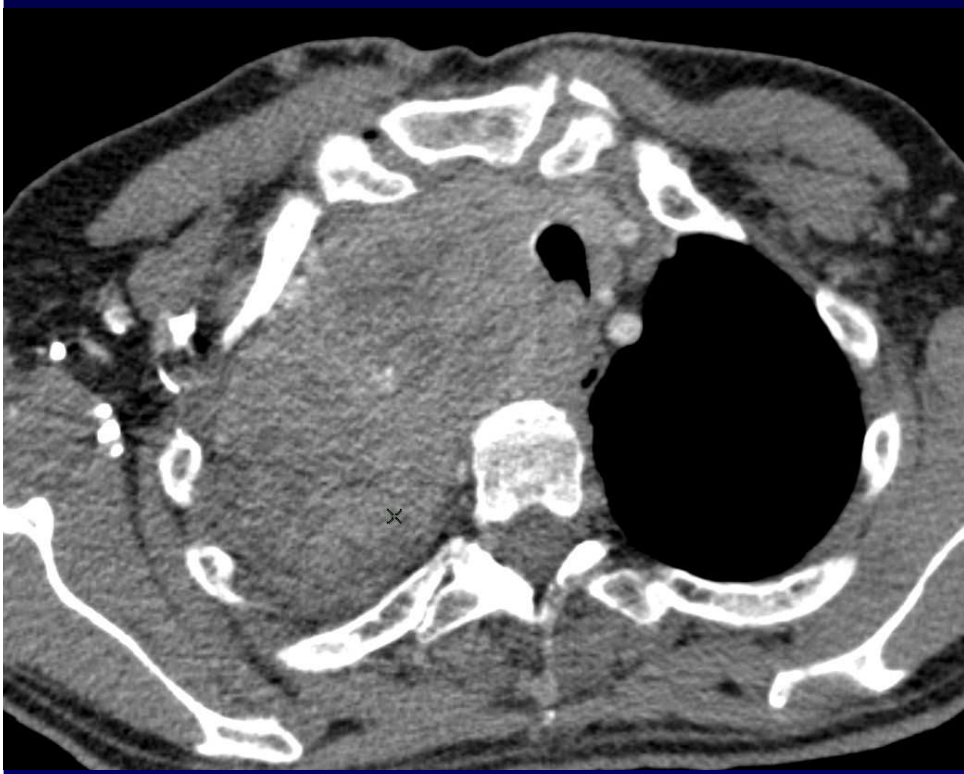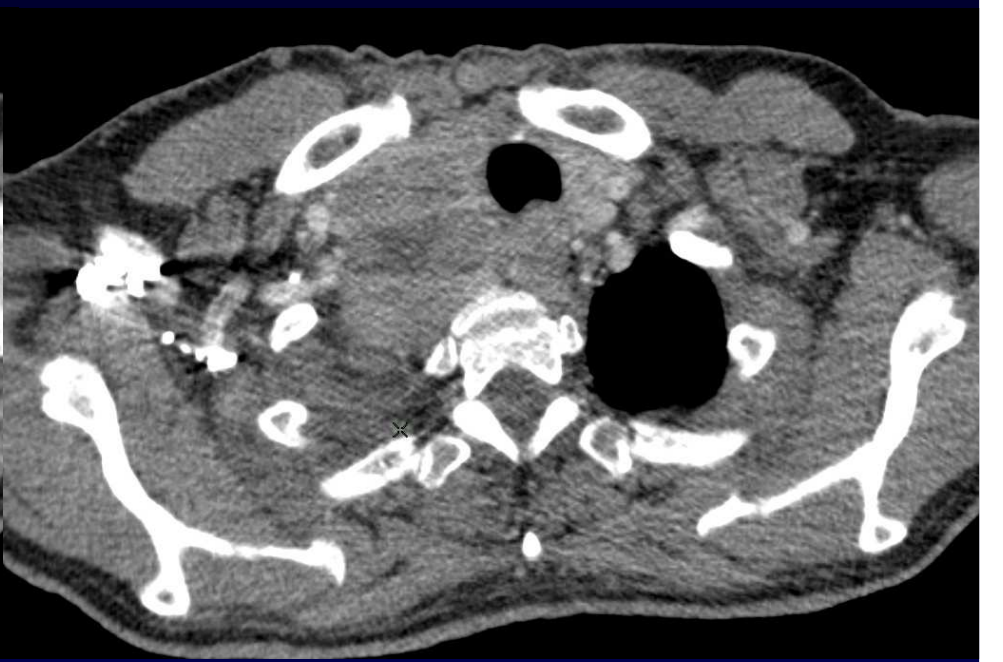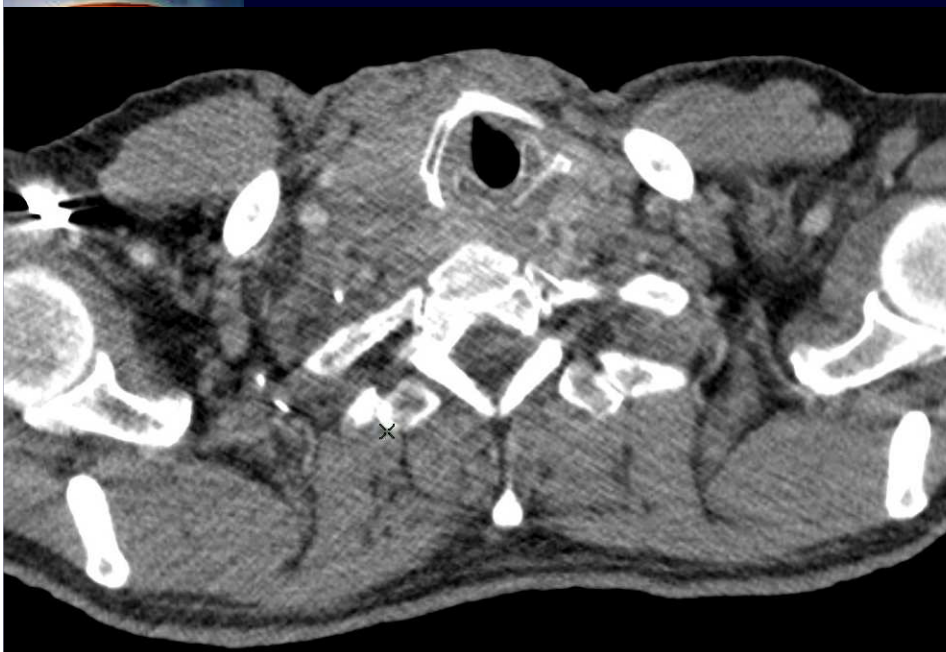
MP DEBRAY

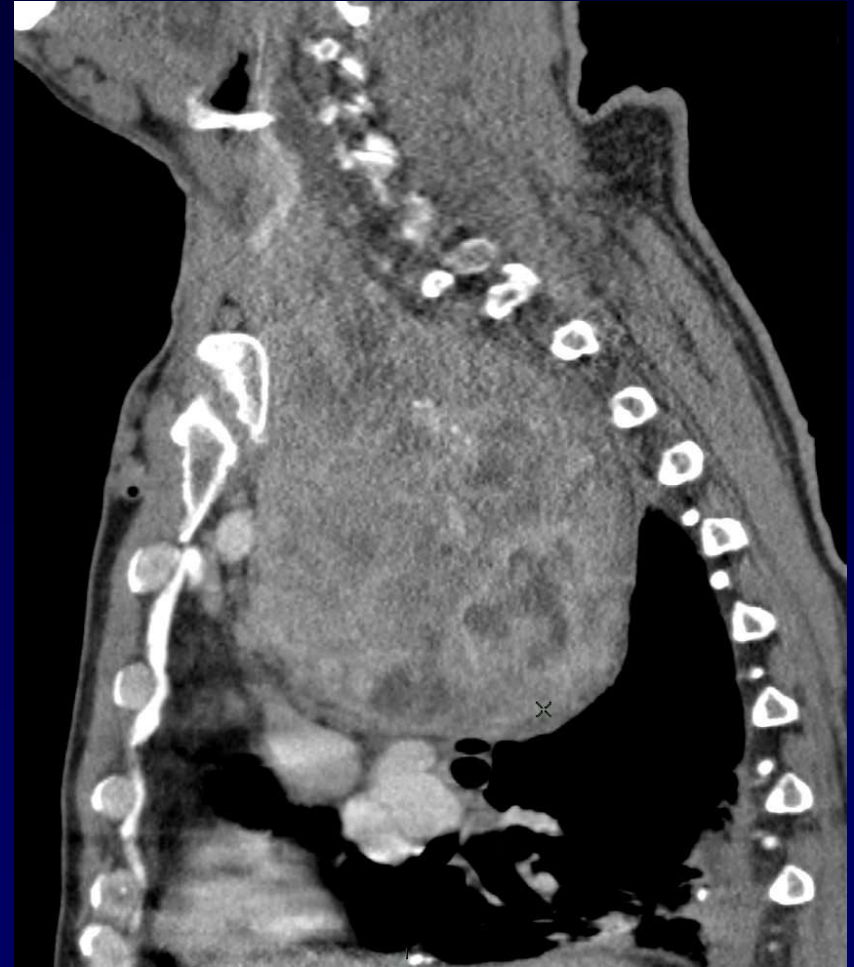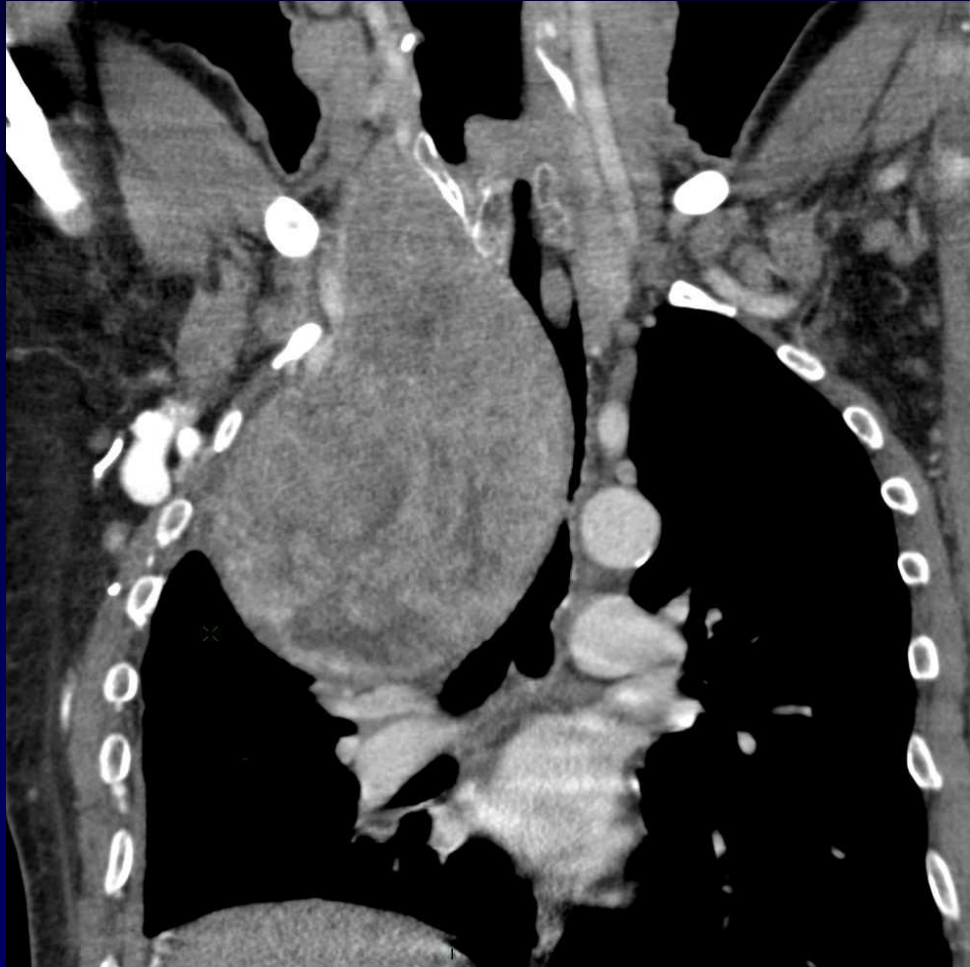Homme de 60 ans
Dyspnée



pa







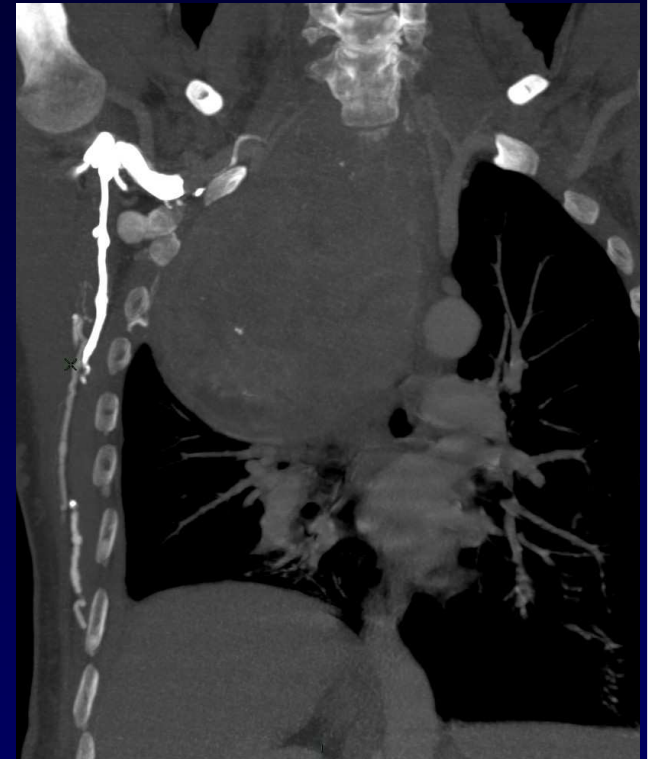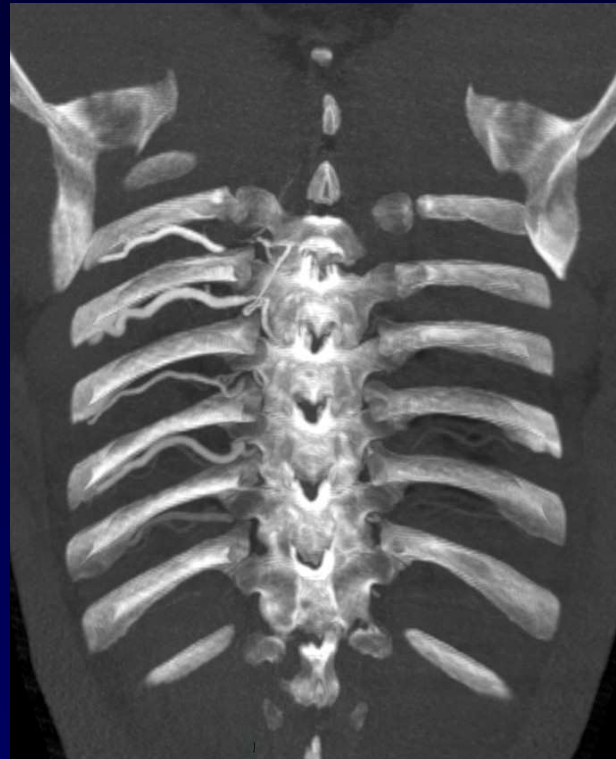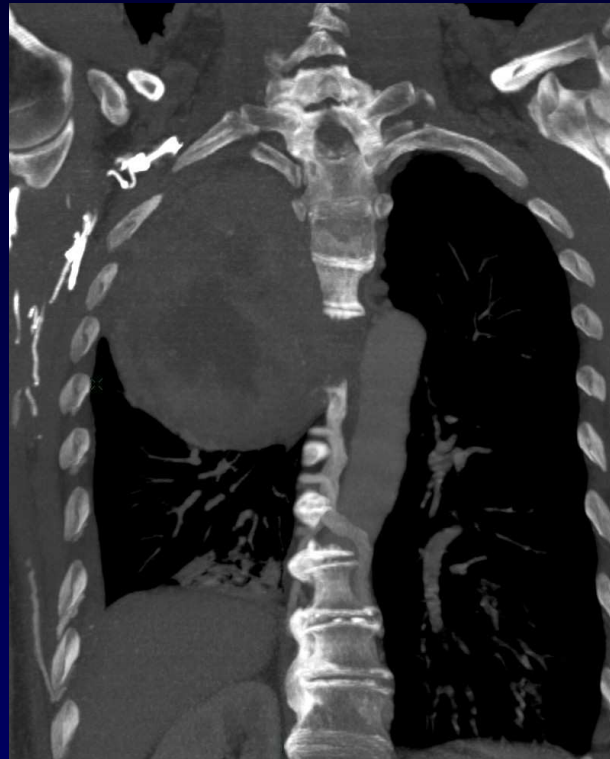


Diagnostic ?



Diagnostic

**Goître volumineux à développement
endothoracique**



Compression de la veine cave supérieure

Voies de dérivation veineuses