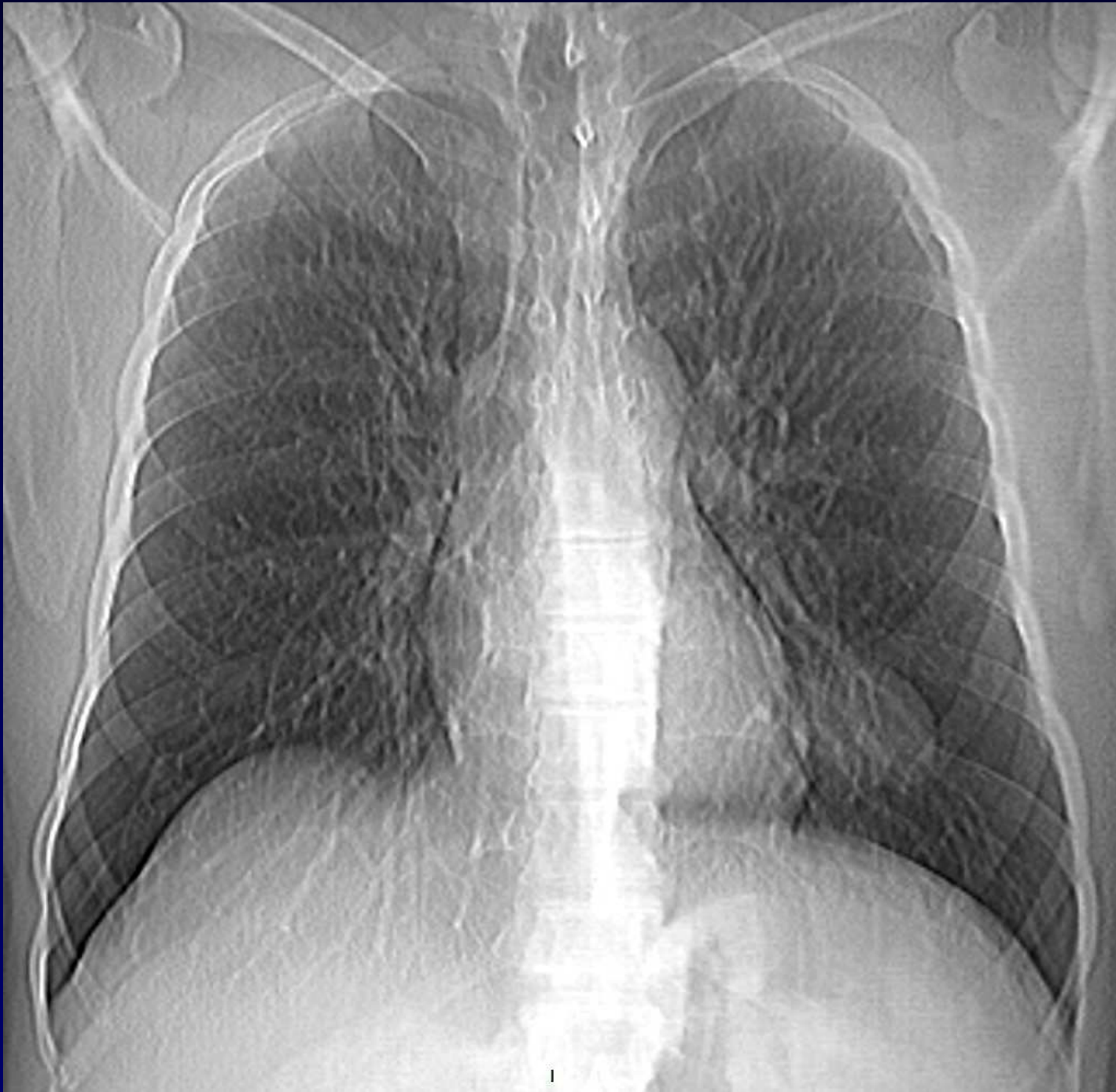

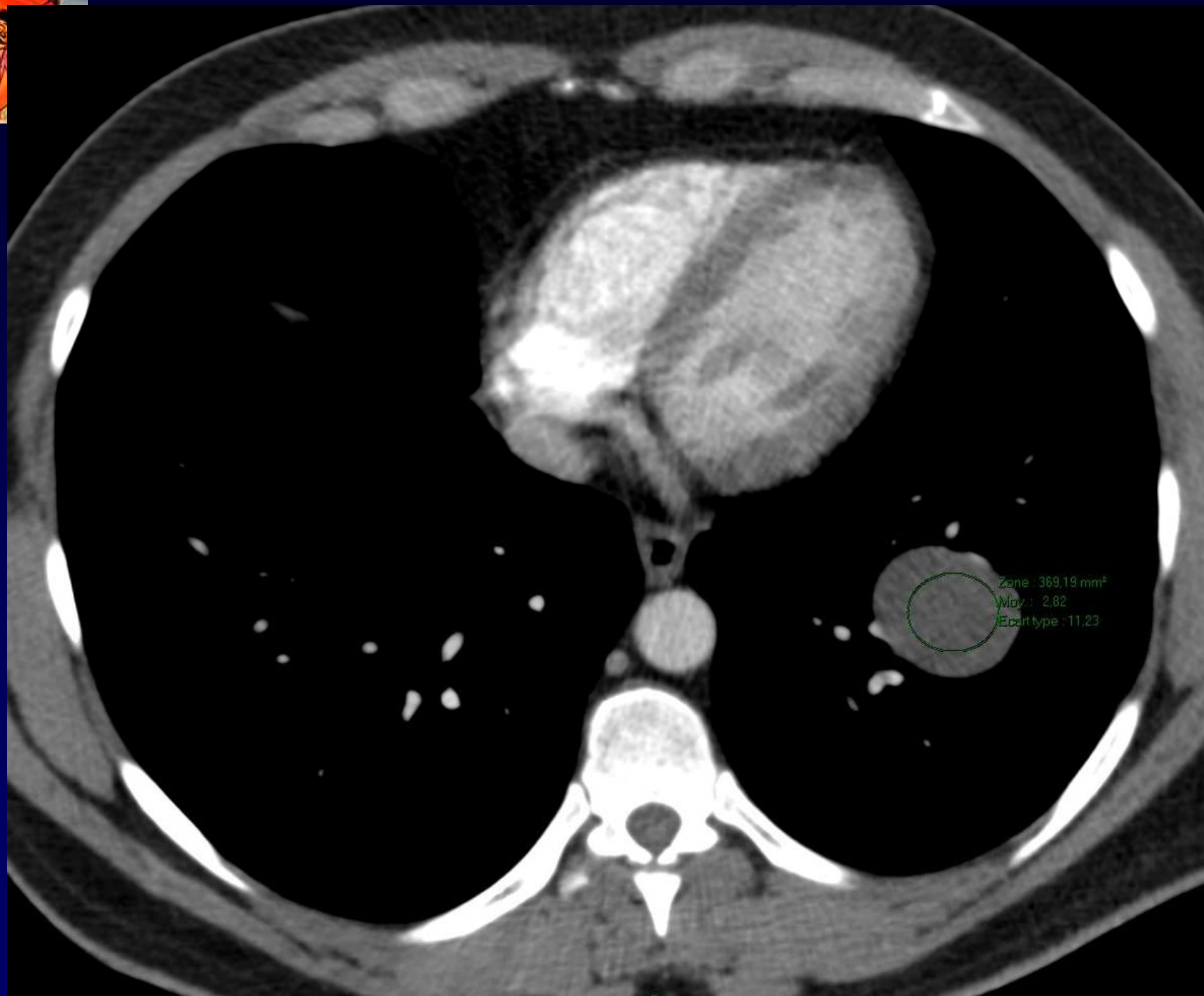


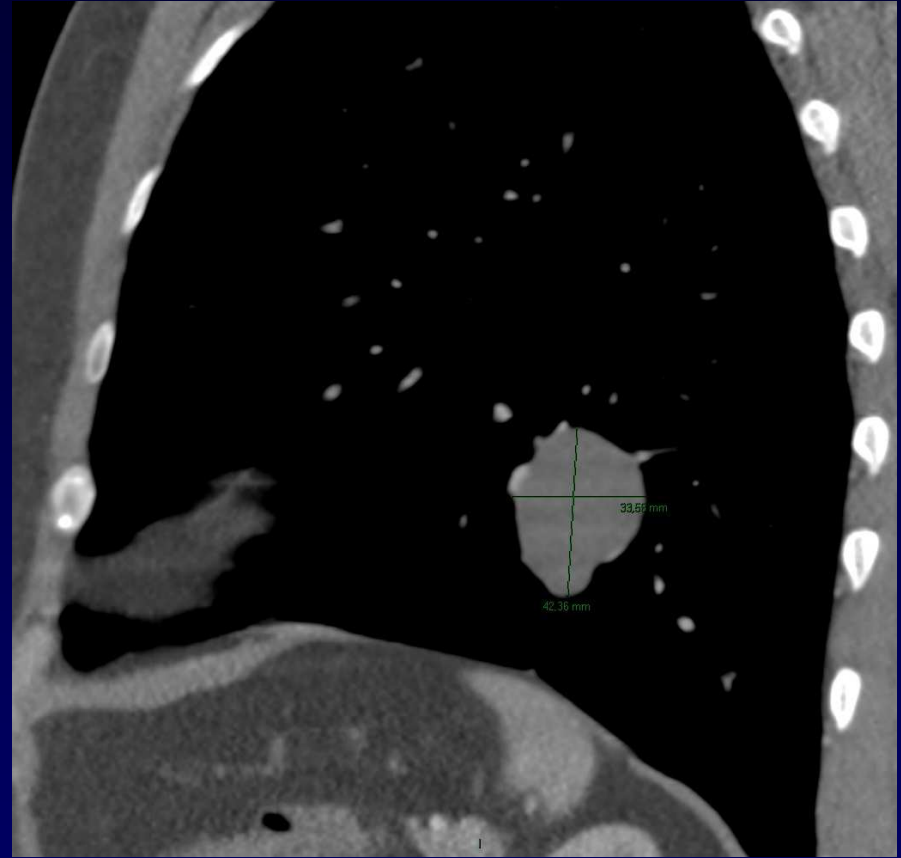
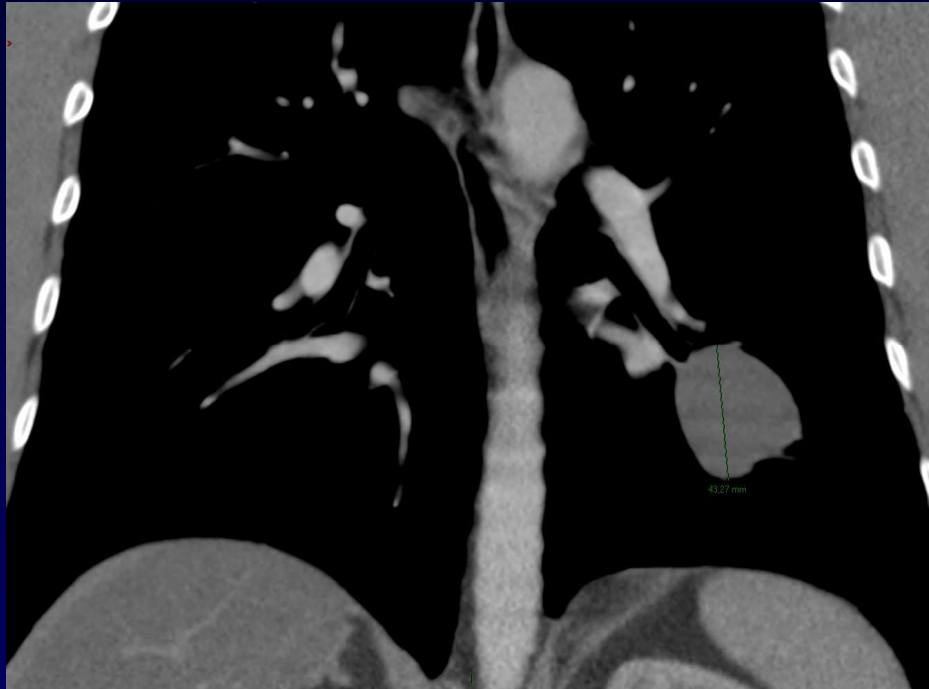**MP DEBRAY**

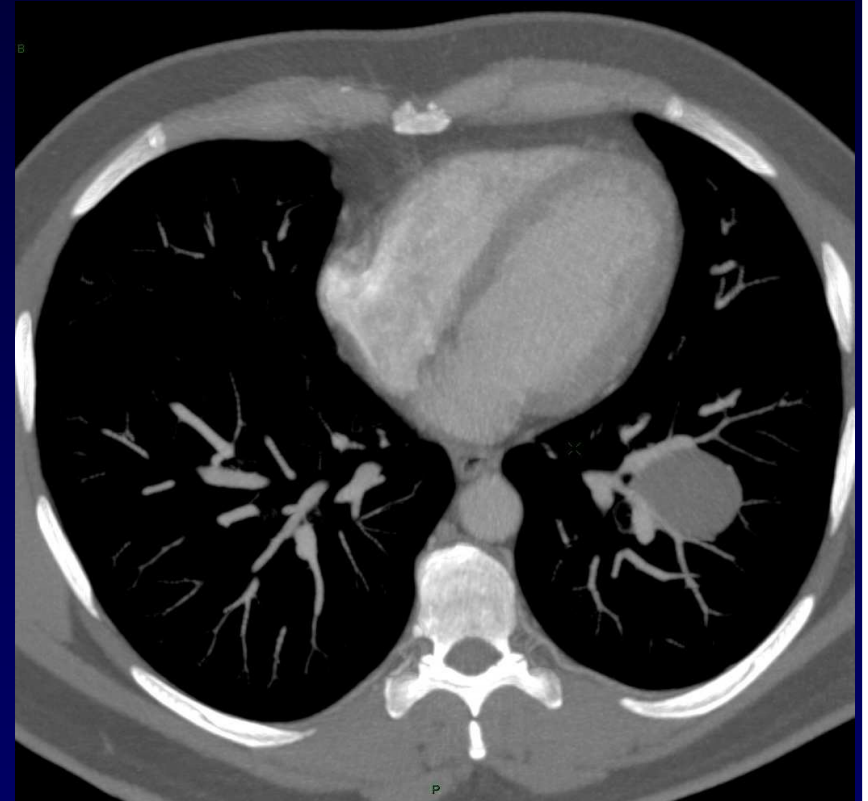
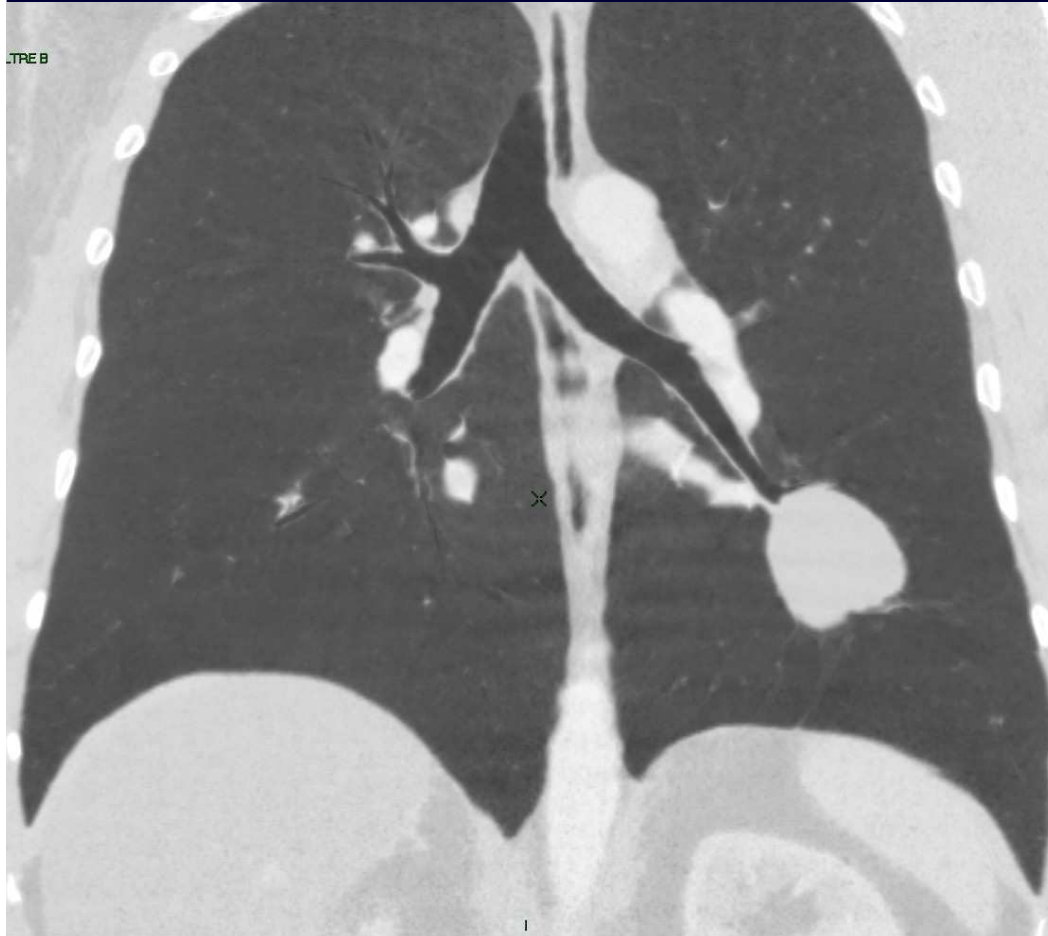Homme de 38 ans

Radiographie thoracique systématique











**Diagnostic ?**



## **Diagnostic**

**Kyste bronchogénique**

**Exérèse en monobloc de la lésion**