

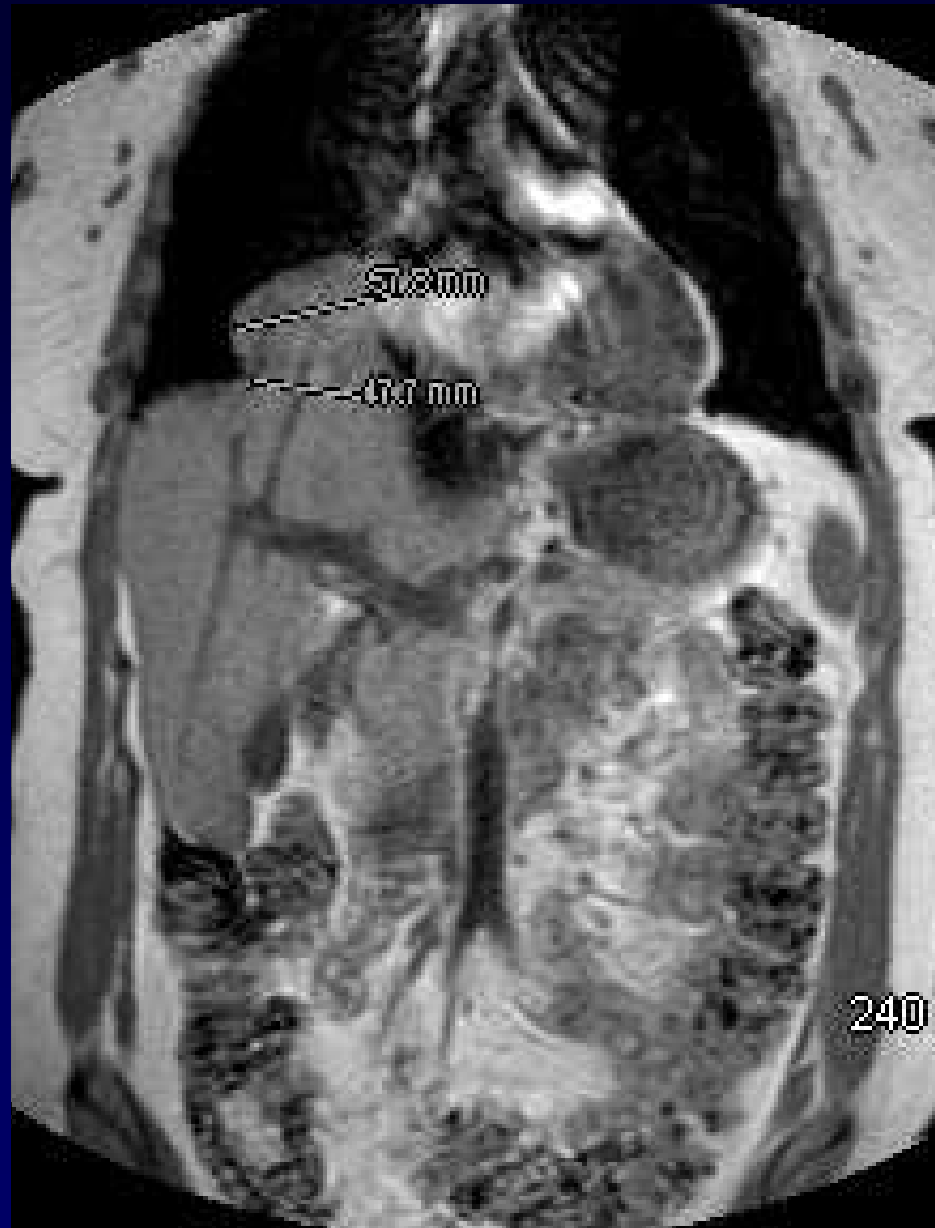

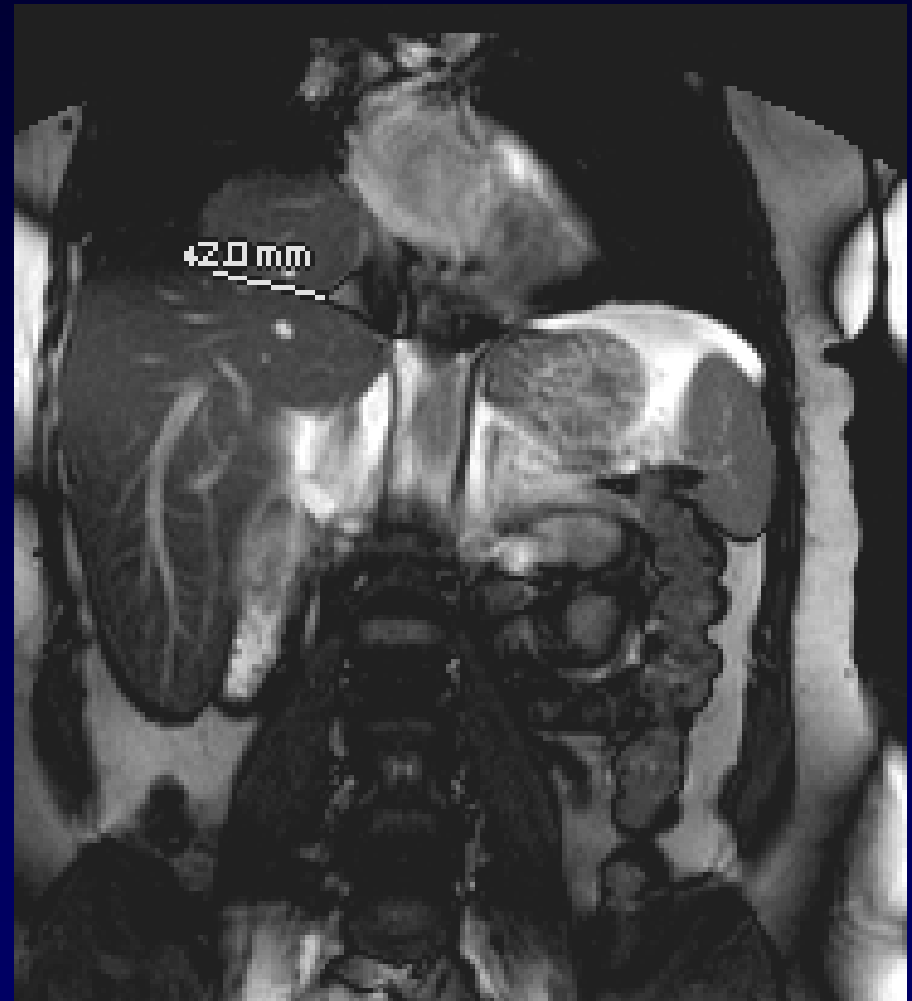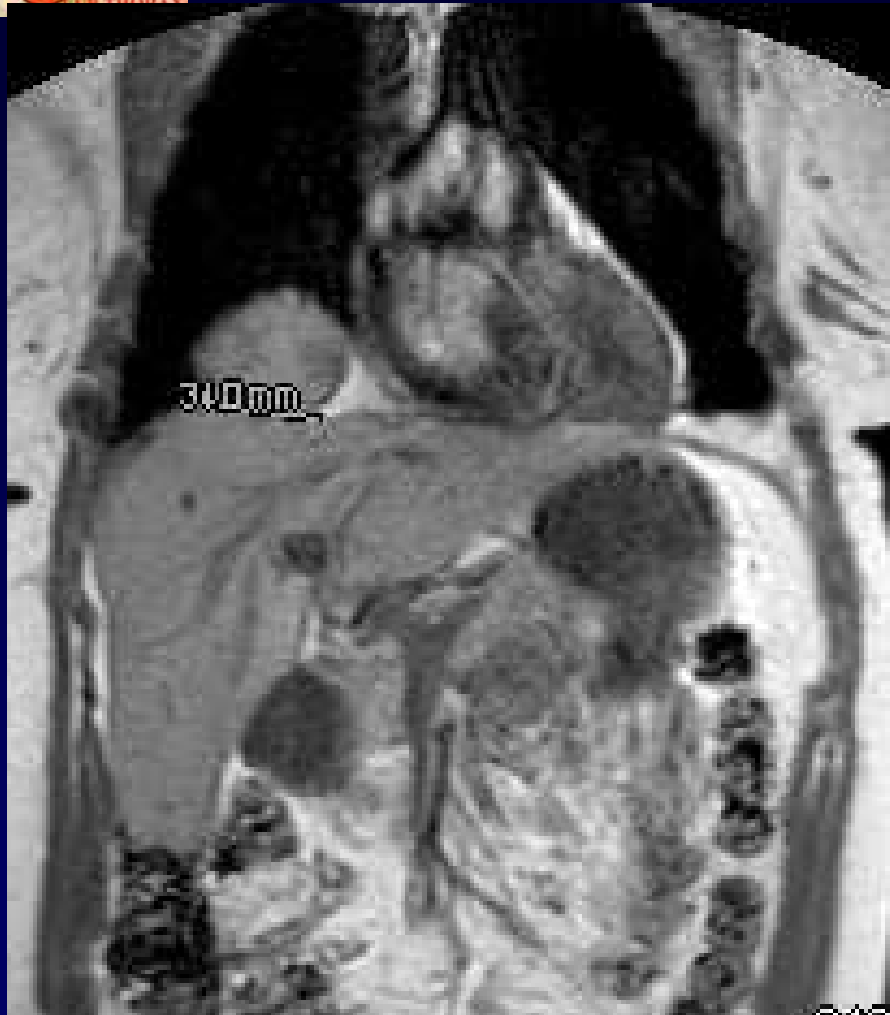J . GIRON – P . FAJADET

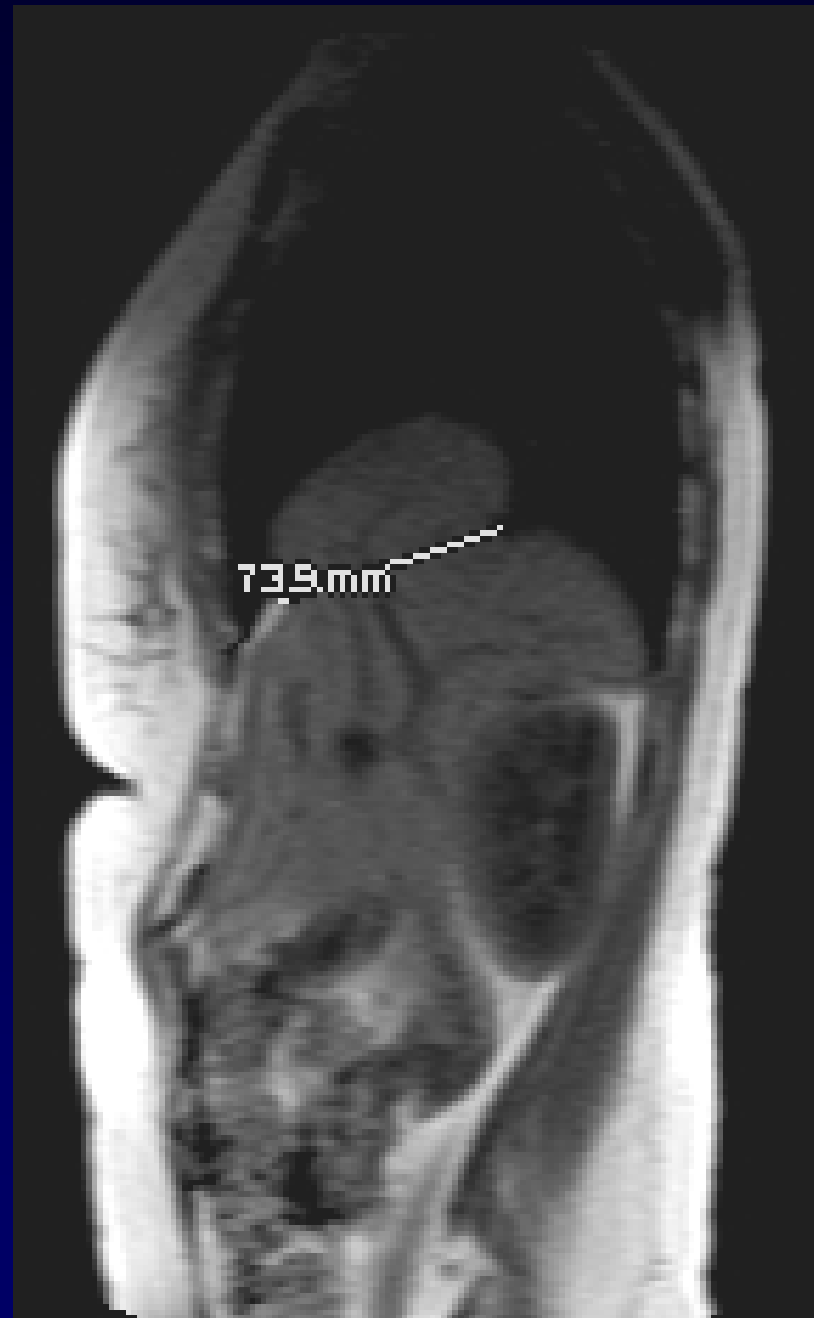
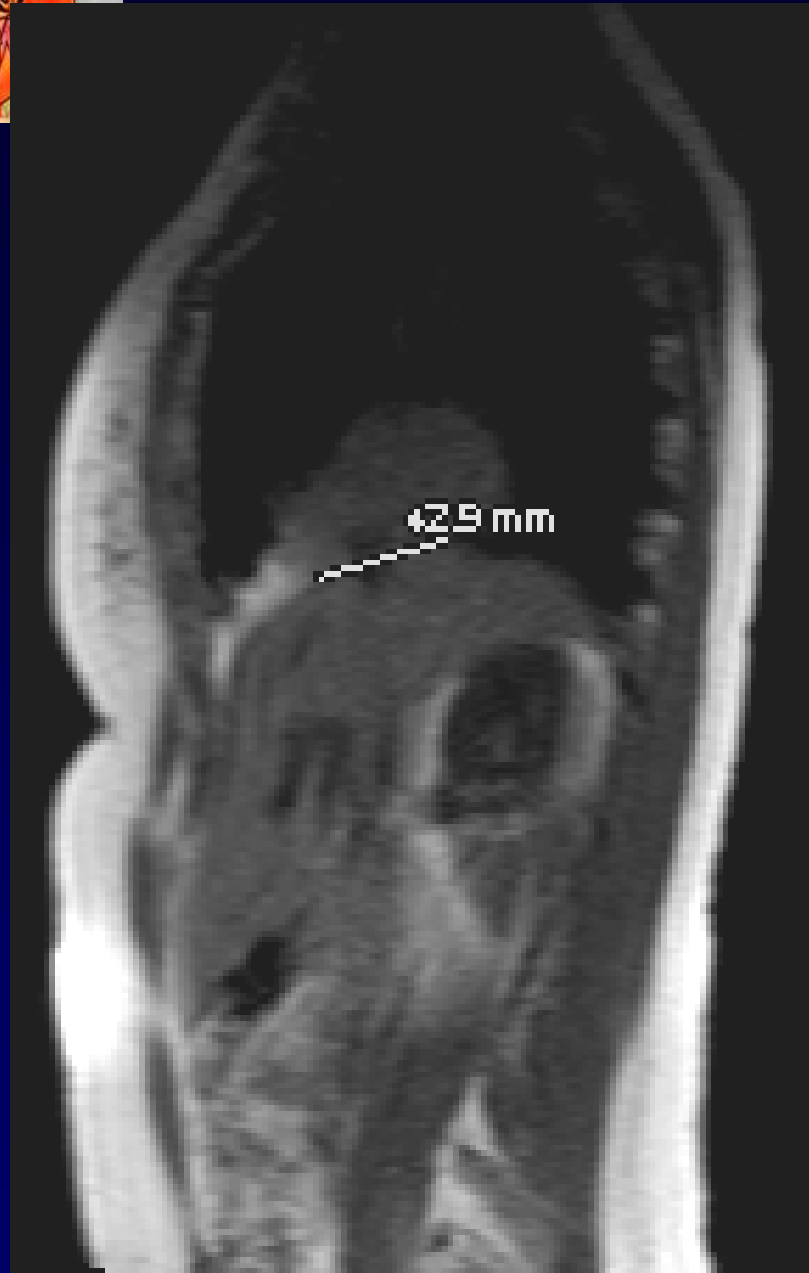
Femme de 50 ans

DOULEURS THORACIQUES RECENTES

IRM.... APRES RT ET TDM









Diagnostic ?

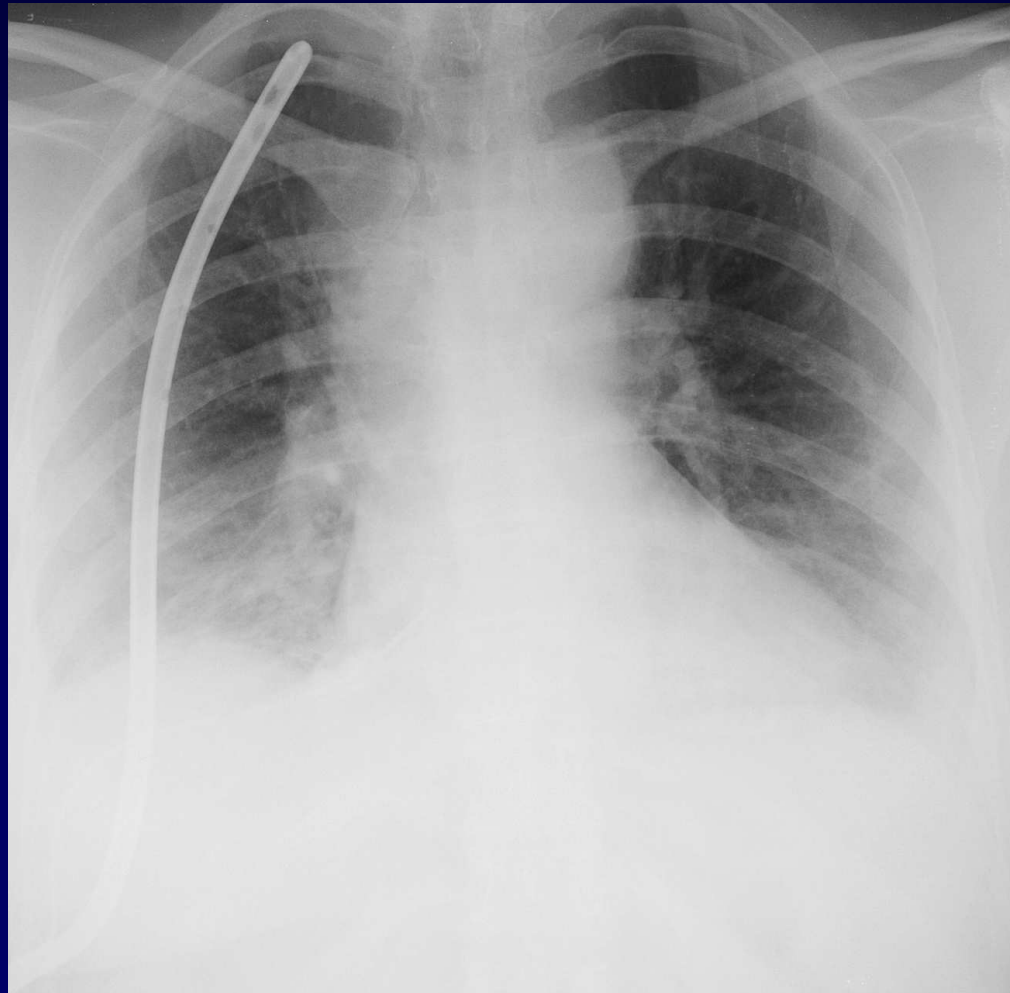


Diagnostic

**HERNIE HEPATIQUE
TRANS DIAPHRAGMATIQUE**



Chirurgie voie thoracique + plastie diaphragmatique





Discussion

ORIGINE : TRAUMATIQUE OU CONGENITALE ?