



**P FAJADET – J GIRON**

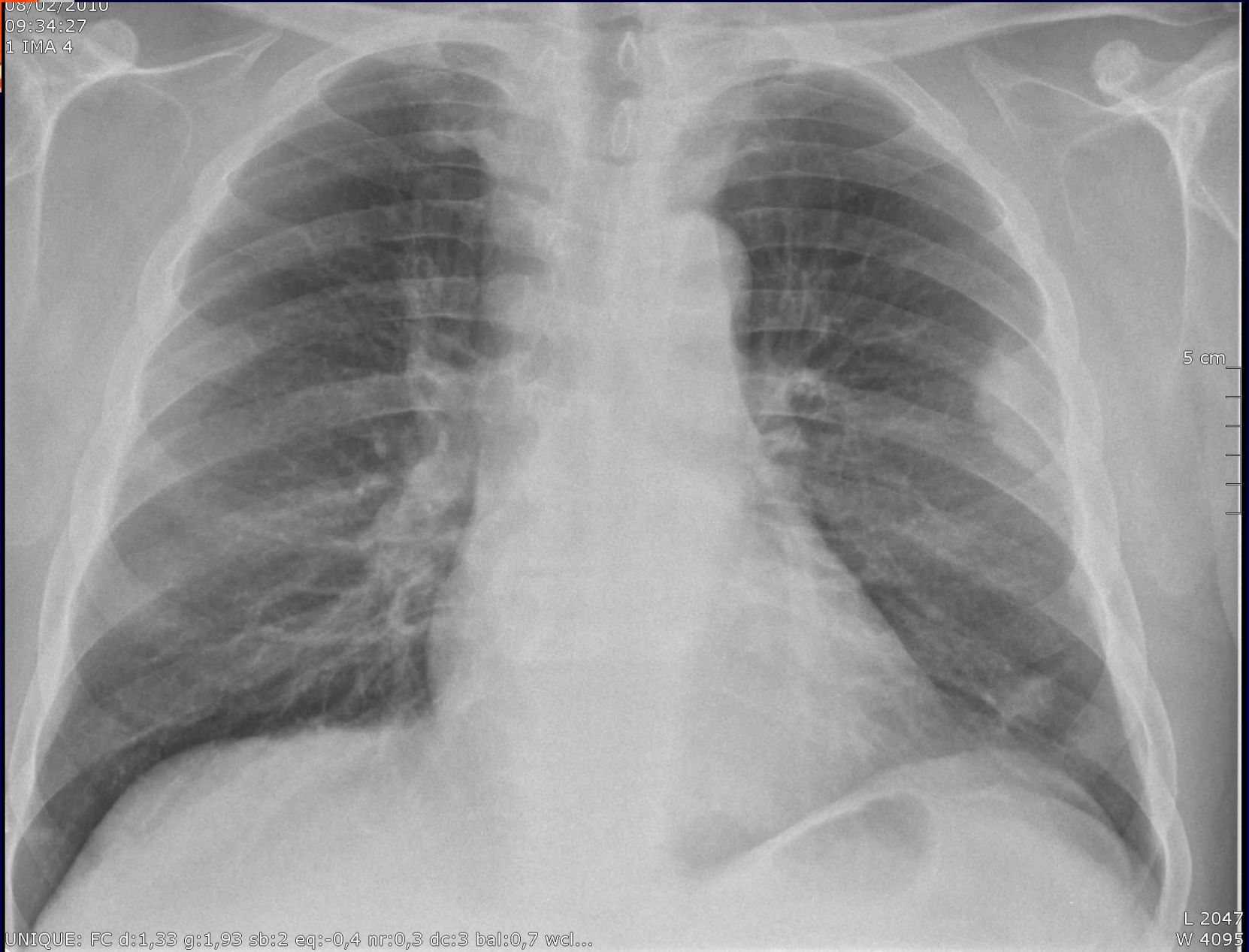
Homme de 64 ans

Clinique : RAS

Radio thorax pré-opératoire

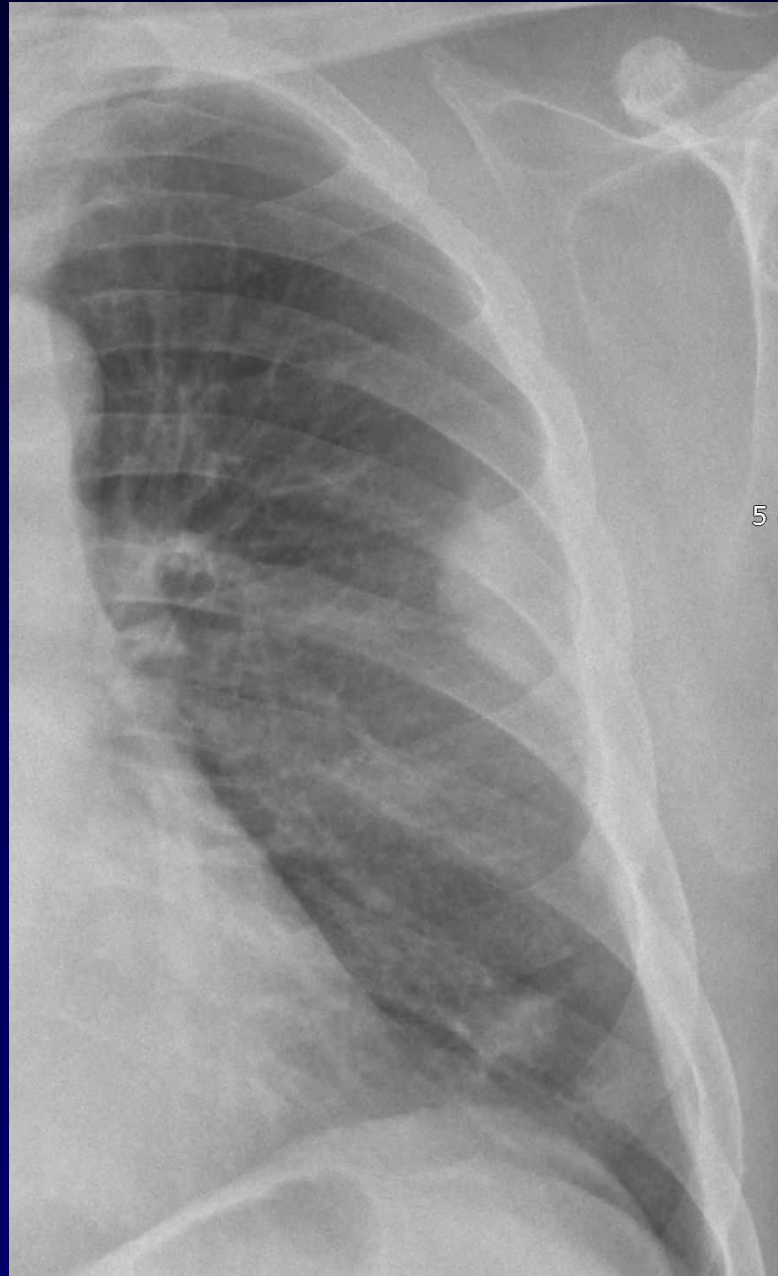

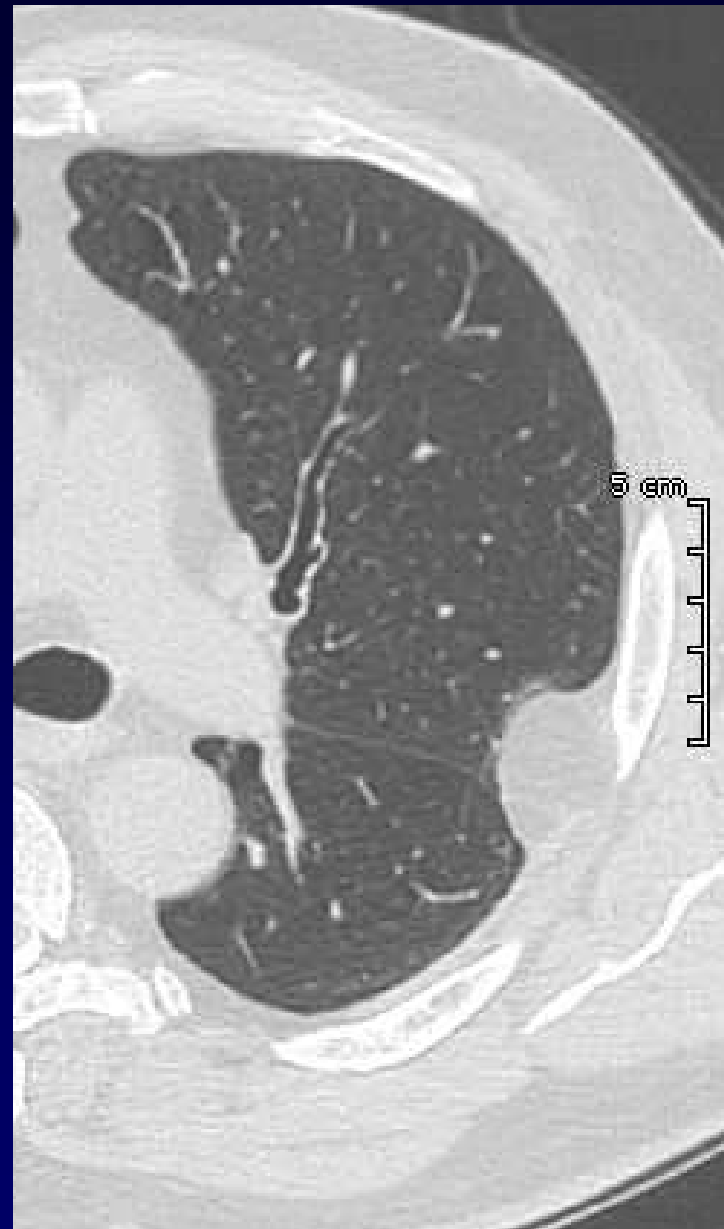
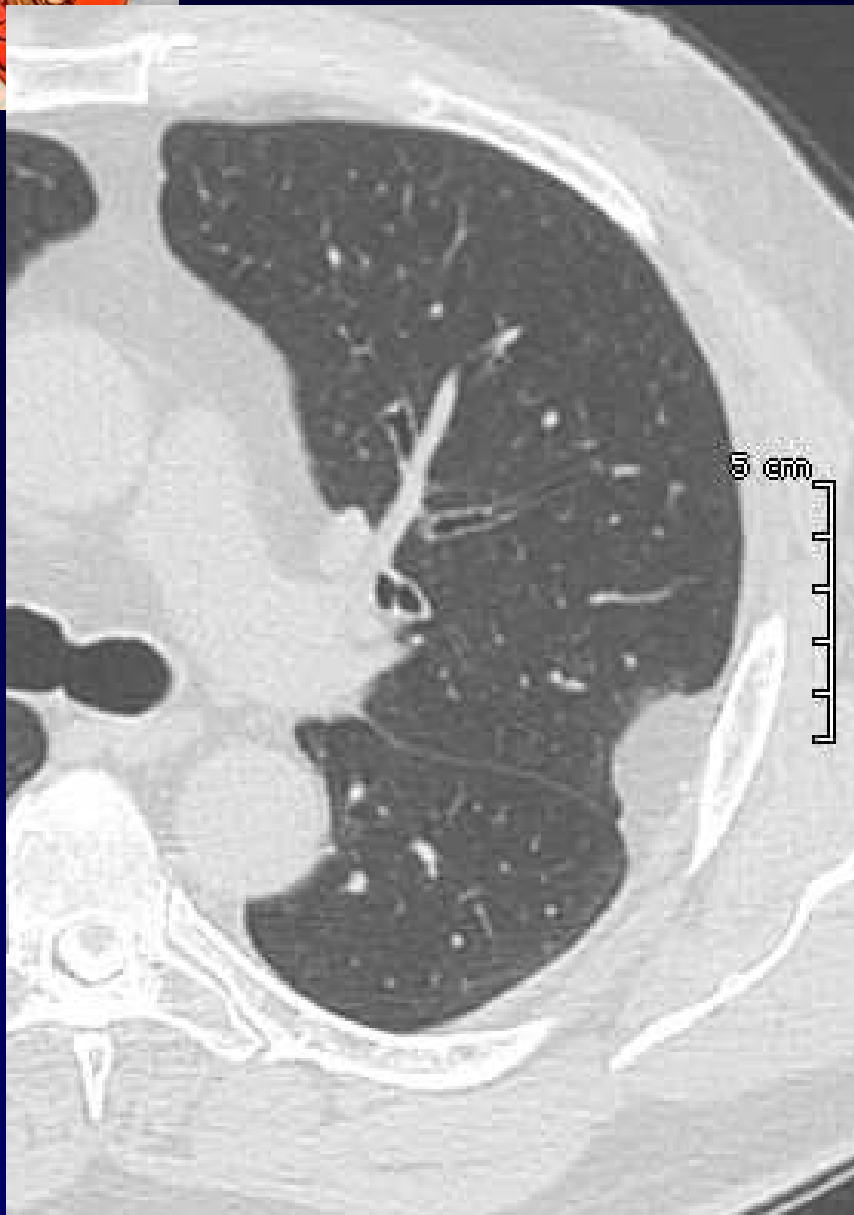08/02/2010  
09:34:27  
1 IMA 4

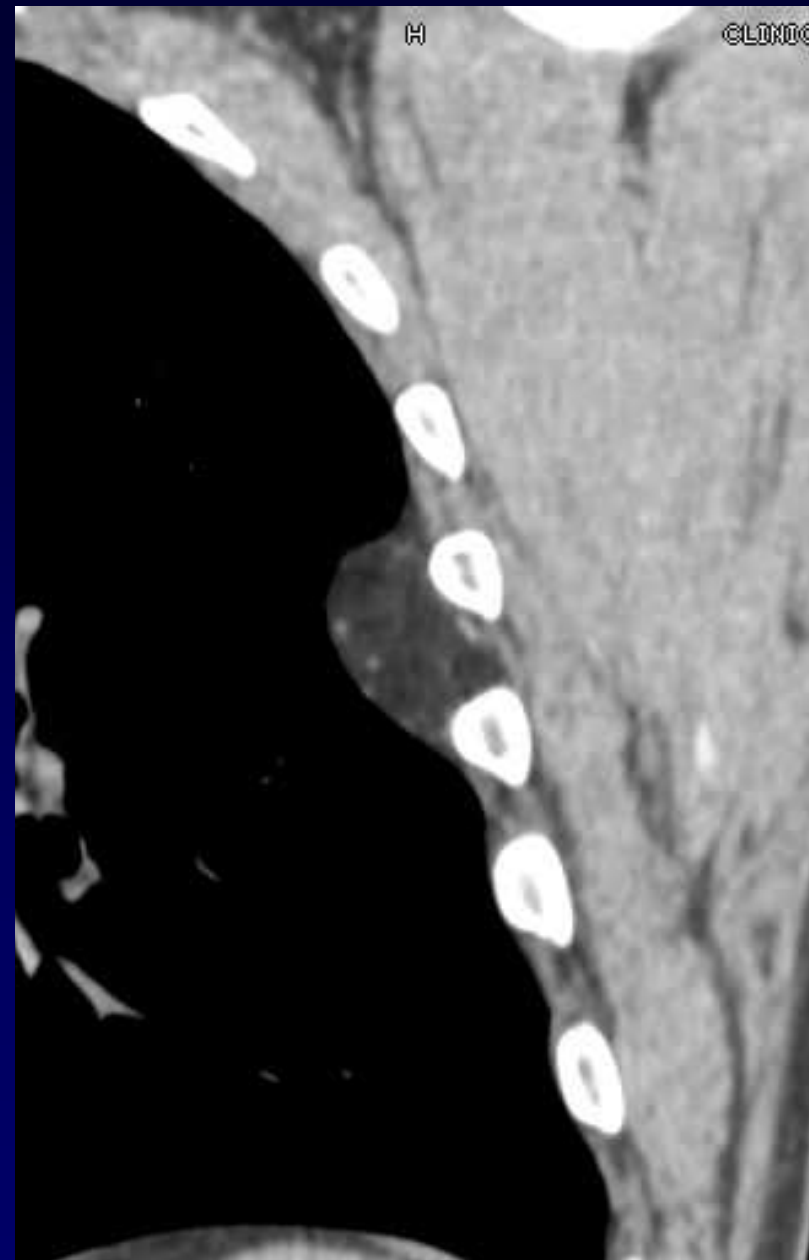
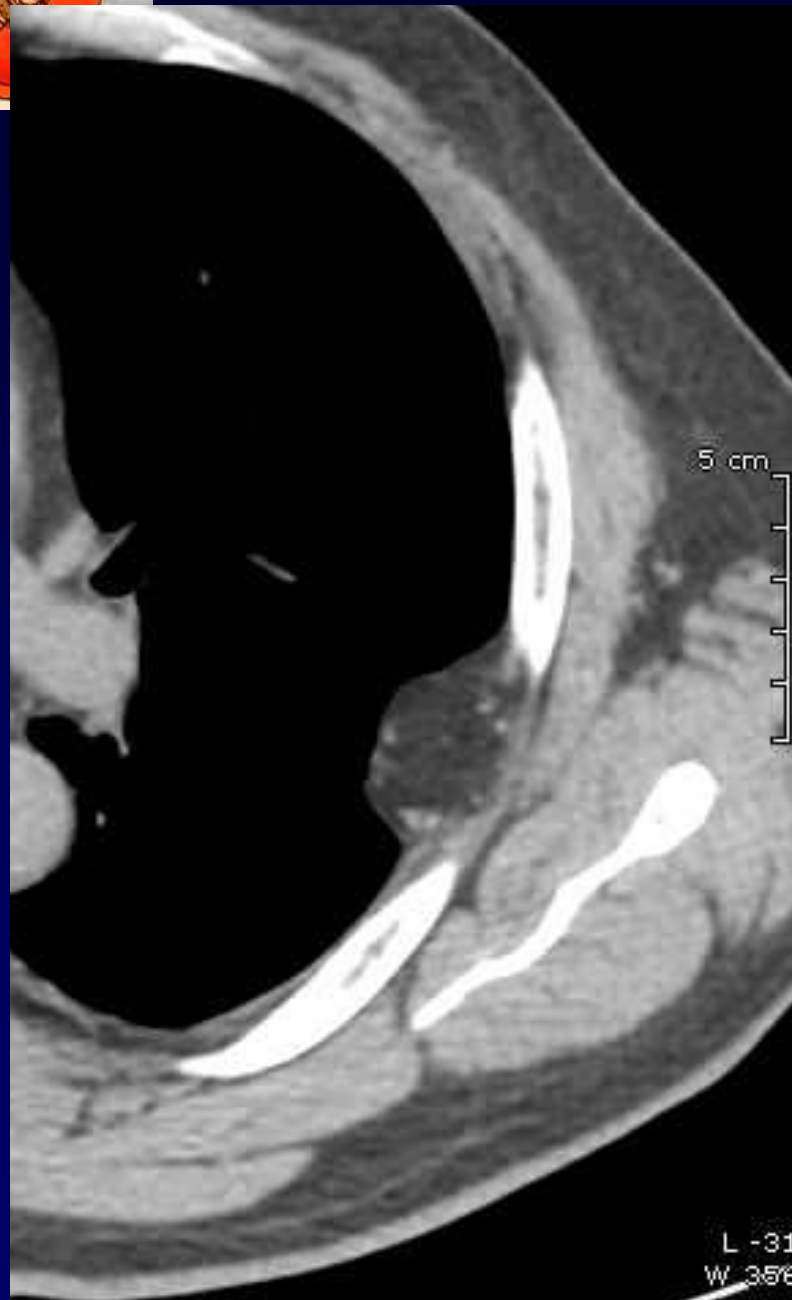


UNIQUE: FC d:1,33 g:1,93 sb:2 eq:-0,4 nr:0,3 dc:3 bal:0,7 wcl...

L 2047  
W 4095









**Diagnostic ?**



**Diagnostic**

**Lipome pleural**