

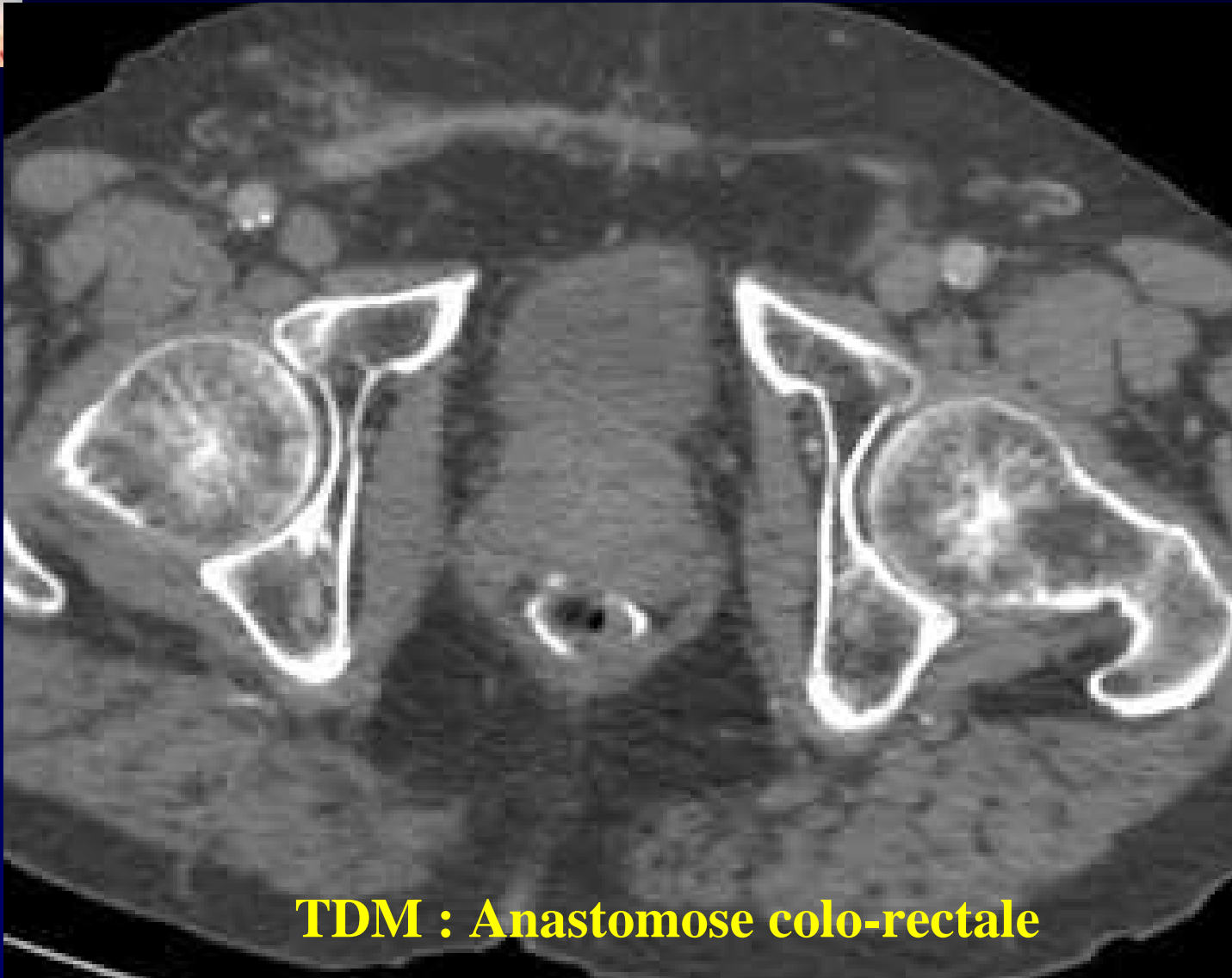
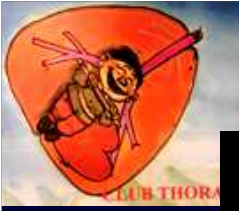

P FAJADET – J GIRON

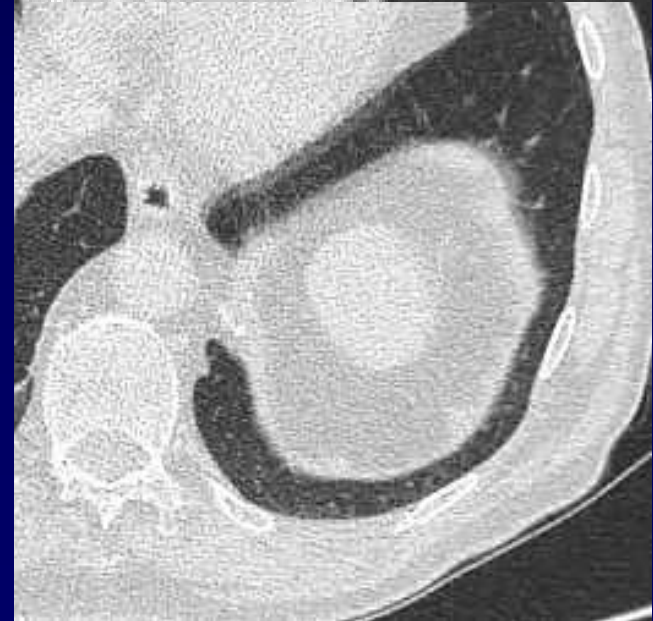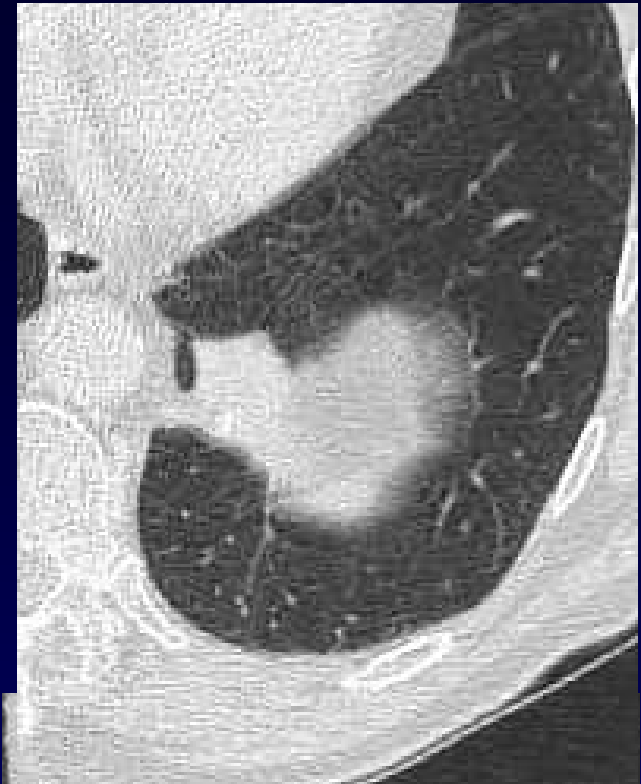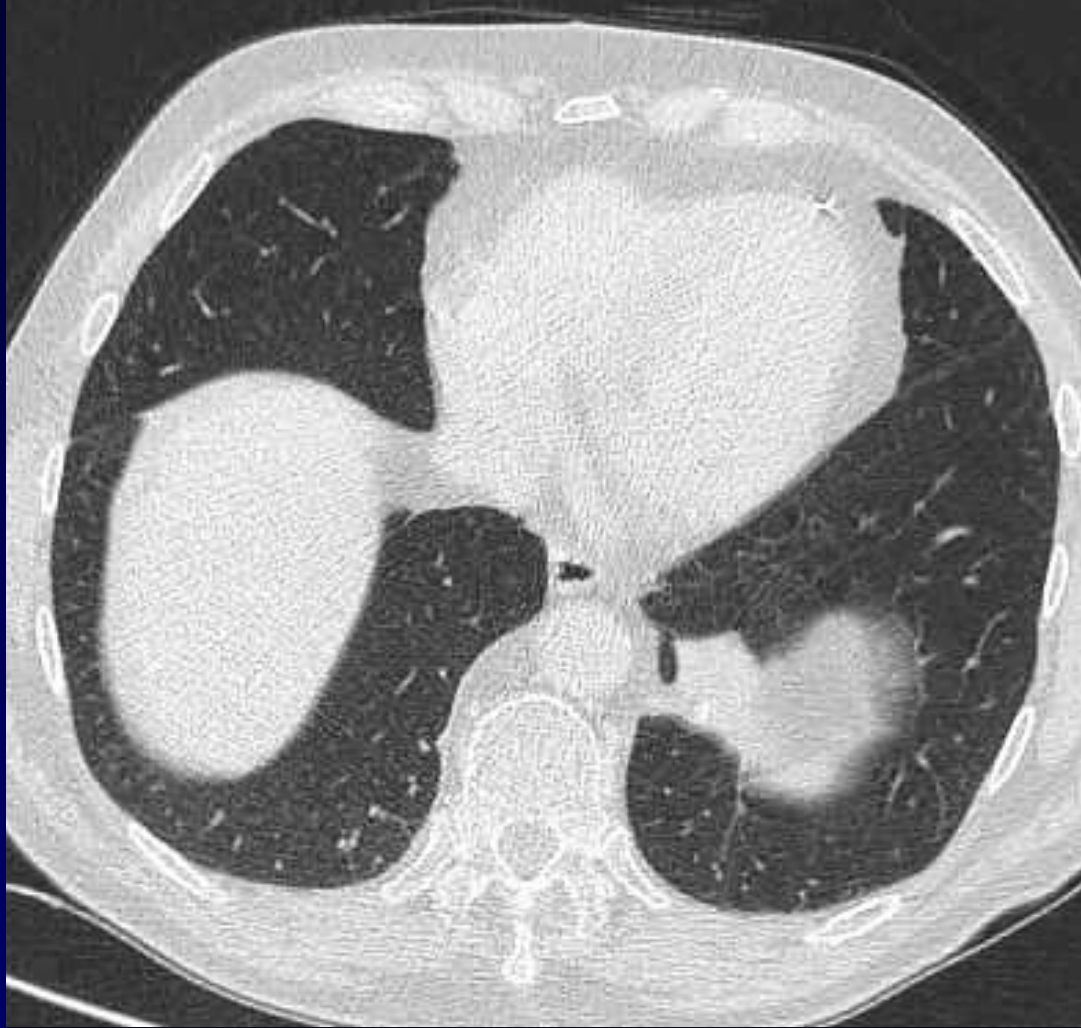
Homme de 82 ans

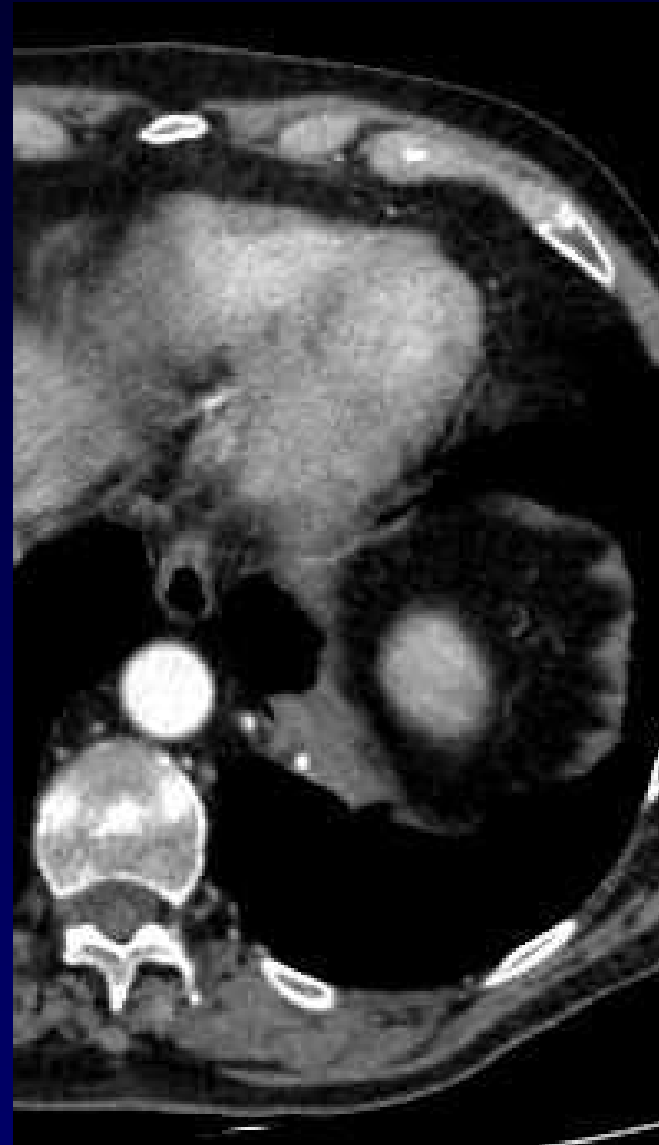
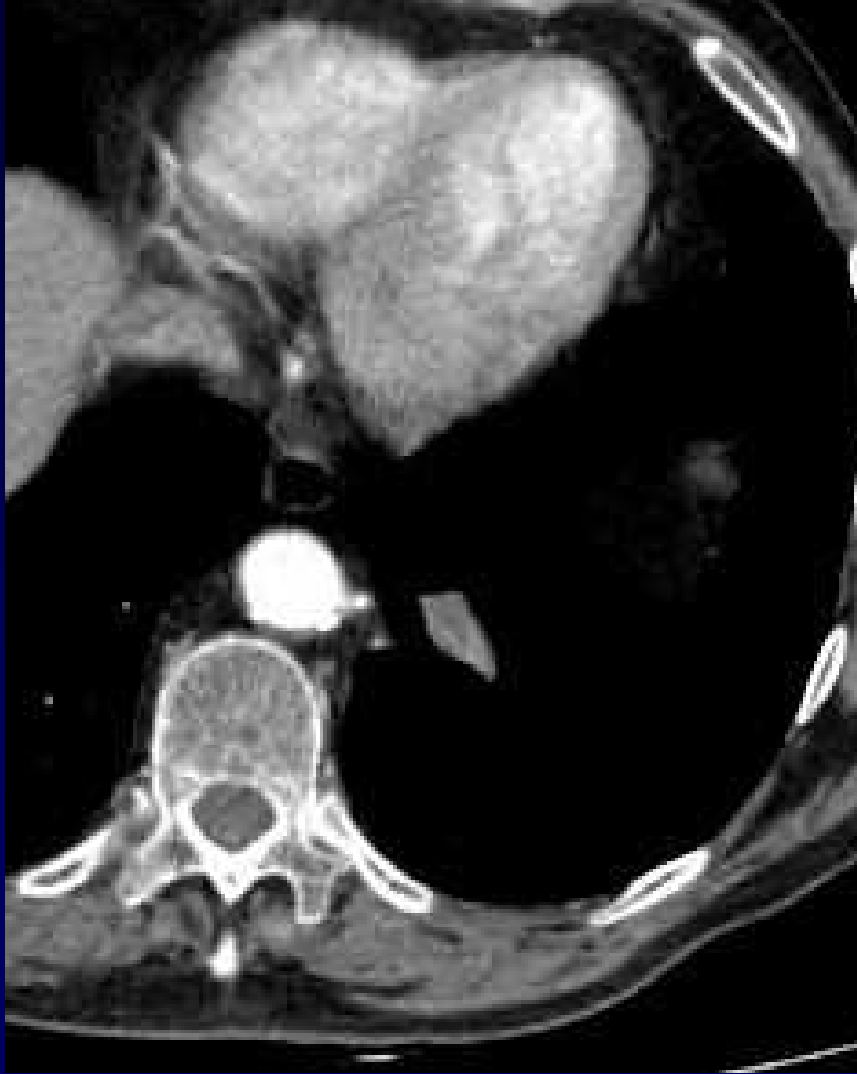Surveillance de rectum opéré

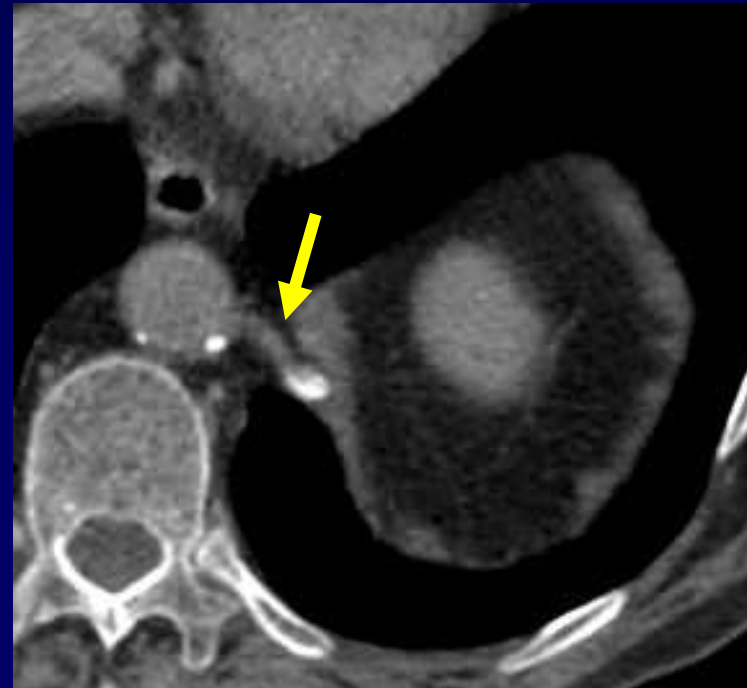
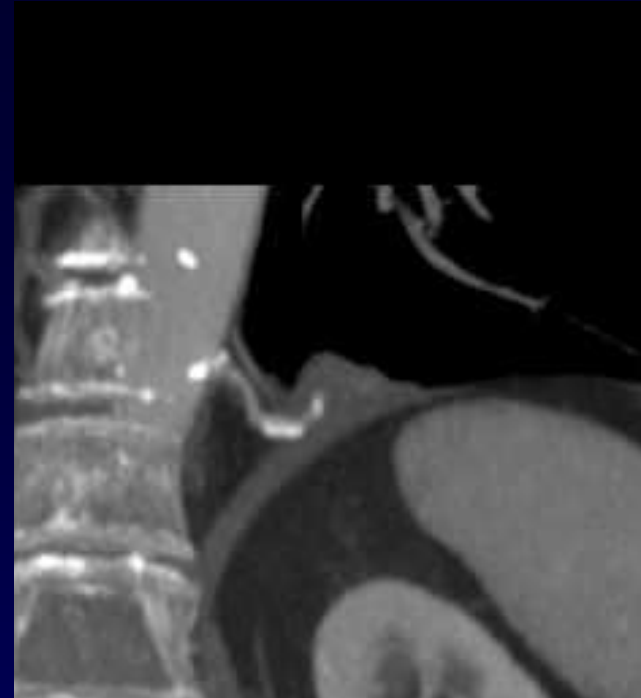
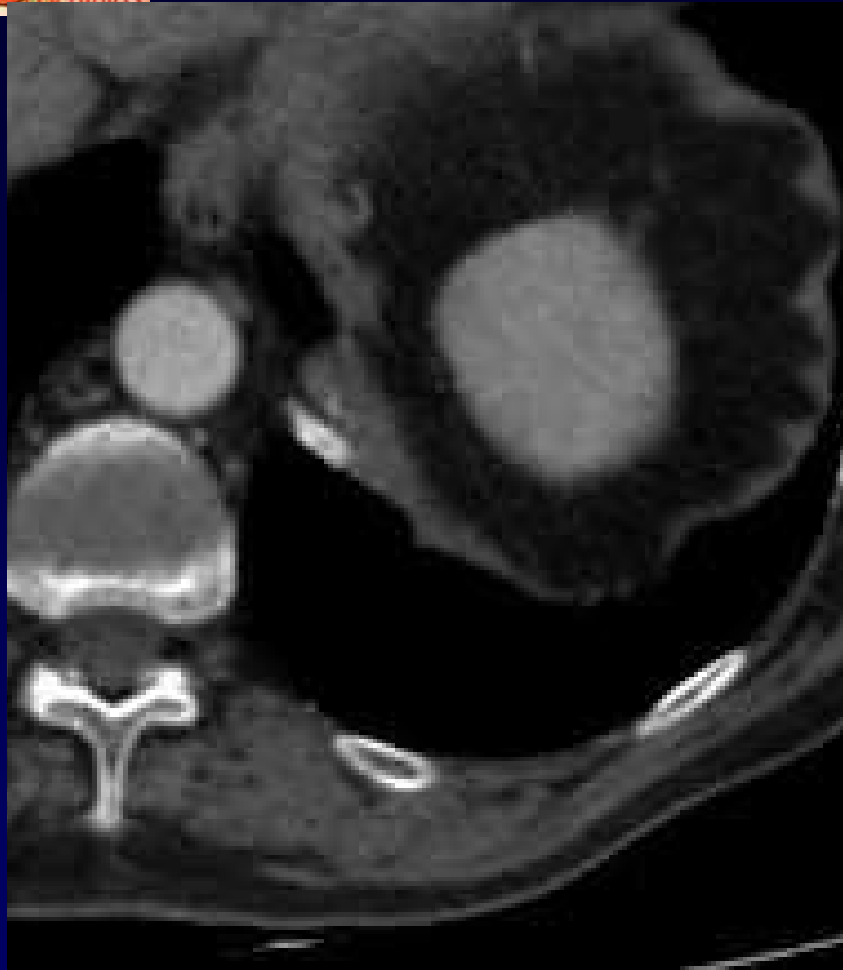
ACE Normal



TDM : Anastomose colo-rectale









Diagnostic ?



Diagnostic

**Séquestration S 10 G avec calcification
(et thrombose ?) de l'artère afférente**