



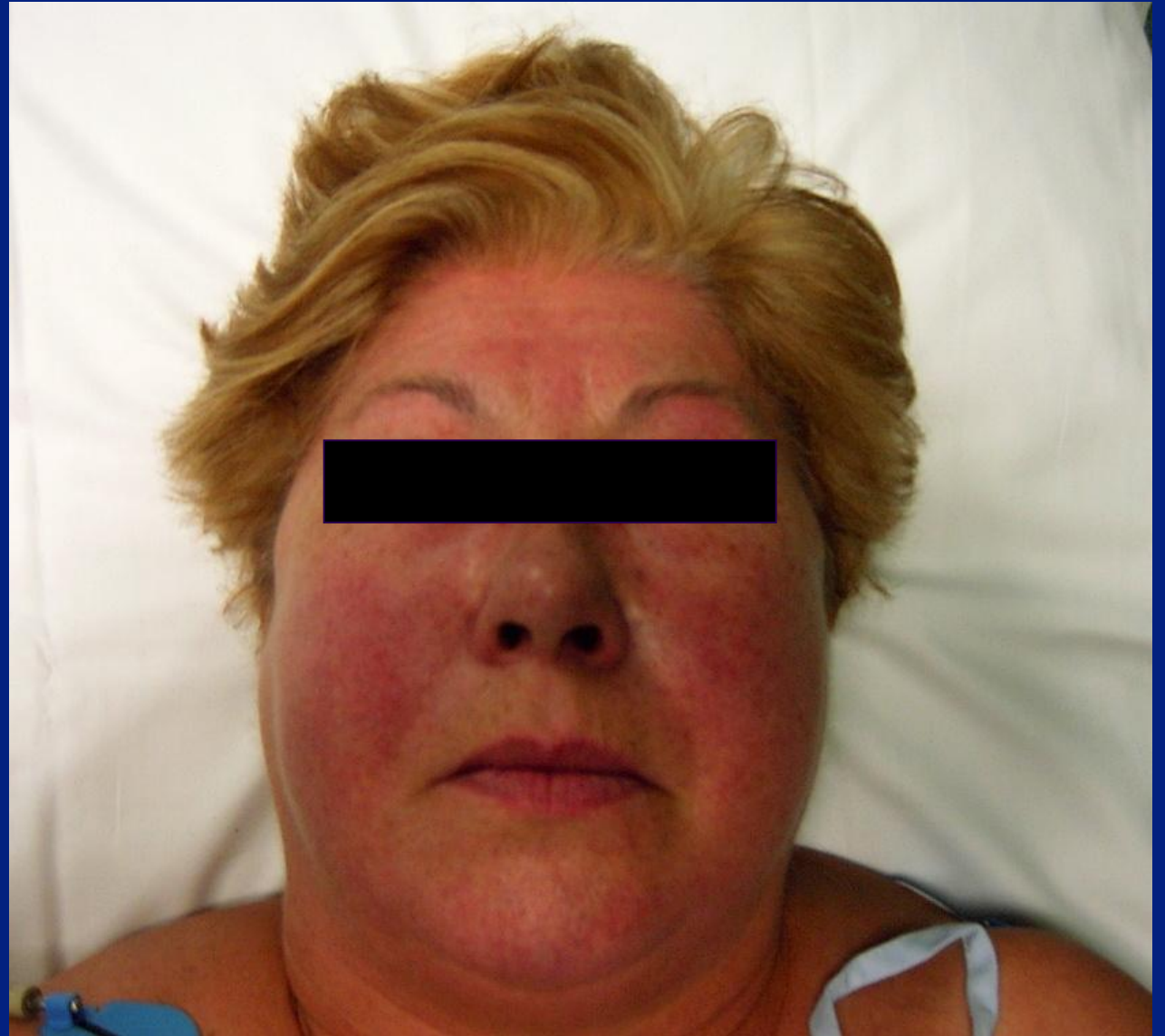M El Hajjam
P Lacombe



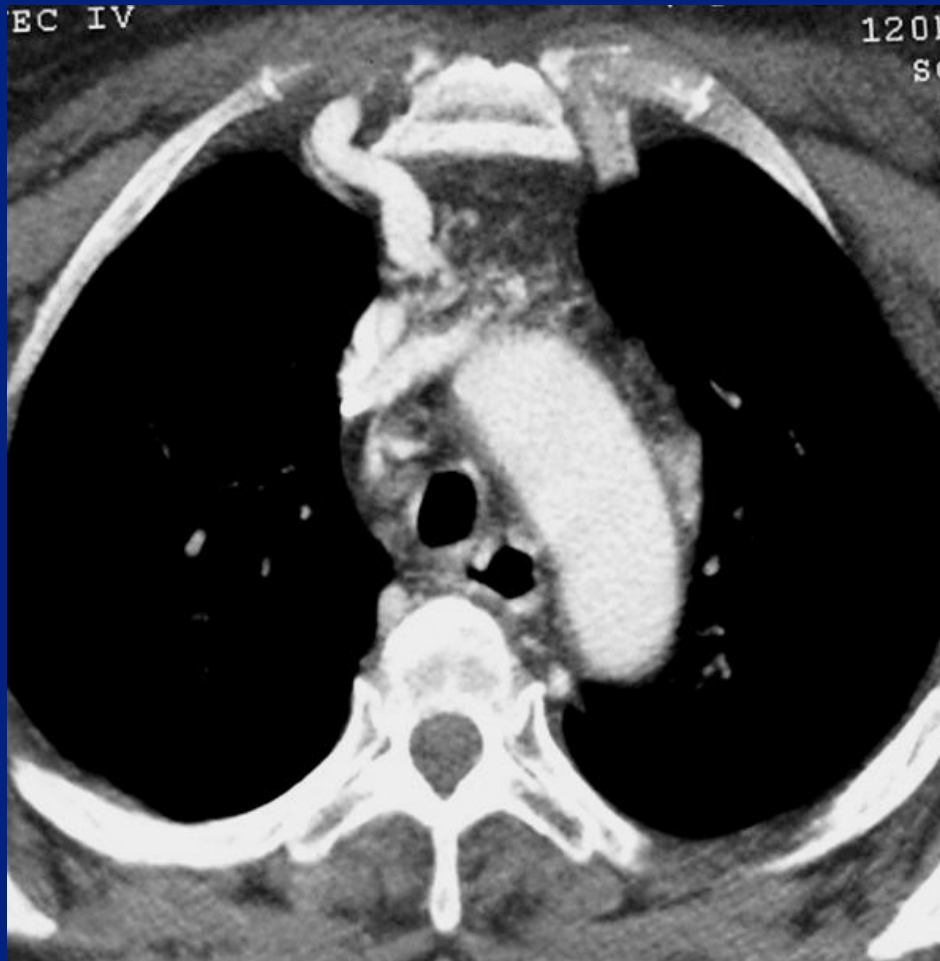
La qualité au meilleur prix

55 ans,
Kc. du sein
Chimiothérapie

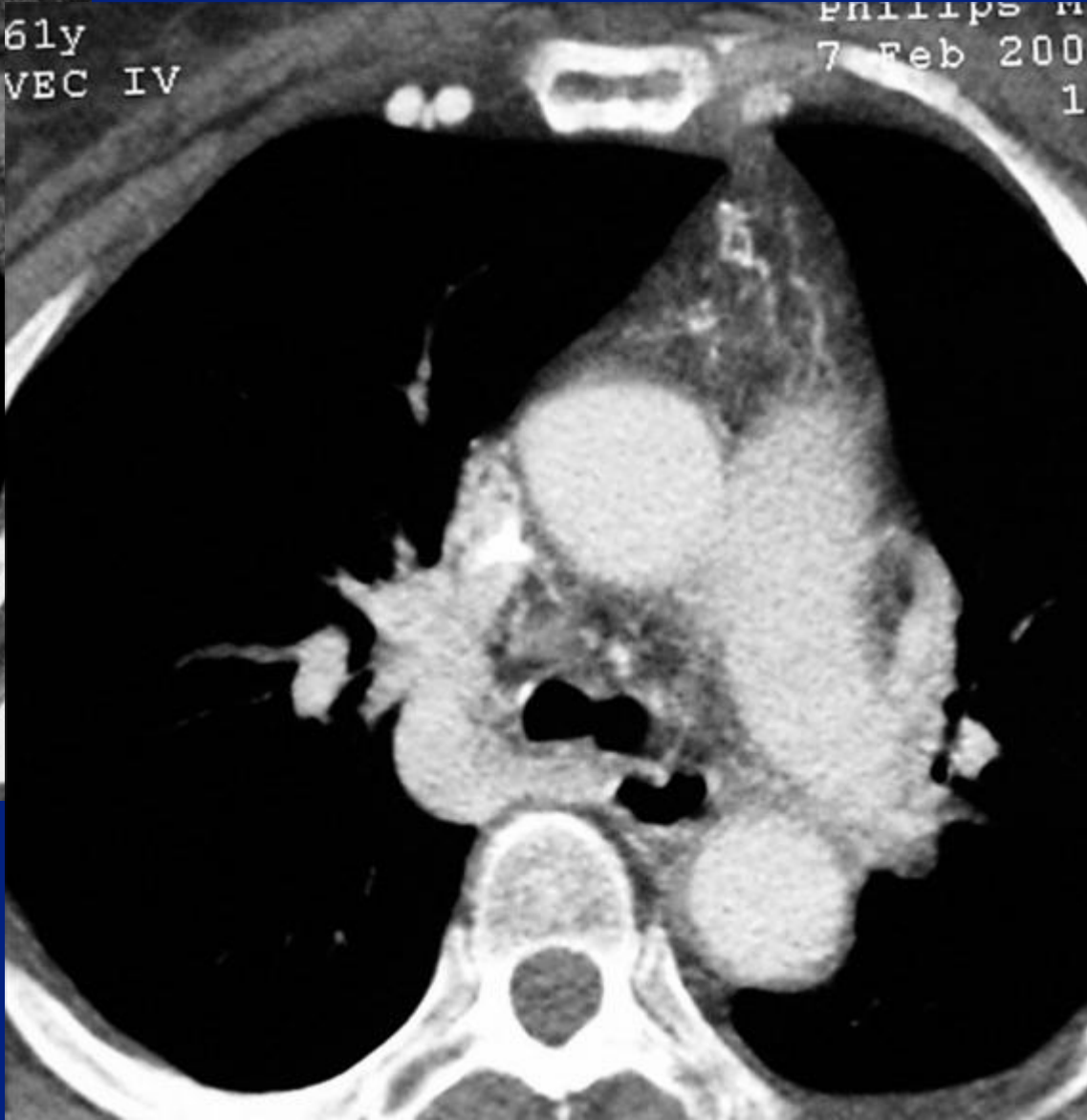SCS



EC IV



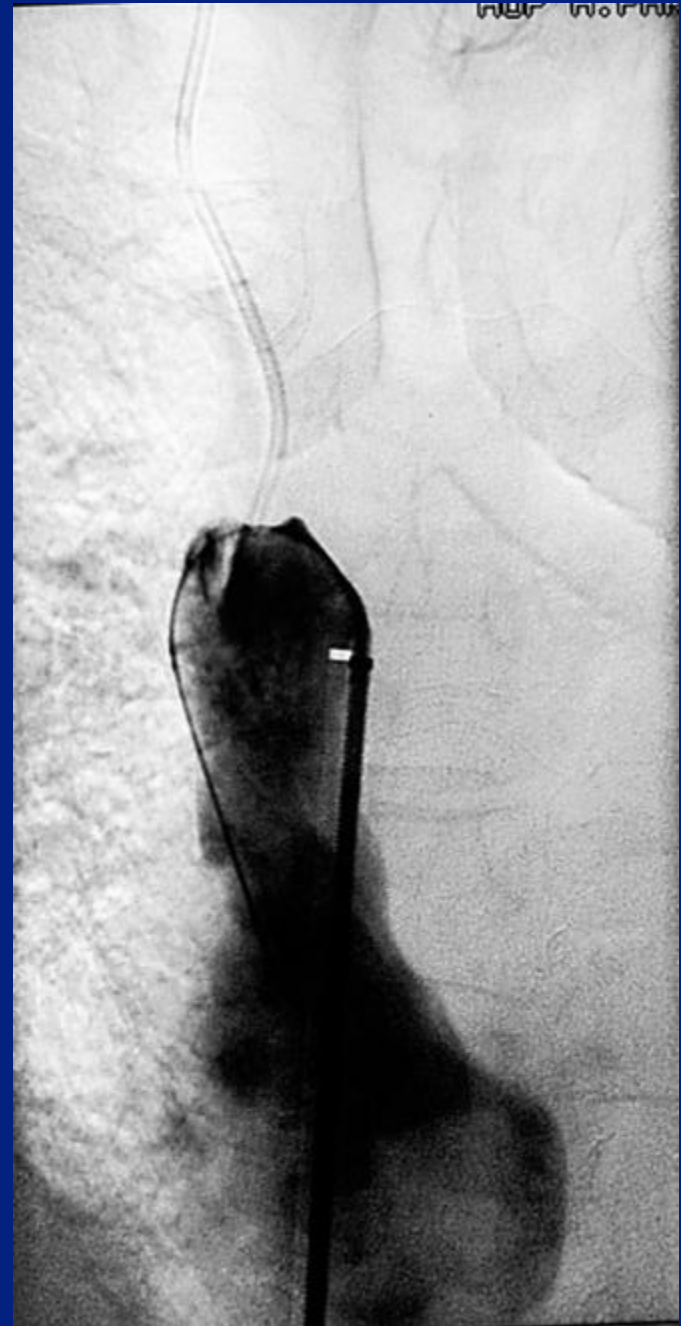120kV,
SC 40
SW 5
61y
VEC IV



PHILIPS
7 Feb 200
1

VCS occluse
Obstacle infranchissable

Que faire ?



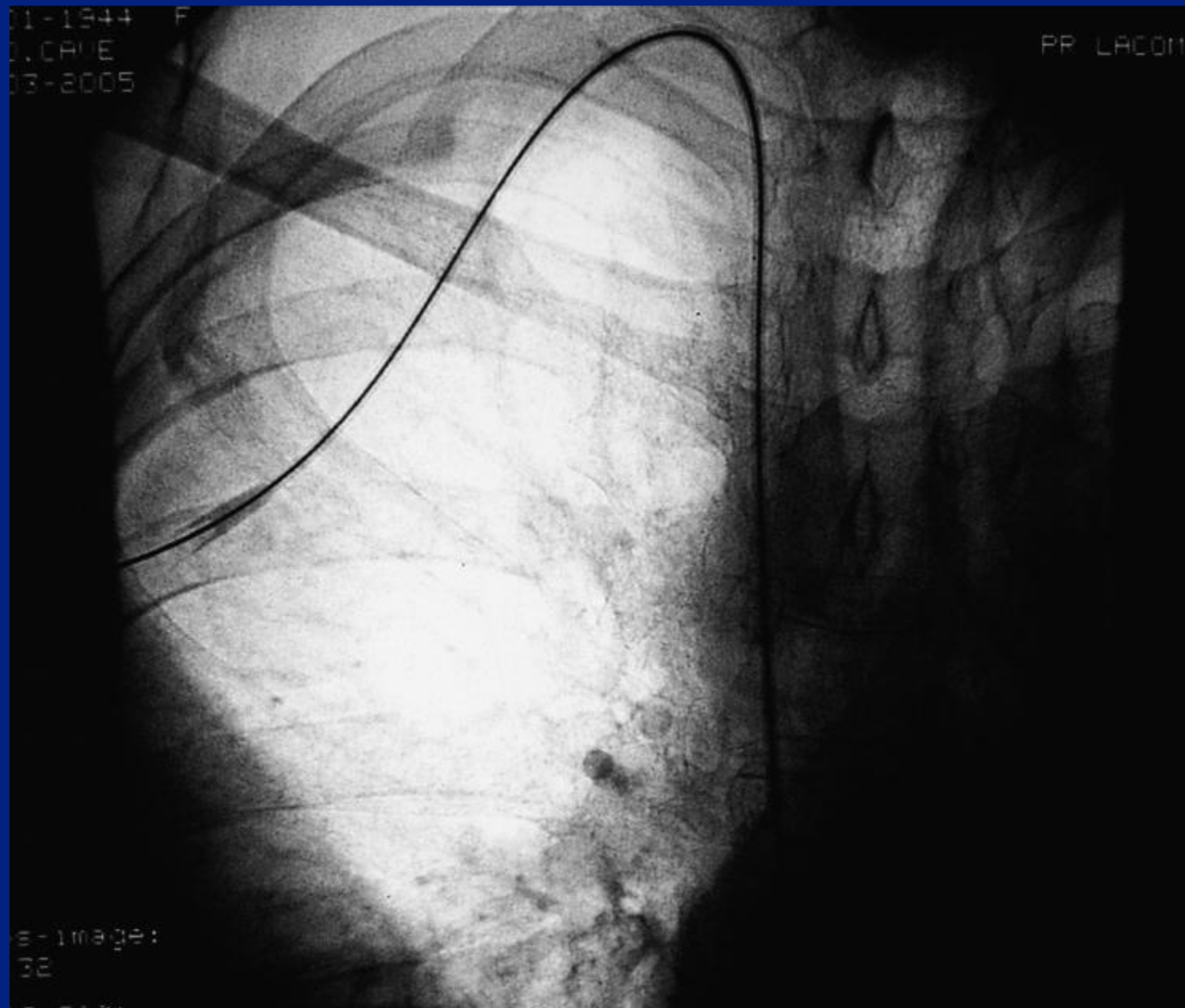

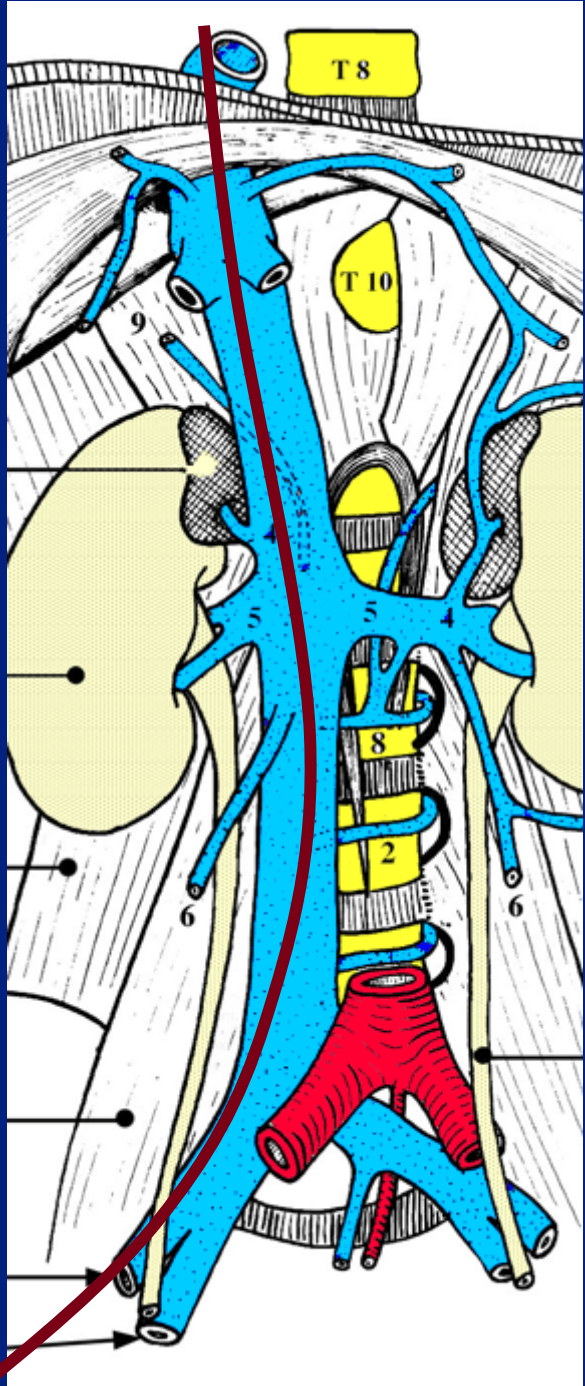
**BRICO
VASC
arrive...!**

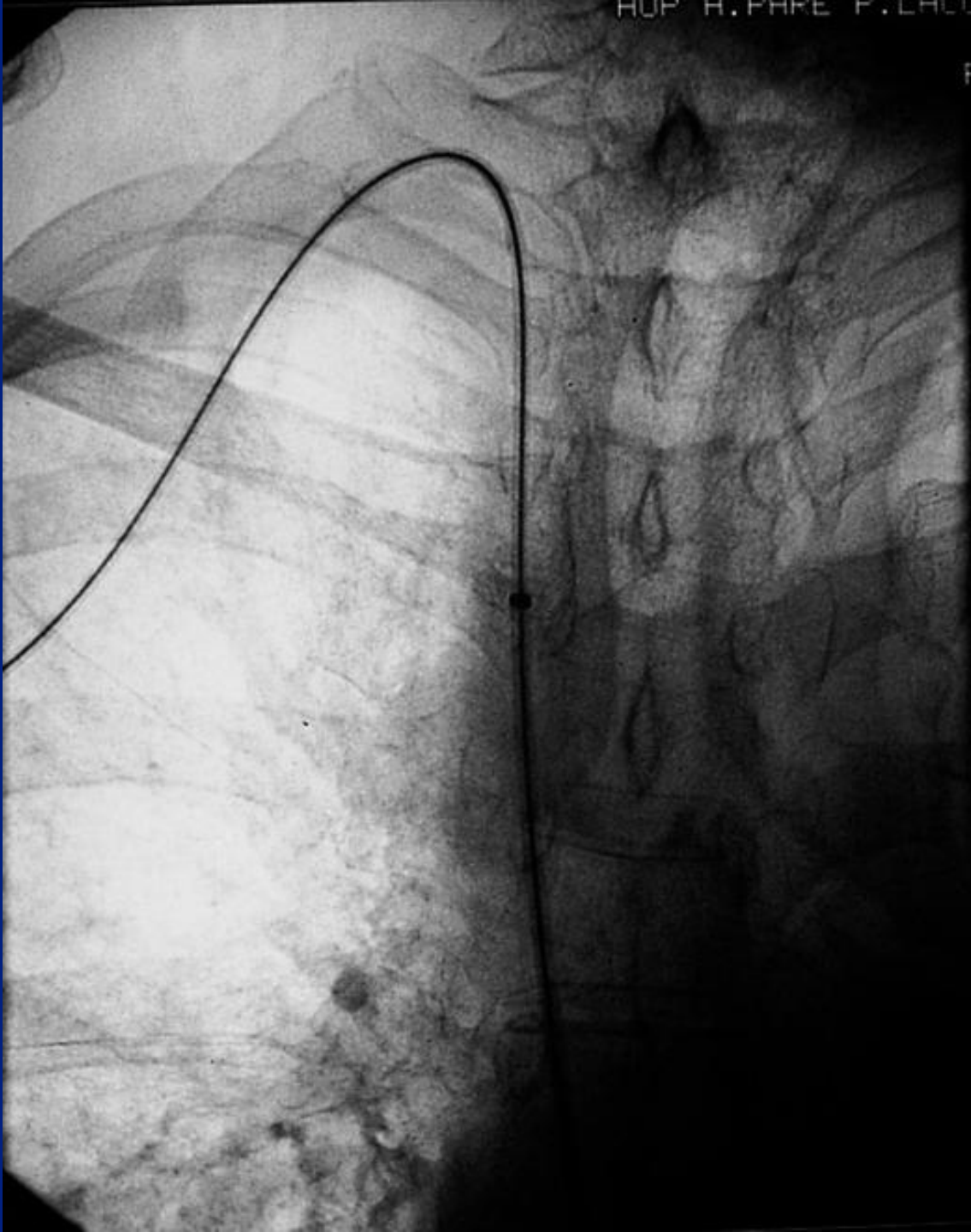
01-1944 F
D. CADE
03-2005

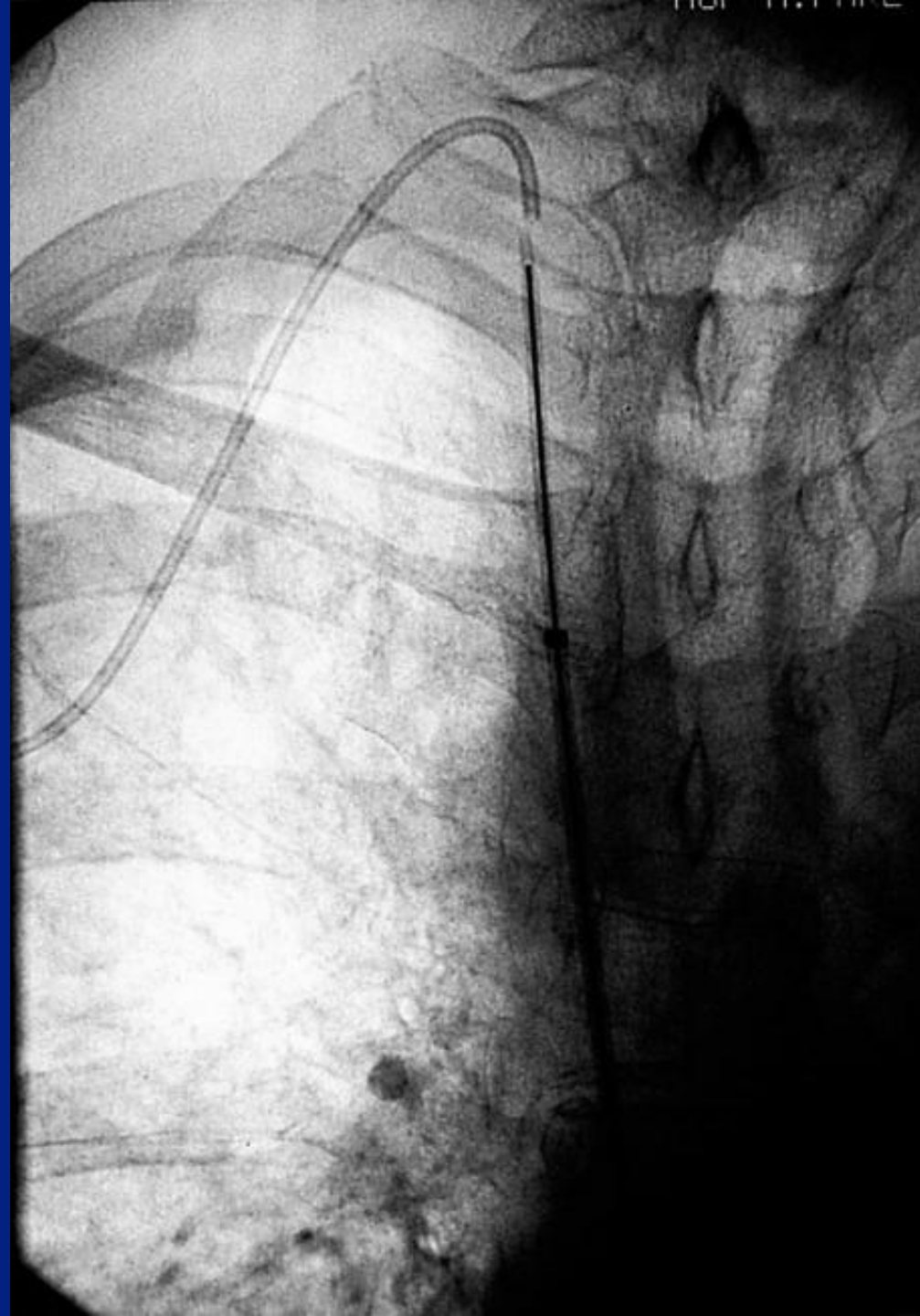
PP LACOM

01 - image:
01



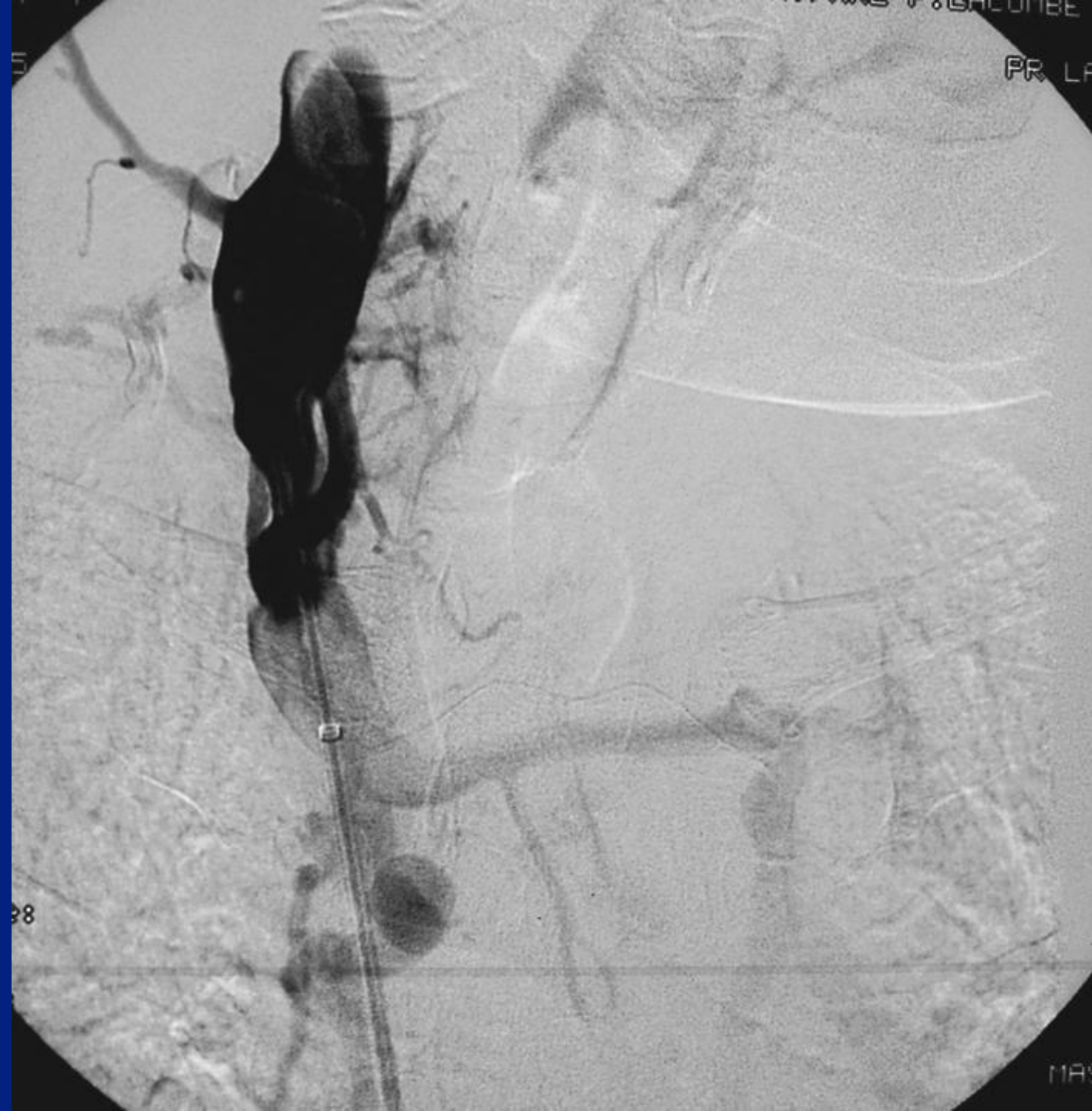





WAS V. SACOMBE

PR LA



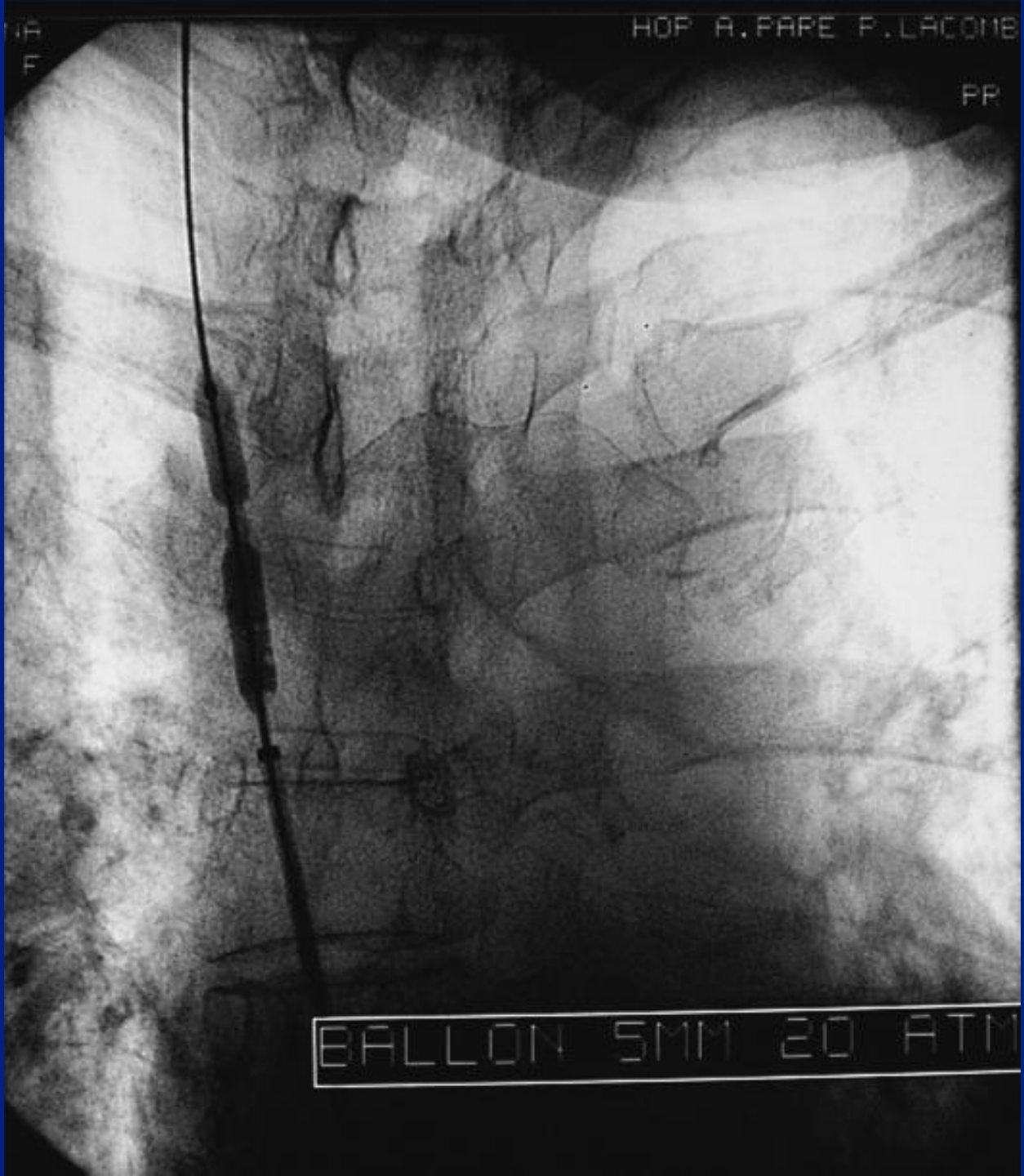
88

MAR

HOP A. PARE P. LACONTE

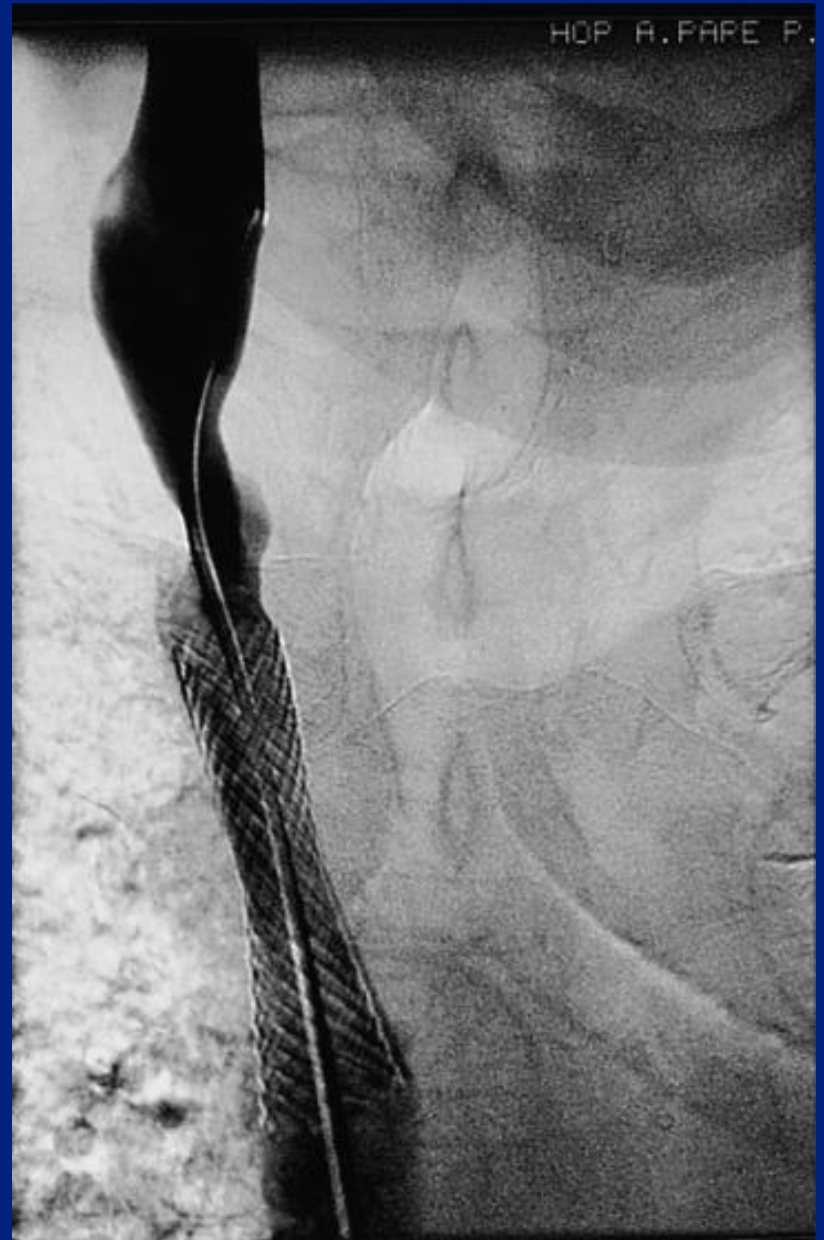
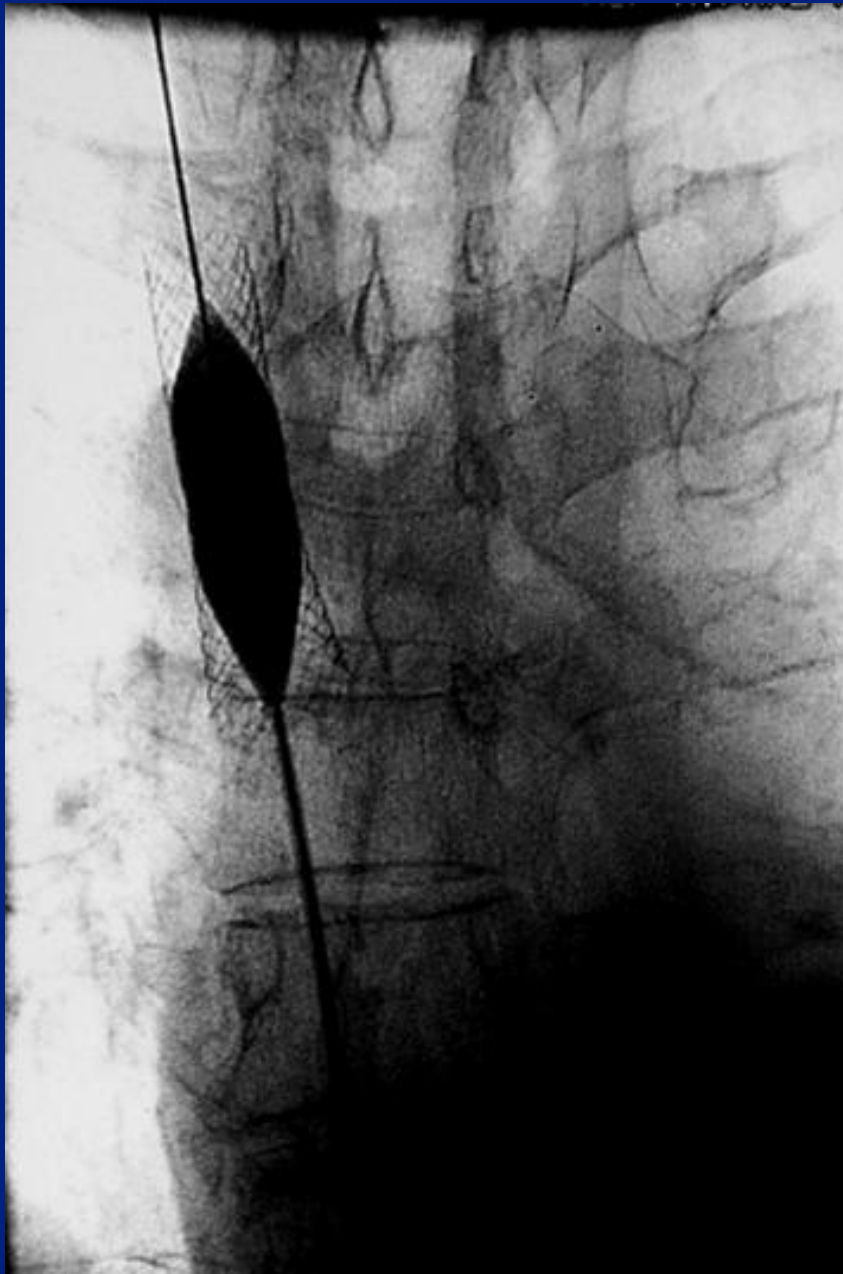
PP

BALLON 5MM 20 ATM

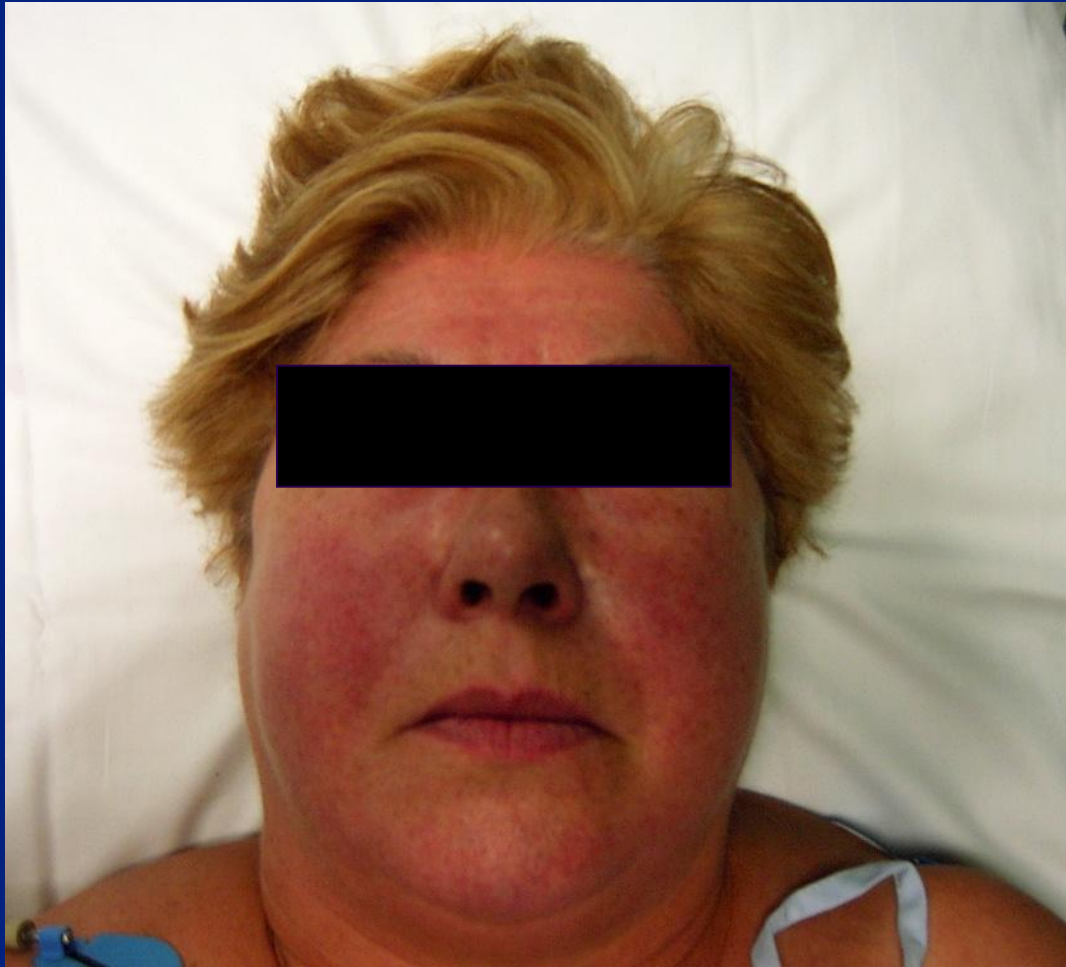

A longitudinal B-mode ultrasound image of a blood vessel. A stent is visible as a dark, mesh-like structure within the vessel lumen. Two balloons are positioned on either side of the stent, appearing as dark, elongated structures. The vessel wall is visible as a bright, curved line at the top of the image. The overall image is in grayscale with a blue background.

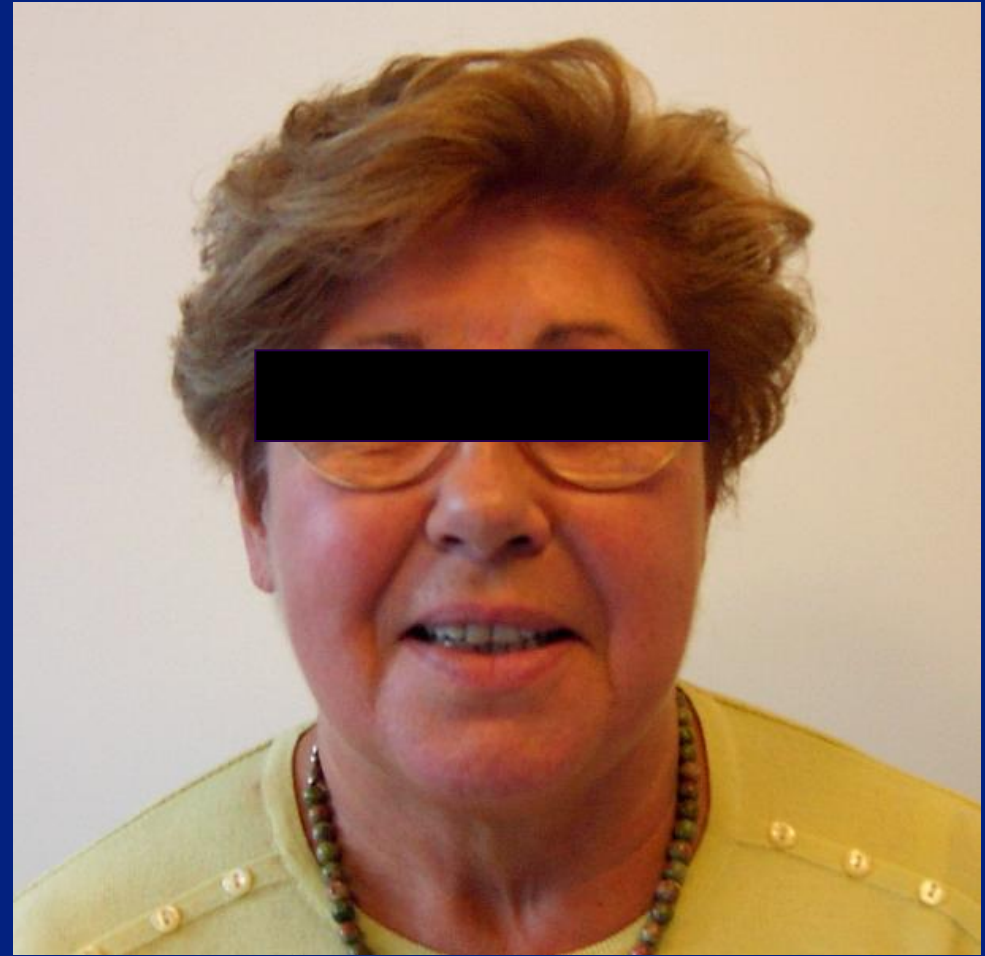BALLONS 6-8-12MM



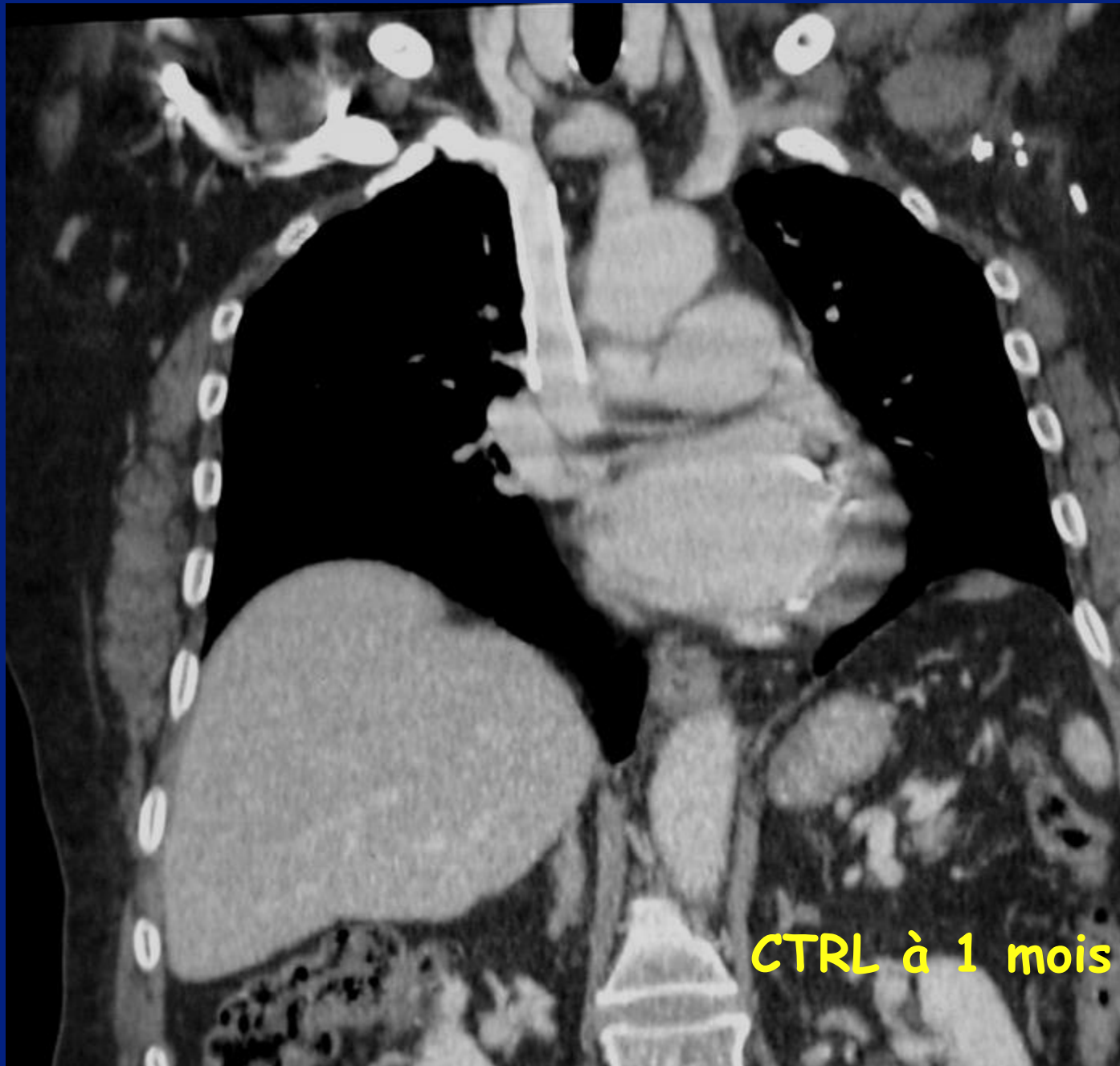
Résultat final



Avant



1 semaine après TTT



CTRL à 1 mois

Site implantable = Fil d'Ariane



Ne jamais le retirer avant le franchissement
de l'obstacle cave supérieur



Dionysos et Ariane
400-375 AV JC

Prévention : Pose correcte des sites implantables

