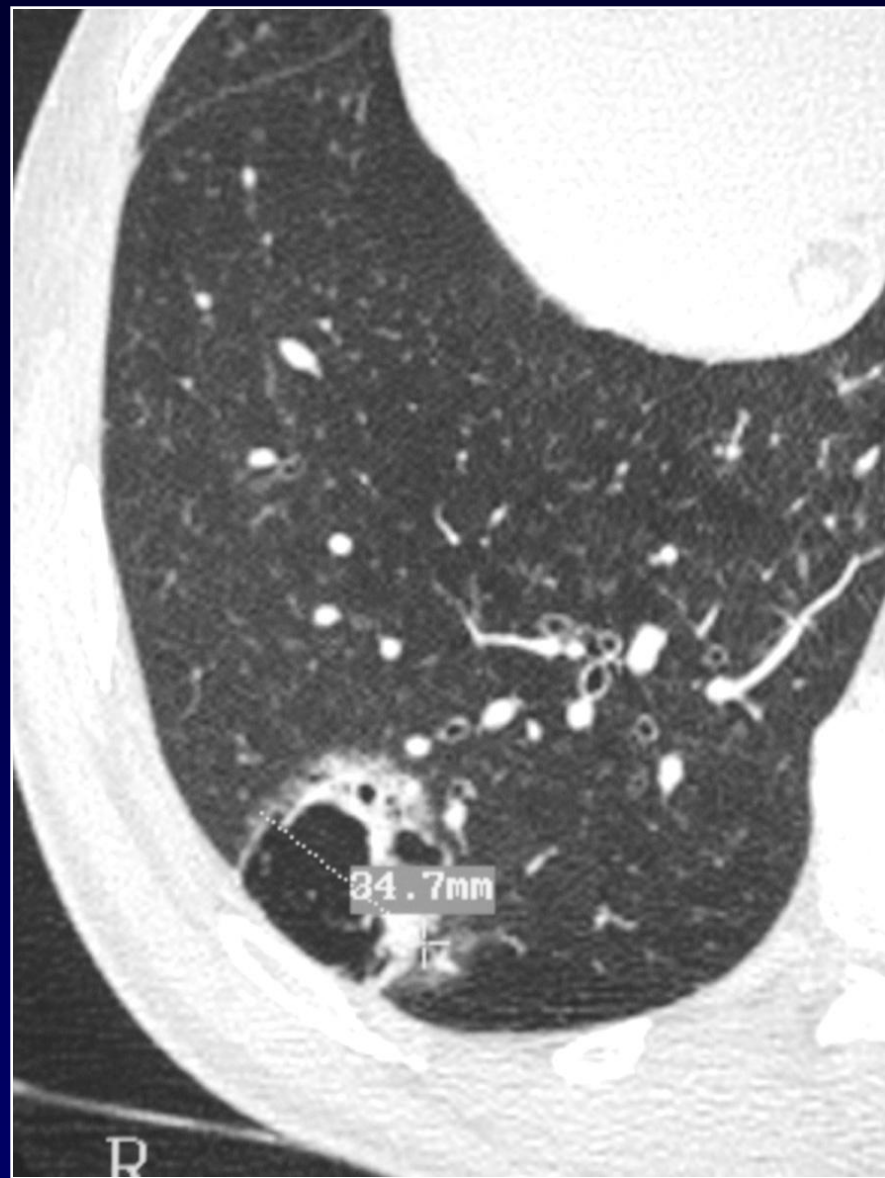
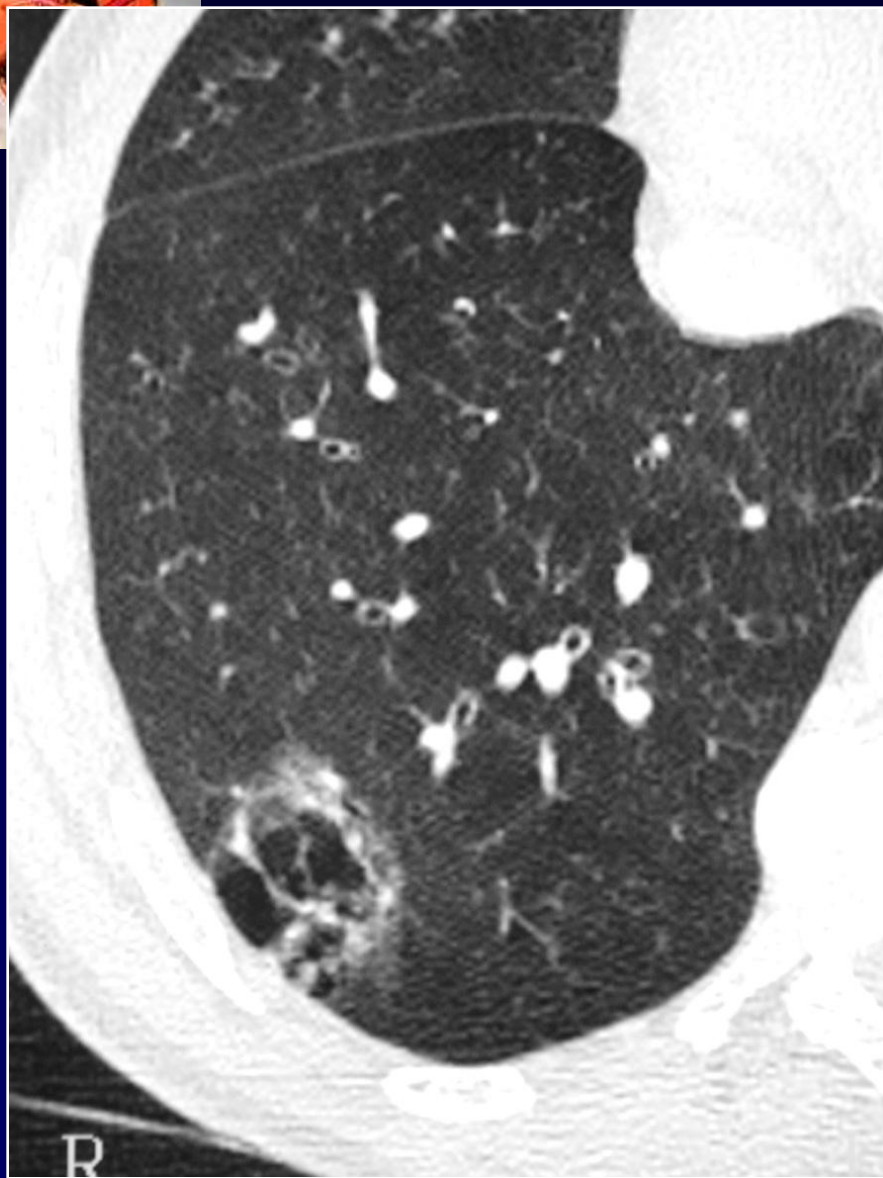




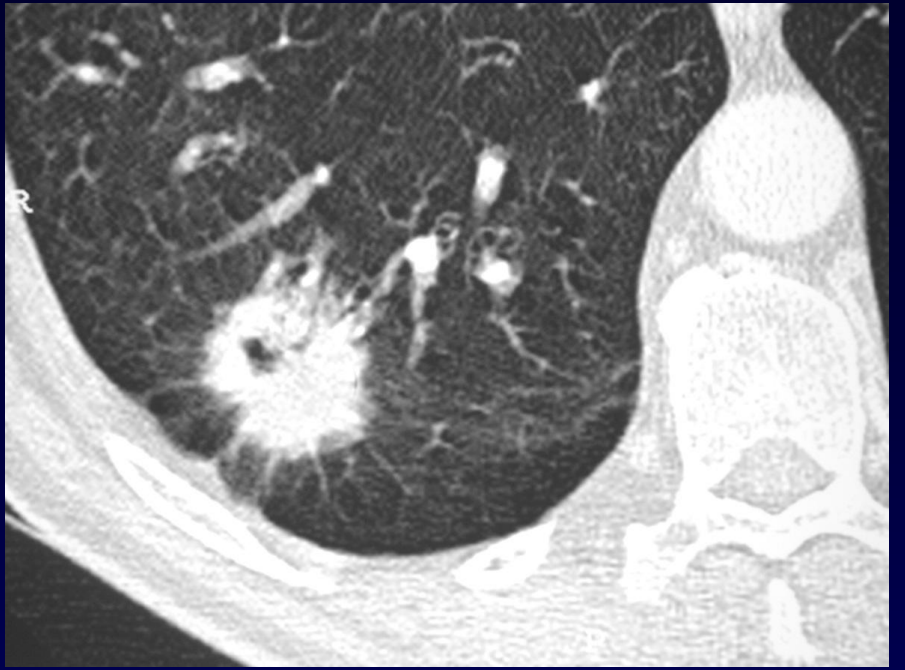
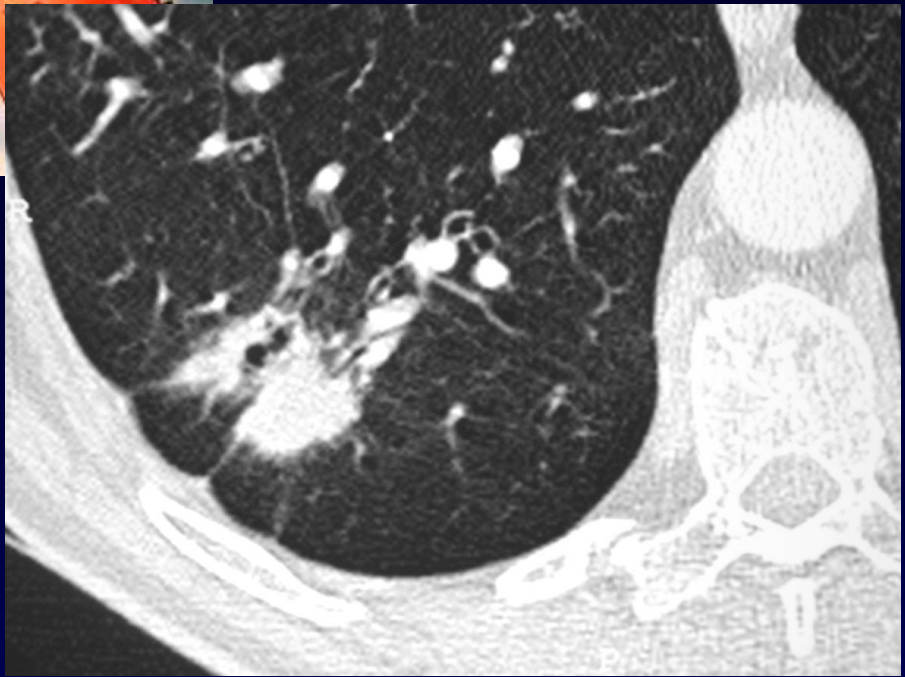
P FAJADET

Femme de 59 ans

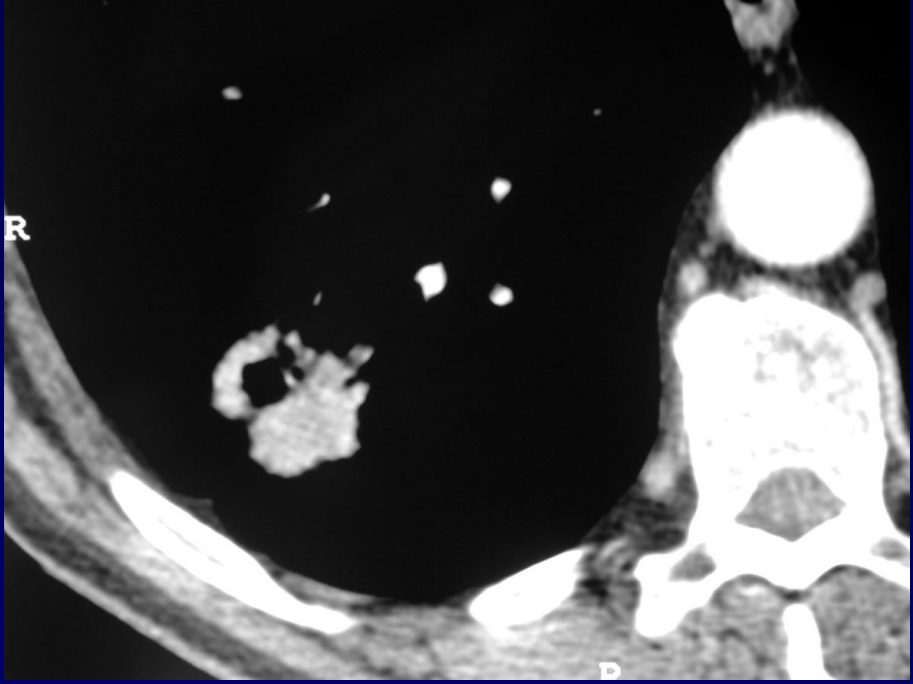
TDM réalisée au décours d'une pneumopathie...



Scanner de 1998



Scanner de 2003





Diagnostic ?



**Transformation des lésions initiales en nodule
spiculé**

Adénocarcinome