



**J GIRON – P FAJADET**

Homme de 50 ans

**PNEUMOPATHIE FEBRILE DEPUIS 15 JOURS**



#1 15-Sep-2009 16:13  
Topogramme 1.0 T20s

Sensation 16 C110292  
HFS  
512 x 512 x 16  
Thorax<sup>®</sup>TAP\_DEUX\_BOITES (Adulte)



R

L

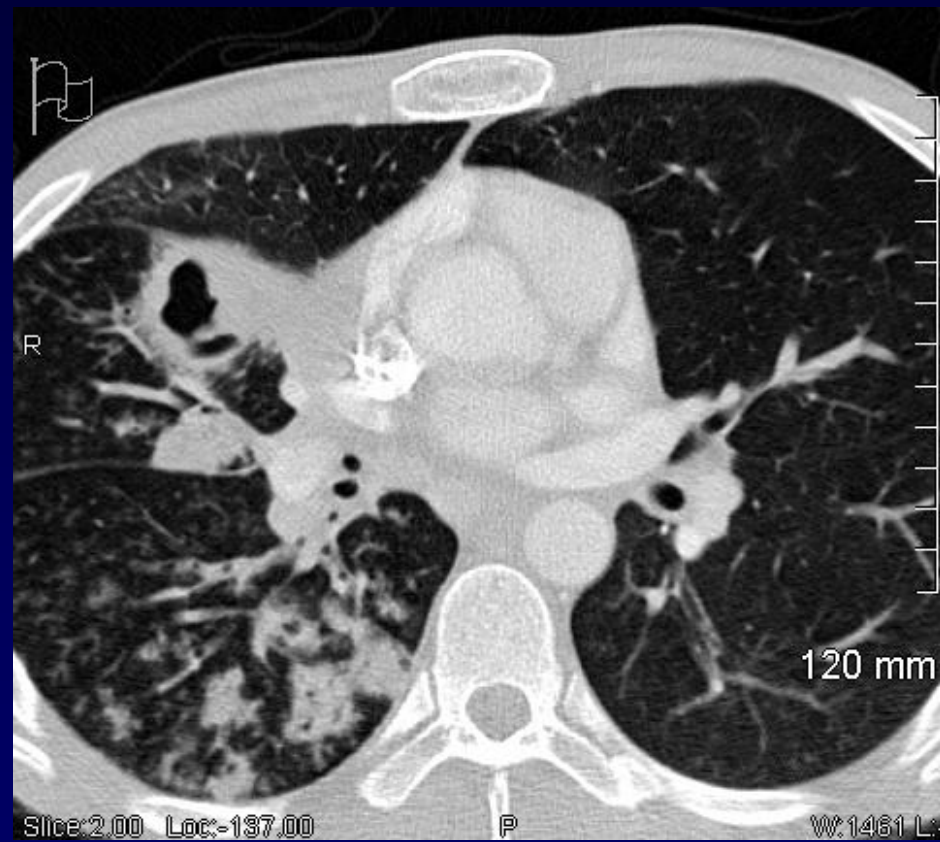
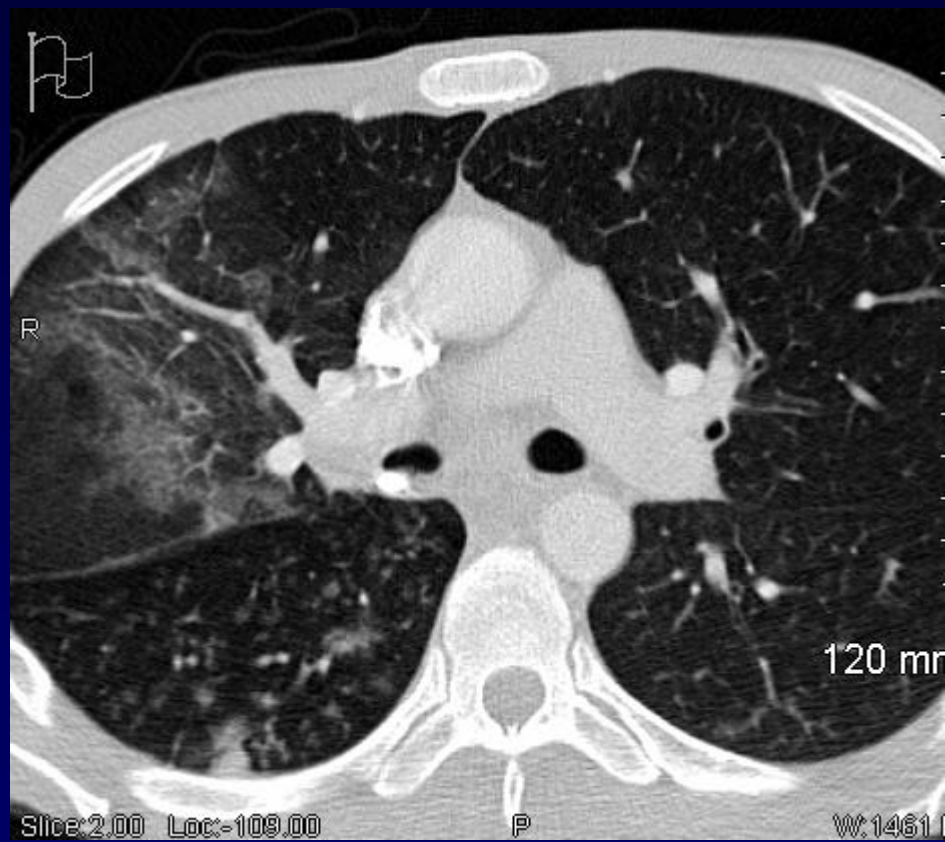


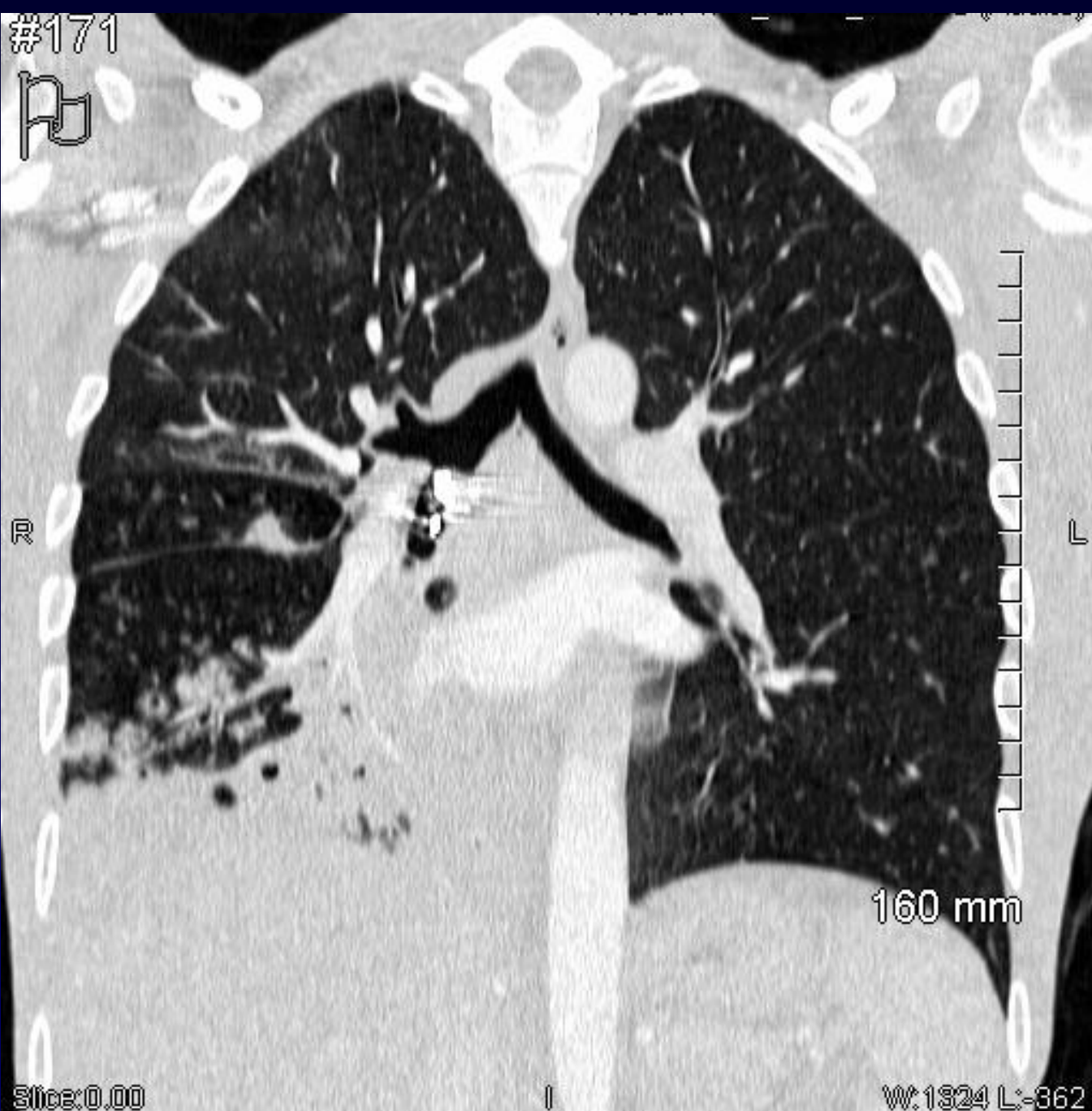
160 mm

Slice: 1.00 Loc: -712.00

I

W: 642 L: 184





#171

R

R

L

160 mm

Slice: 0.00


I

W: 1824 L: -362



#1 15-Sep-2009 20:35  
Individually captured images

Voxar 3D CT10292  
HFS  
512 x 512 x 16  
SCANNER THORAX ABDOMEN PELVIS APC,



Slice: 12.02

I

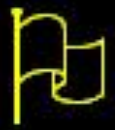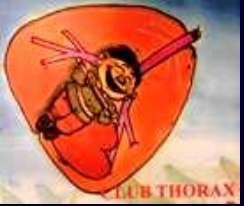W: 3288 L: 670



**Diagnostic ?**



**INHALATION SPONTANEE D'UN BRIDGE**  
**PNEUMOPATHIE NECROSEE**  
**OBSTRUCTION BRONCHIQUE**



Rt

