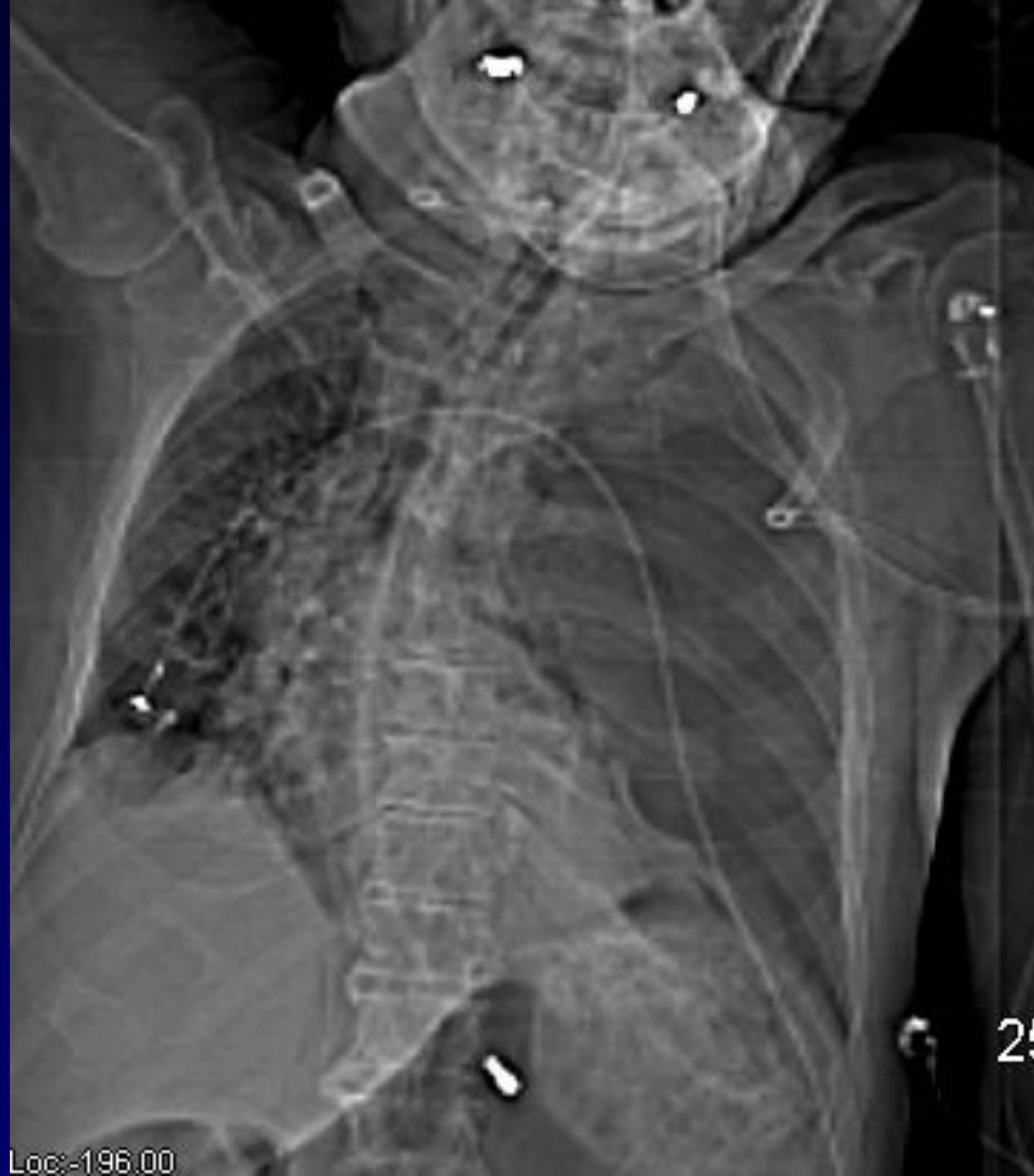



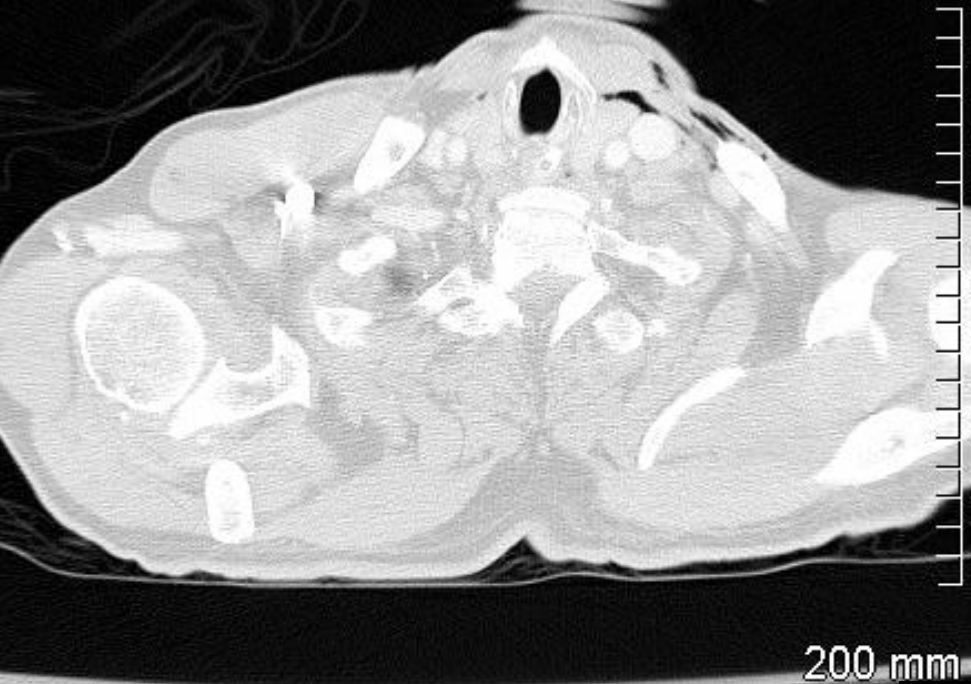
**J-GIRON – P-FAJADET**

**Homme de 55 ans**

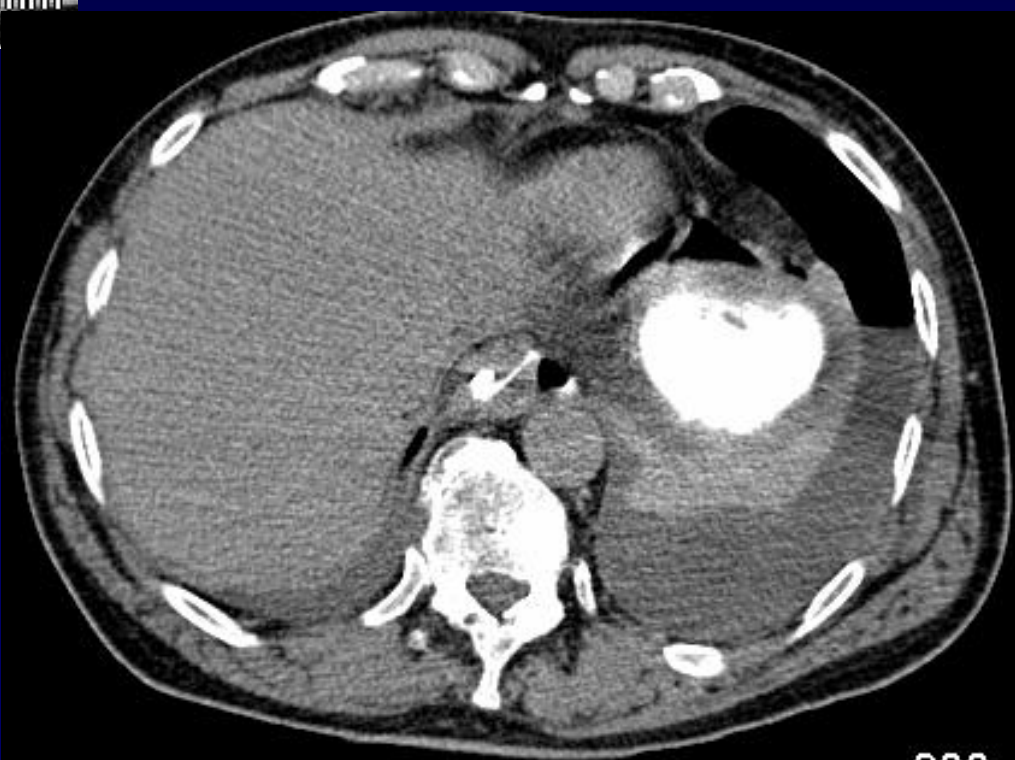**URGENCES : douleur thoracique à G**  
**Vomissements ++**



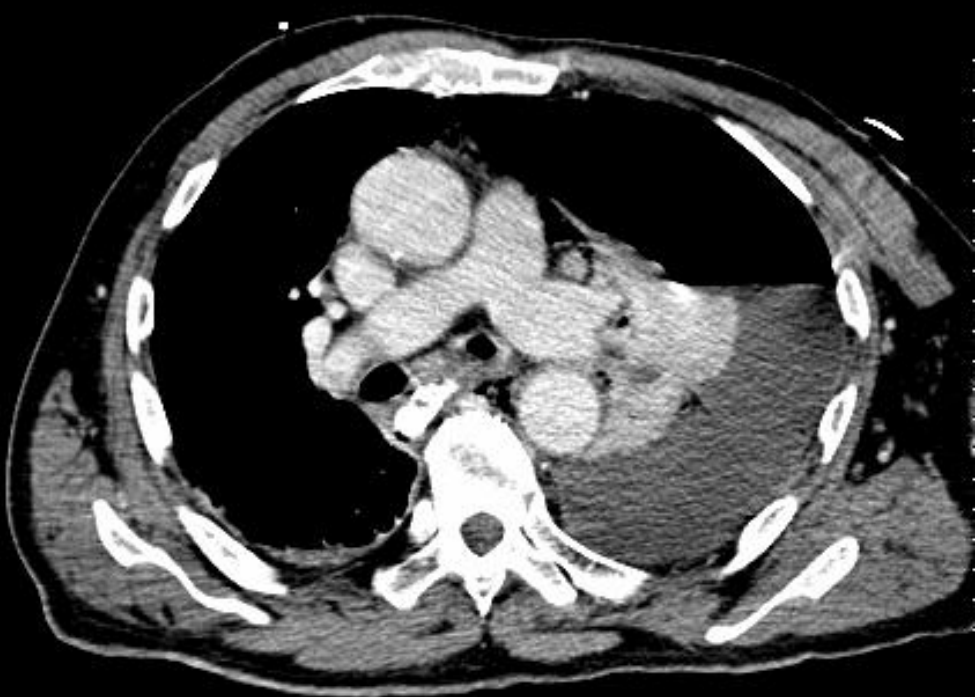
Loc:-196.00



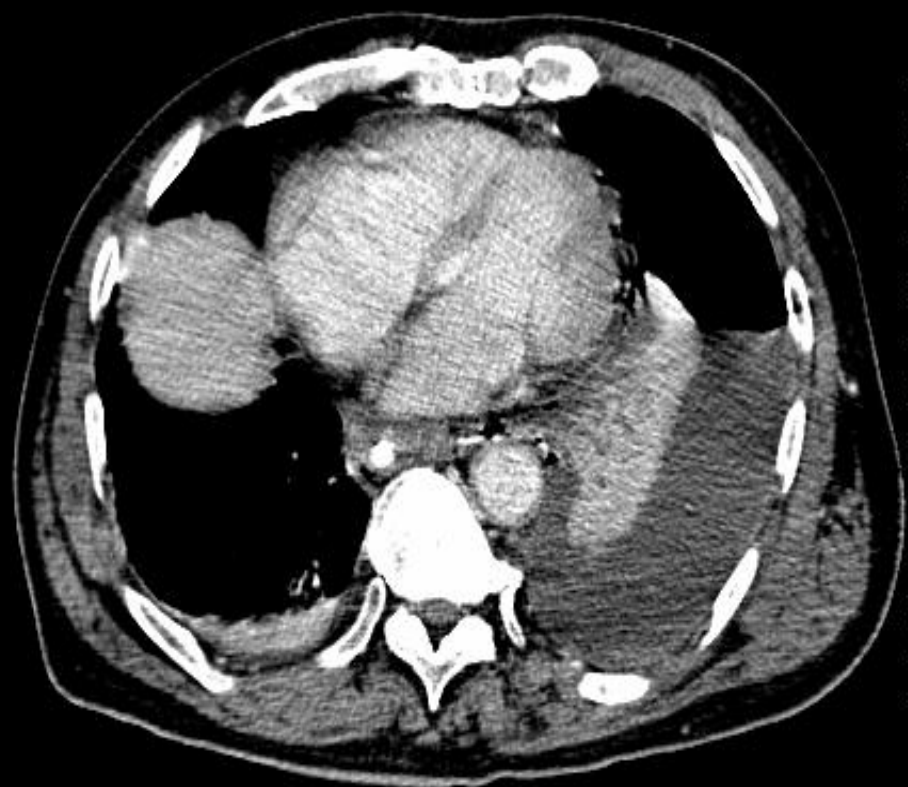
200 mm



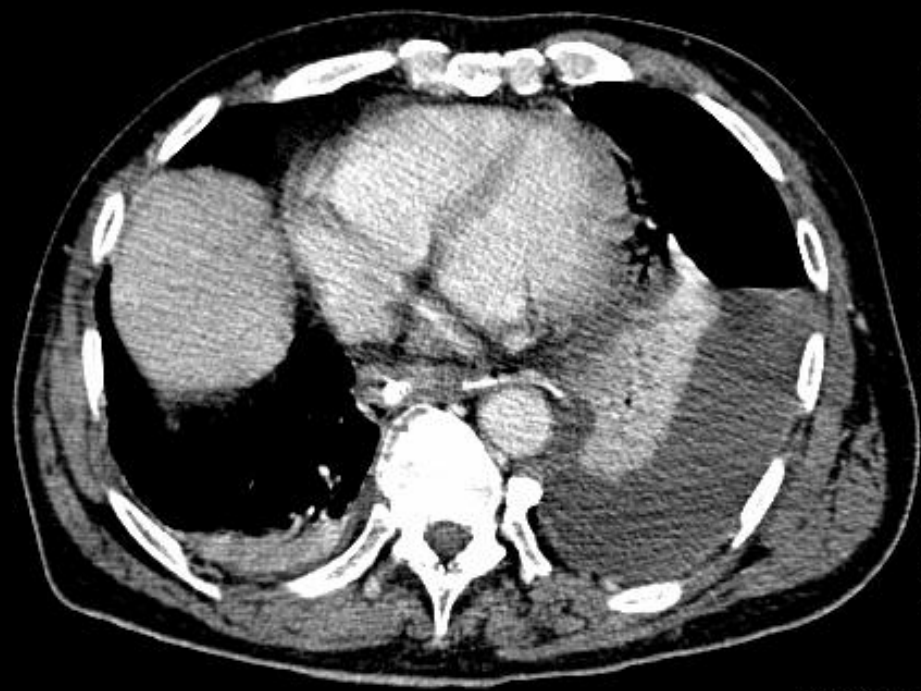
200



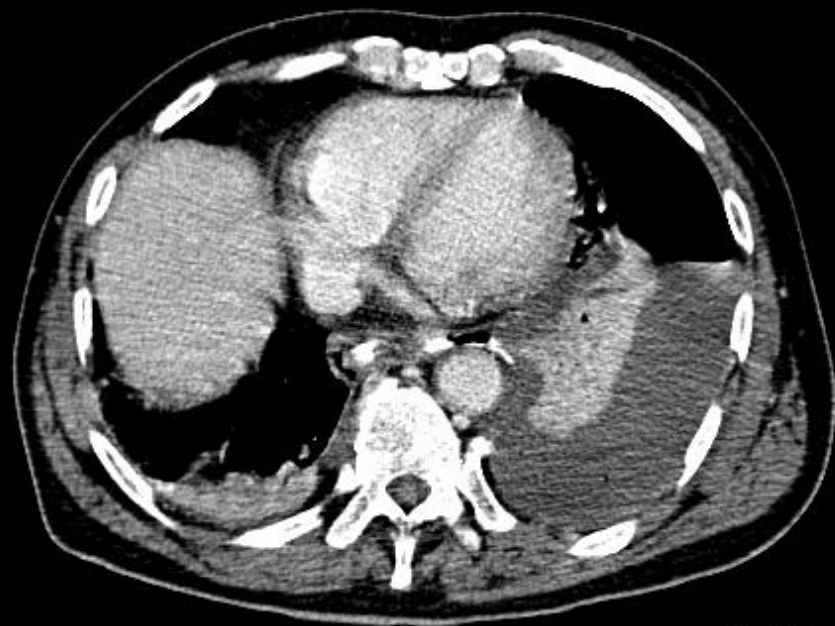
200 mm



200 mm



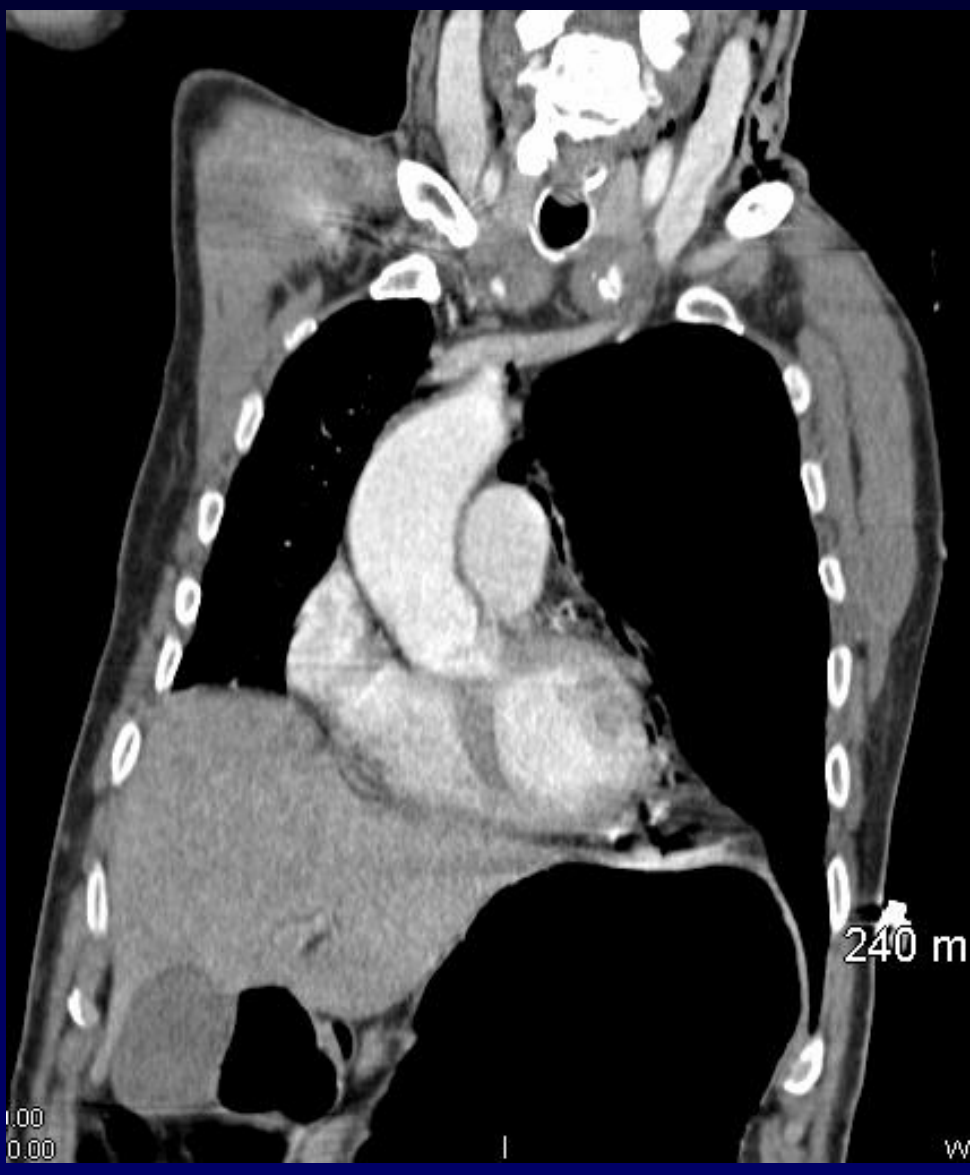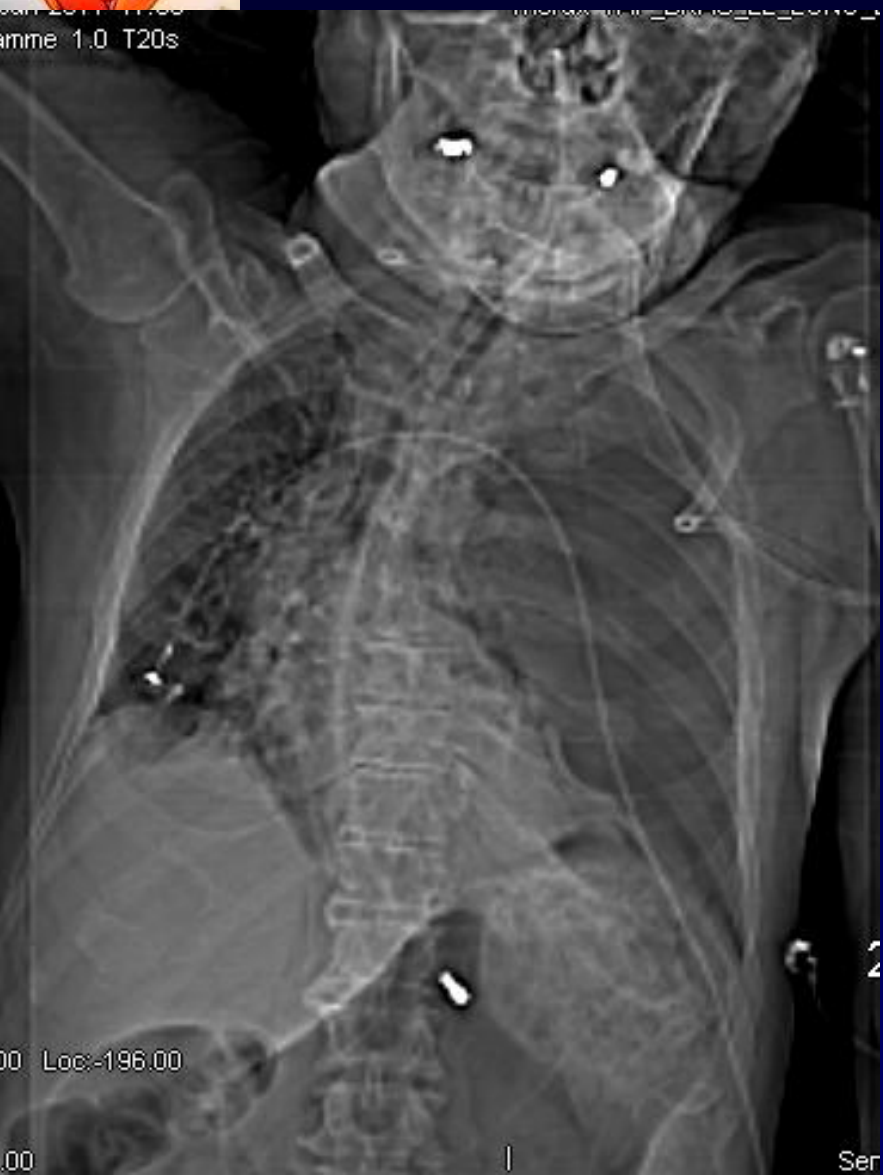200 mm



200 mm

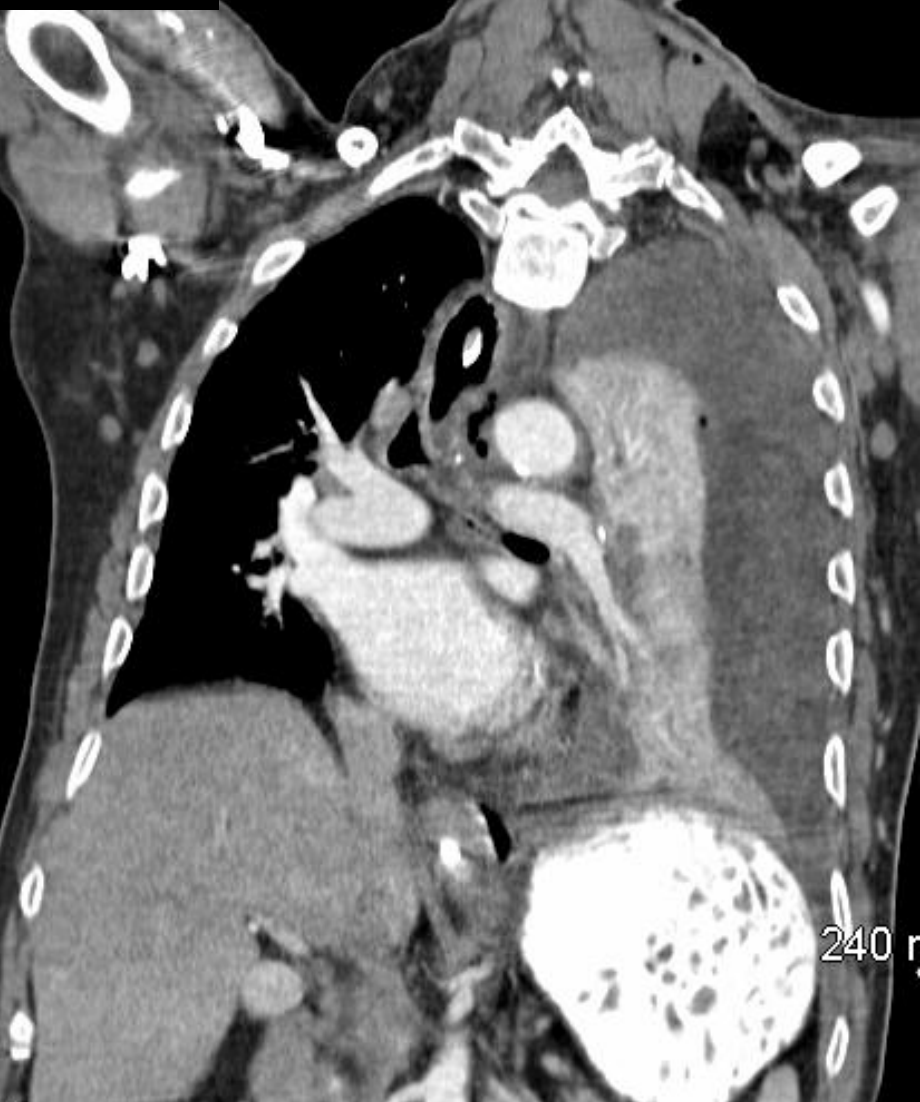

amme 1.0 T20s

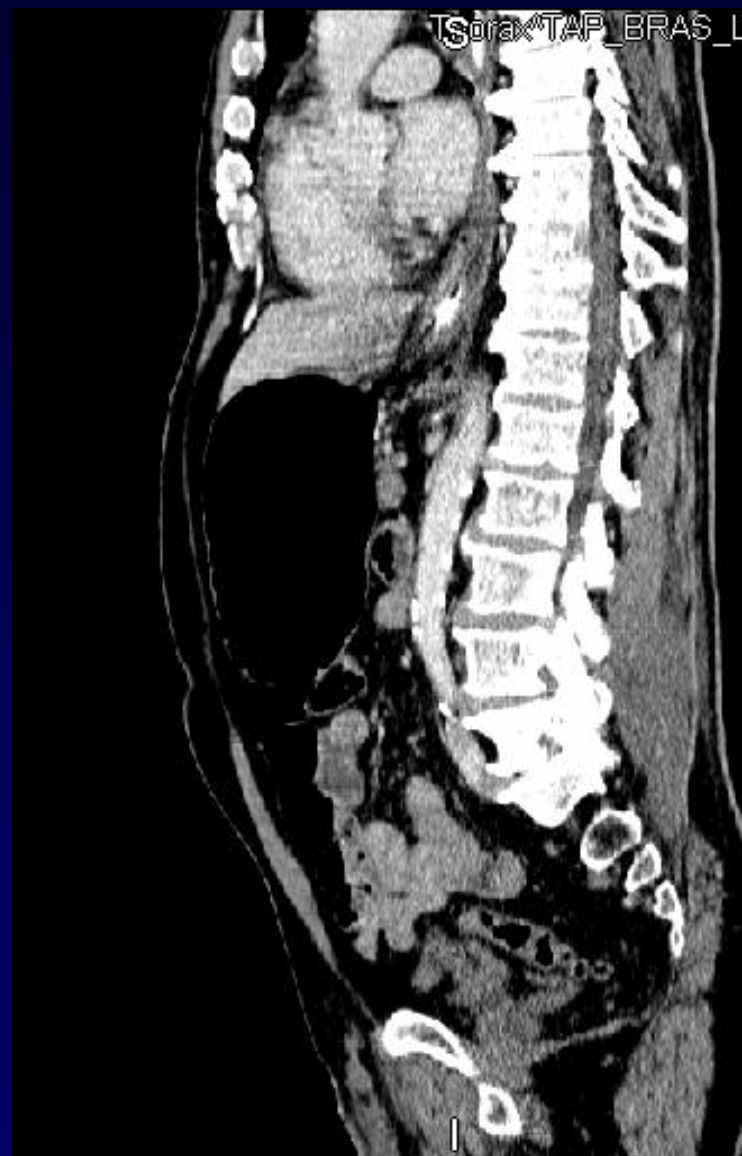

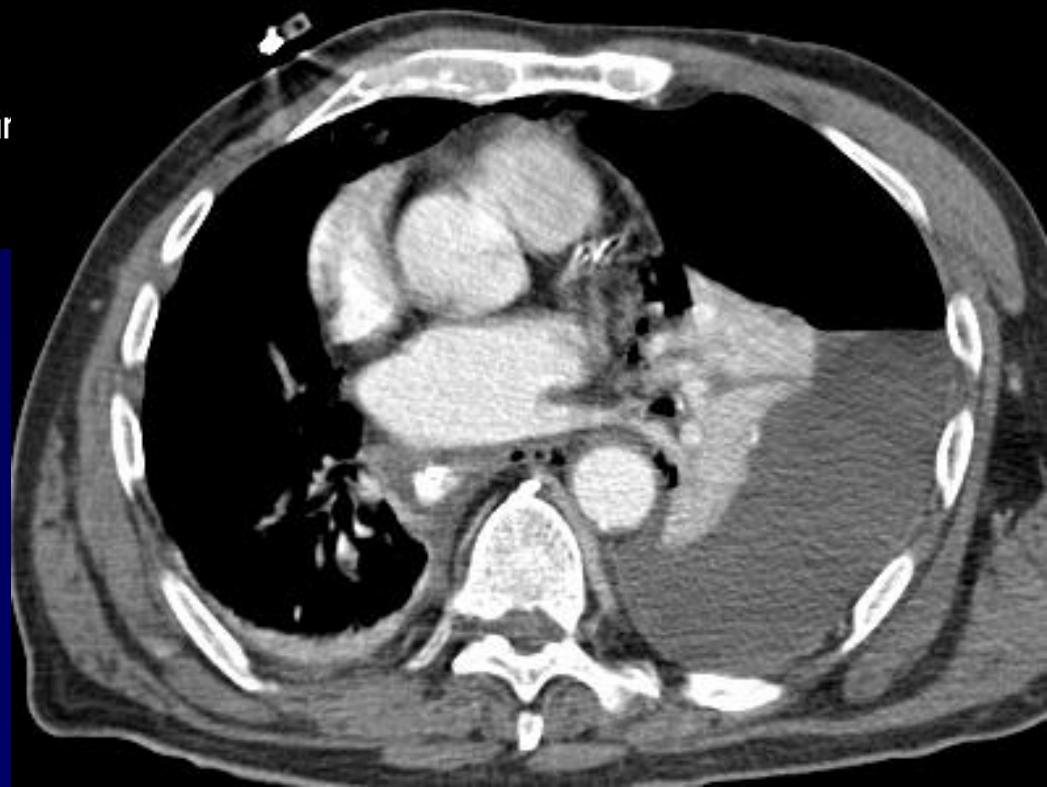

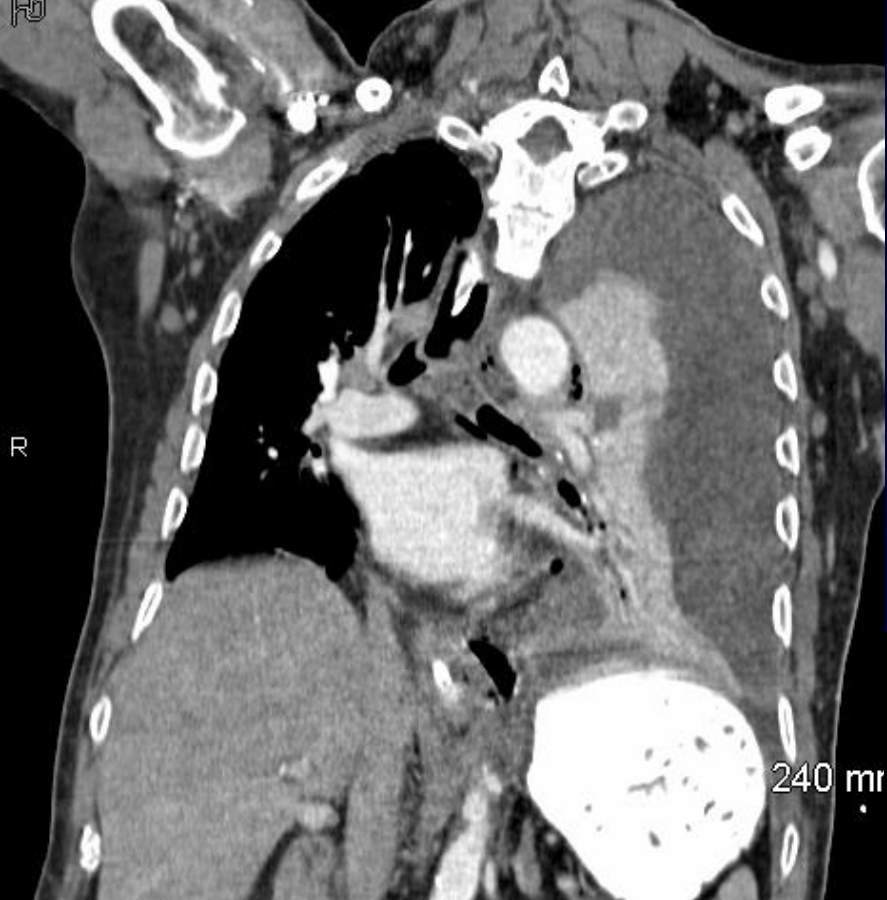
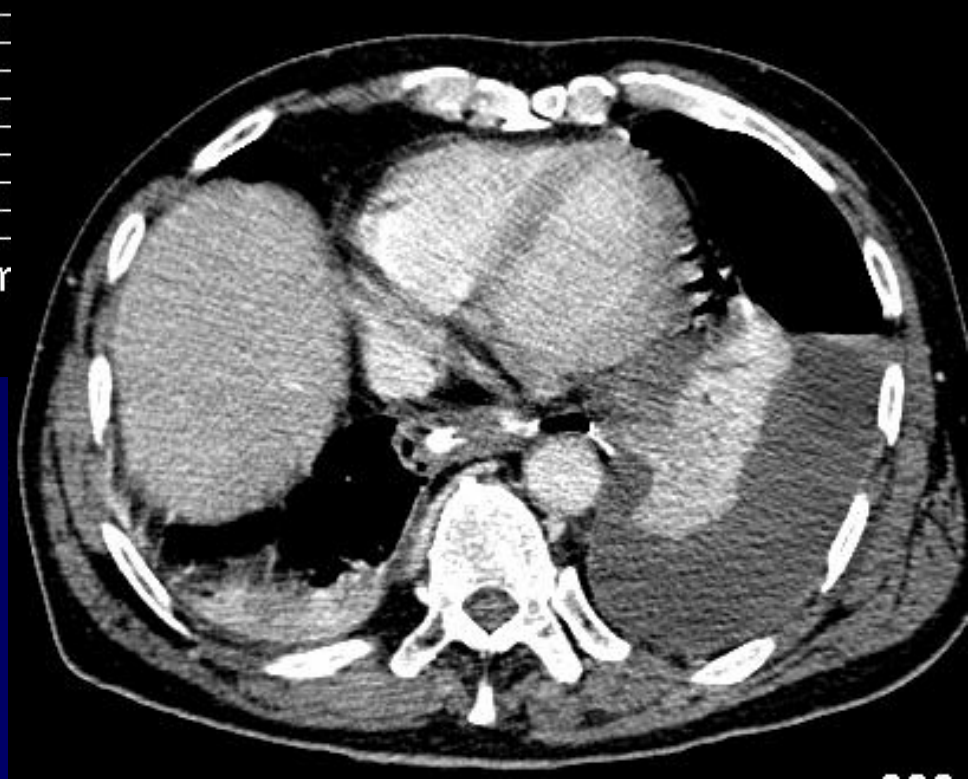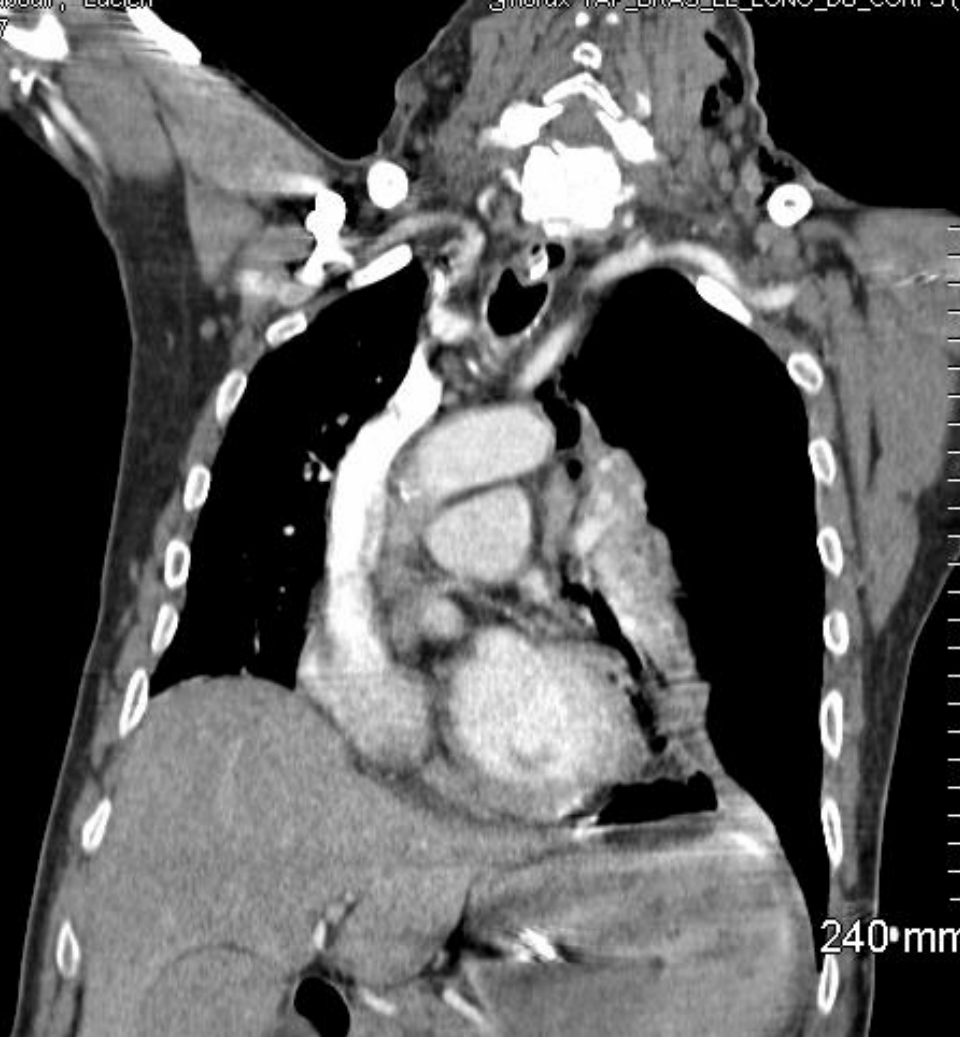
Schorax^TAP\_BRAS\_LE\_LONG\_DU\_COR

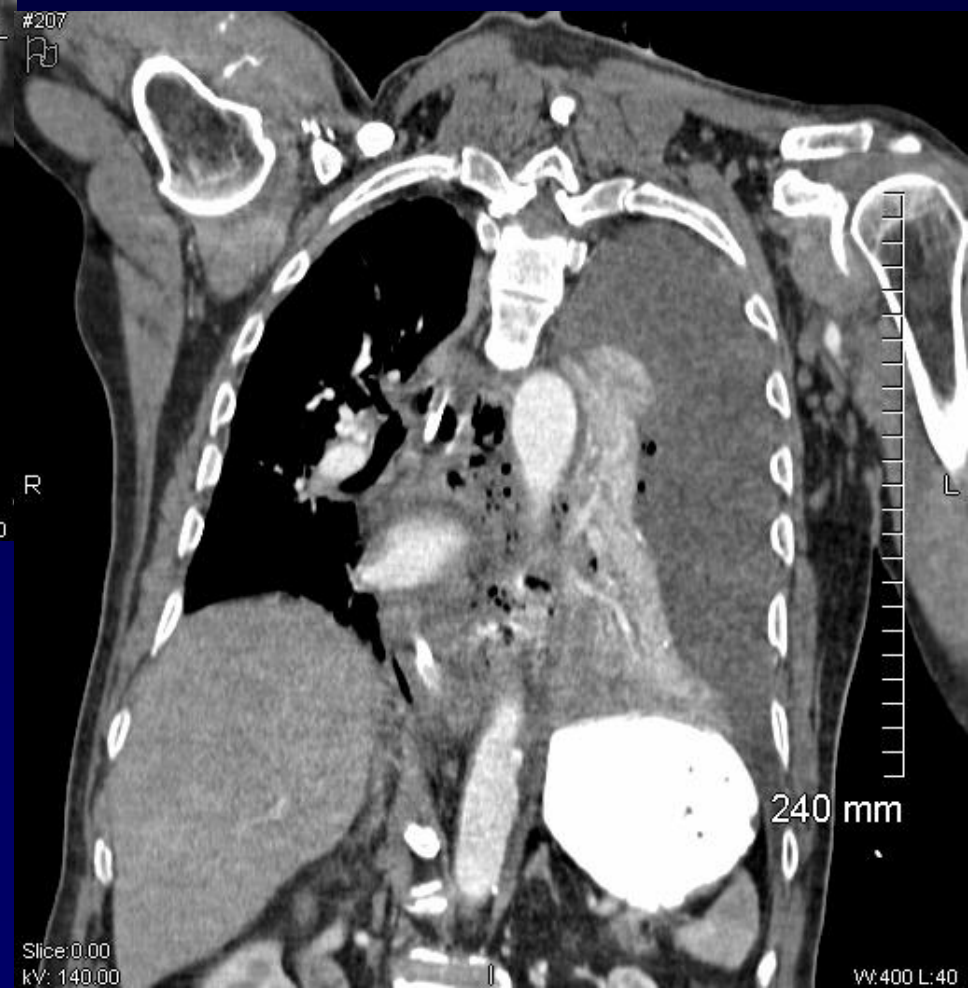
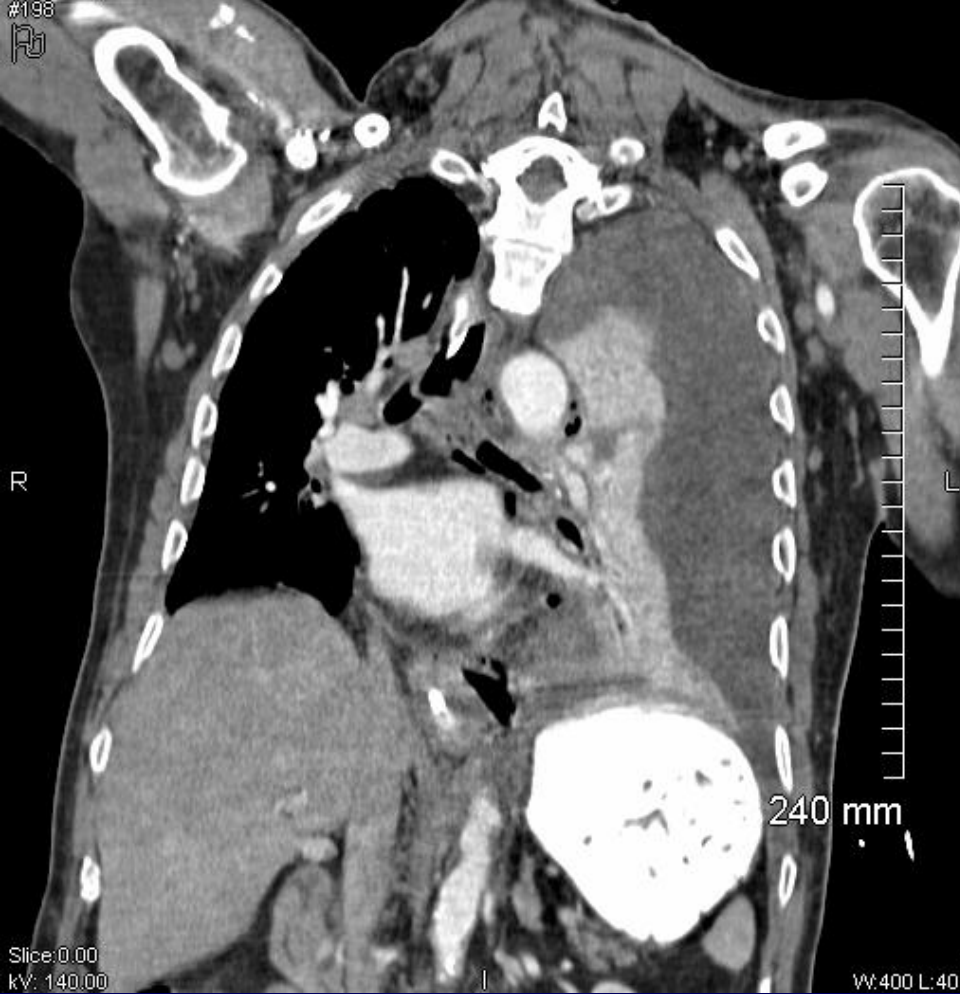


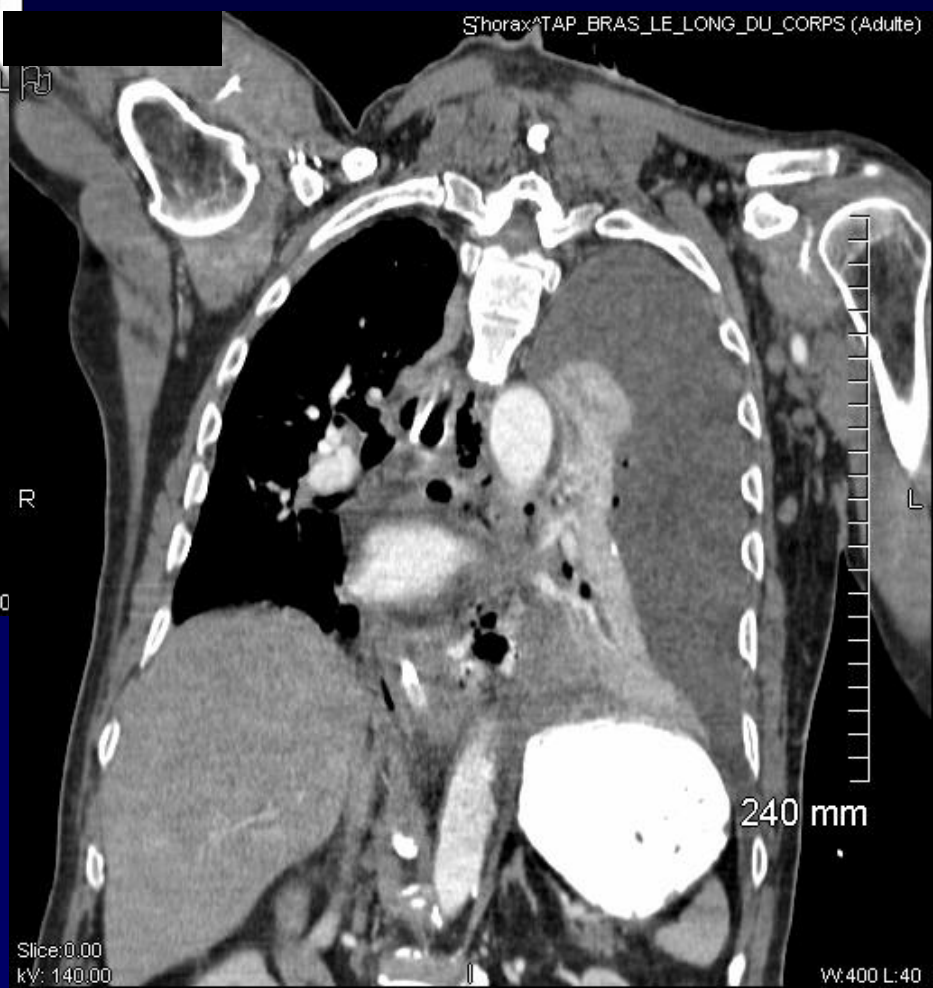
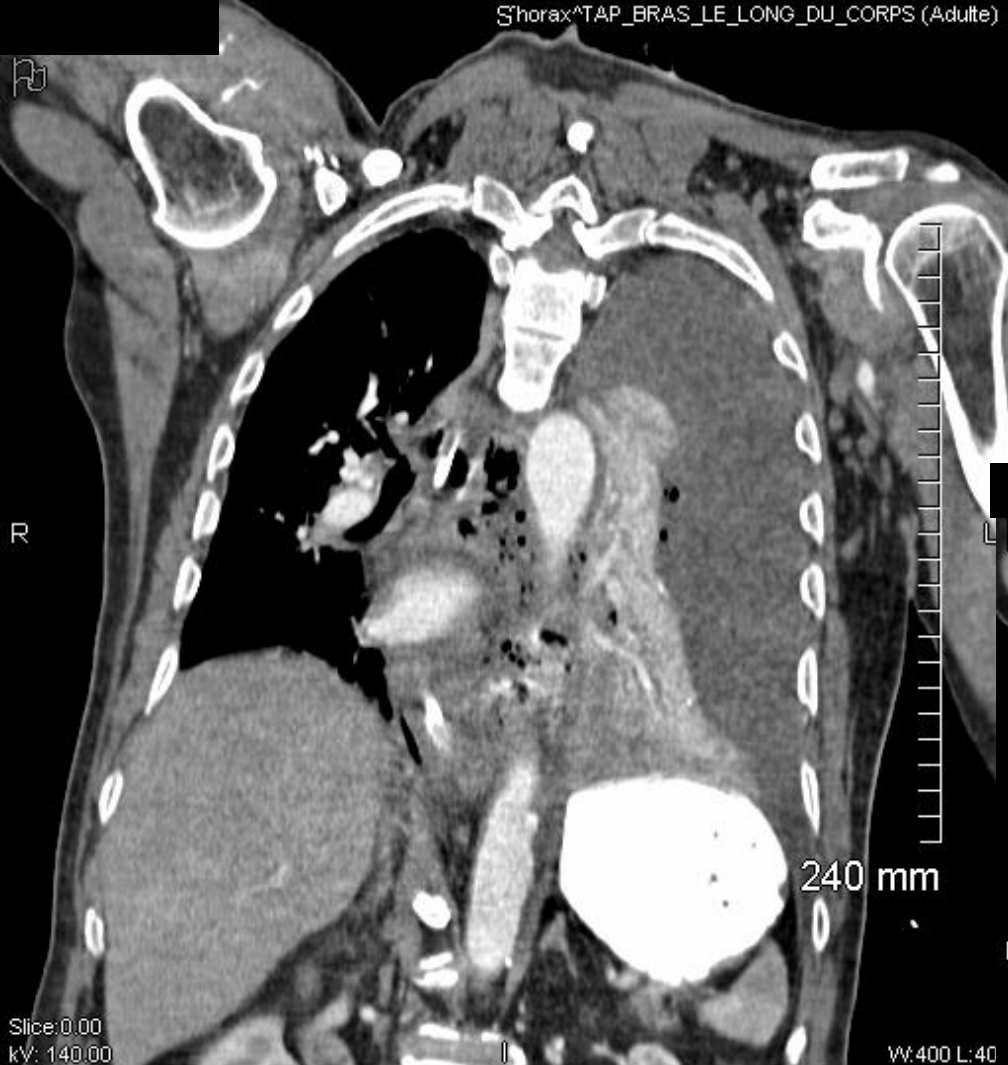Schorax^TAP\_BRAS\_L





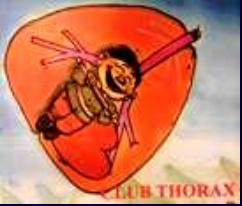







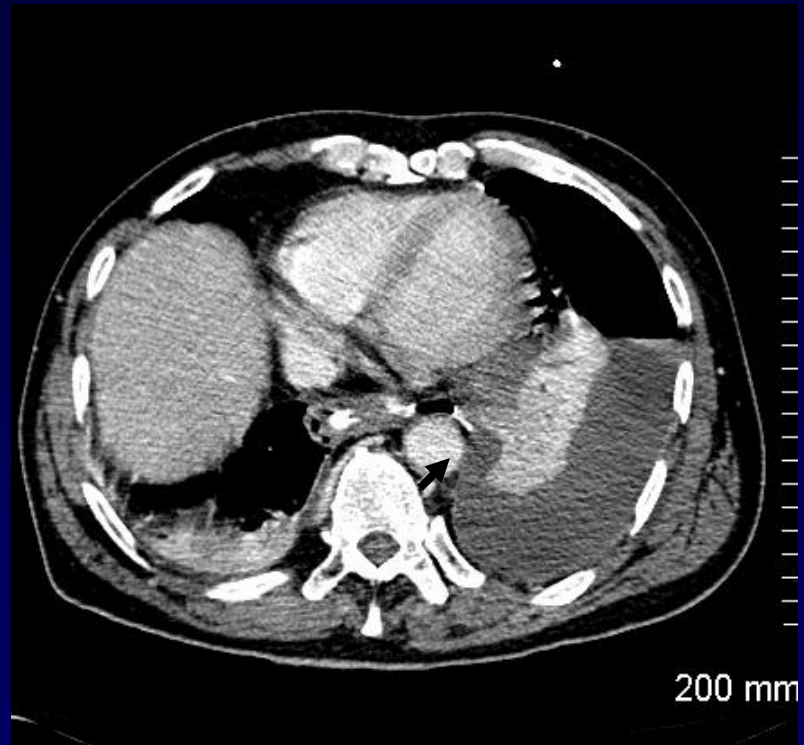
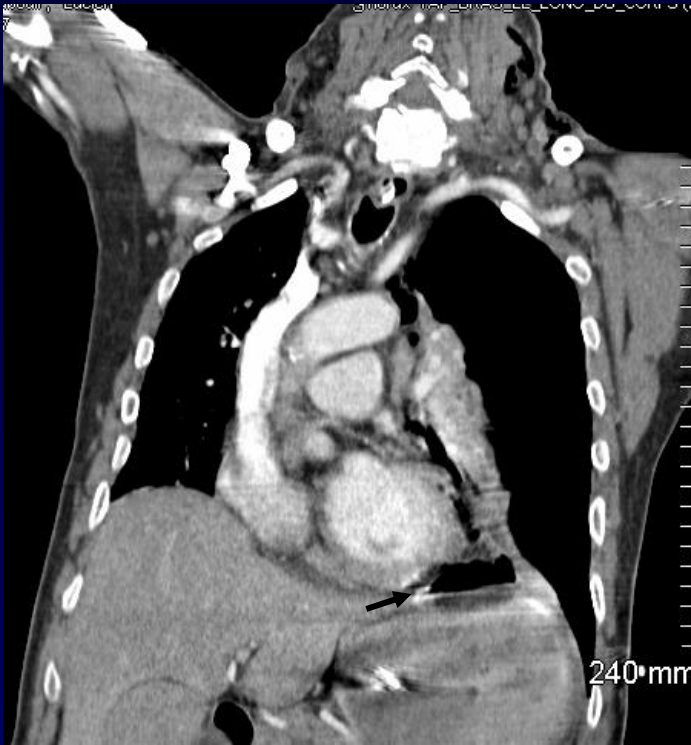
**DIAGNOSTIC?**

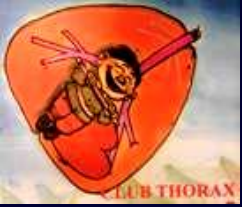

# Diagnostic

**Syndrome de Boerhaave**

**Rupture oeso. / orifice  
diaphragmatique**





**TO – Scan +++**

**Efforts de vomissements : +ou -**

**Pneumo médiastin / le long de l'oeso ...puis sous cut**

**Epanchement pleural sous pulm ...puis global**

**Chirurgie / oeso si très précoce sinon drainages**