

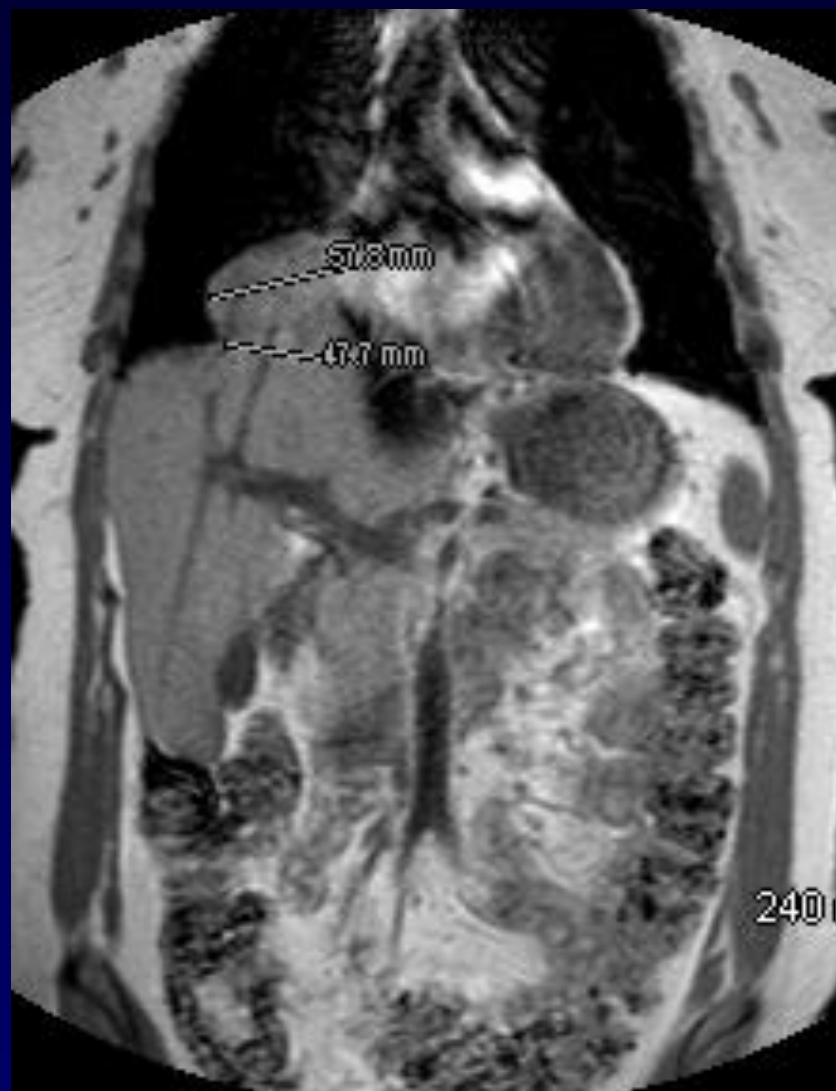


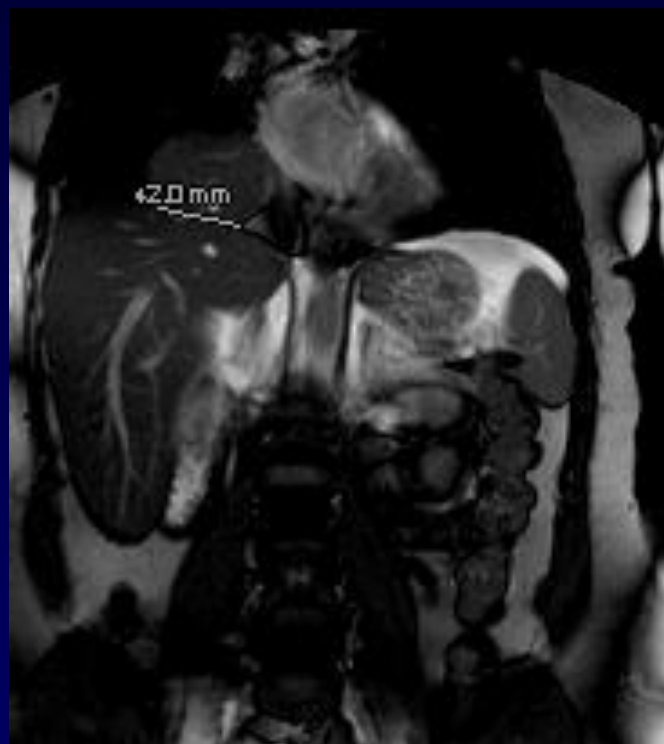
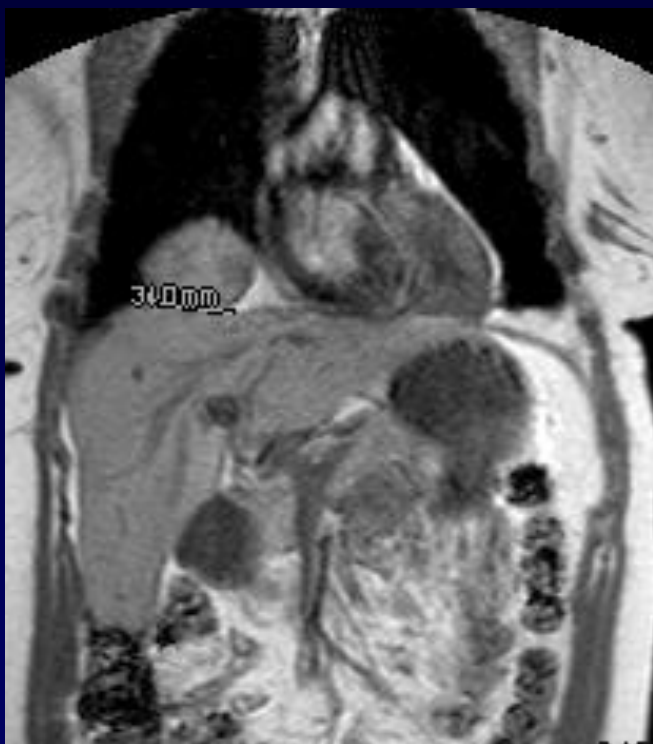J . GIRON – P . FAJADET

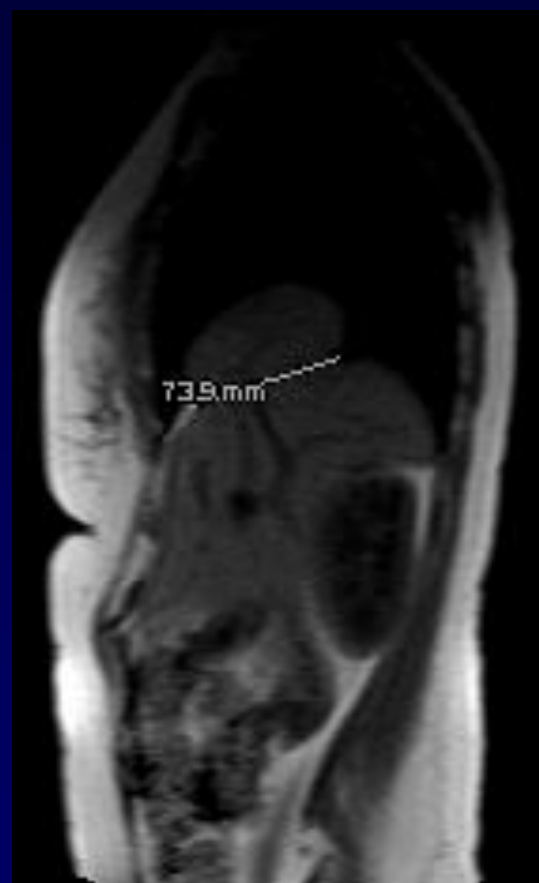
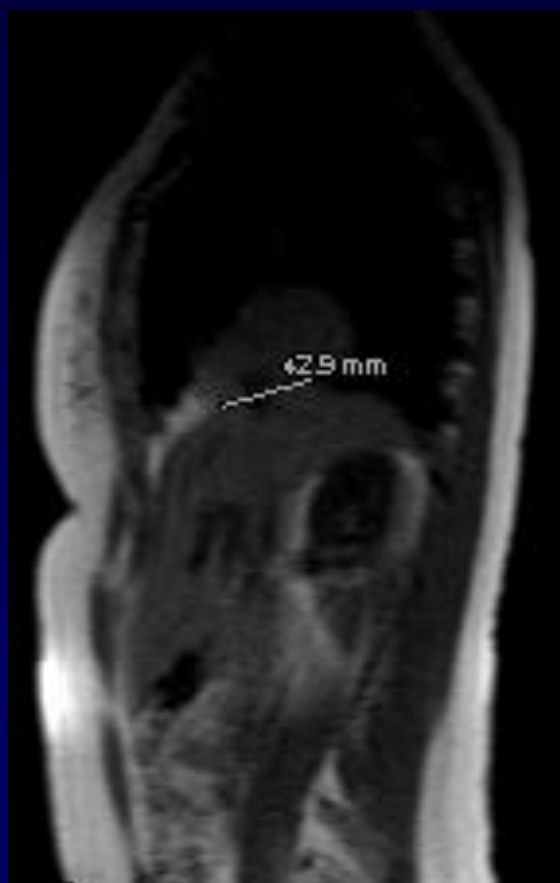
F, 50 ans

DOULEURS THORACIQUES RECENTES

IRM.... APRES RT ET TDM









Diagnostic ?

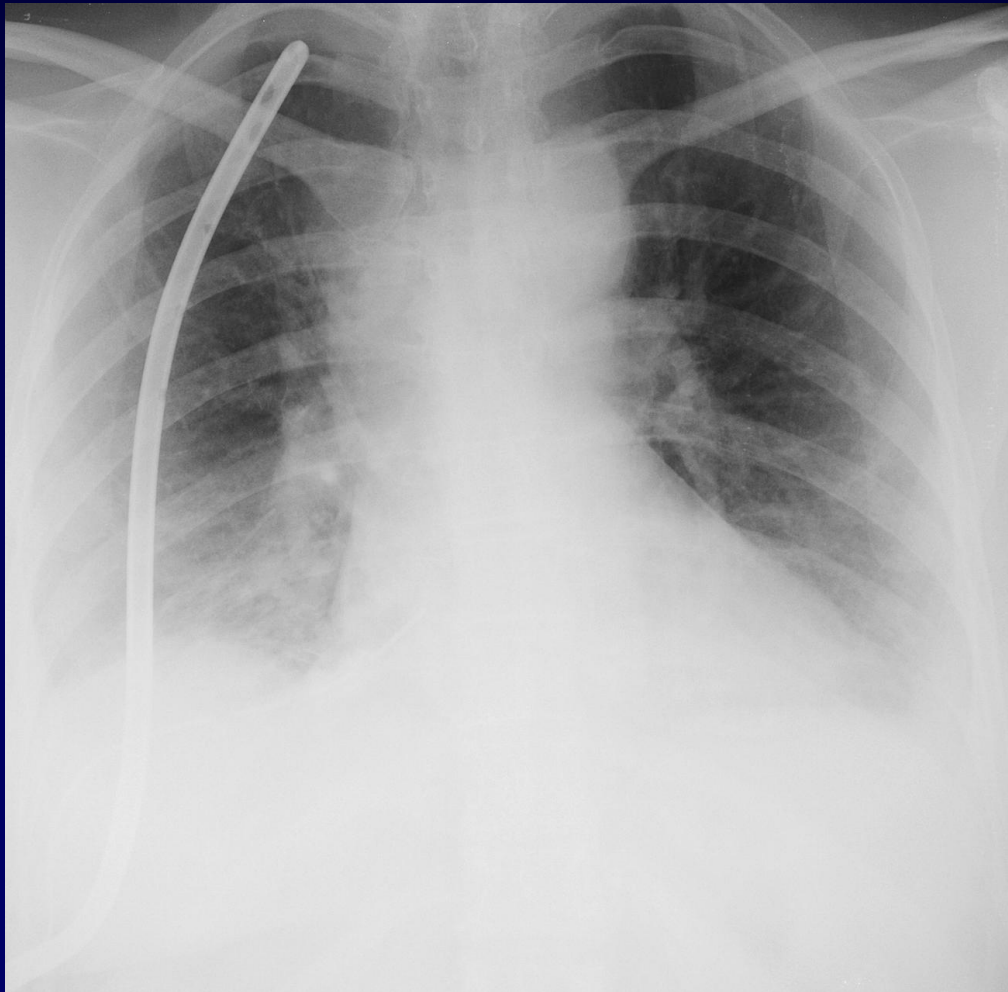


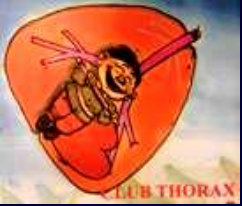Diagnostic

HERNIE HEPATIQUE TRANS DIAPHRAGMATIQUE



CHIRURGIE VOIE THORACIQUE AVEC PLASTIE





Evolution-Discussion-Point fort

ORIGINE : TRAUMATIQUE OU CONGENITALE ?

CAUSE DES DOULEURS ?