



Femme de 76 ans :

Tuberculose pulmonaire G : collapsothérapie en 1955

Tumorectomie du sein gauche suivie de radiothérapie en 1992

Fibrome pleural G opéré en 2003

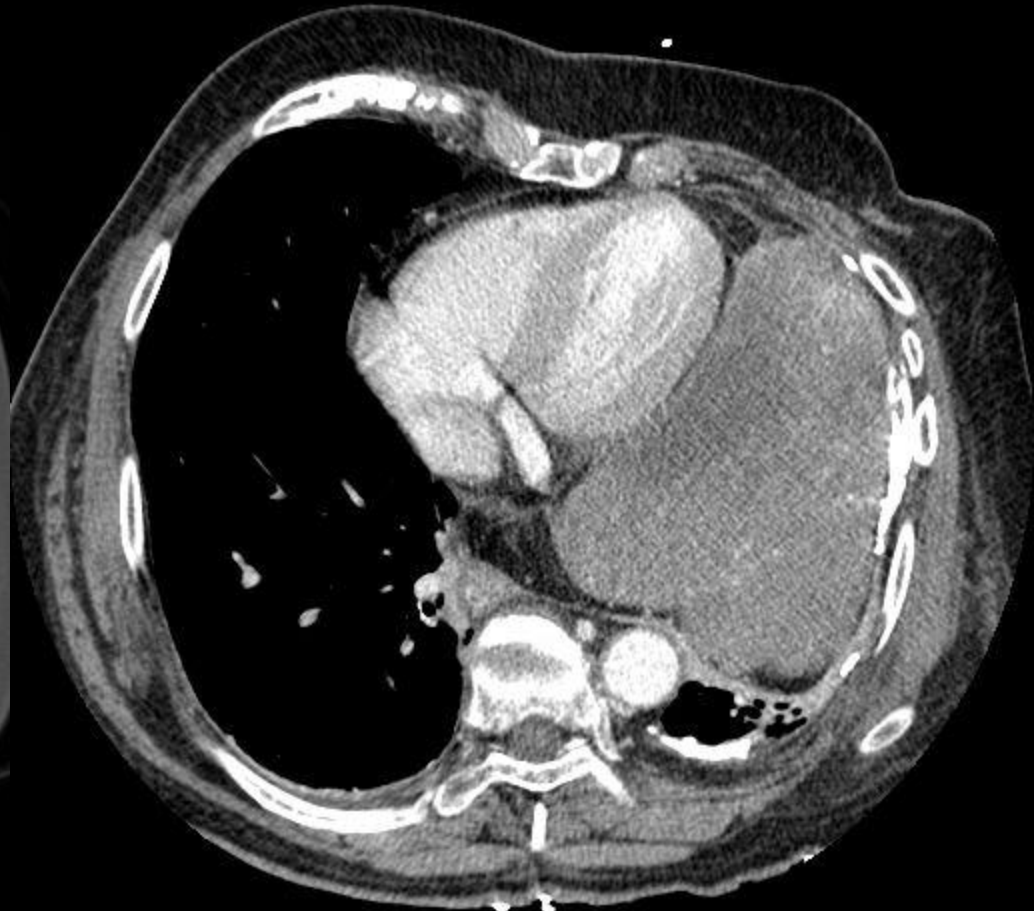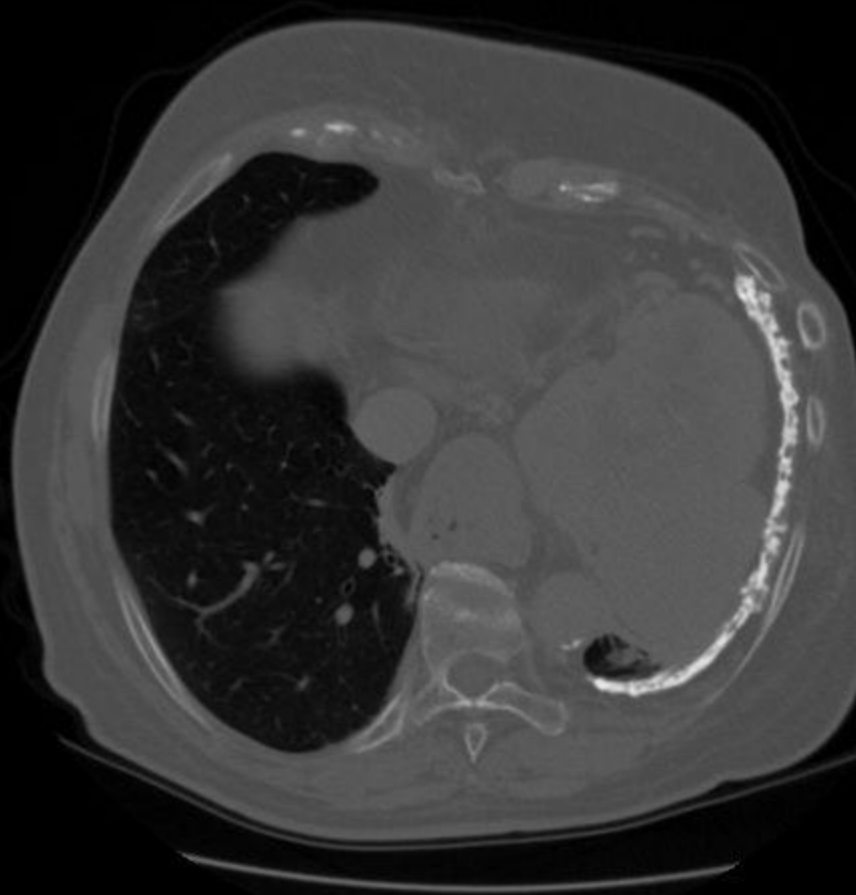
Depuis quelques mois :

Dyspnée

Malaises inexplicables (dérobements des membres inférieurs, sueurs)

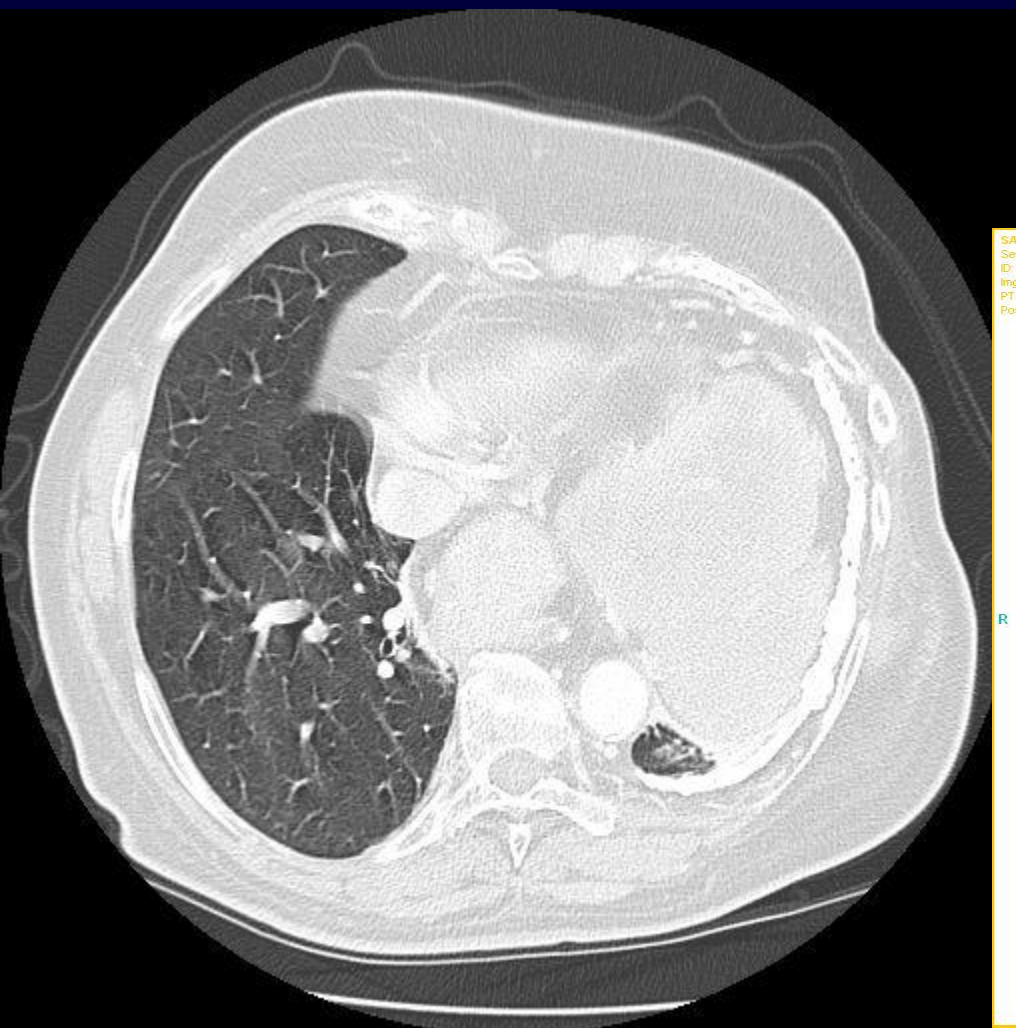


Calcification étendue pleurale G, masse
inhomogène nécrosée





Tep négative




SANTACREU MARIE
Sec: F
ID: 002353343
Img [110] #110/263
PT - W: 4964 L: 2758
Pos: -808.031 mm

A

R

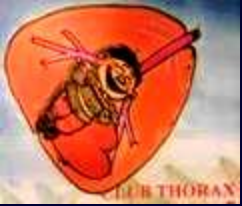L



61 cm

61 cm

P



- La veille de l'intervention hypoglycémie très sévère
- Quel est votre diagnostic ?



SYNDROME DE DOEGE POTTER

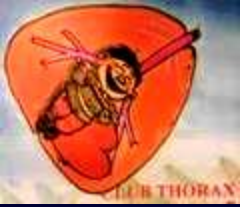FIBROME PLEURAL « récidivant » et
hypoglycémie

sécrétion : IGF 1, IGF 2

AUTRES TUMEURS:

tumeur neuro endocrine

fibrosarcome



1. Macaulay VM. Insulin like growth factors and cancer. *Br J Cancer*. 1992 65:311-320. (9)
2. Gordon P., Hendricks CM., Kahn RC., Megyesi K., Roth J. Hypoglycaemia associated with non-islet cell tumour and insulin like growth factors. *N Eng. J Med*. 305; 24: 1452-1455 (g)
3. Kondo M., Suzuki H., Ueda R., Osada H., Takagi K., Takahashi Toshitada., and Takahashi T., Frequent loss of imprinting of the H19 gene is often associated with its over-expression in lung cancers. *Oncogene* 1995; 10:1193-1193 (f)
4. Fukuda I., Hizuka N., Takano K., Asakawa-Yasumoto K., Shizume K., Demura H., Characterisation of Insulin like growth factor II (IGF-2) and IGF binding proteins in patients with Non Islet Cell tumour hypoglycaemia. *Endocrine Journal* 1993, 40 (1), 111-119 (G)
5. Doege KW., Fibrosarcoma of the mediastinum. *Ann Surg* 1930;92:955-961 (g)
6. Potter RP., Intrathoracic Tumours. Case Report. *Radiology* 1930;14; 60-61 (f)
7. Cardillo G., Facciolo F., Cavazzana A.O., Capece G., Gaspani R., and Martelli M. Localised (solitary) fibrous tumours of the pleura: an analysis of 55 patients. *Ann Thorac Surg* 2000; 70 (6) : 1808-1812 (5)
8. Bouchi J., Gharios E., Cortbawi E., and Aftimos G. Tumeur fibreuse solitaire de la pleure avec coma et hypoglycémie. *Rev Pneumol Clin* 1993;49 (5):2a3-2a6 @)
9. England D.M., Hochholzer L. and McCarthy M.J. Localised Benign and Malignant Fibrous Pleural Tumours of the pleura. A clinicopathologic review of 223 cases. *Am J Surg Pathol* 1989; 13 : 8: 640-658 (g)