

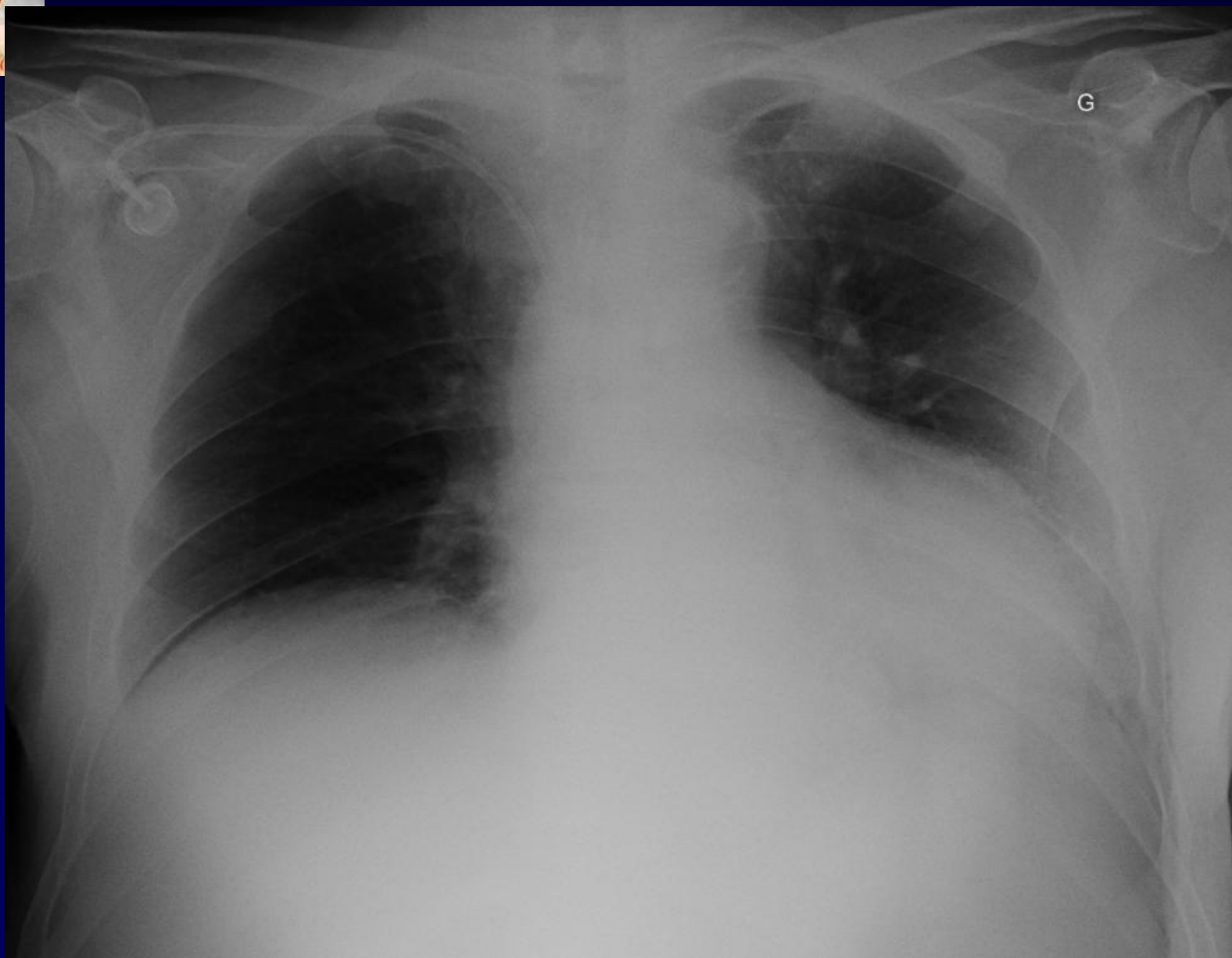


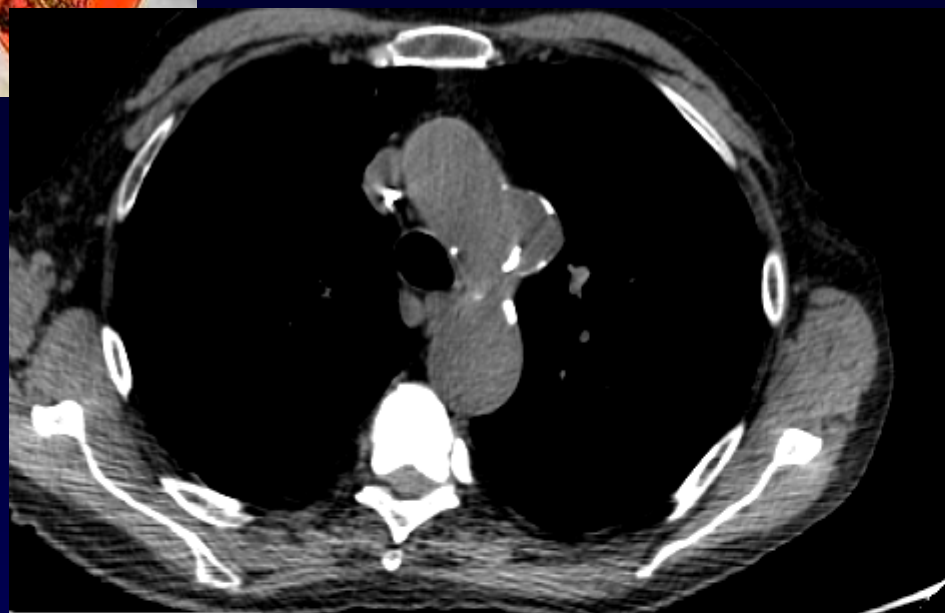Alexis LACOUT

Homme de 83 ans, dyspnée

Cancer de prostate métastatique

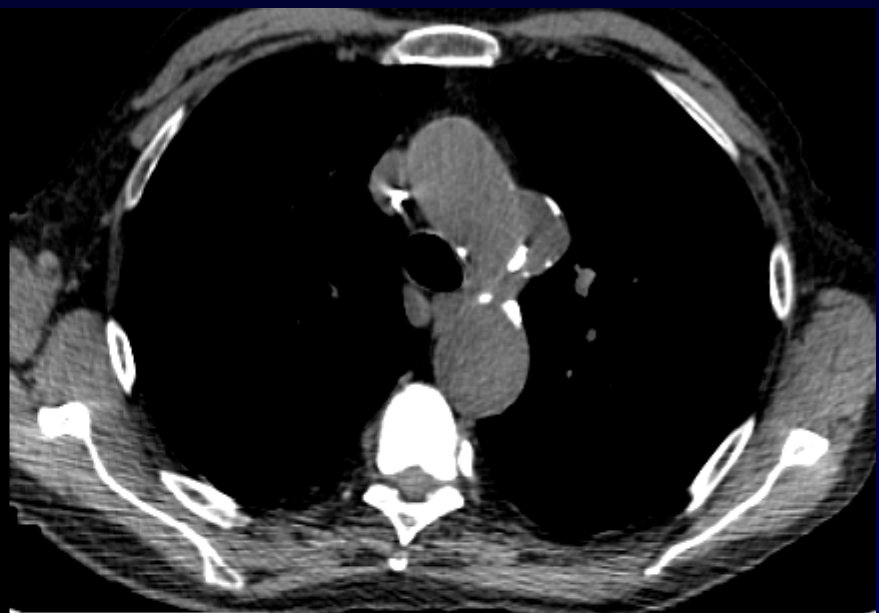

Scanner thoracique sans injection





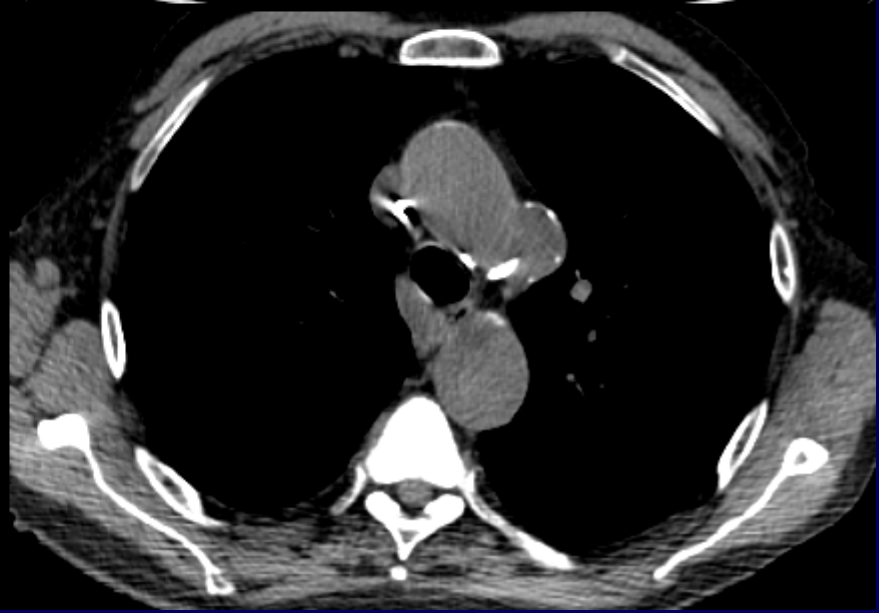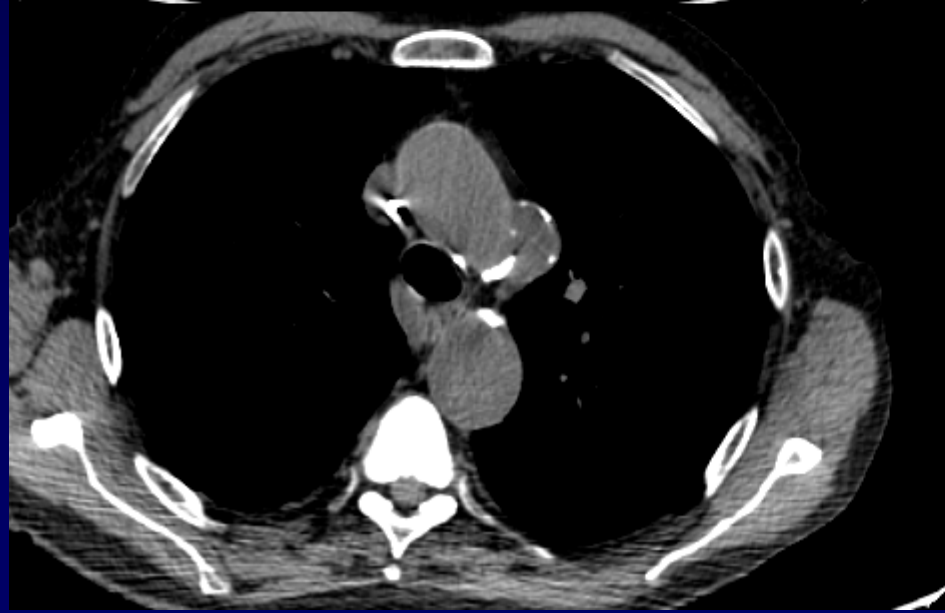

Page: 11 sur 32 (82%)

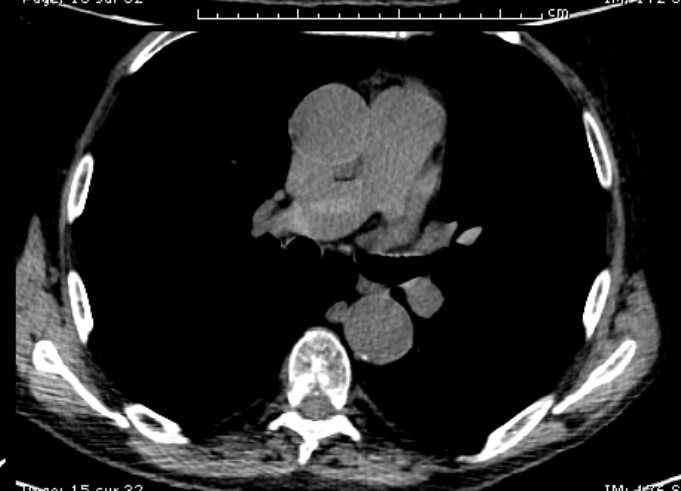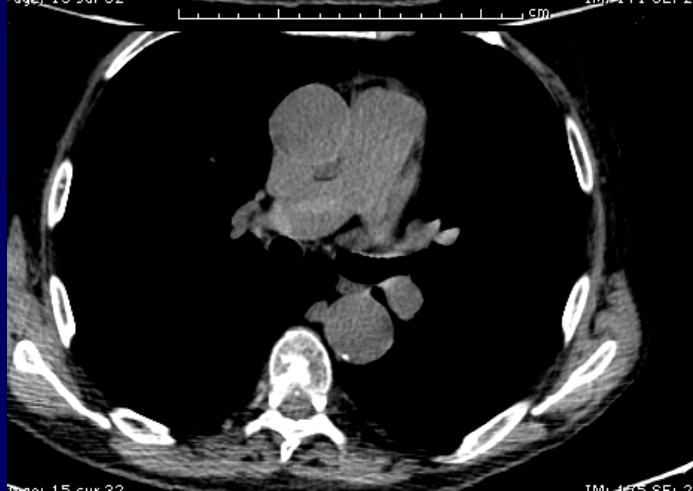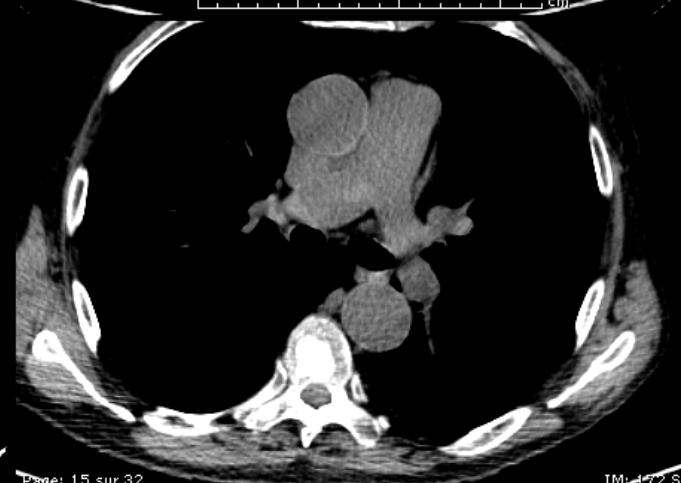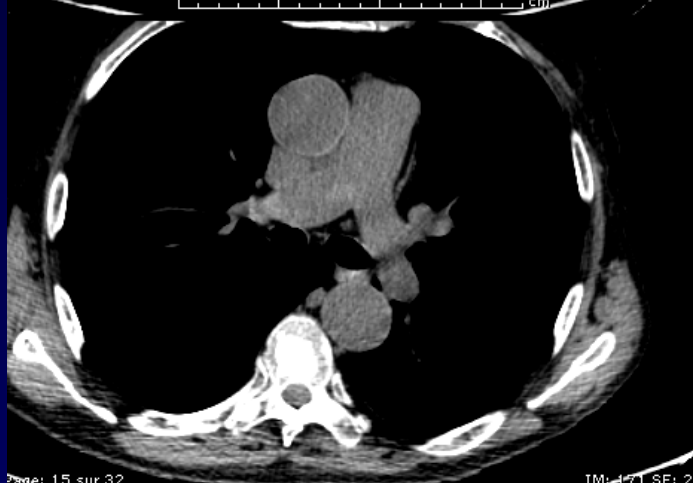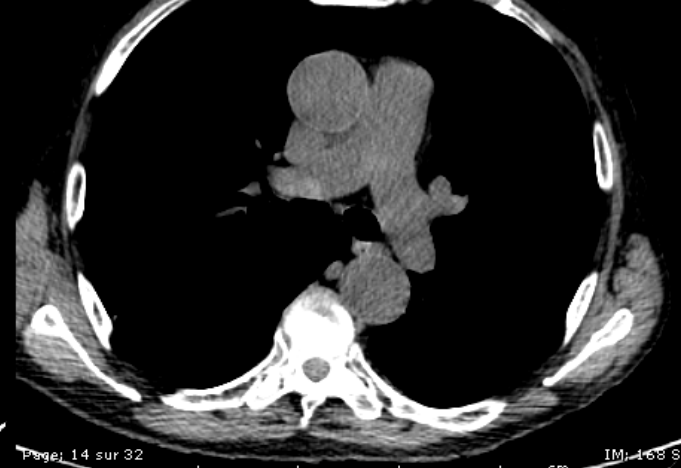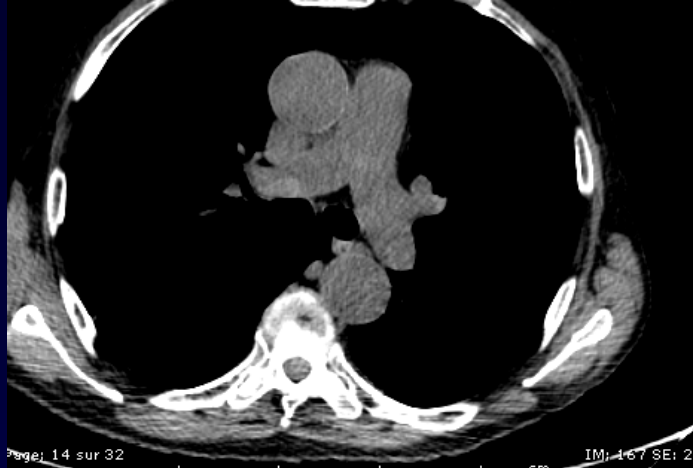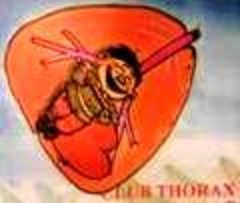IM: 131 SE: 2



Page: 11 sur 32 (82%)

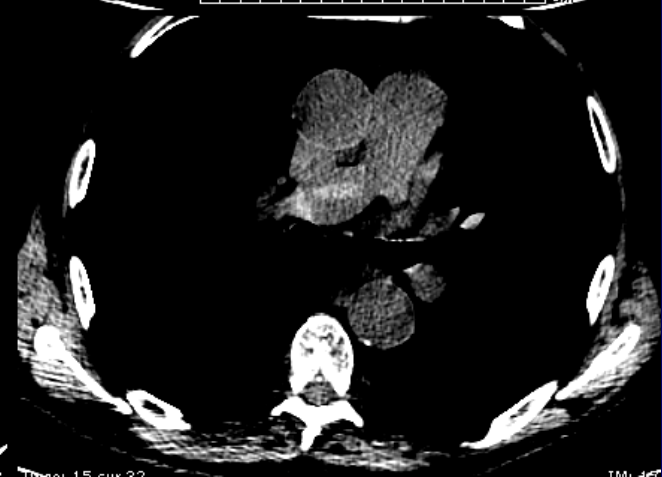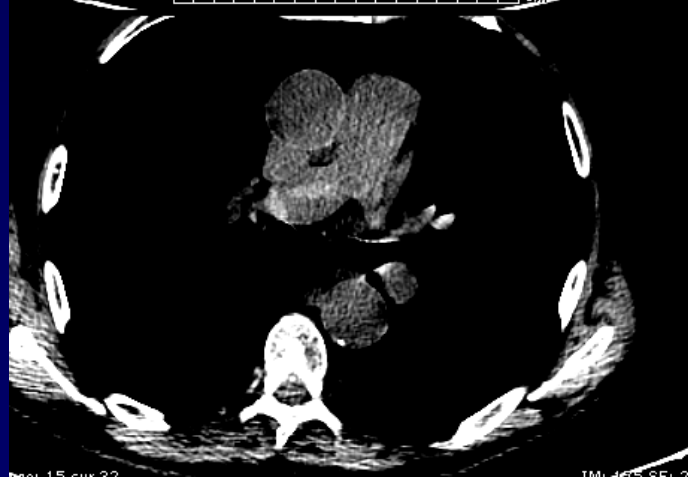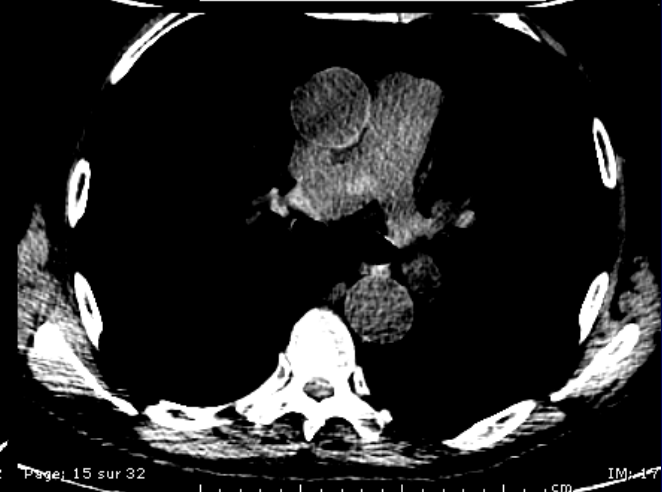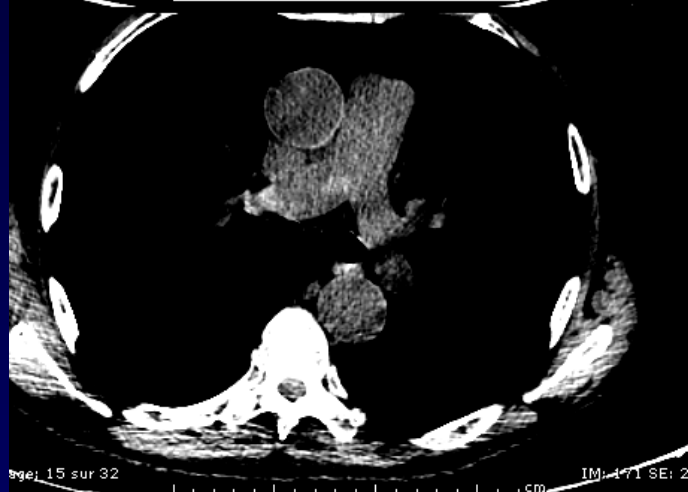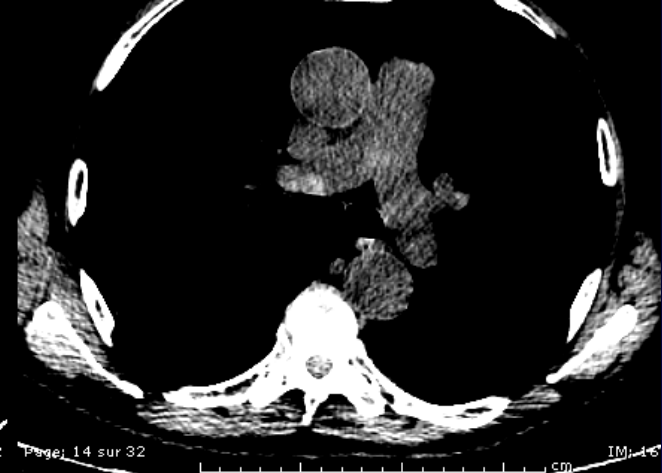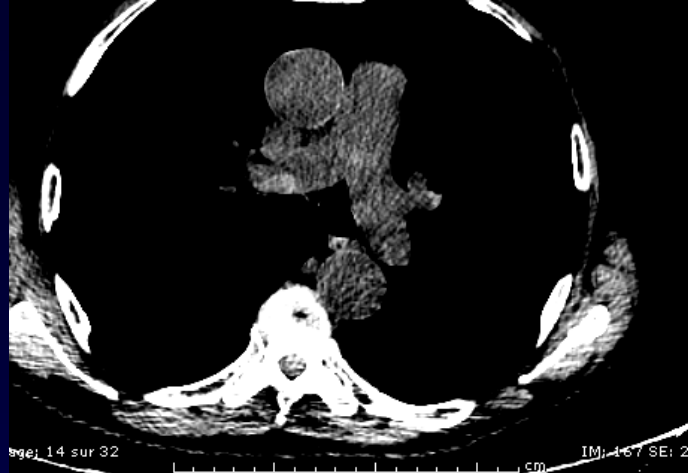
IM: 131







Diagnostic ?





Diagnostic

Embolie pulmonaire

Anévrisme de la crosse aortique

