



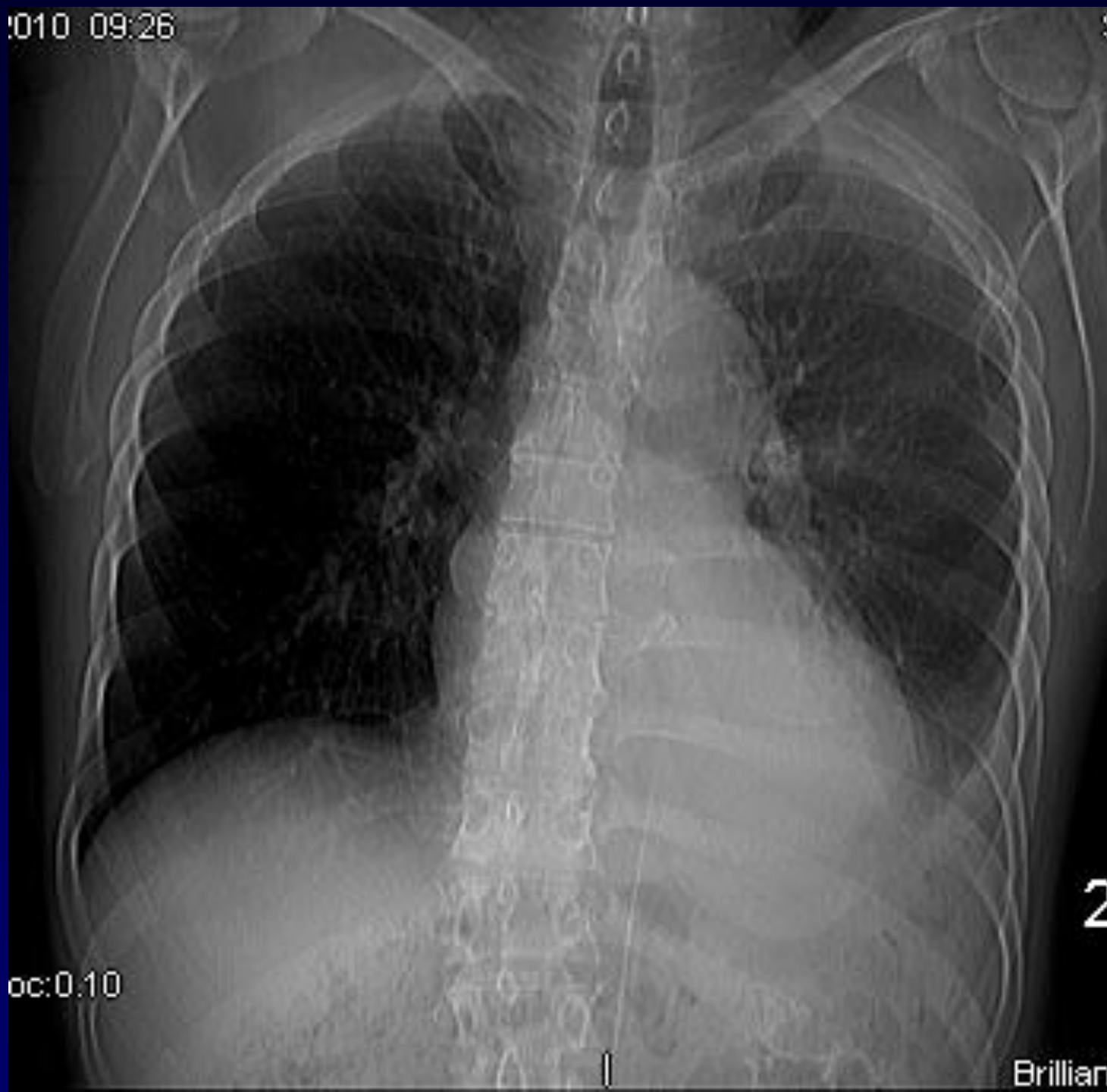
**J GIRON – P FAJADET**

Homme de 50 ans

Douleurs thoraciques rachidiennes et pleurales



010 09:26



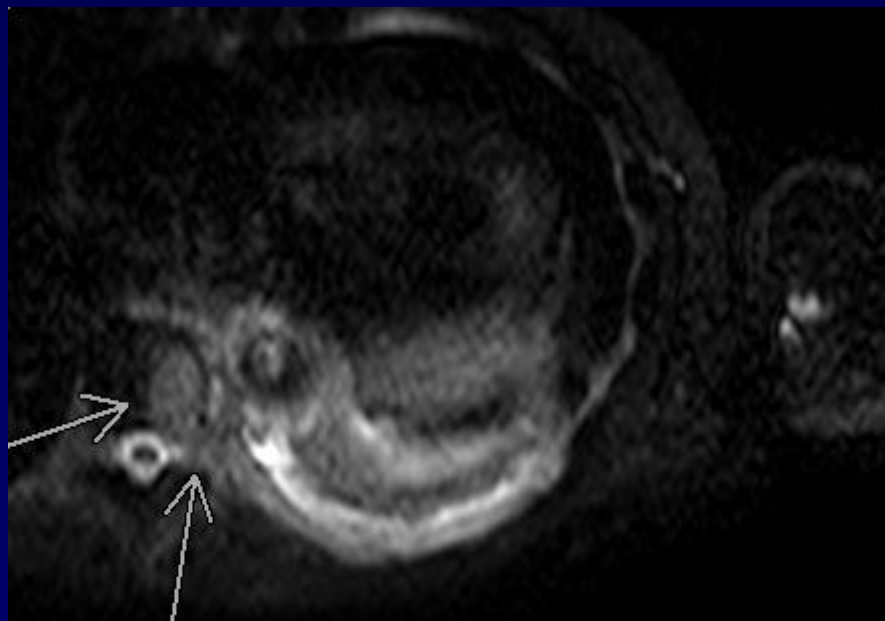
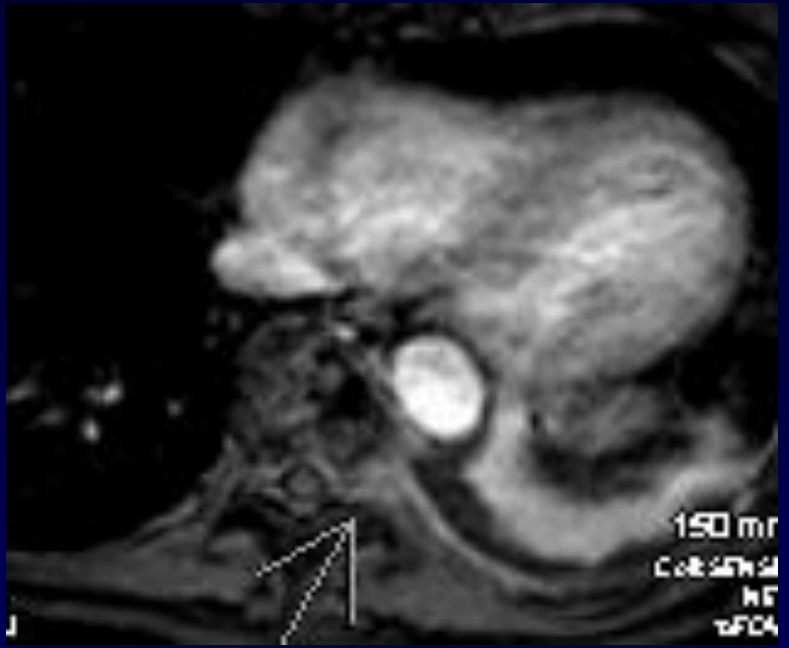
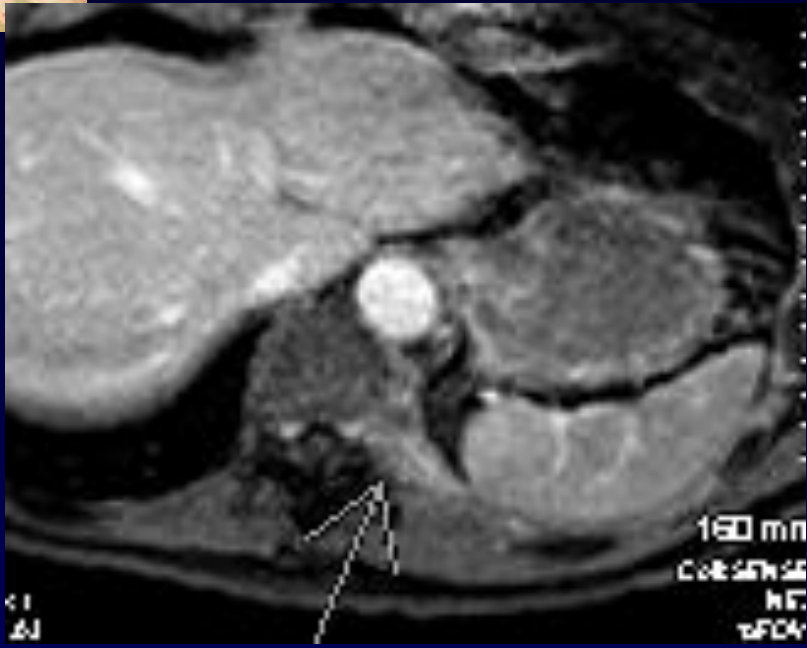
oc:0.10

2

Brilliant



# IRM RACHIS



T2 Apnee sag fs



512 x 512  
IRM THORACIQUE APC, IRM ANGIO TH

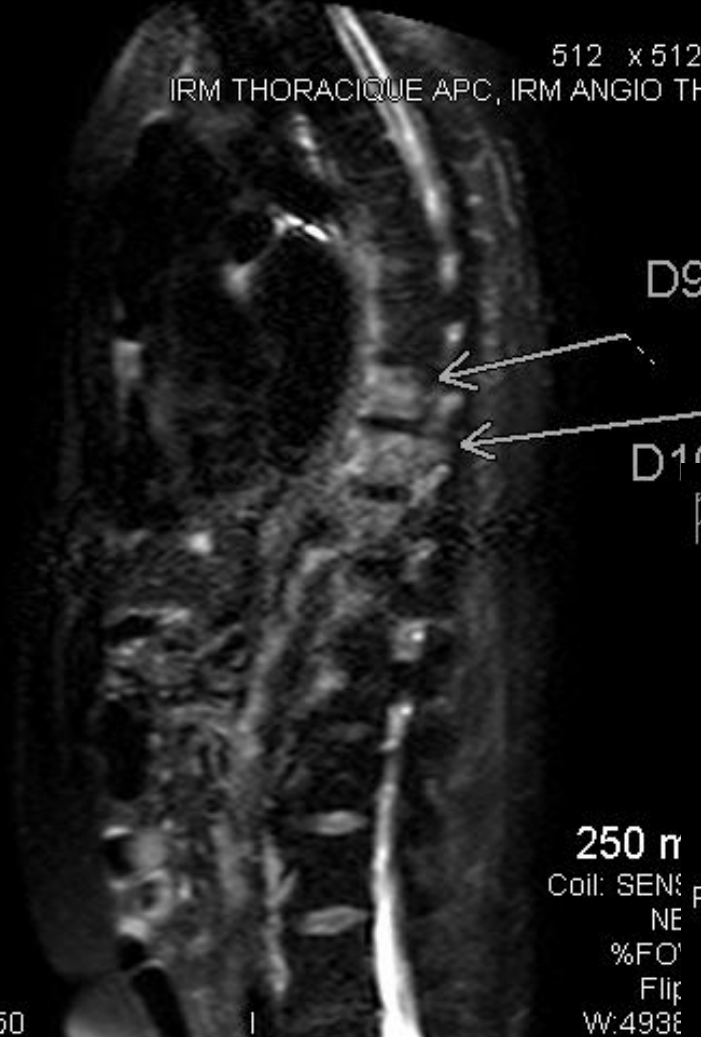A

D9

D10

2D  
Echo: 1  
TR: 435.18  
TE: 80.0  
Slice: 5.00 Loc: 137.50

250 mm  
Coil: SENSE  
NE  
%FOV  
Flip  
W: 4938

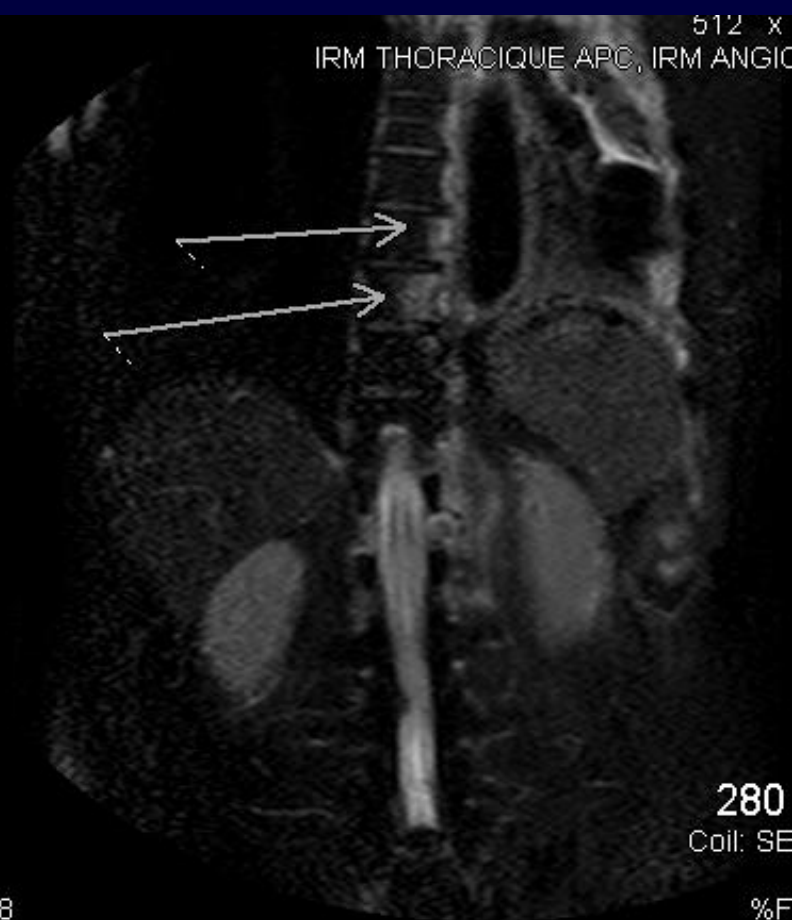

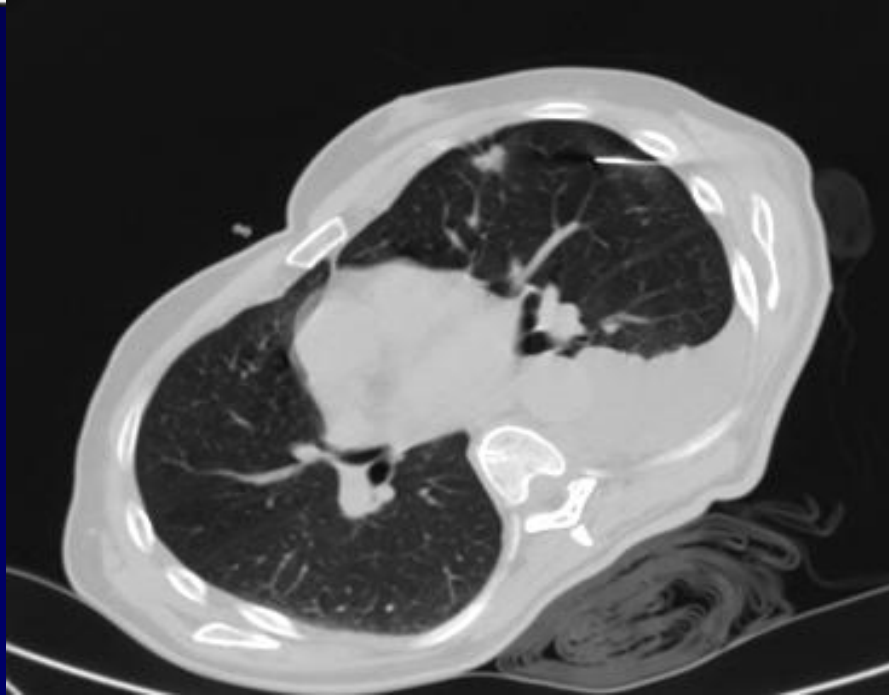
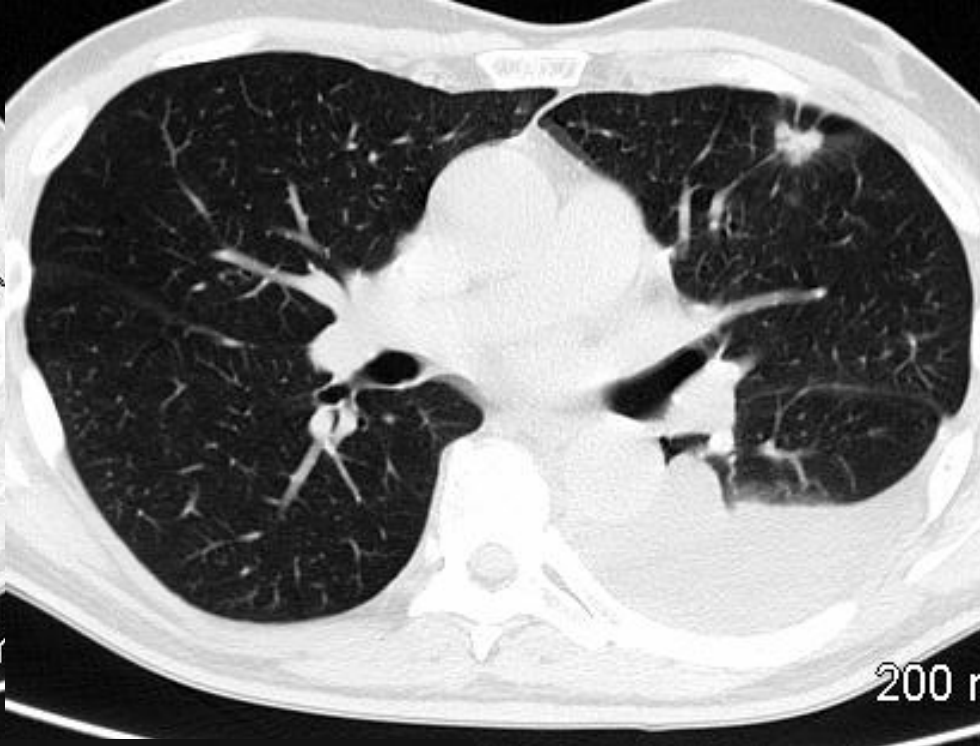
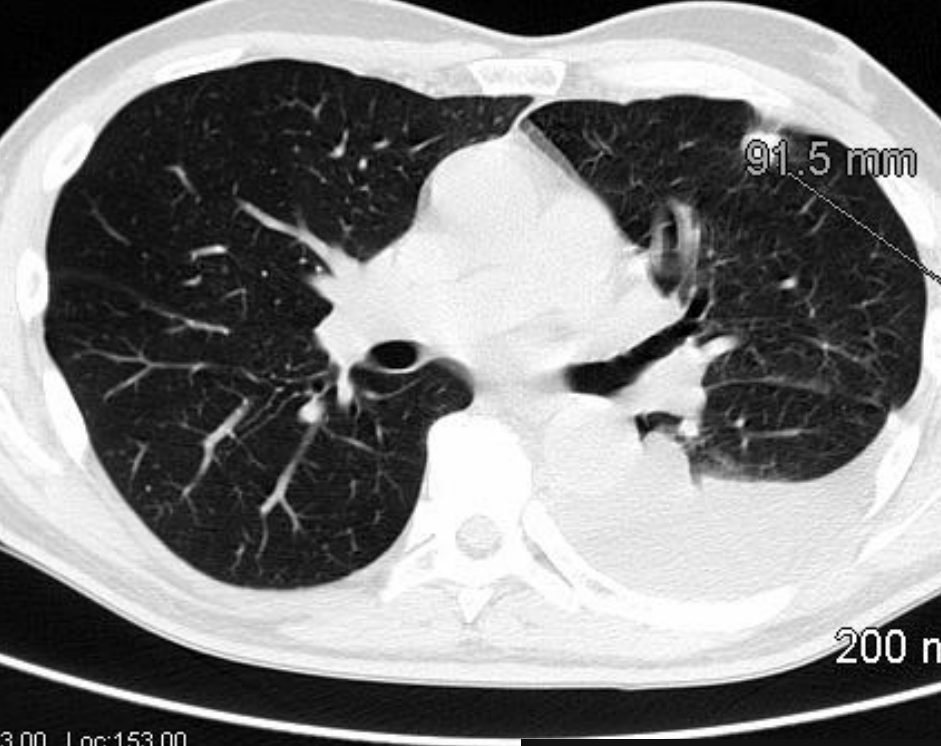
512 x 512  
IRM THORACIQUE APC, IRM ANGIO TH

2D  
Echo: 1  
TR: 435.18  
TE: 80.0  
Slice: 5.00 Loc: 110.00

280  
Coil: SENSE

%FOV  
F  
W: 34



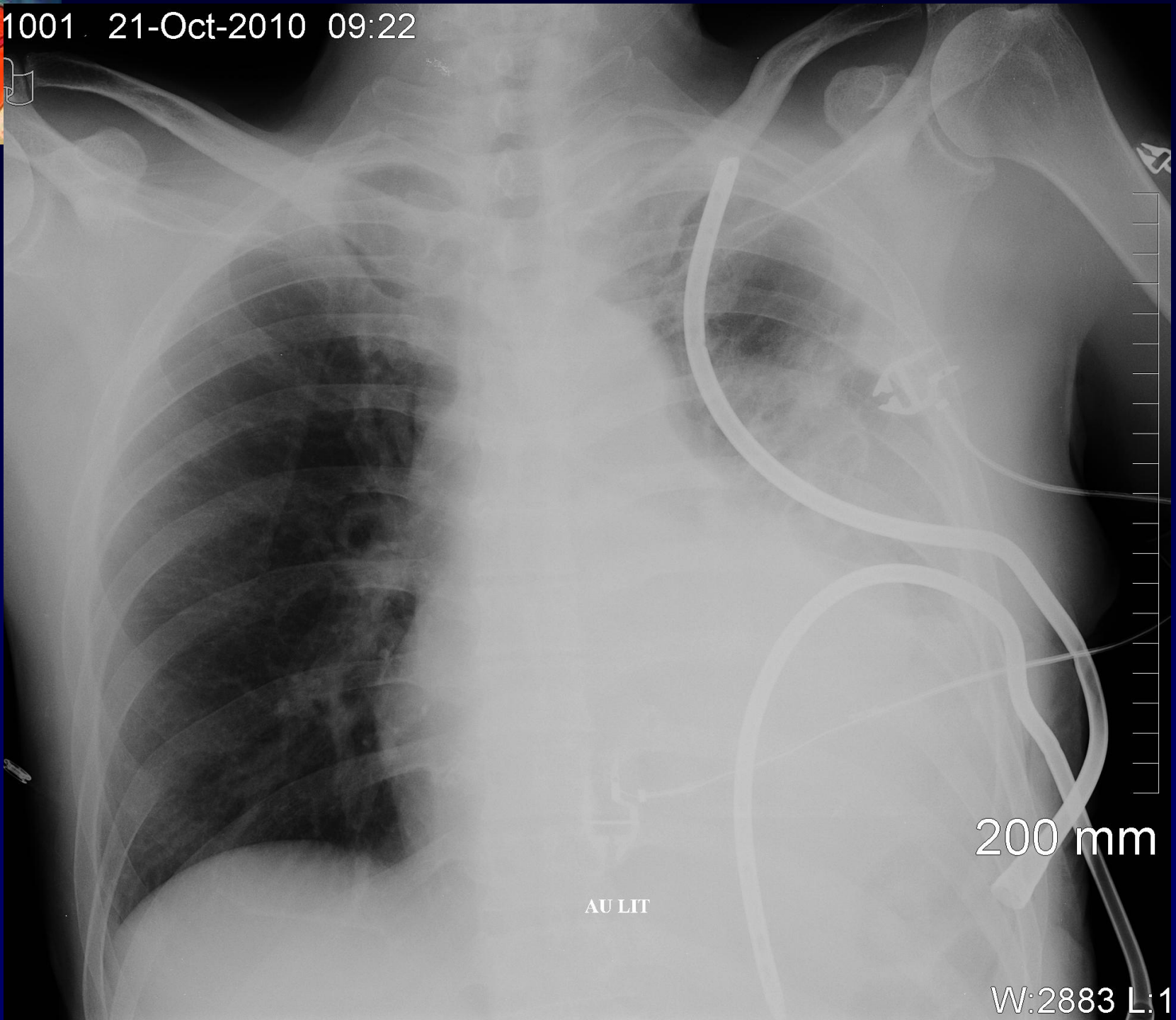




**DIAGNOSTIC ?**



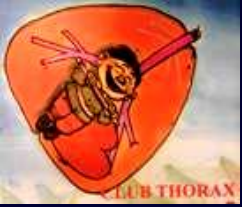1001 21-Oct-2010 09:22



200 mm

AU LIT

W:2883 L:1



# Diagnostic

**Hémangio-Endothéliome-Epithélioïde**

**Localisations os et poumon (pas foie )**

**Lobectomie et biopsie - stabilisation vertébrale**