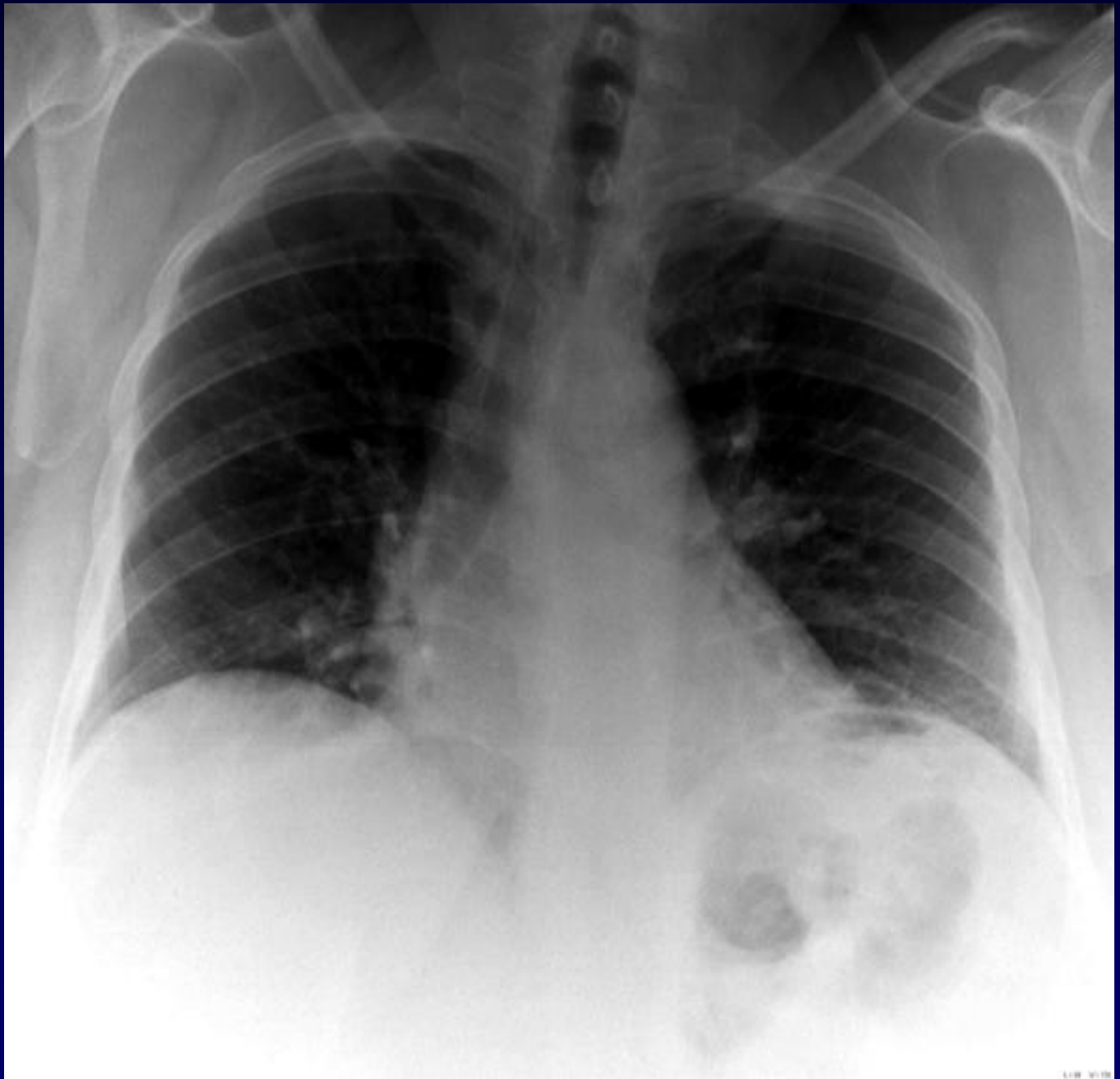


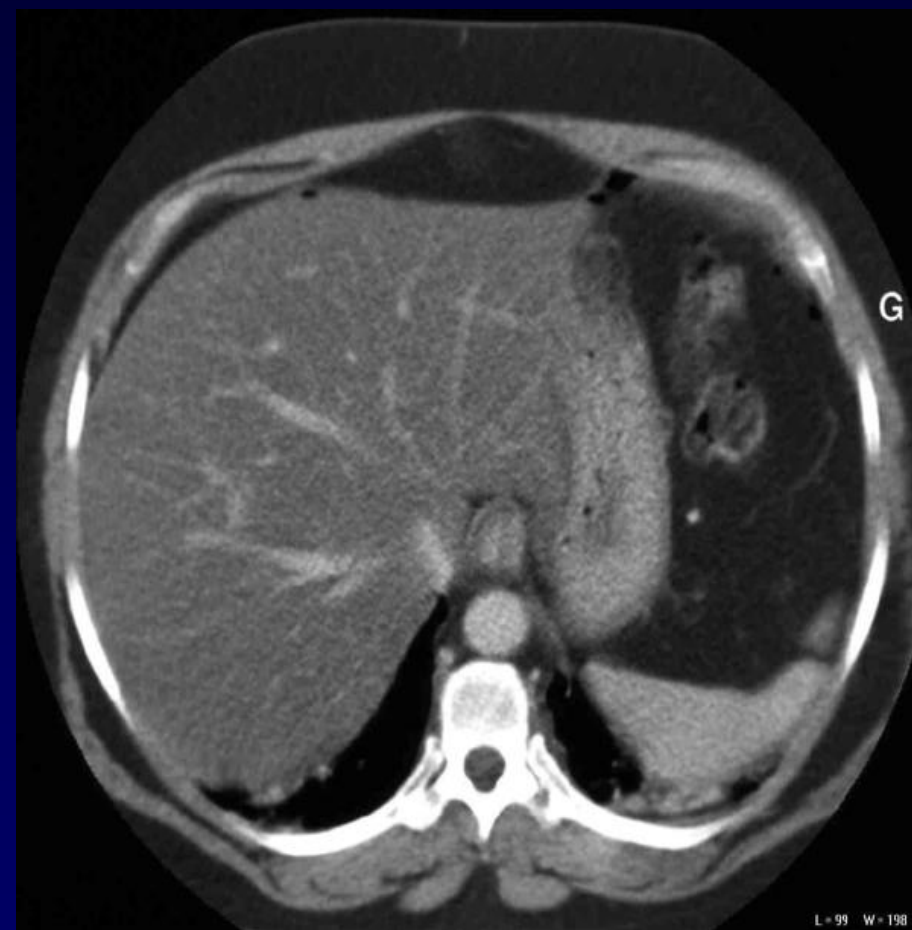
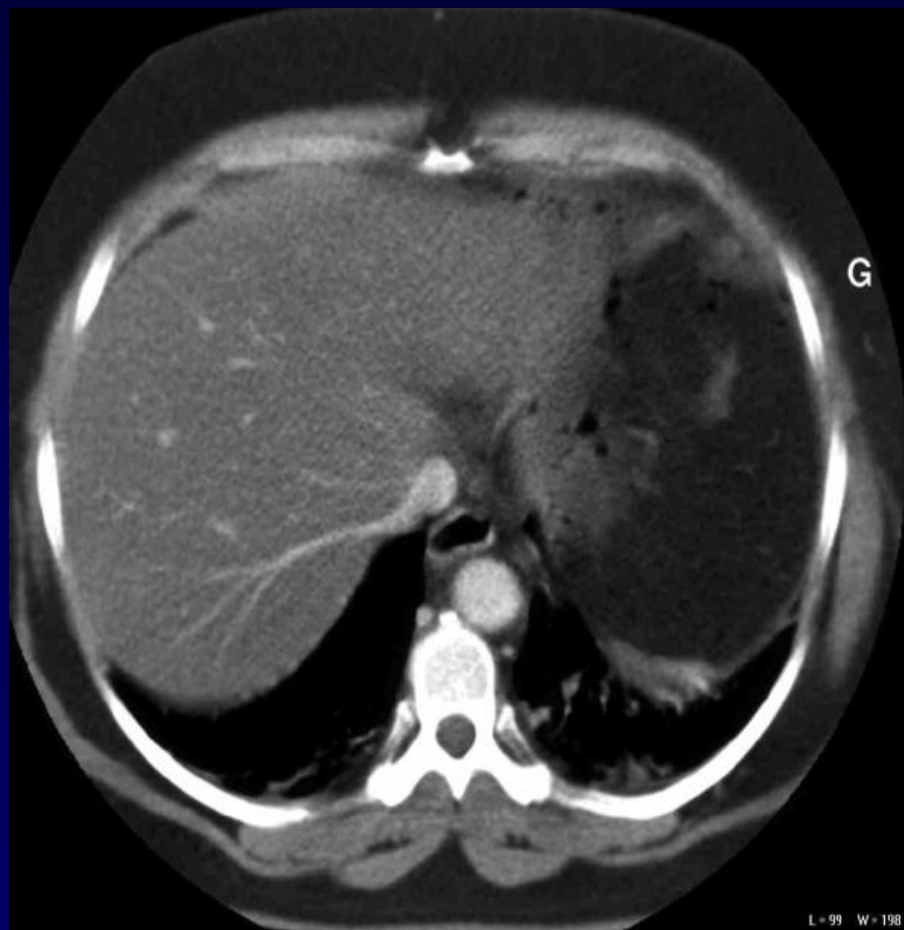
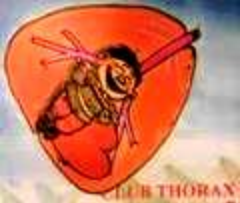

D. Jeanbourquin

femme de 51 ans

Douleur basithoracique gauche







Diagnostic ?



Pneumopéritoine par perforation d'un ulcère de la petite courbure