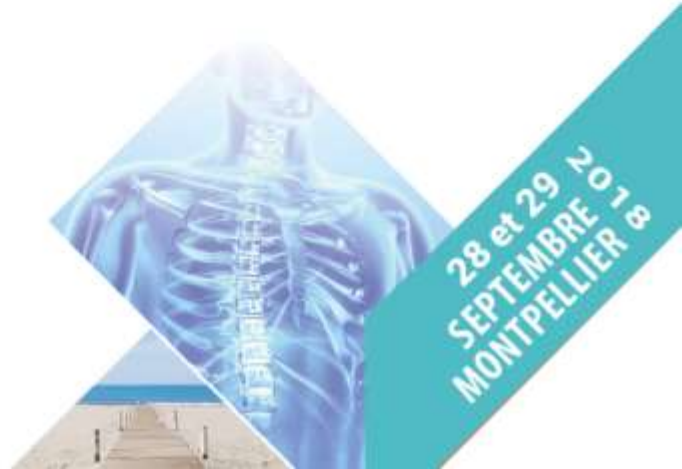



CONGRÈS

Imagerie Appliquée à la Pratique Pneumologique

Cas N°7

N. Cherif Idrissi El Ganouni
M. Ouali Idrissi – K. Elatiqi



28 et 29
SEPTEMBRE 2017
MONTPELLIER

Femme de 27 ans

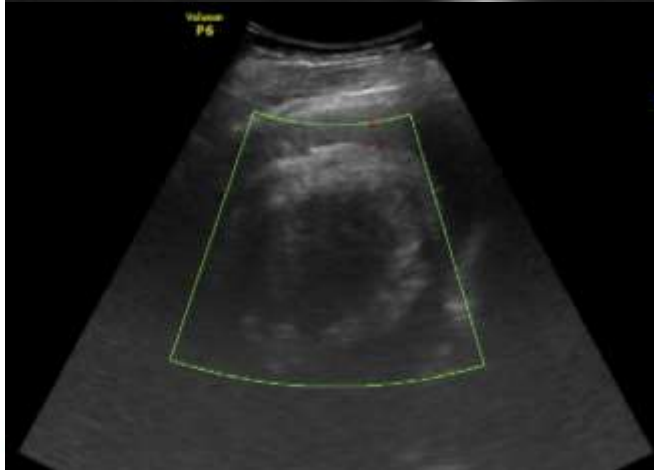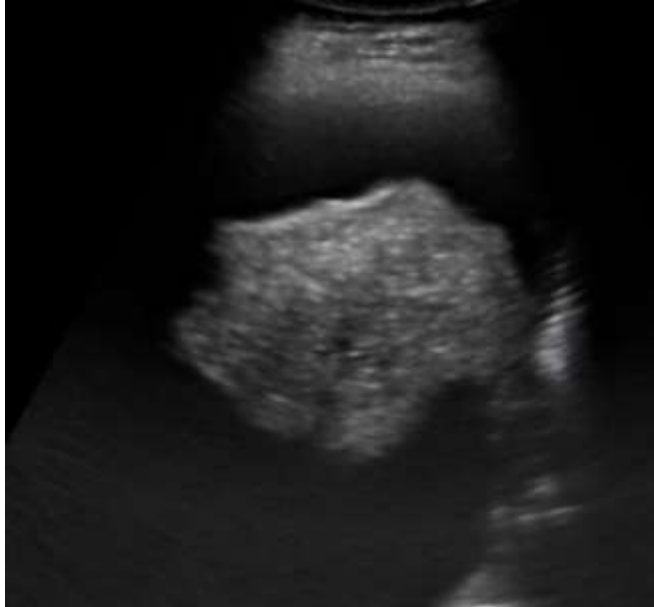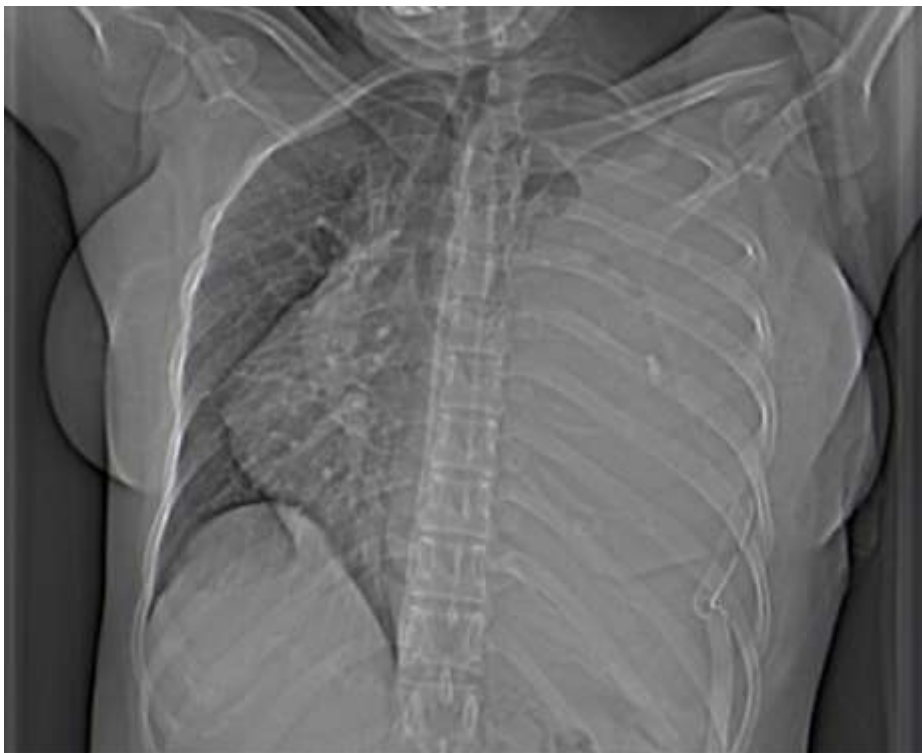ATCD = 0

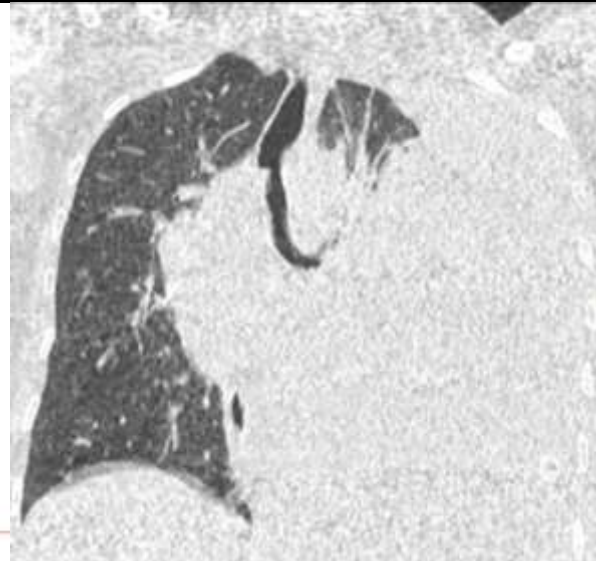
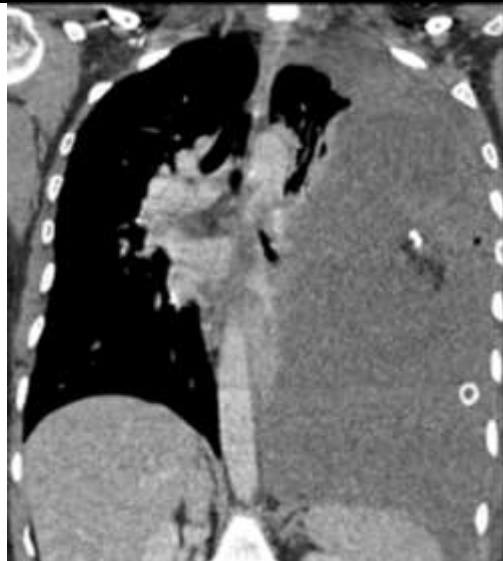
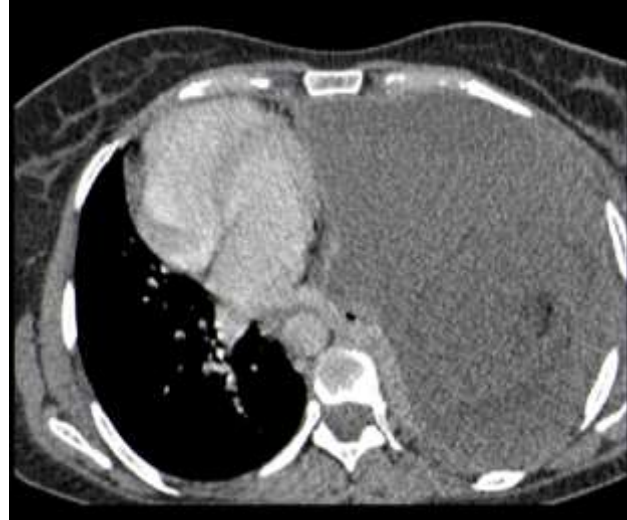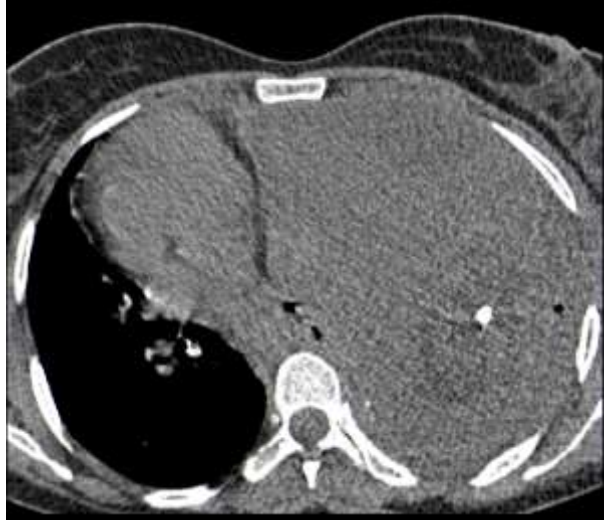Dyspnée d'aggravation progressive

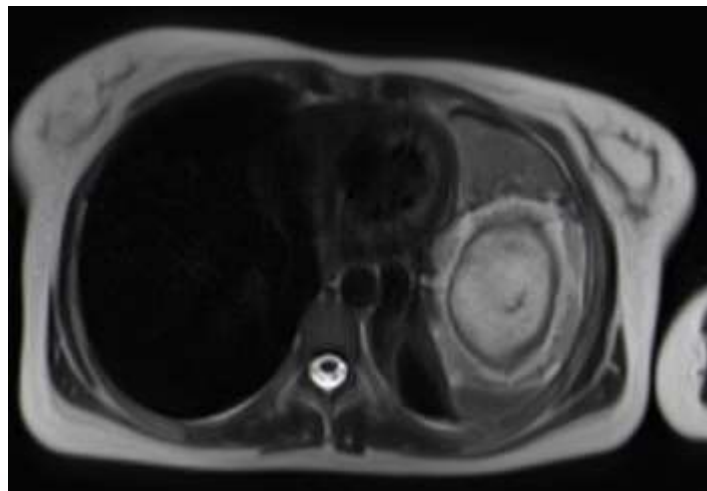
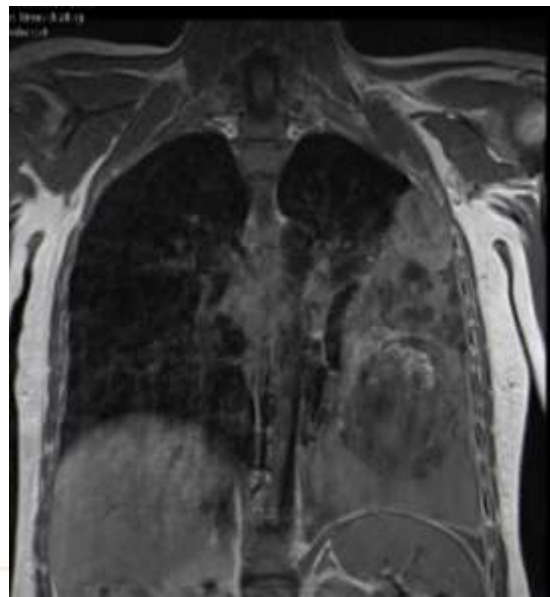
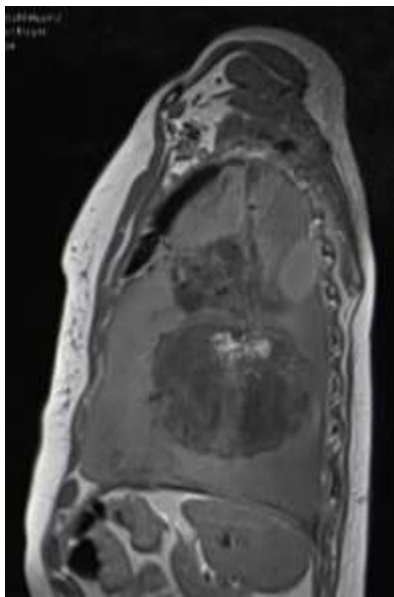
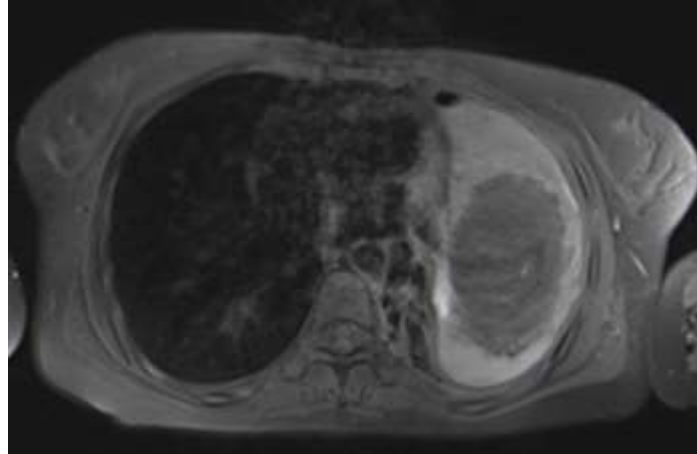
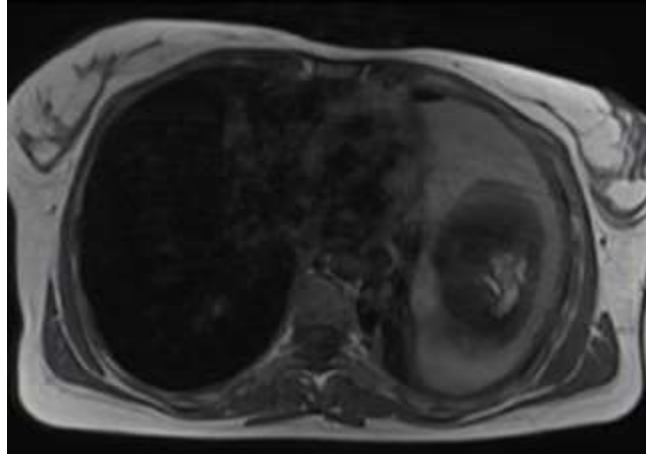
Apyrexie + conservation de l'état général

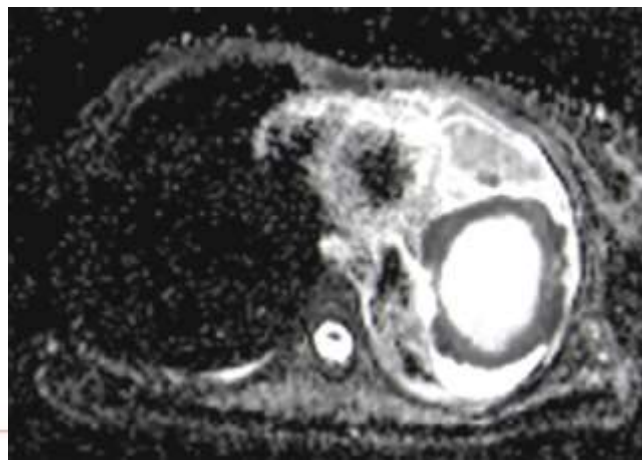
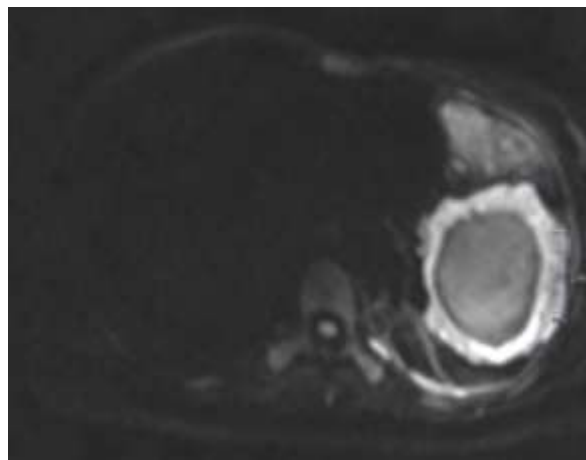
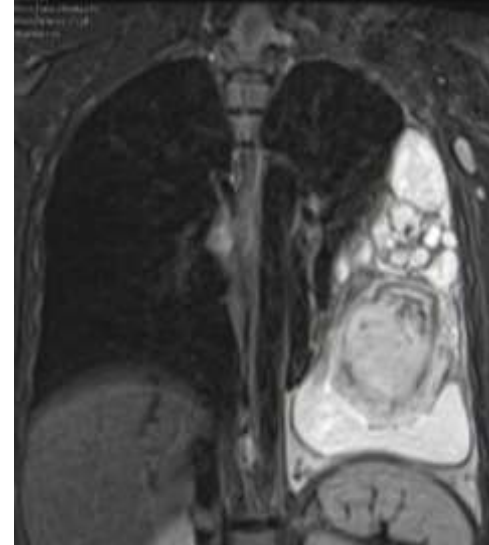
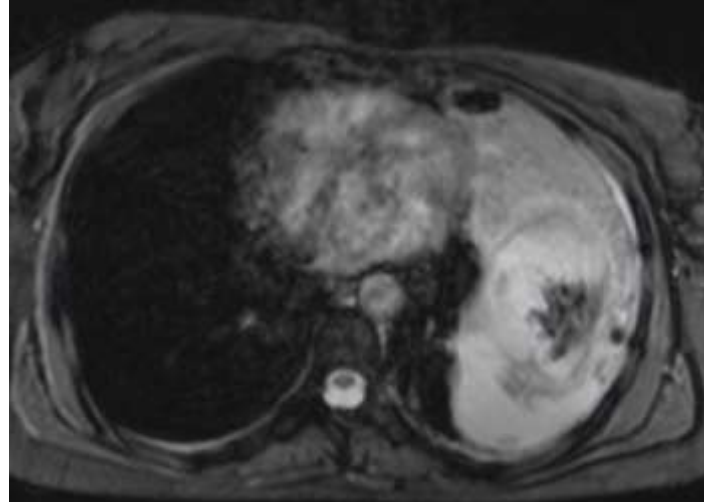
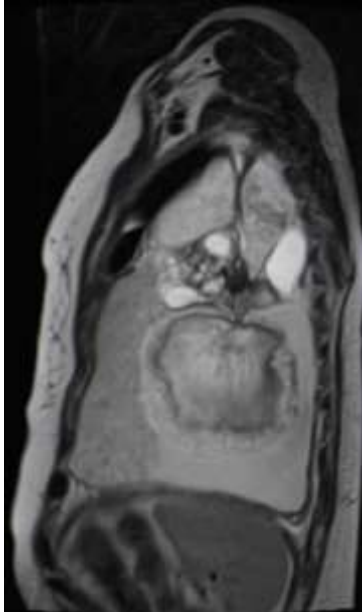
Examen clinique: matité de l'hémichamp pulmonaire gauche











Diagnostic ?

