

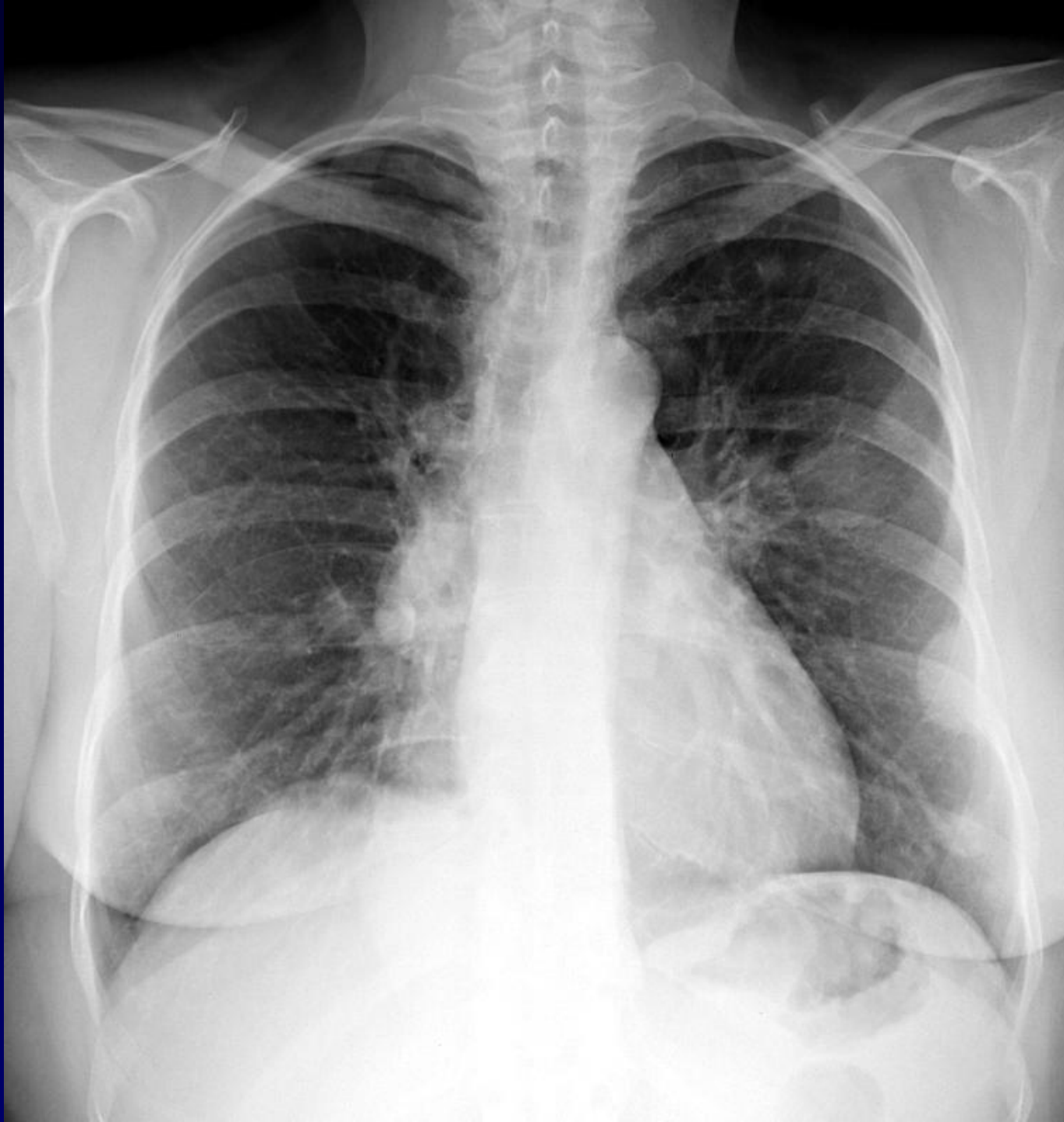

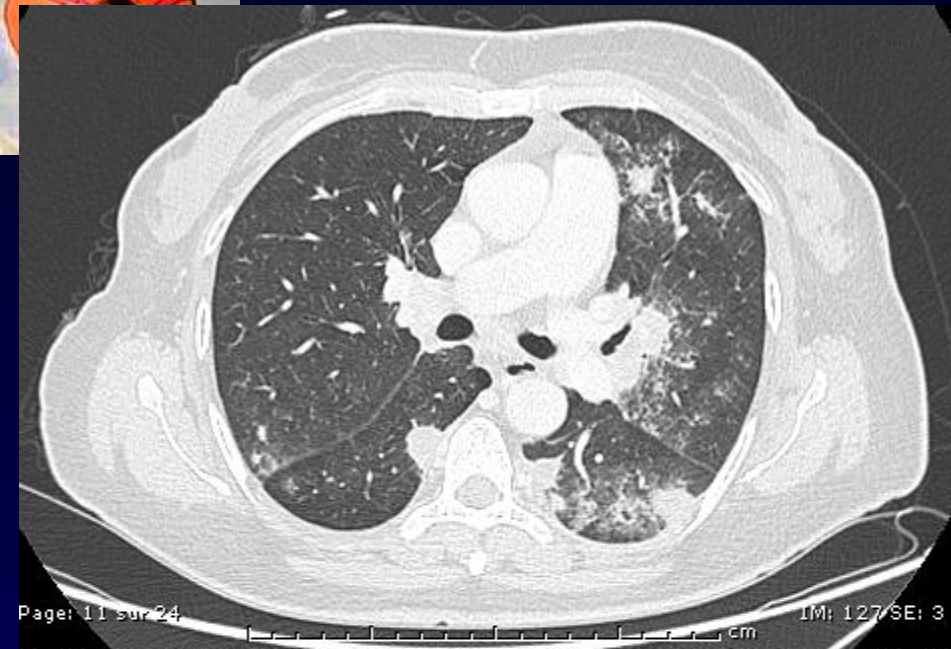
A LACOUT

Femme de 54 ans

Bilan rhumatismal : Rx articulaires et RT

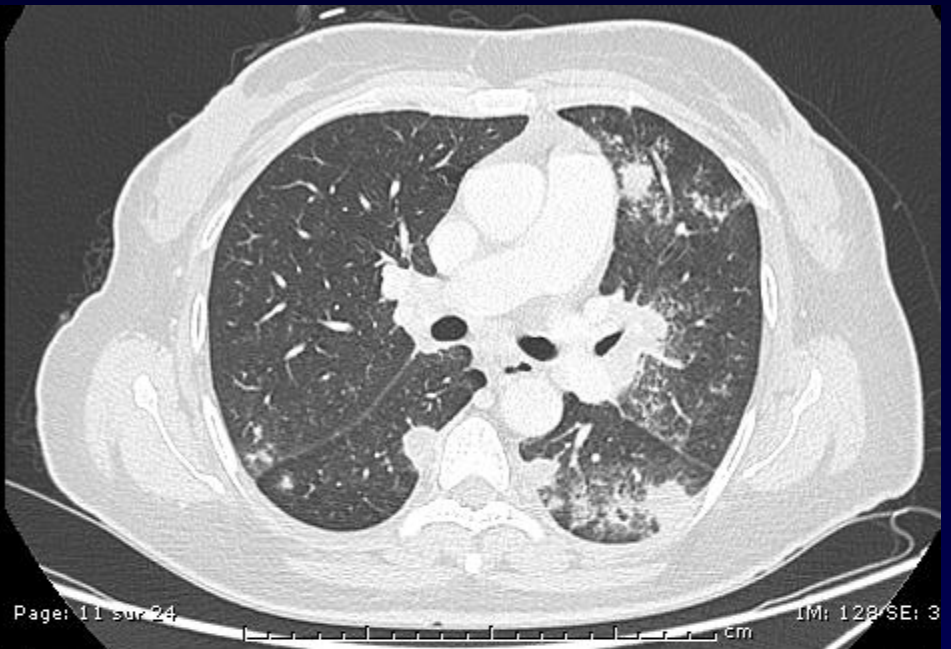
Asymptomatique sur le plan respiratoire





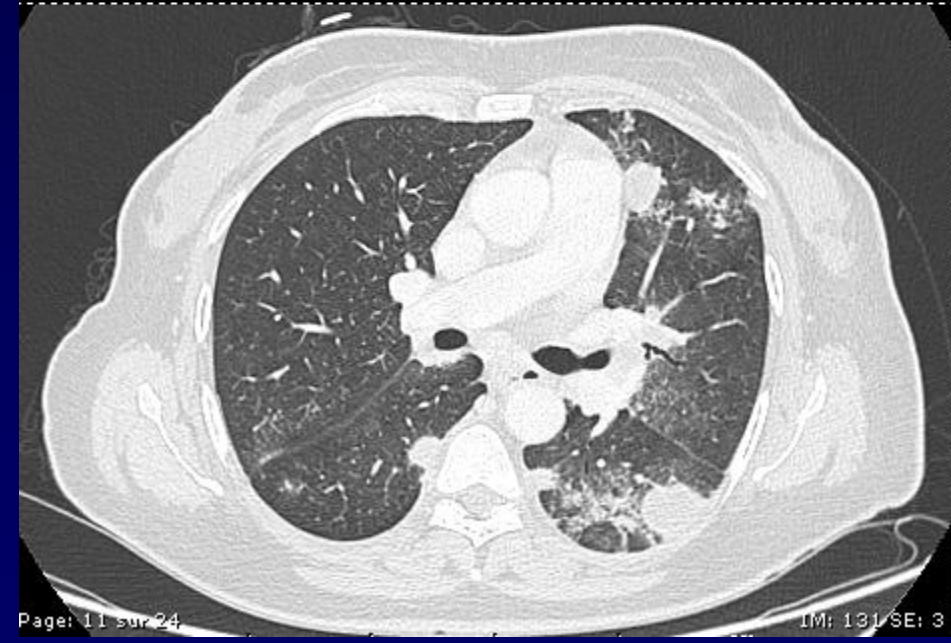
Page: 11 sur 24

IM: 127/SE: 3



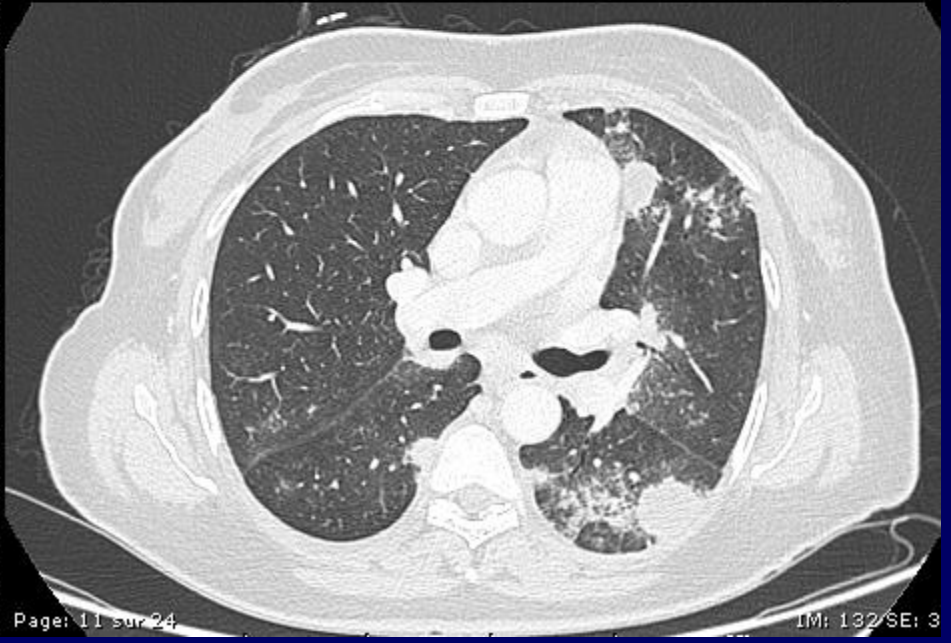
Page: 11 sur 24

IM: 128/SE: 3



Page: 11 sur 24

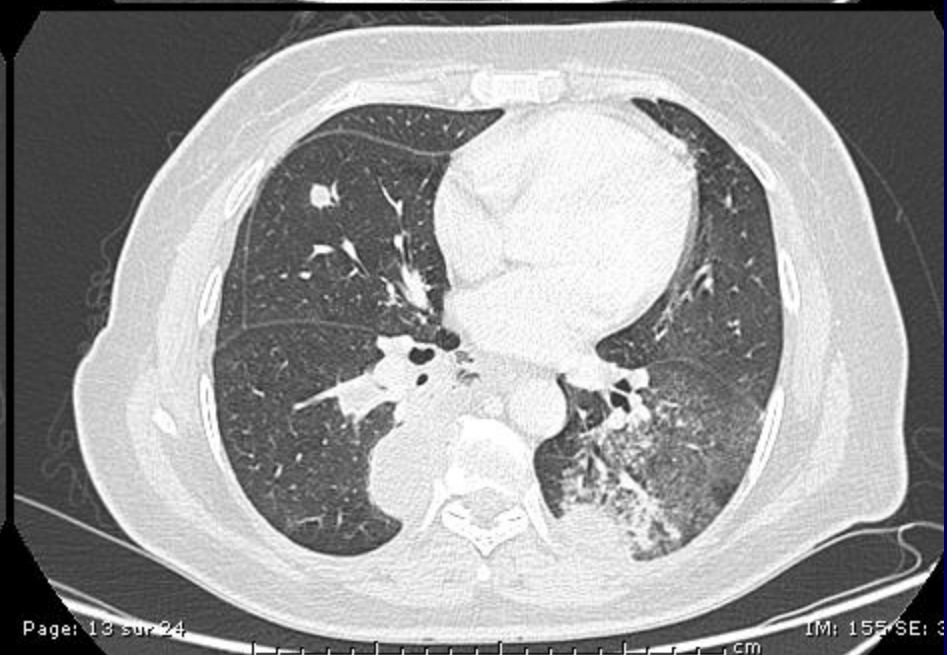
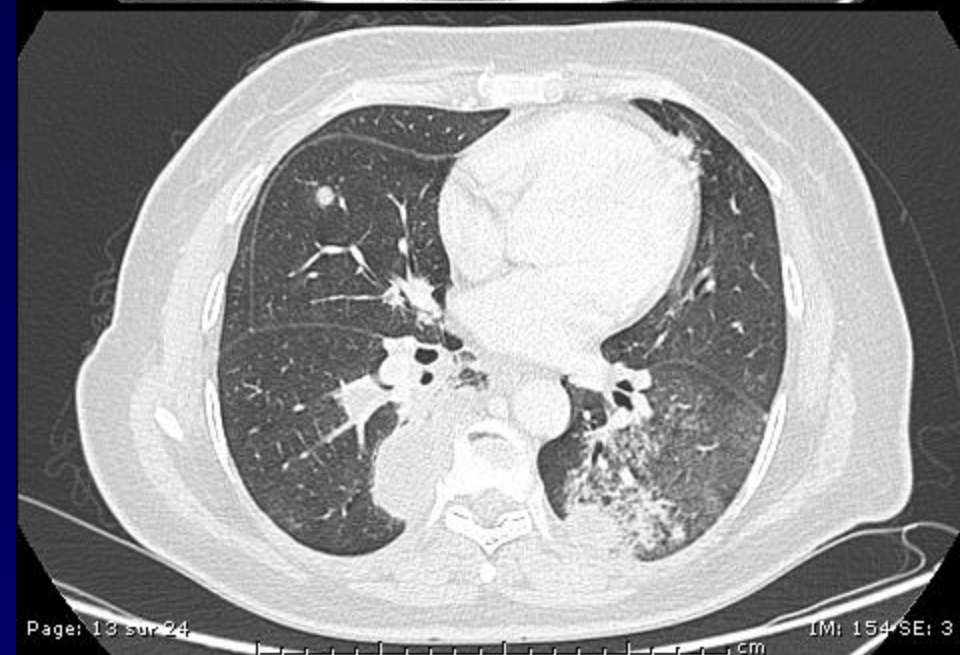
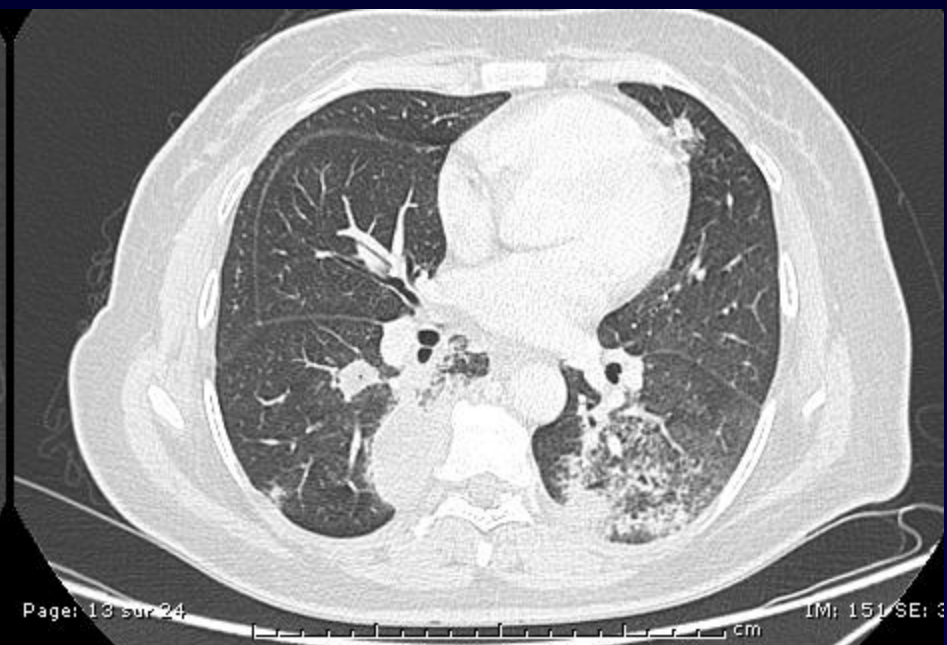
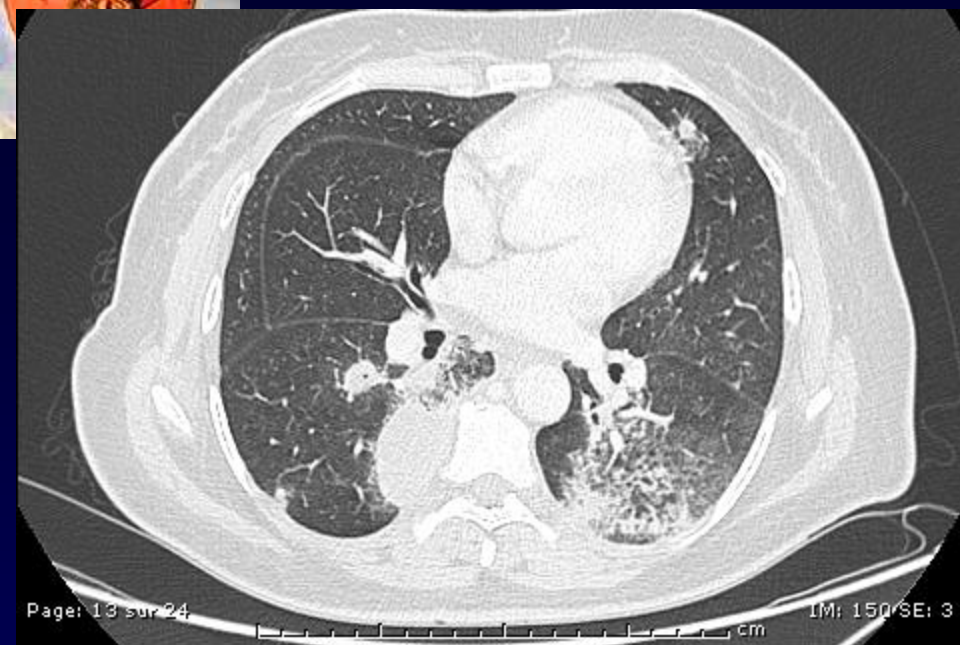
IM: 131/SE: 3

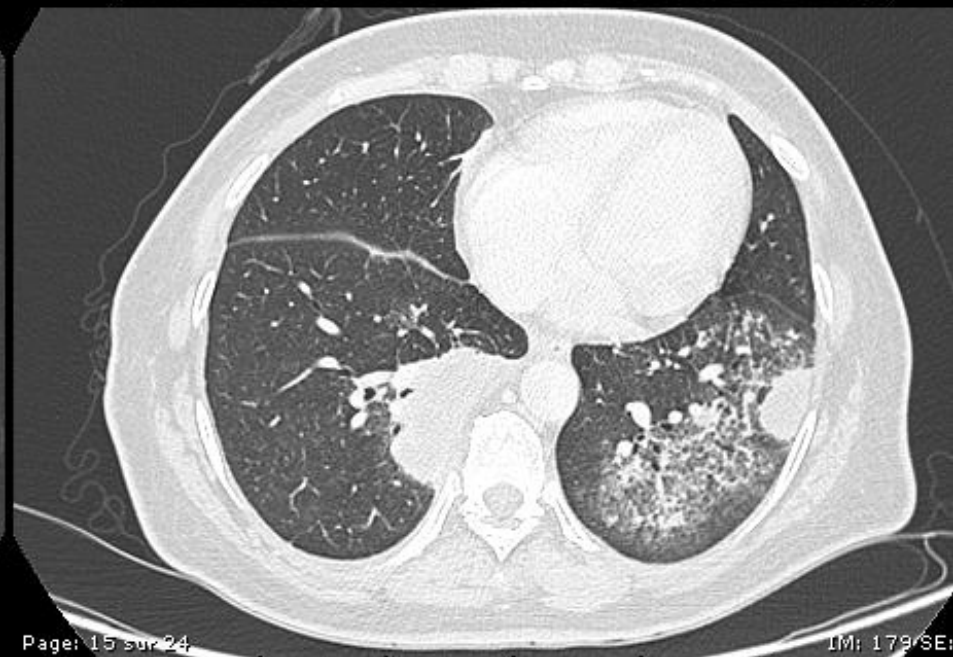
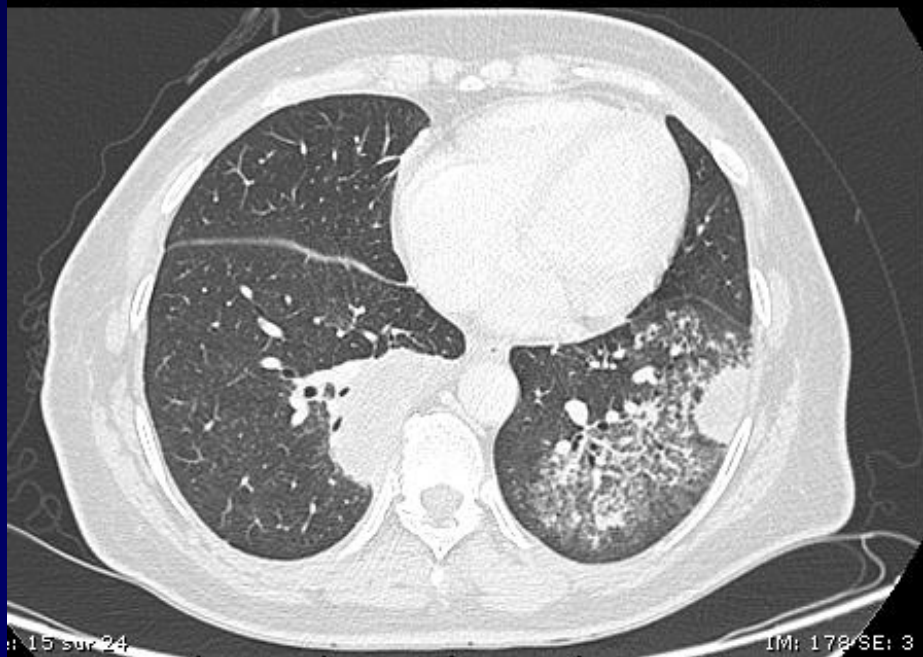
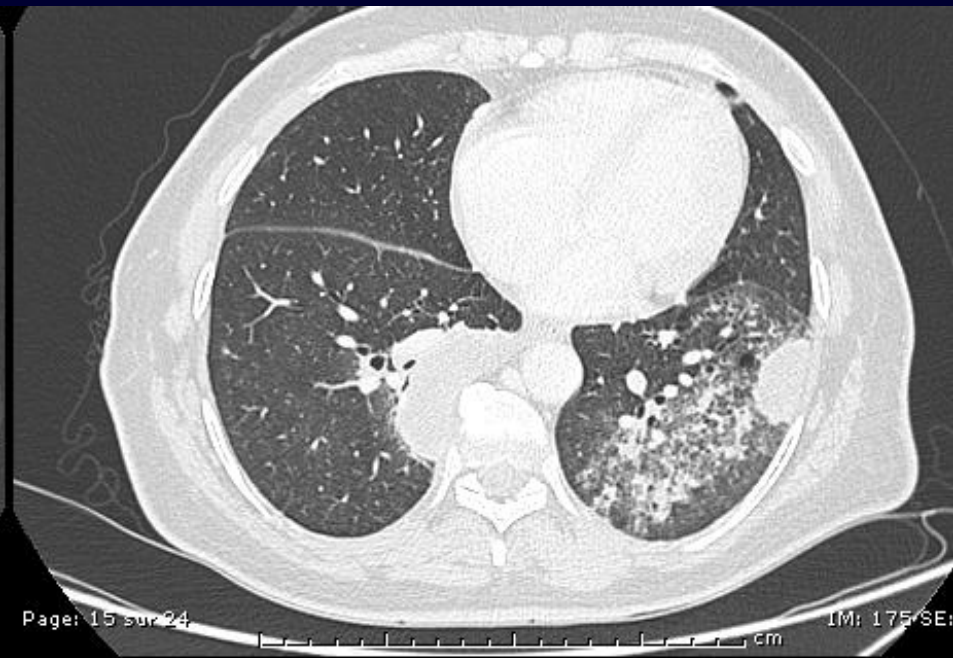
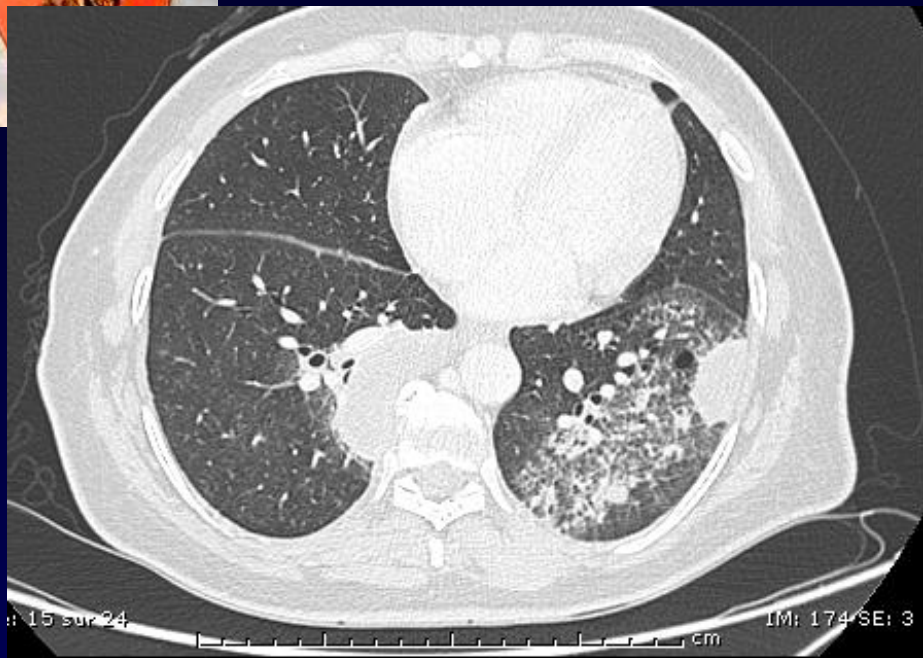


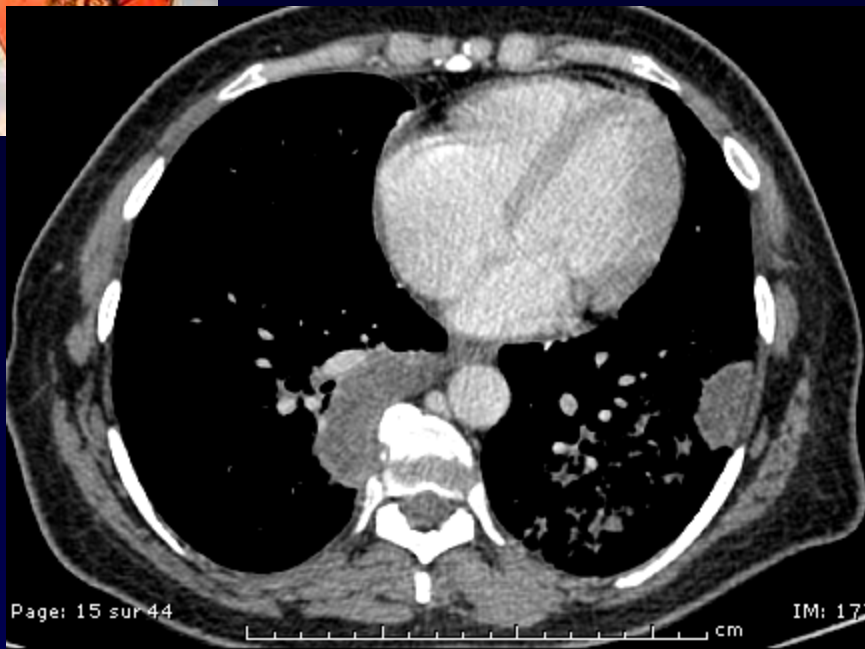
Page: 11 sur 24

IM: 132/SE: 3

Scanner J7

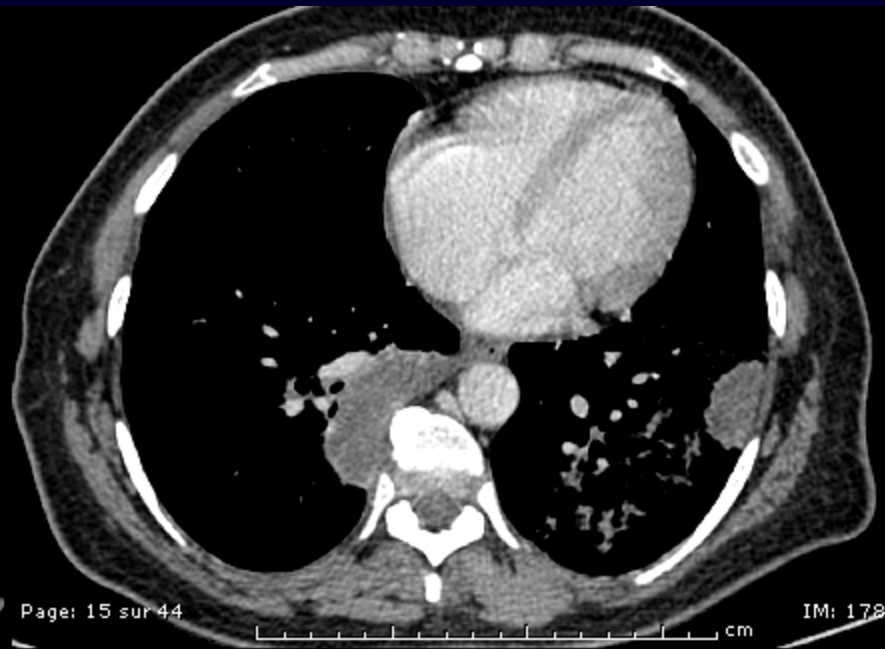






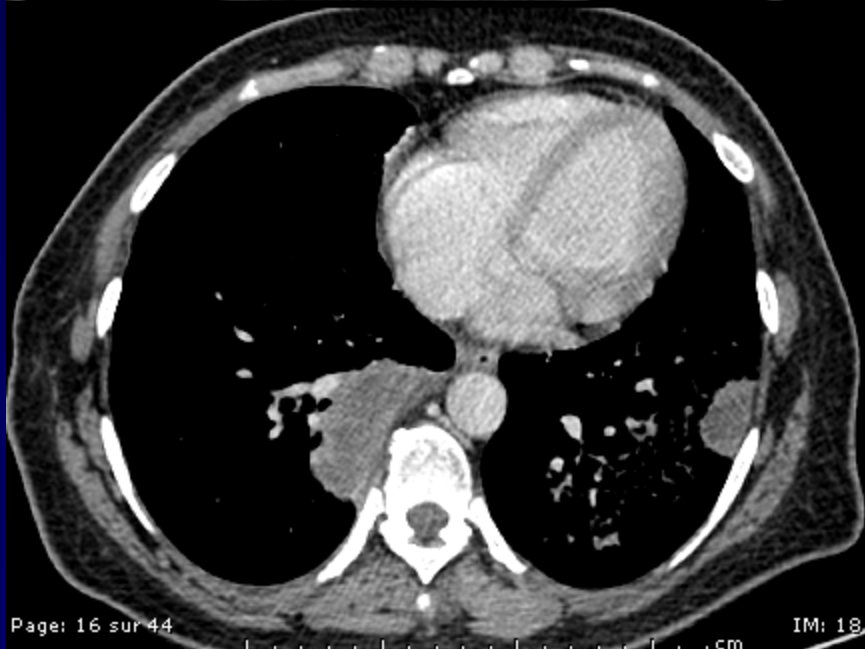Page: 15 sur 44

IM: 177 SE: 2



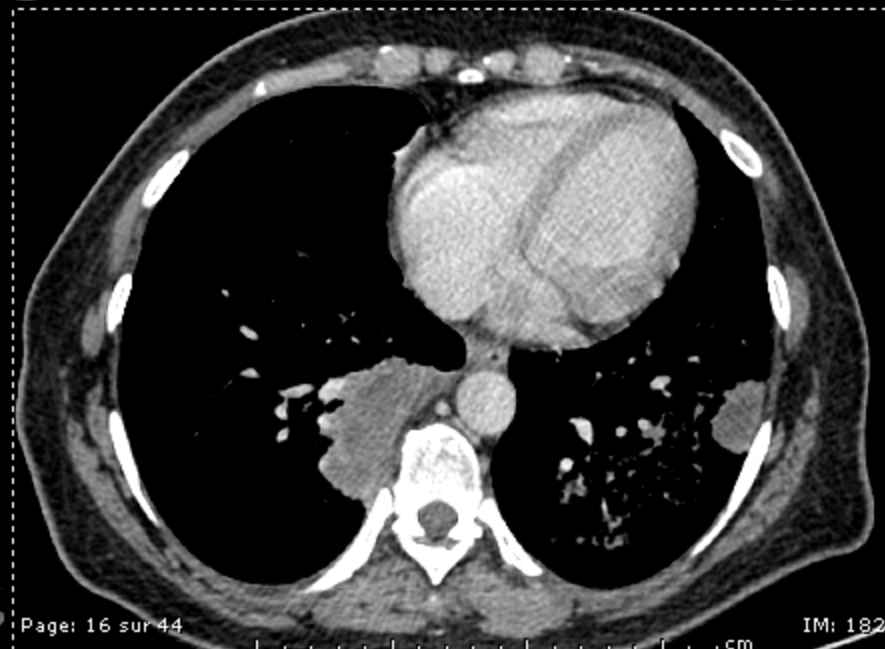
Page: 15 sur 44

IM: 178 SE: 2



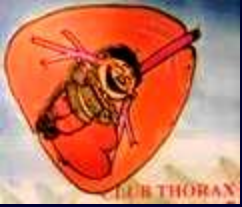Page: 16 sur 44

IM: 181 SE: 2



Page: 16 sur 44

IM: 182 SE: 2



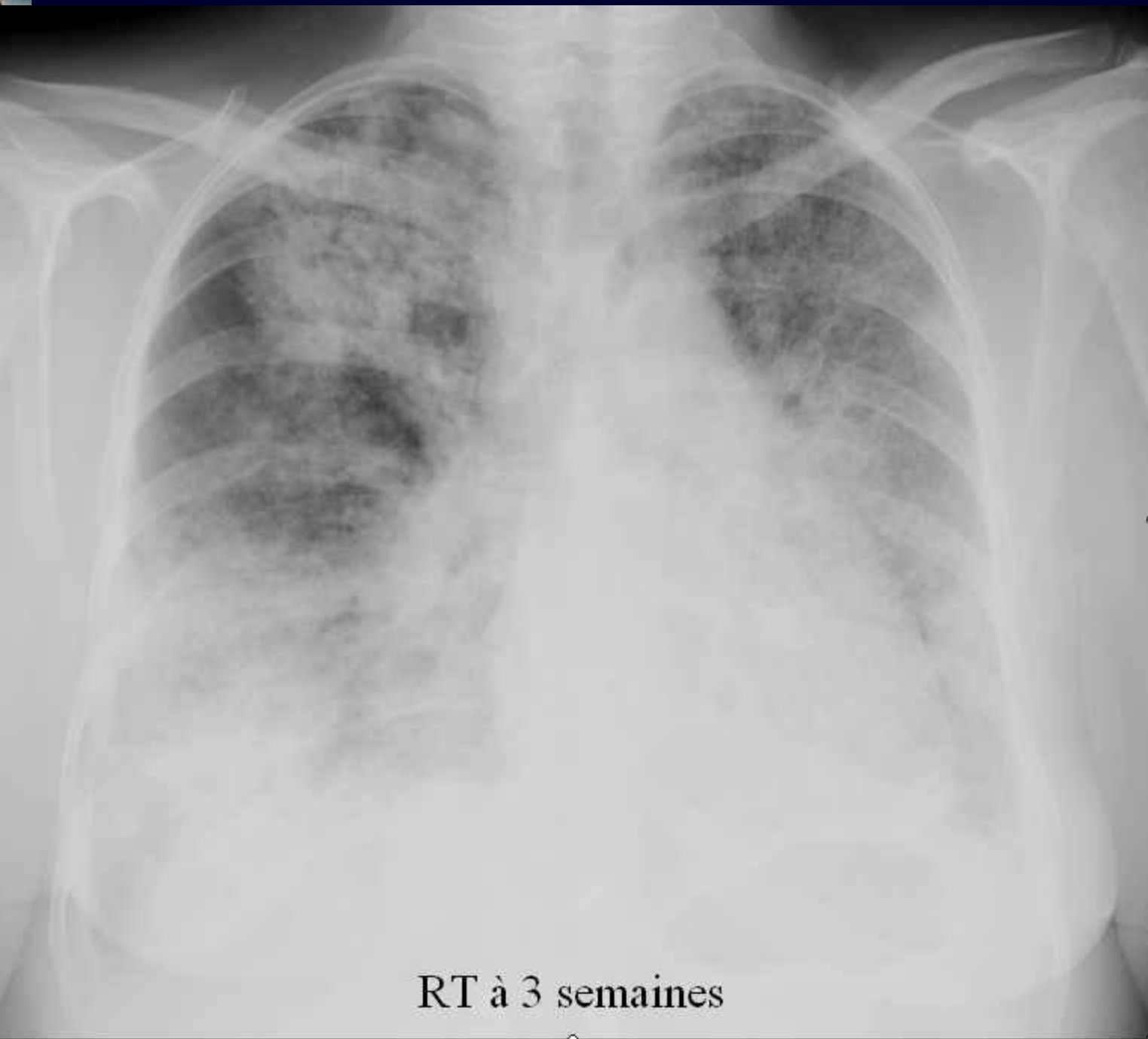
Bilan

Fibroscopie ; pas de biopsie effectuée ; saignement en base gauche

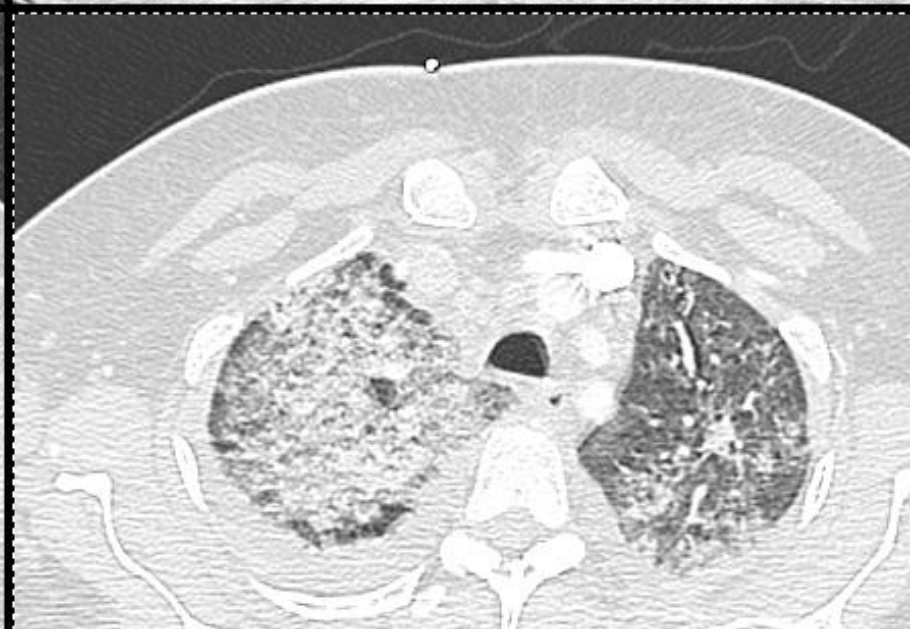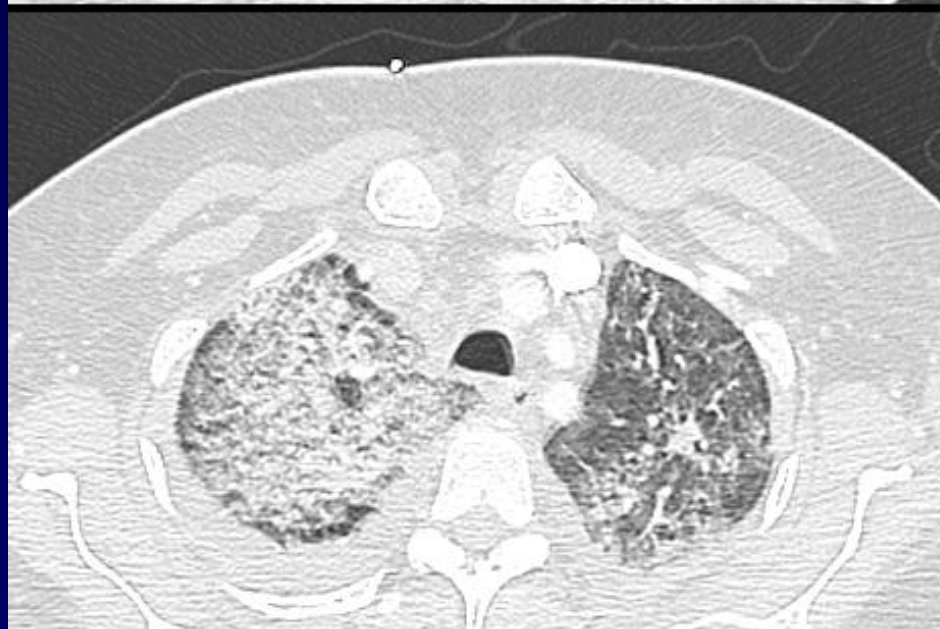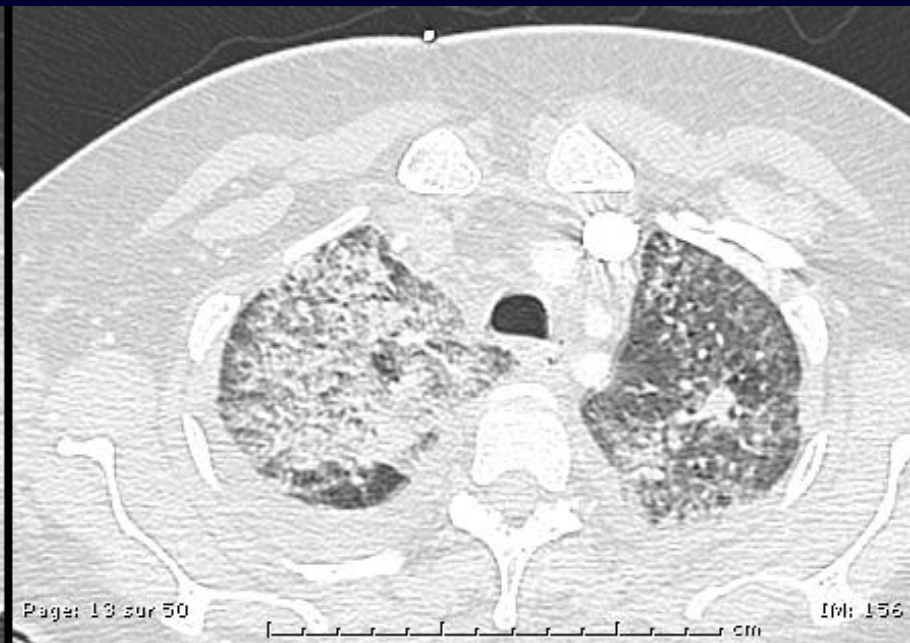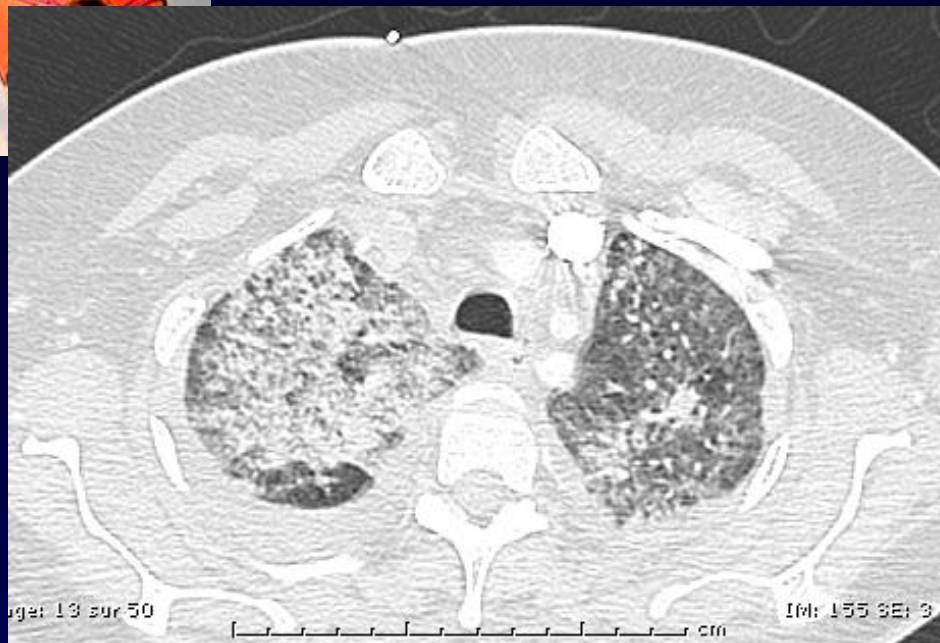Pas de néoplasie primitive (?)

Déglobulisation avec Hb : 5 g/dL....

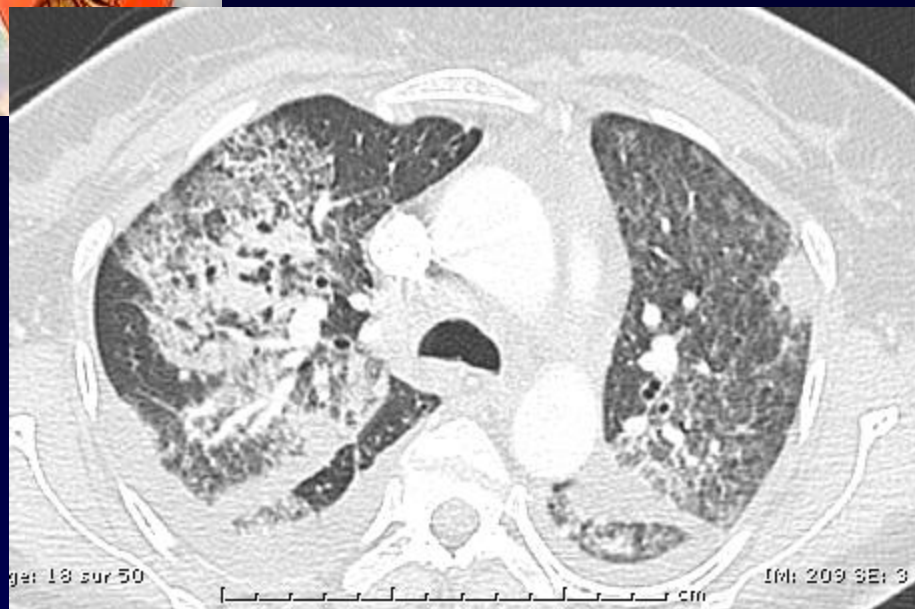Insuffisance respiratoire aigue rapidement progressive



RT à 3 semaines

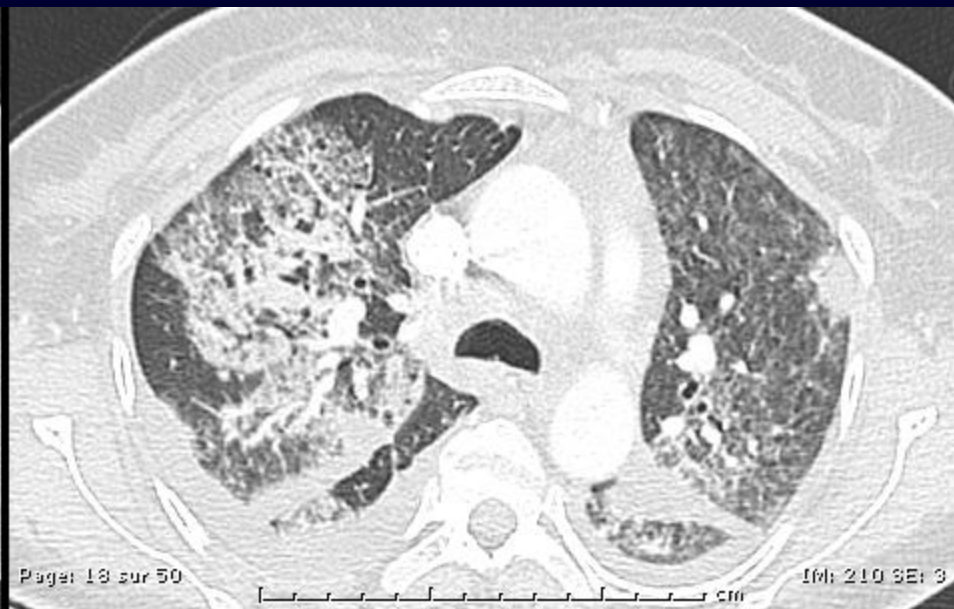

Scanner à 3 semaines



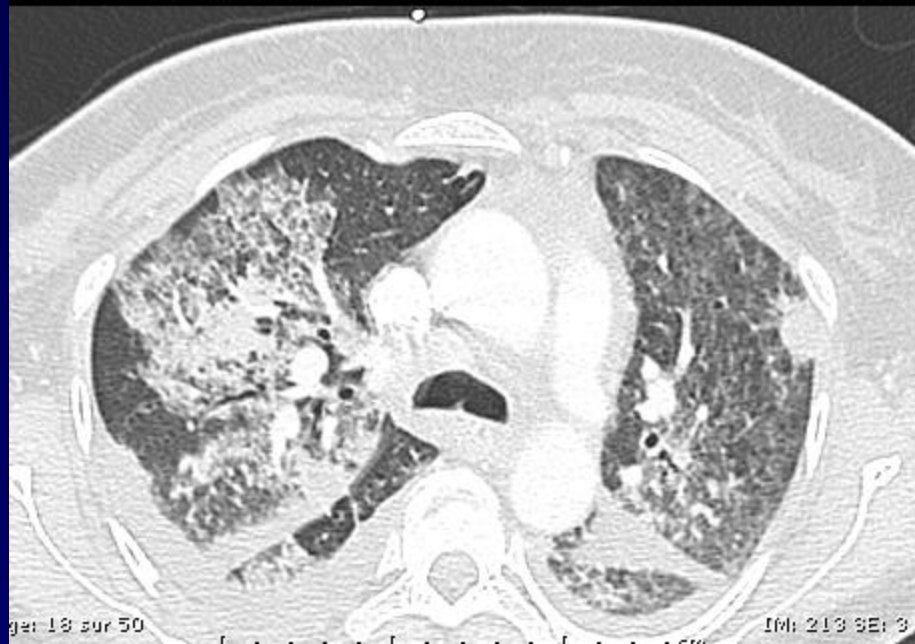Page: 18 sur 50

Im: 209 SE: 3



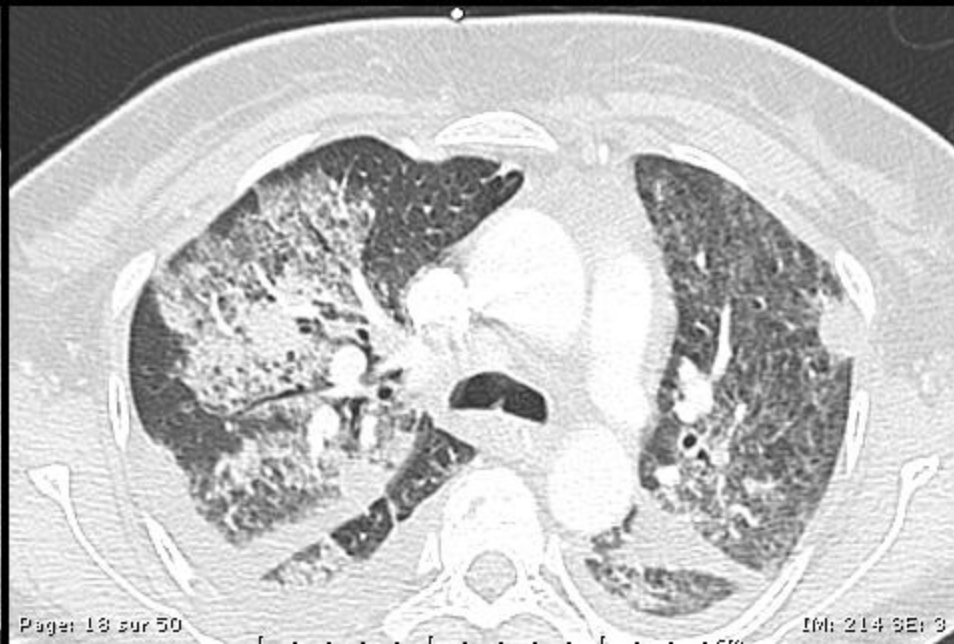Page: 18 sur 50

Im: 210 SE: 3



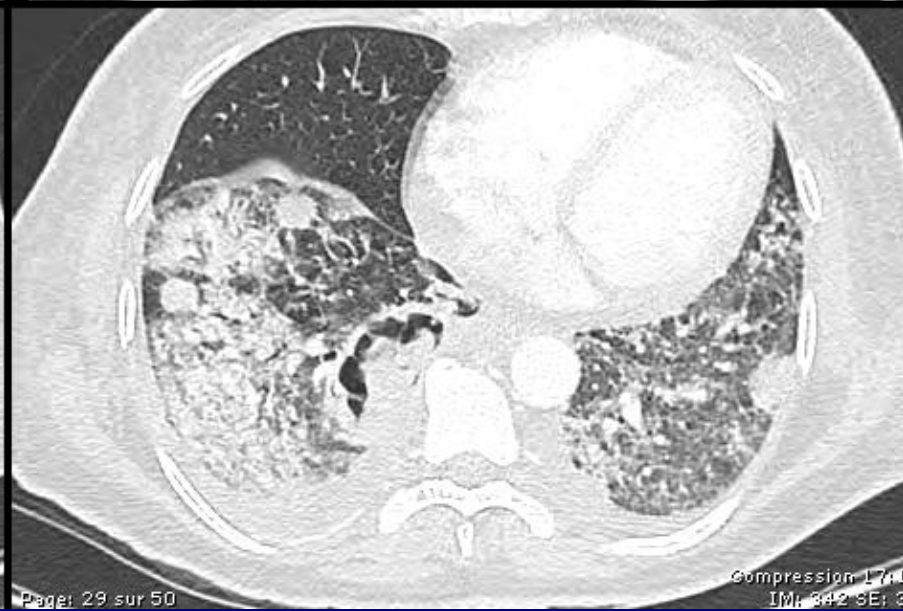
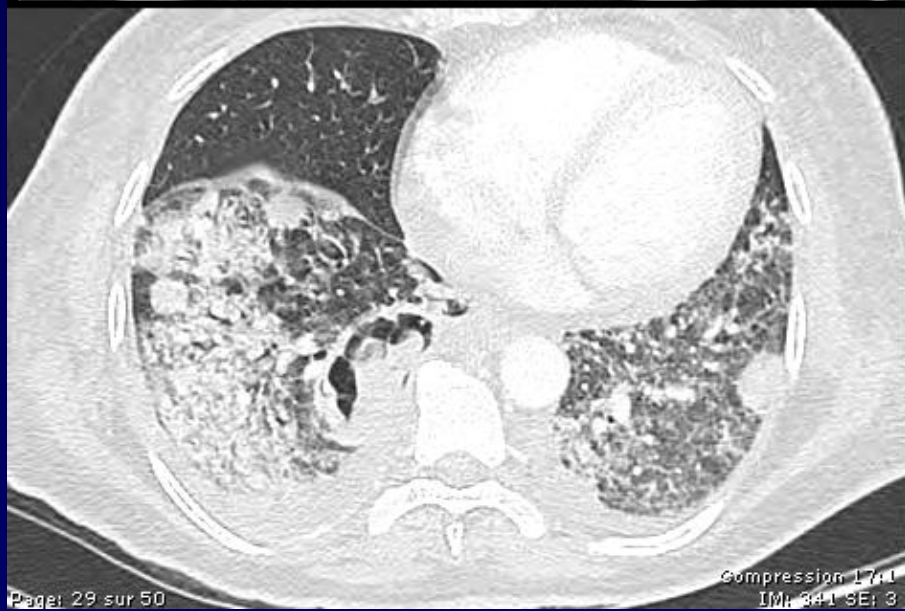
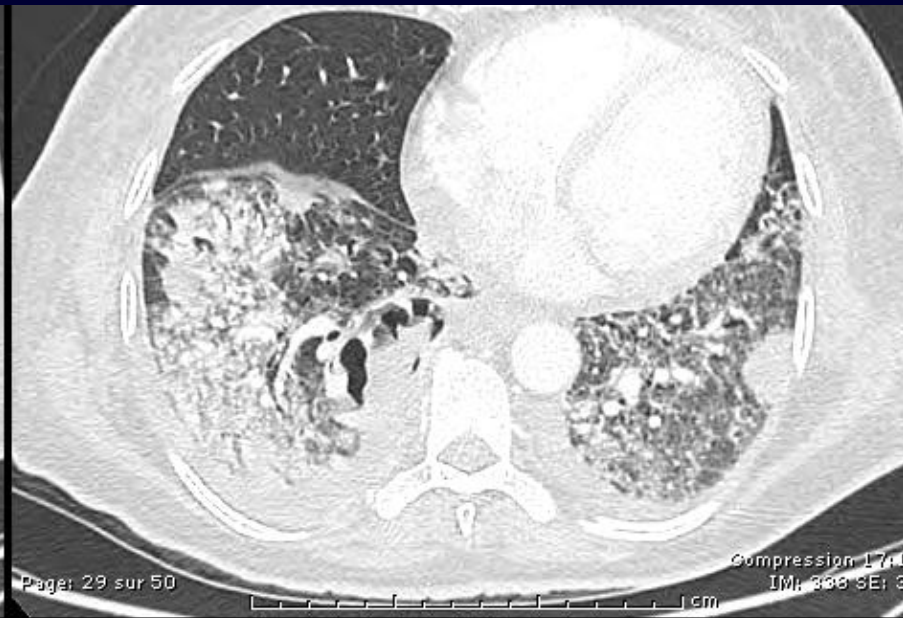
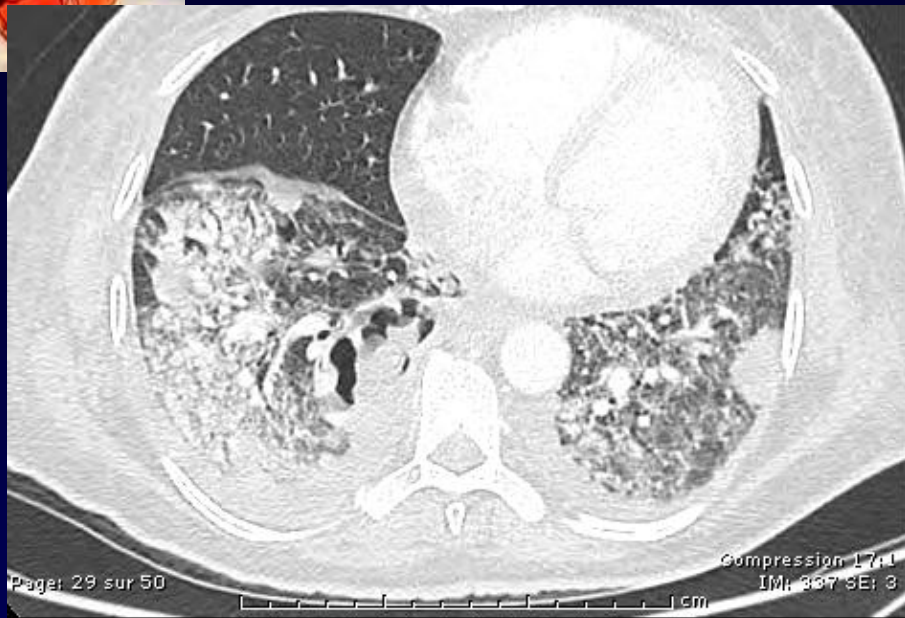Page: 18 sur 50

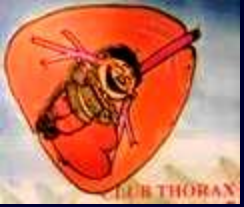Im: 213 SE: 3



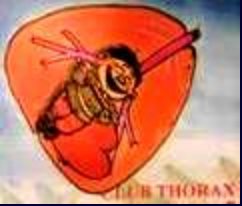Page: 18 sur 50

Im: 214 SE: 3





Diagnostic ?



Wegener fulminant

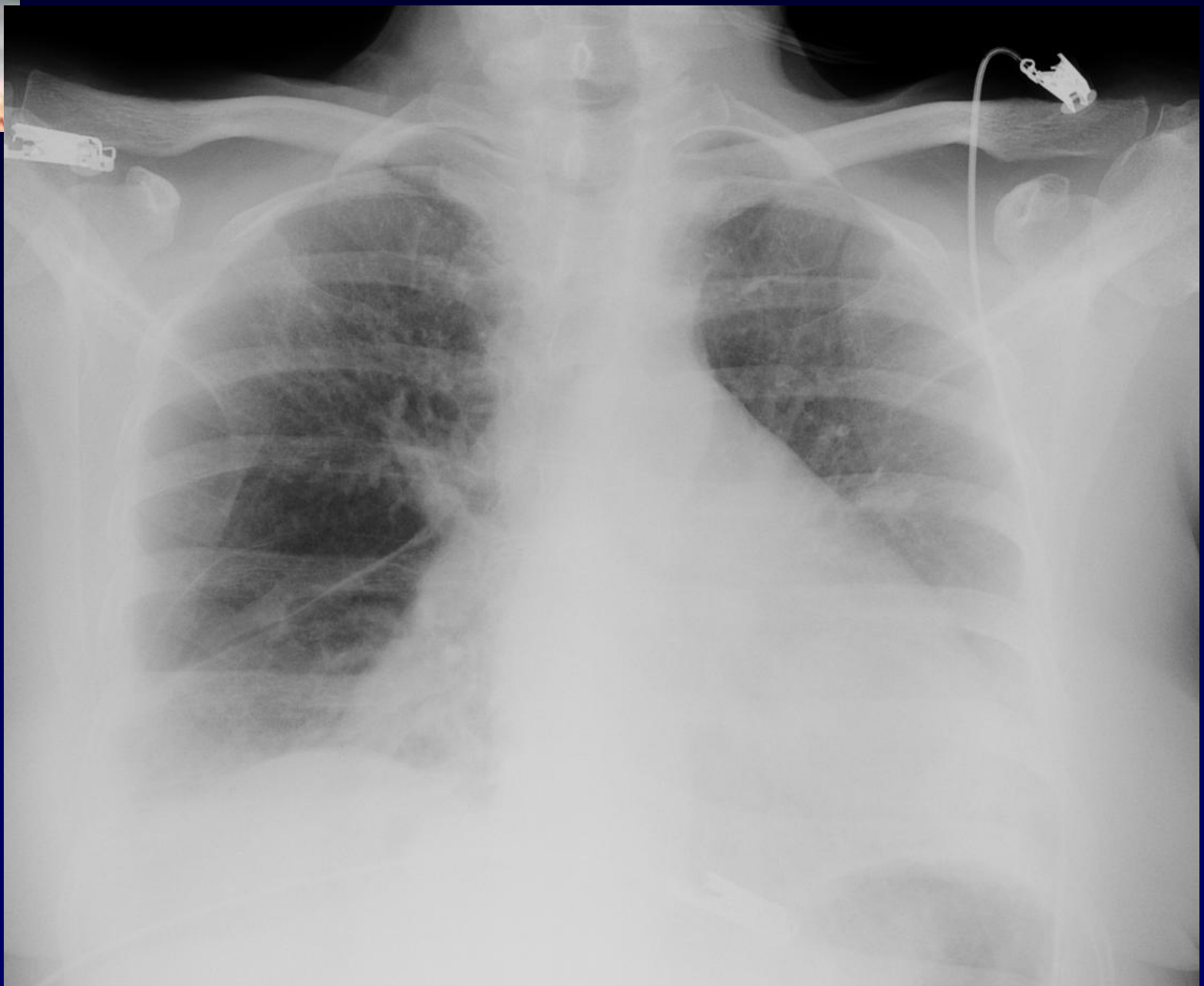
Evolution fulminante

Absence de tumeur primitive

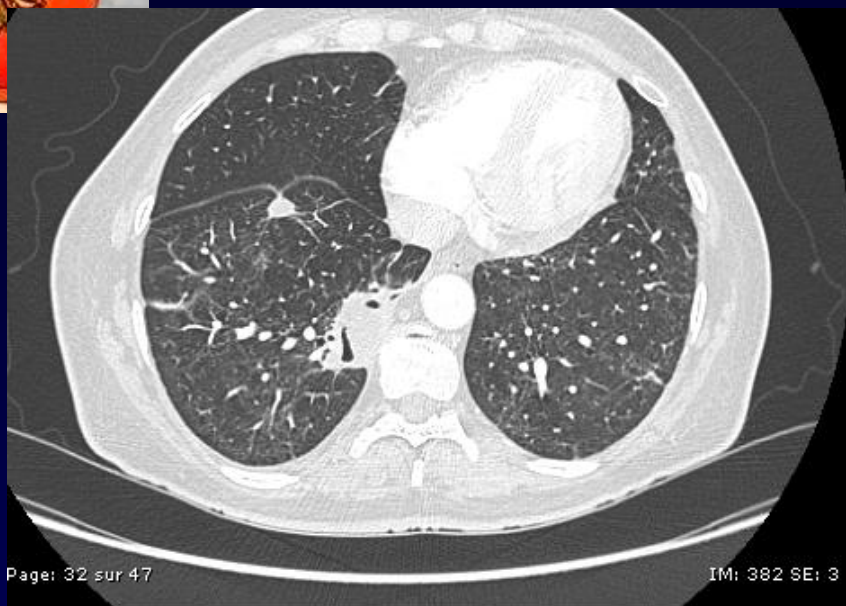
Saignement

Positivité des ANCA-PR3 +++

Cavitation

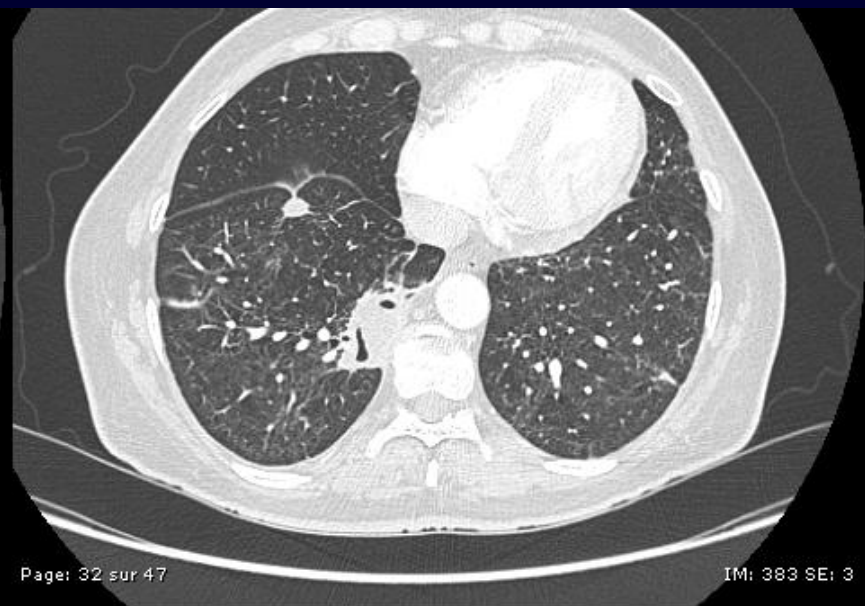


RT à 5 semaines (patiente sous traitement)

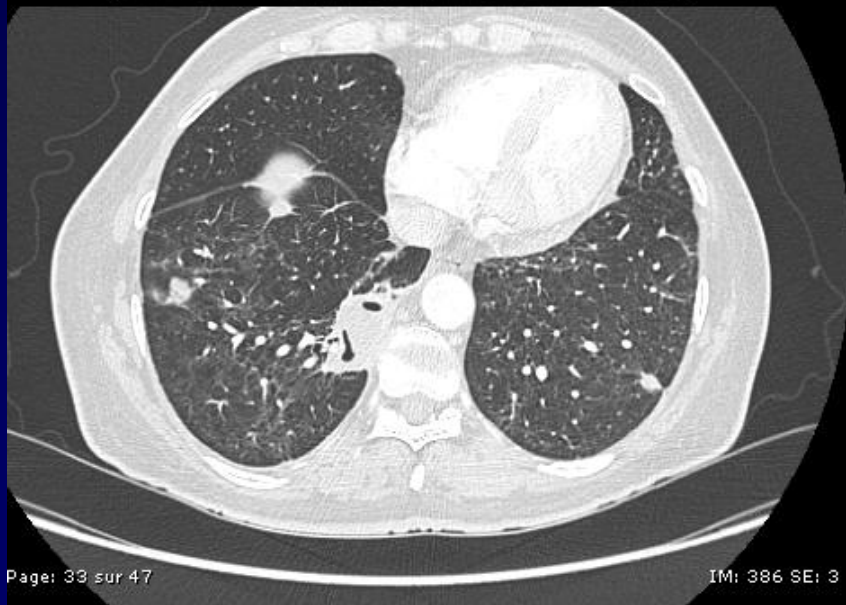


Page: 32 sur 47

IM: 382 SE: 3 Page: 32 sur 47

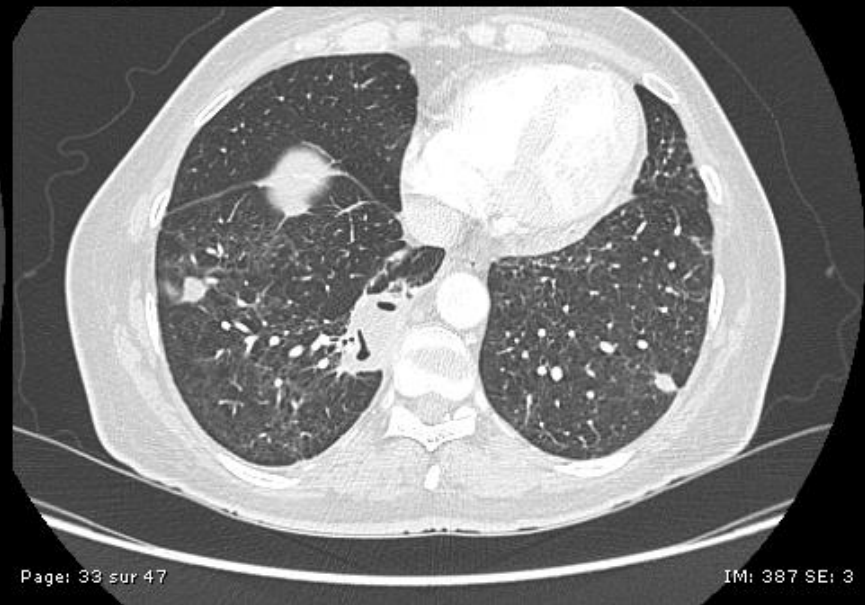


IM: 383 SE: 3



Page: 33 sur 47

IM: 386 SE: 3 Page: 33 sur 47



IM: 387 SE: 3

Scanner à 2 mois (patiente sous traitement)