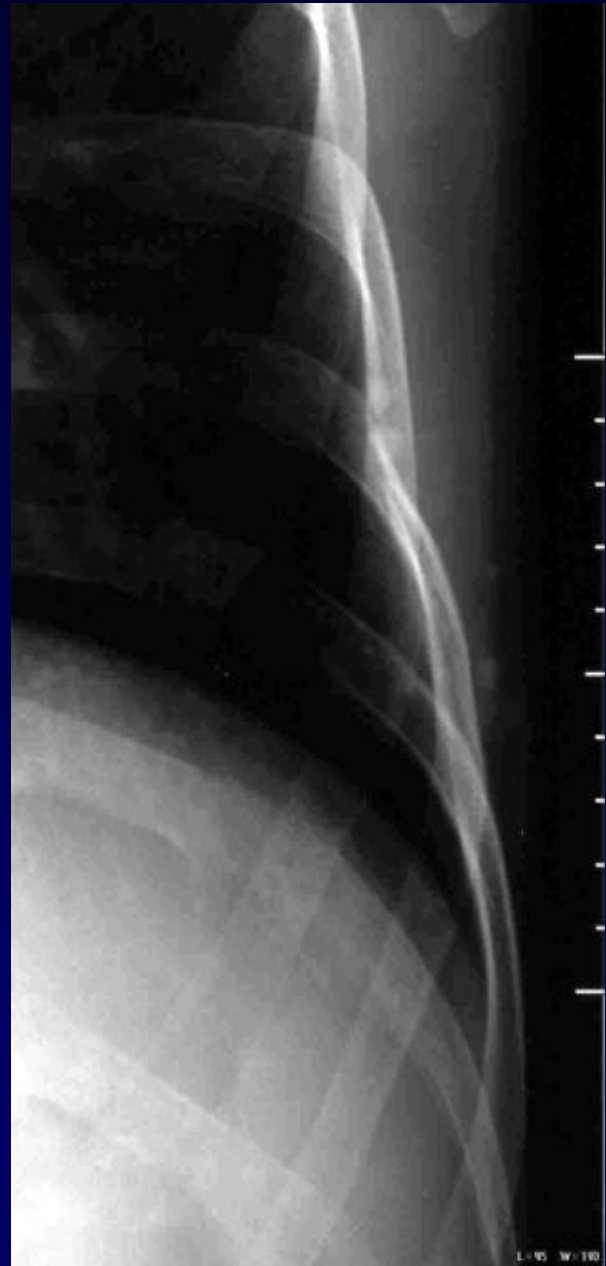
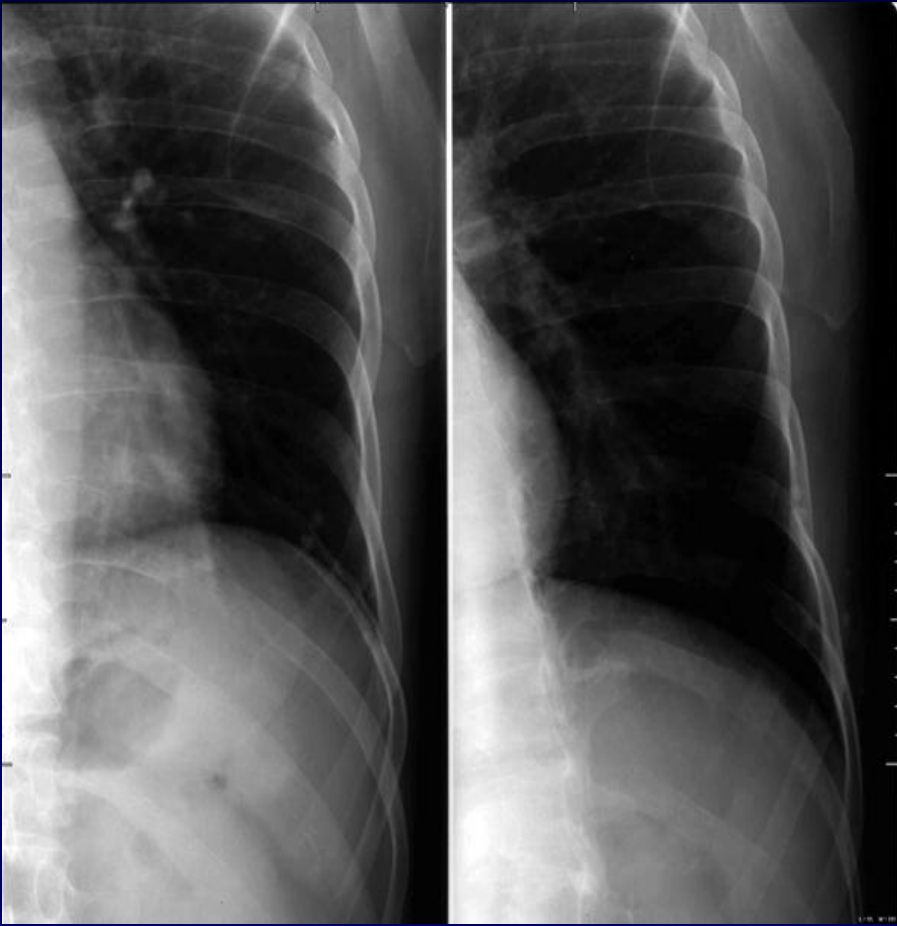
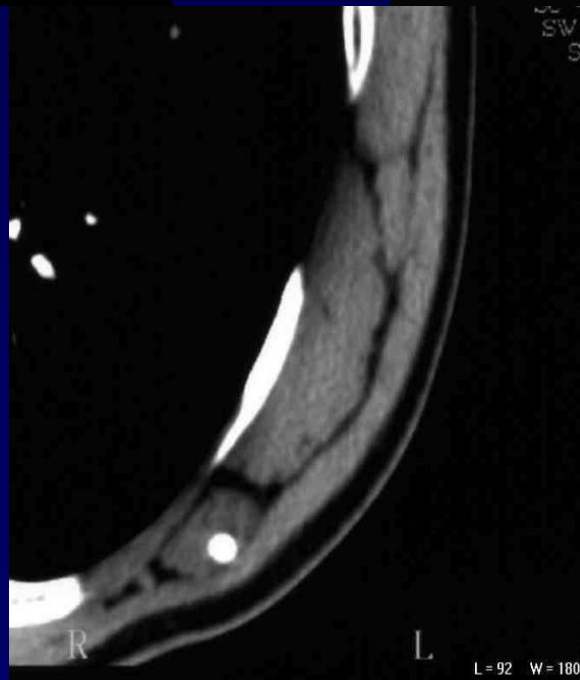
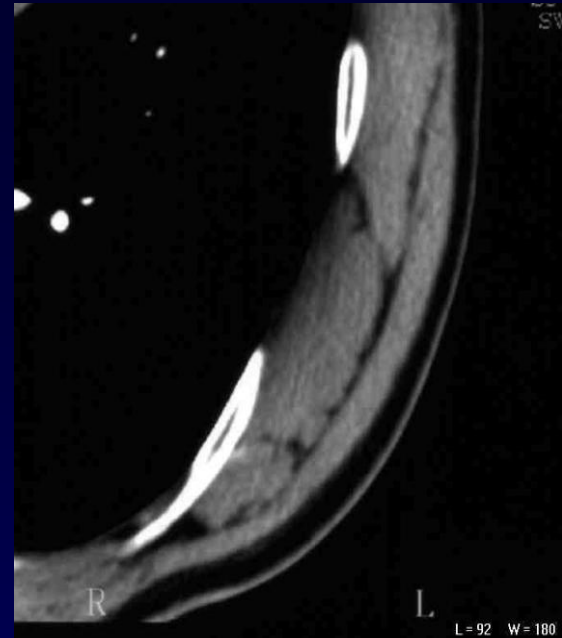
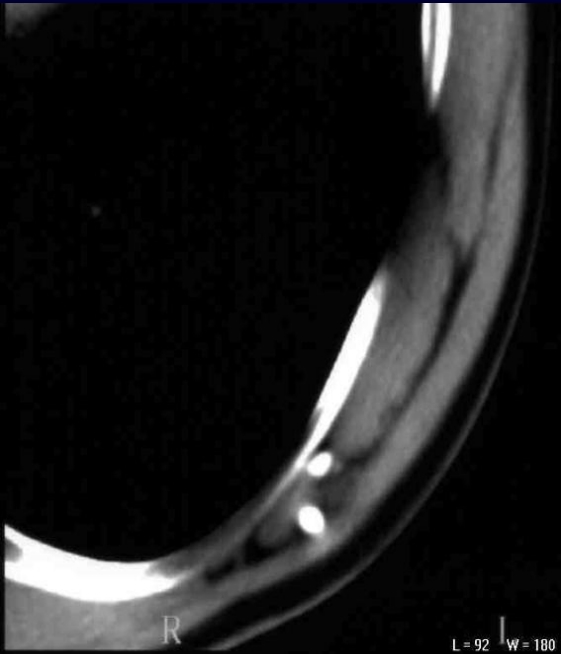


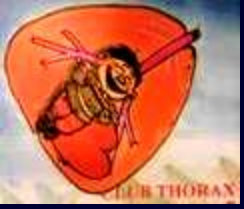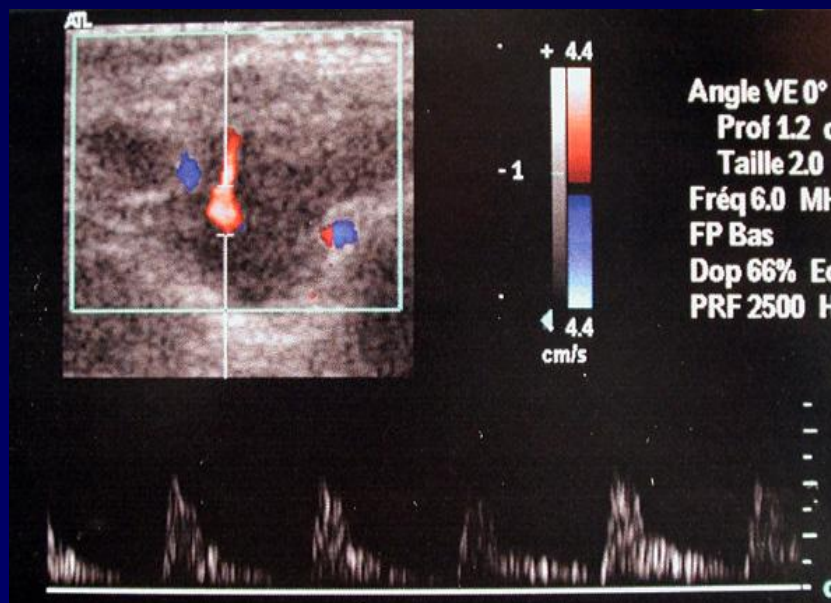
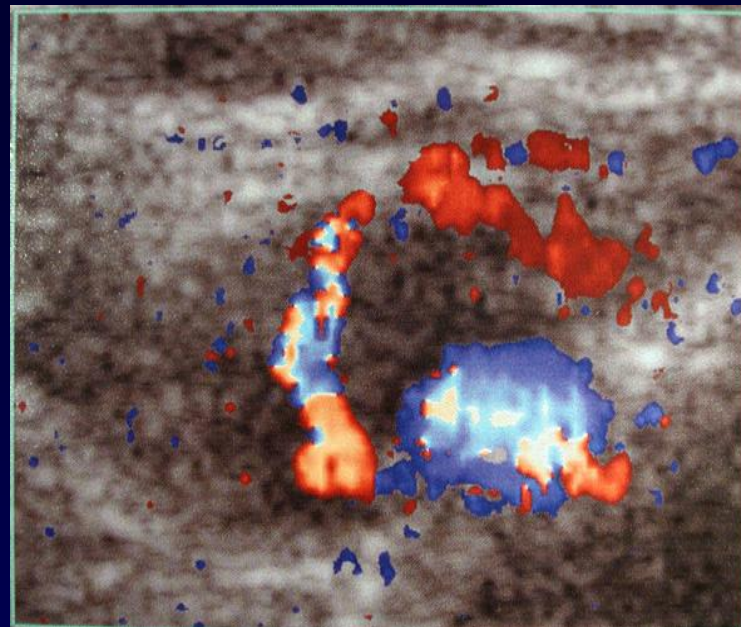
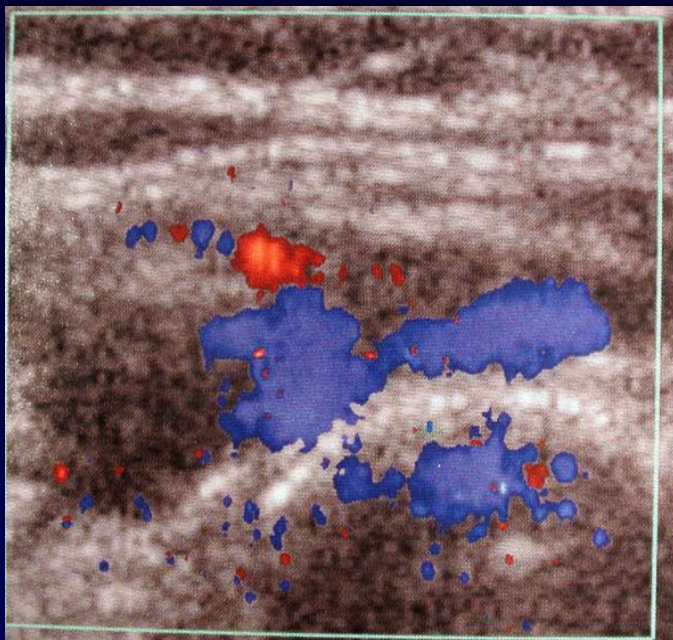
P. FAJADET

Homme de 50 ans

Masse pariétale basithoracique gauche

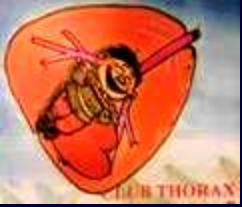







Diagnostic ?



**Anomalie de l'arc costal antérieur de
la 9ème côte gauche avec calcifications
nodulaires des parties molles, sans
rehaussement significatif après
injection**

**Présence de flux vasculaire à
l'échodoppler**

Angiome pariétal