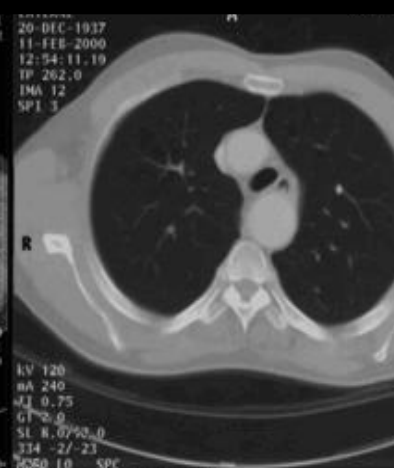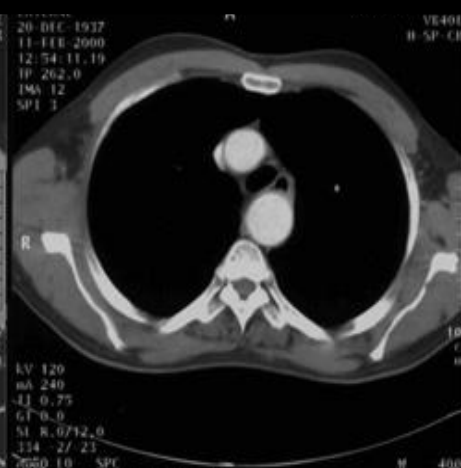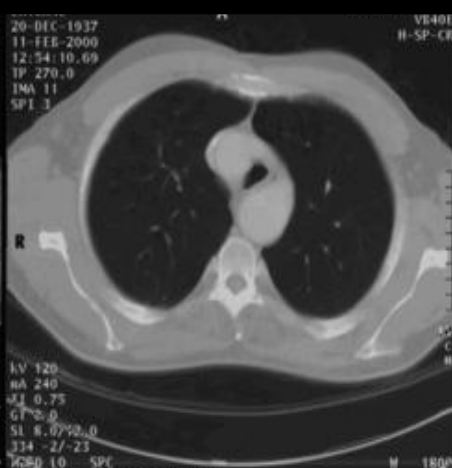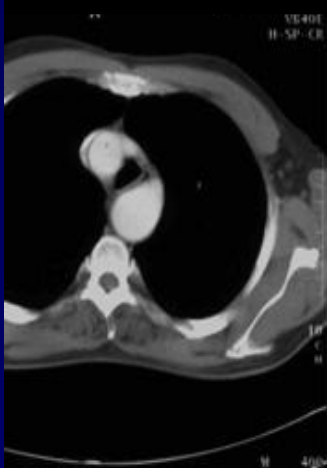
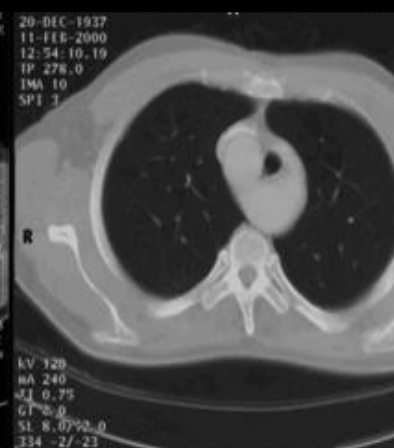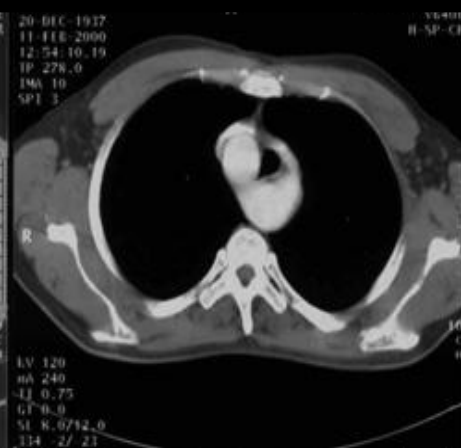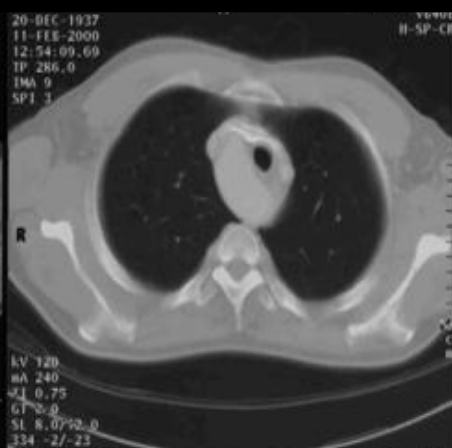
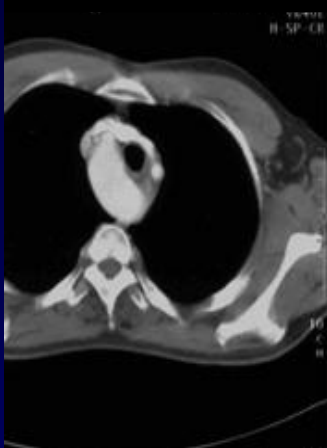


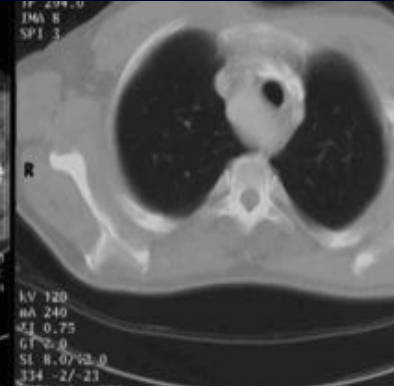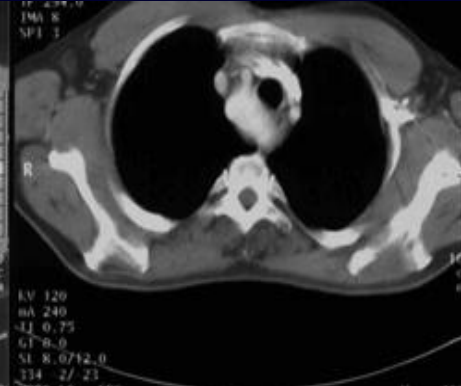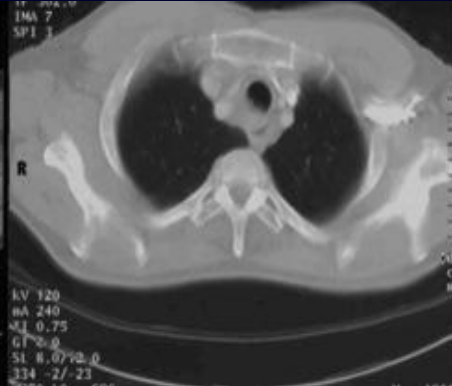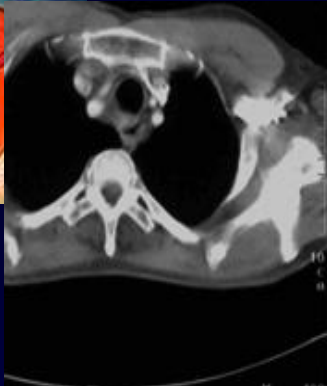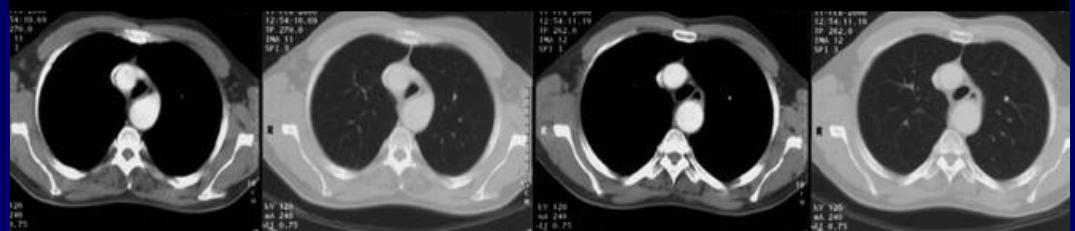
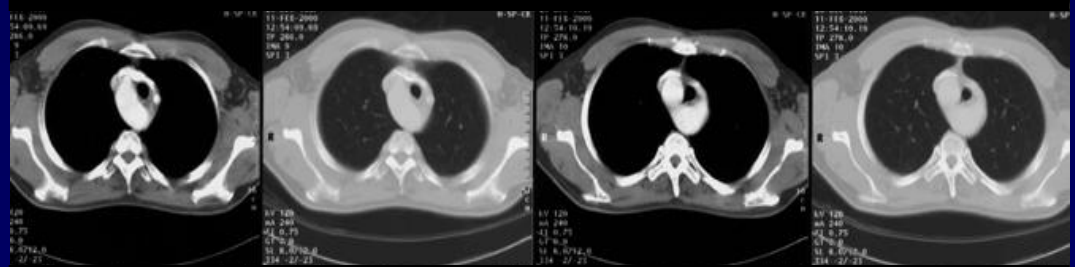
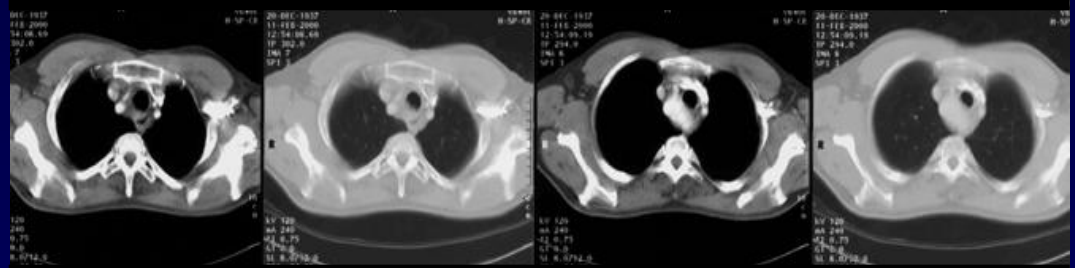
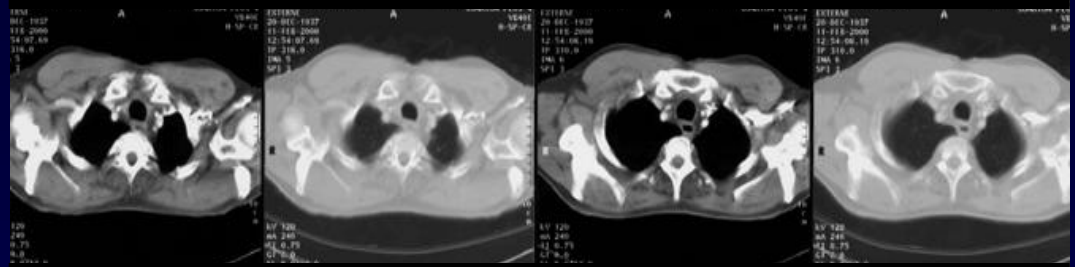
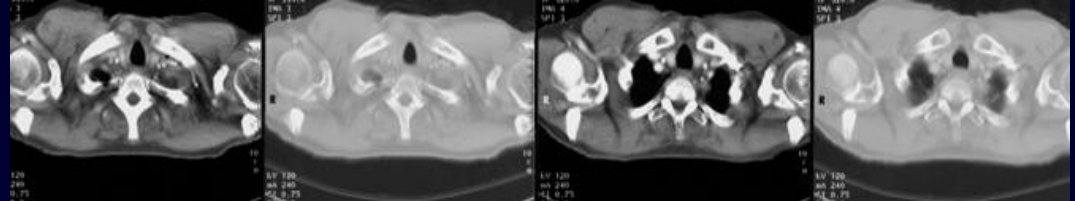


J GIRON

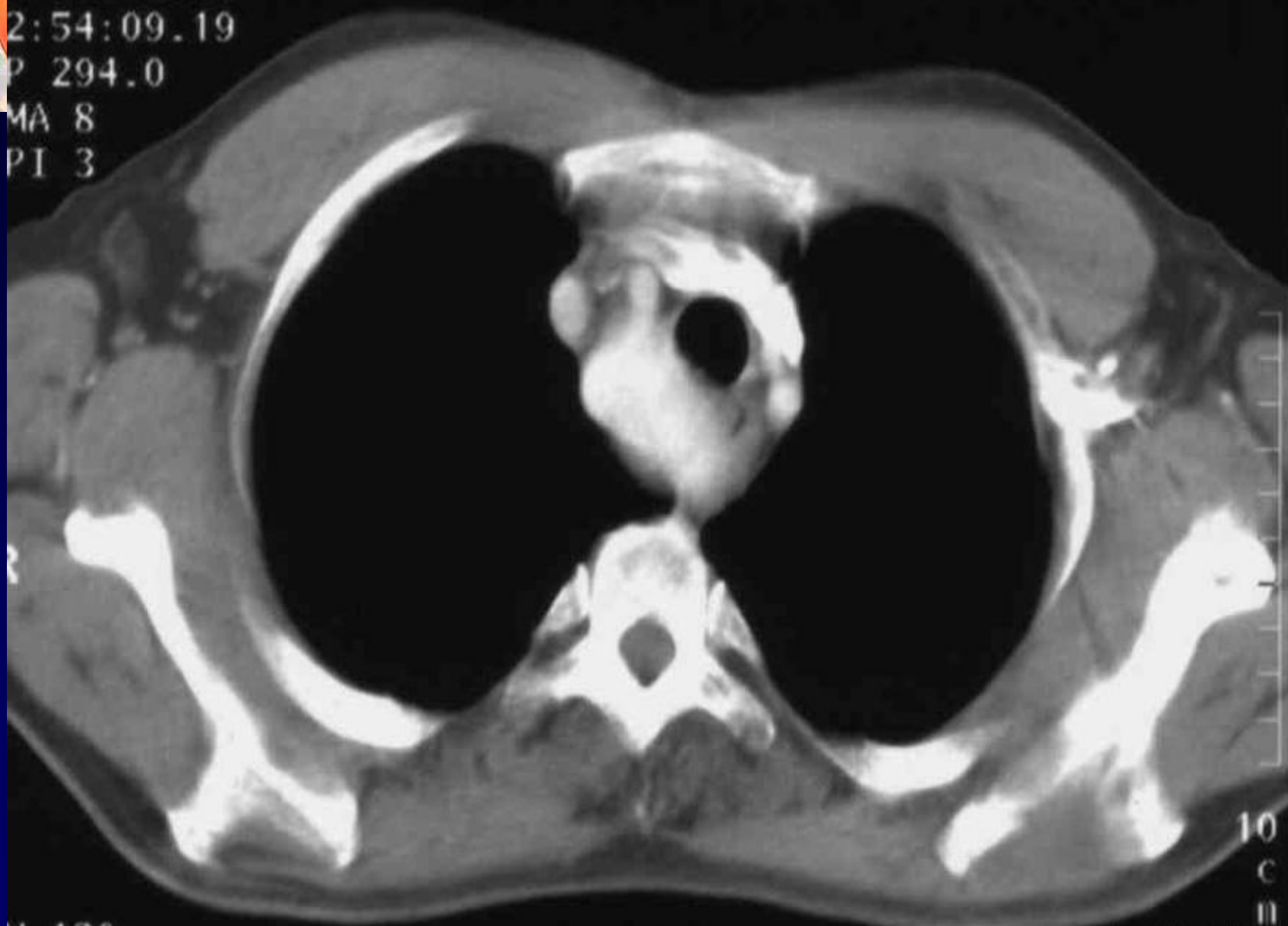
Homme de 67 ans

Asymptomatique





1-FEB-2000
2:54:09.19
P 294.0
MA 8
PI 3

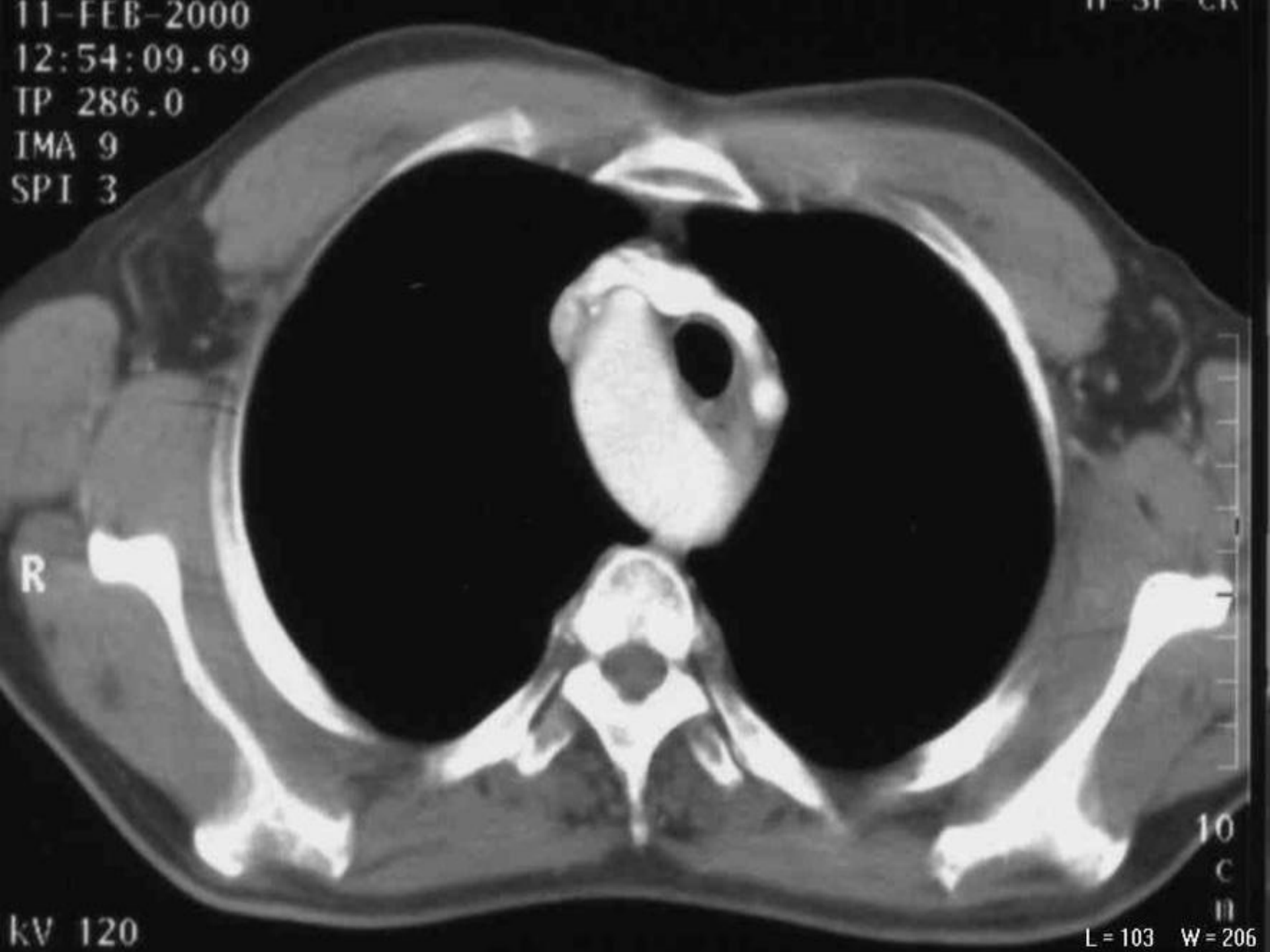

10
C
II

V 120

L = 103 W = 206

11-FEB-2000
12:54:09.69
TP 286.0
IMA 9
SPI 3



R

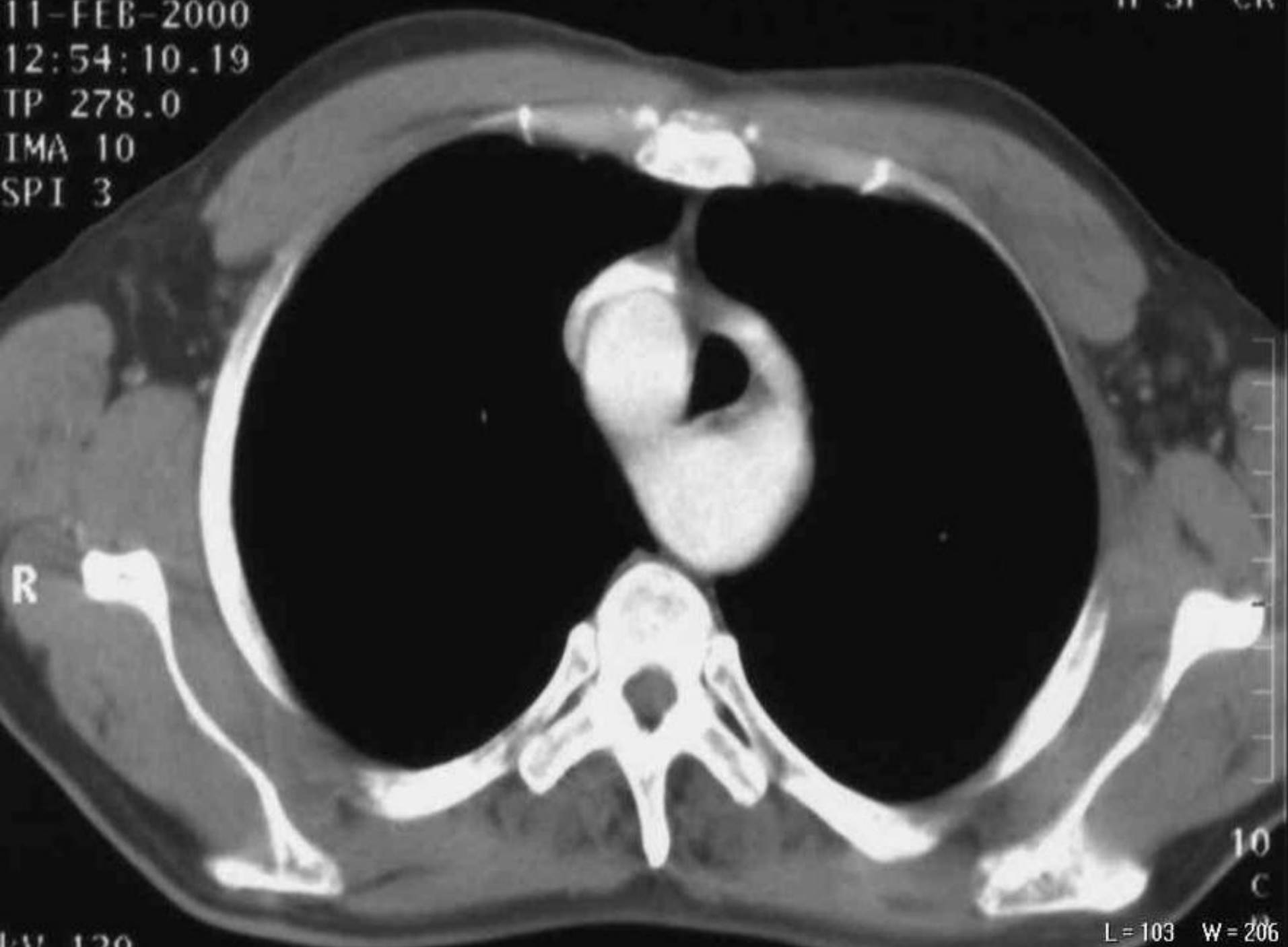
10
C
II

kV 120

L = 103 W = 206

DEC 1997
11-FEB-2000
12:54:10.19
TP 278.0
IMA 10
SPI 3

H-SP-CR



R

10
C

L = 103 W = 206

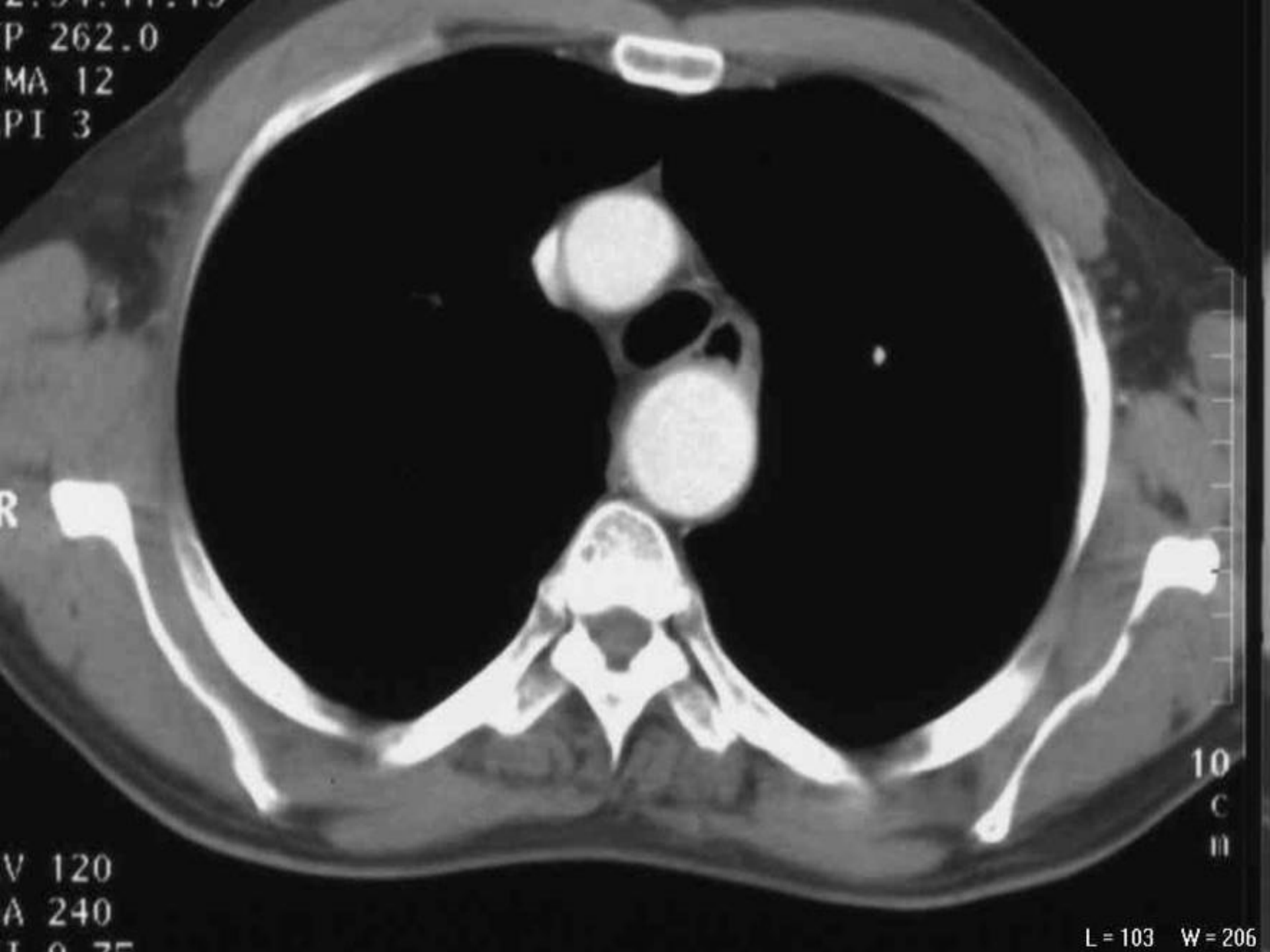P 262.0
MA 12
PI 3

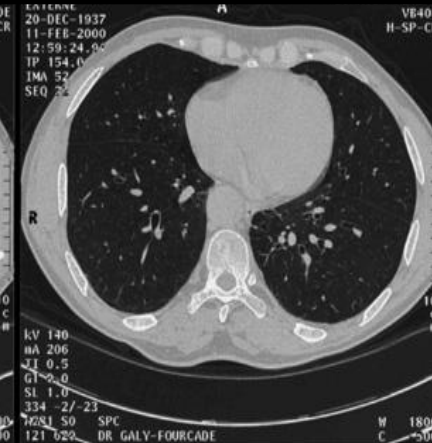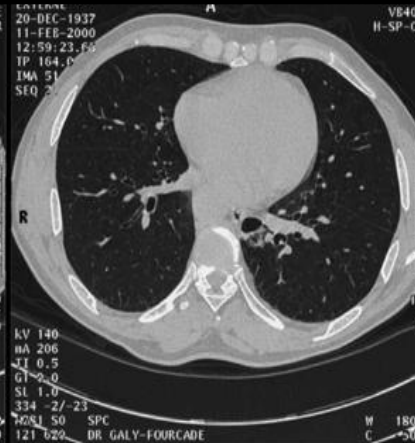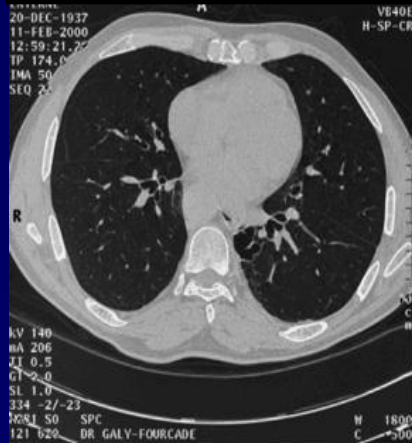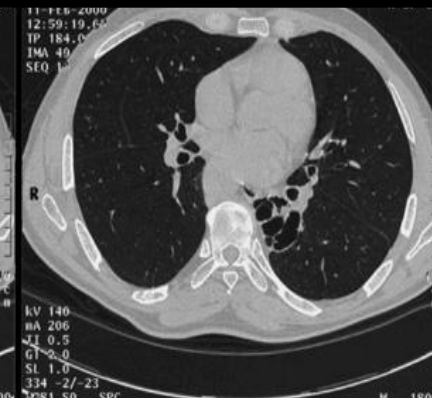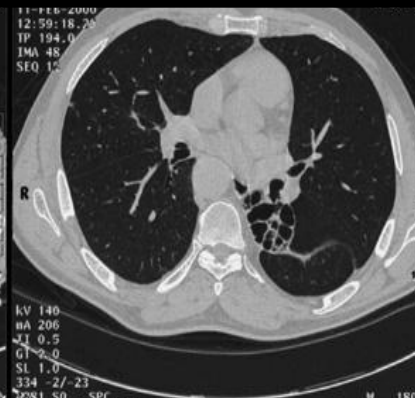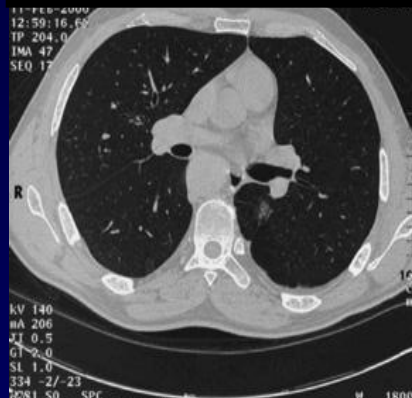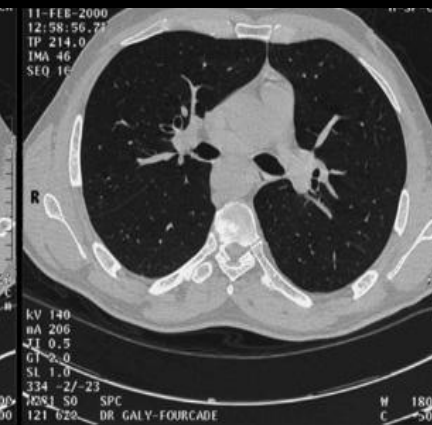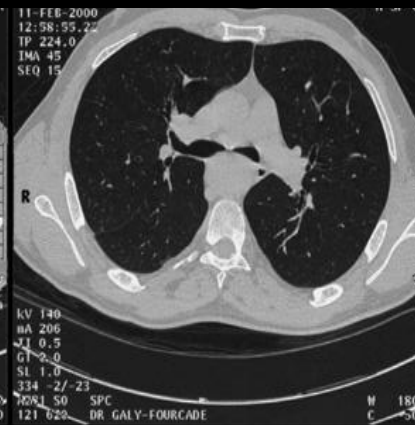
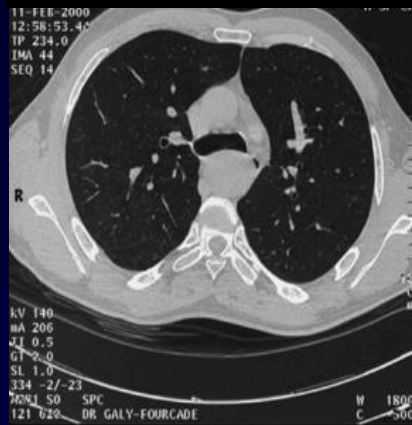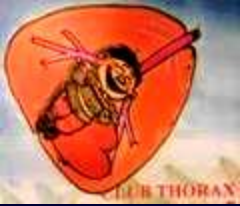R

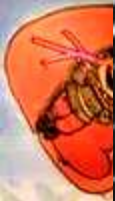V 120
A 240
I 0.75

10
C
II

L = 103 W = 206

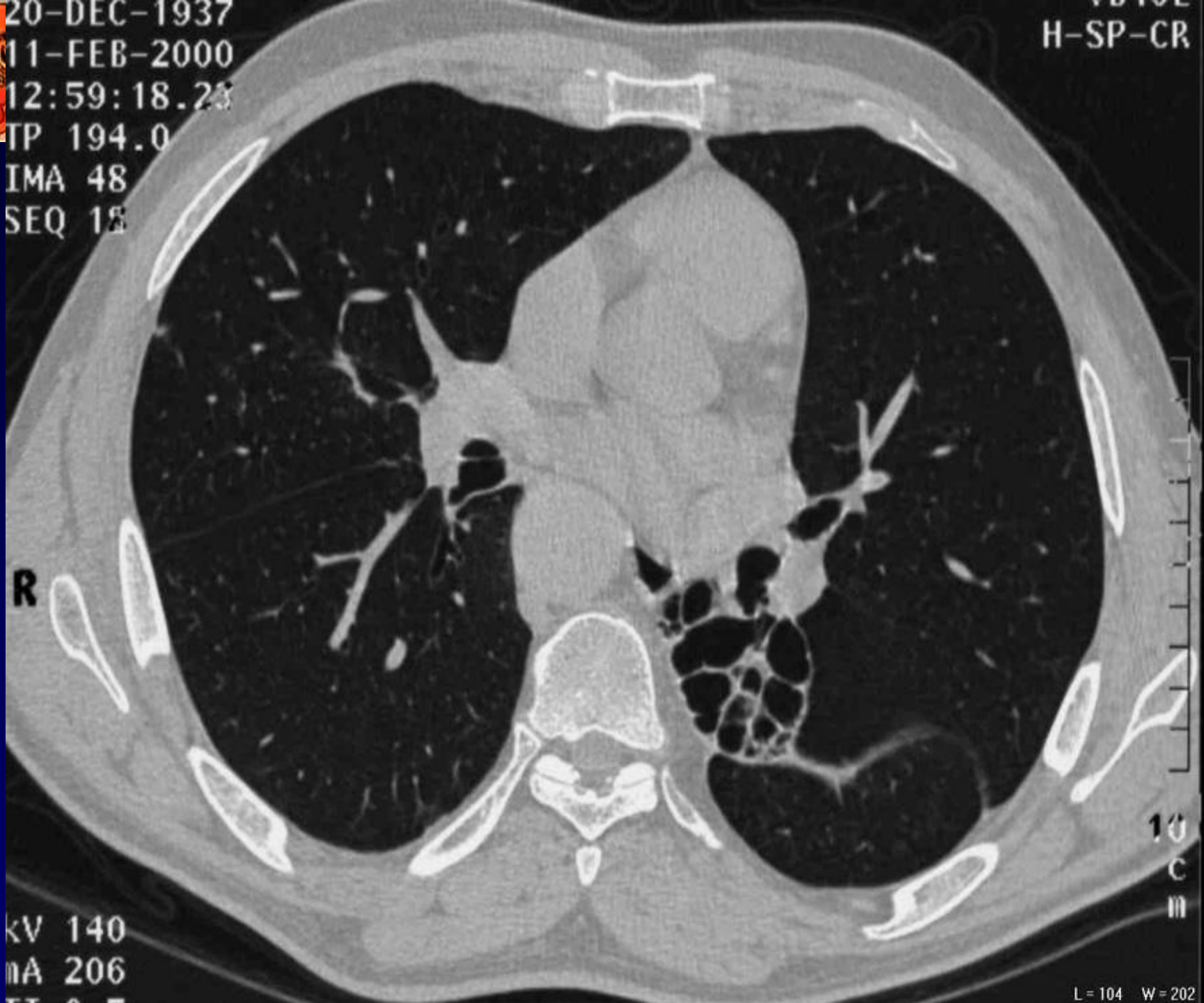






20-DEC-1937
11-FEB-2000
12:59:18.23
TP 194.0
IMA 48
SEQ 15

FB 10E
H-SP-CR

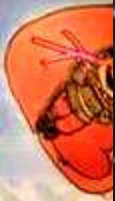

R

10
C
M

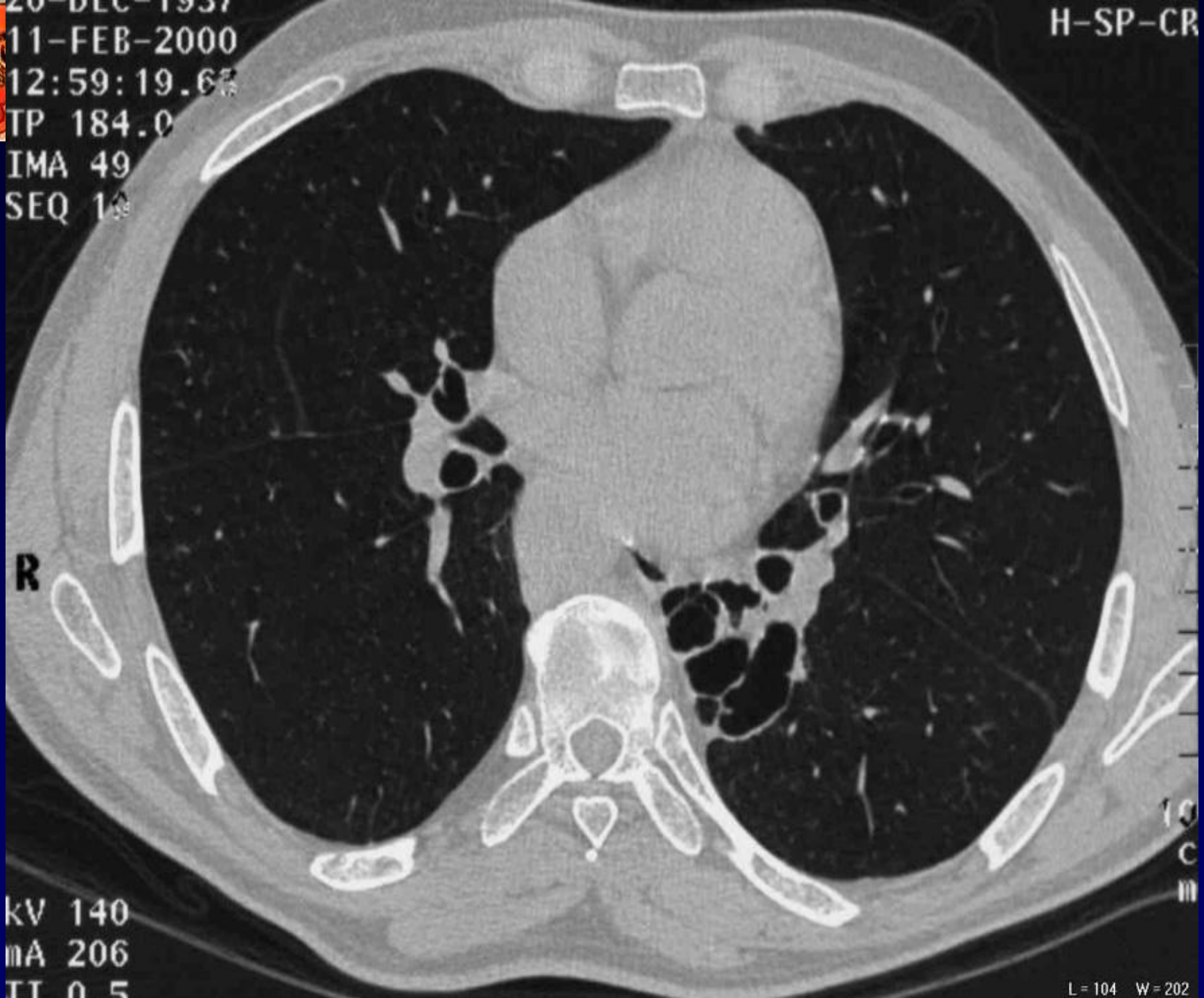
kV 140
mA 206
ET 6.5

L = 104 W = 202



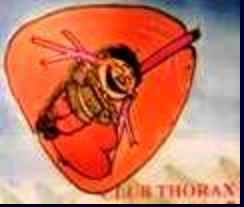20 DEC 1997
11-FEB-2000
12:59:19.6
TP 184.0
IMA 49
SEQ 14

H-SP-CR



kV 140
mA 206
TI 0.5

L = 104 W = 202



Diagnostic ?



Anomalie des arcs aortiques

**DDB du segment de Fowler
gauche**