

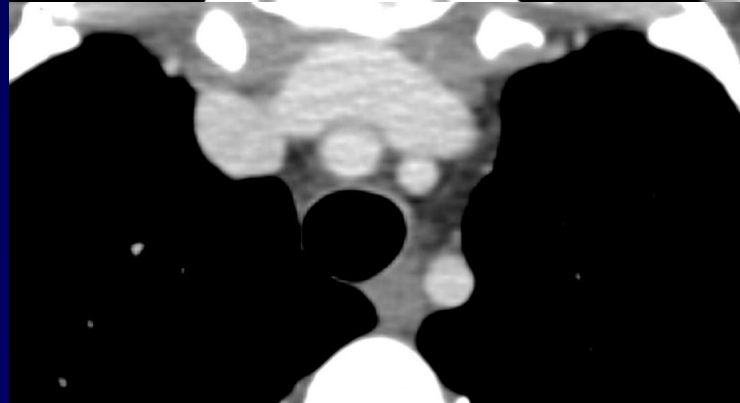
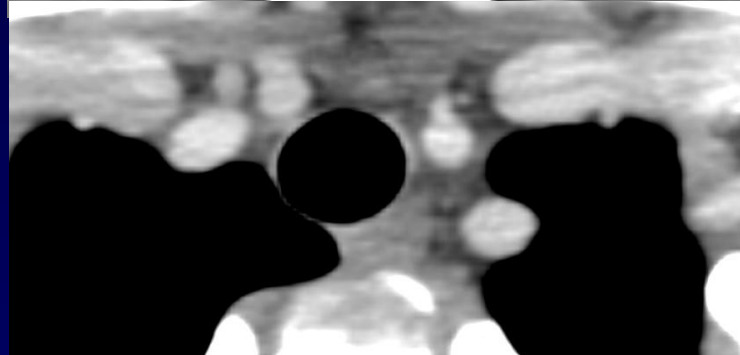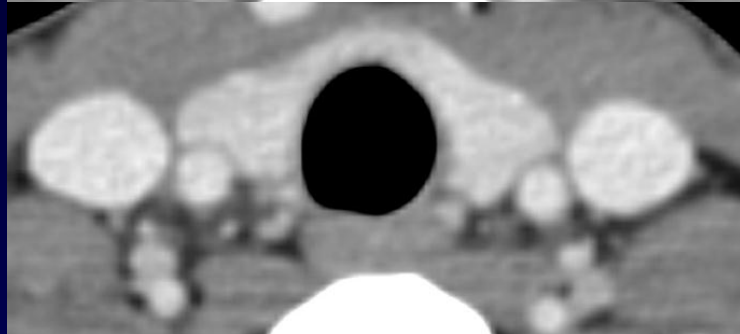
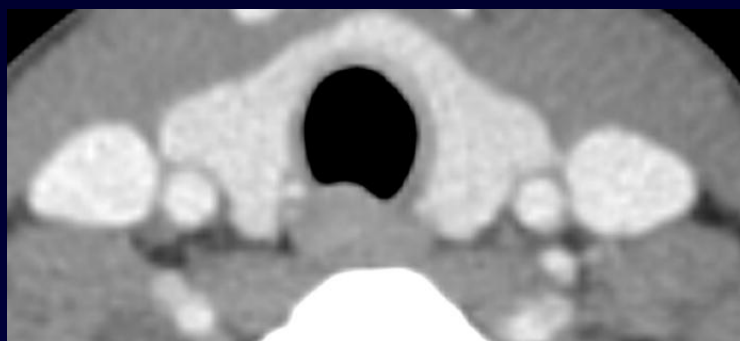
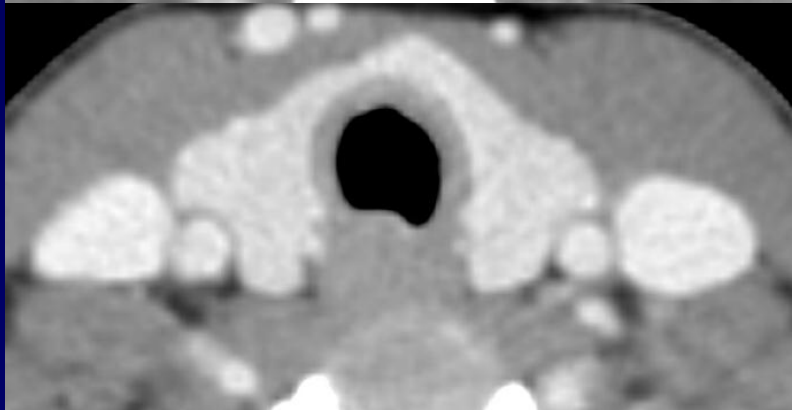
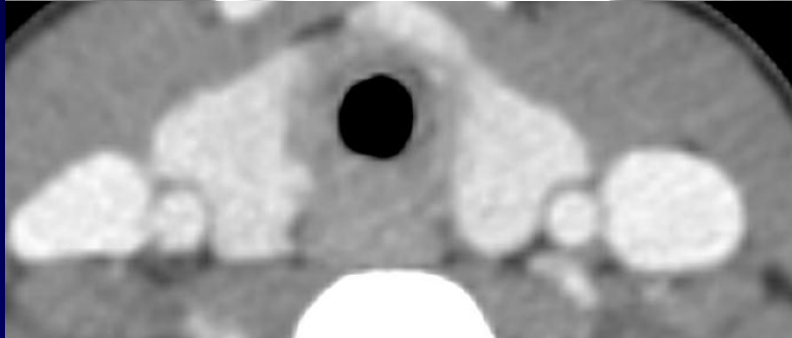
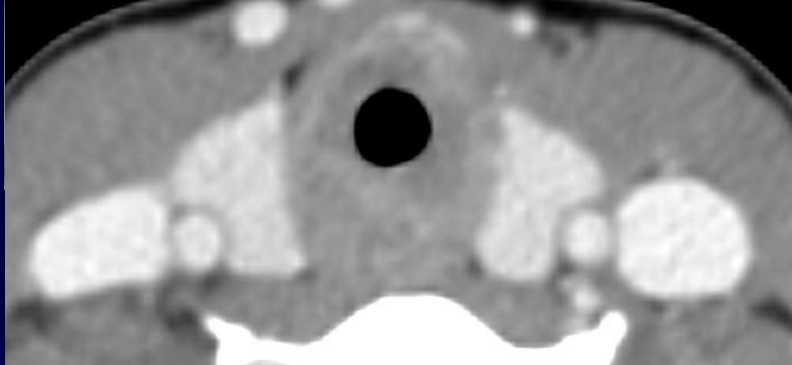
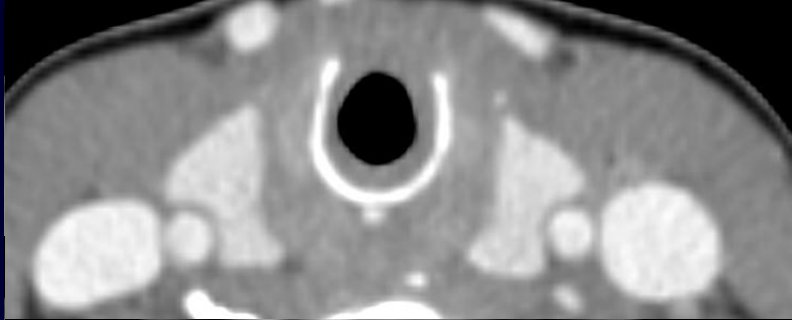


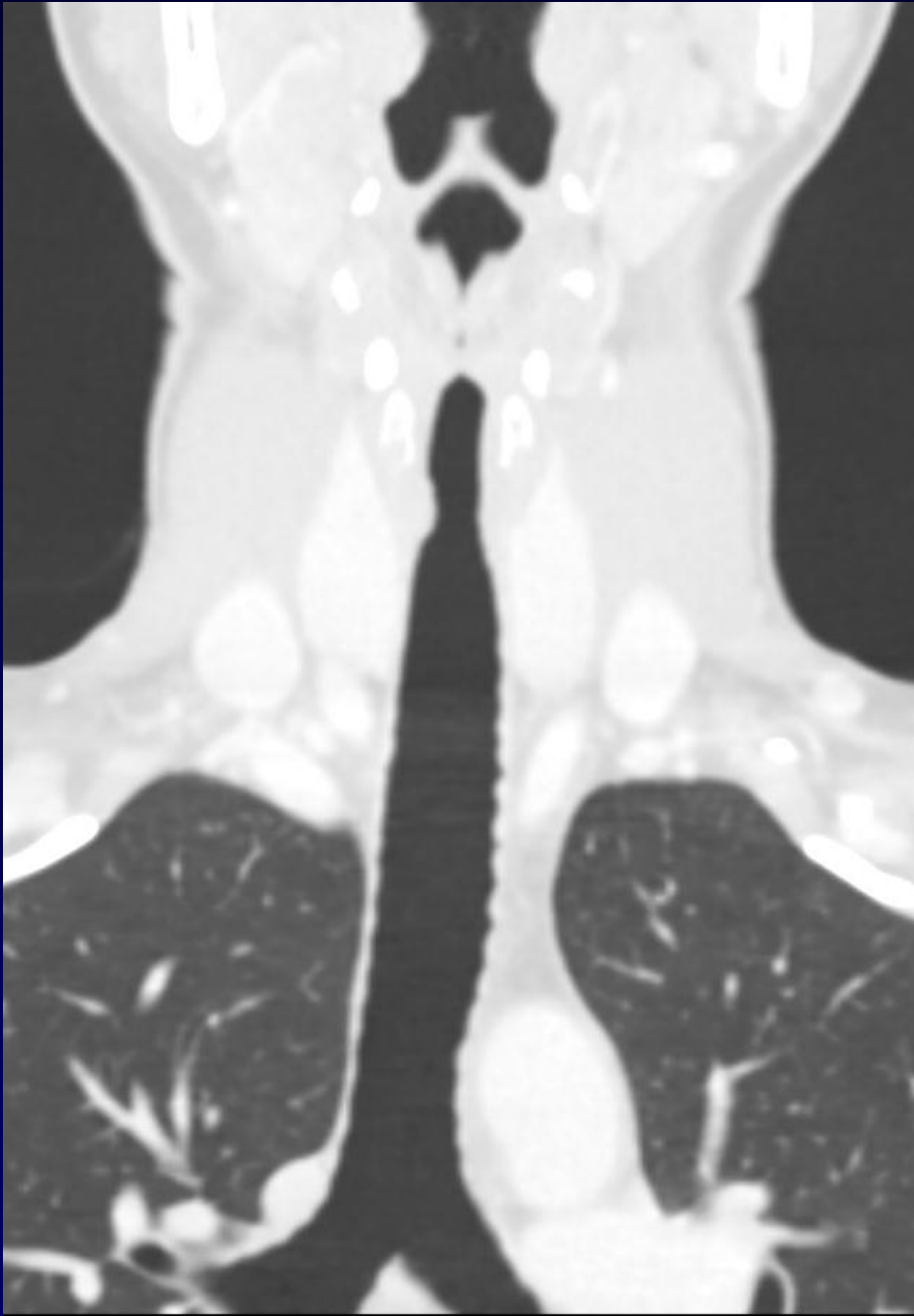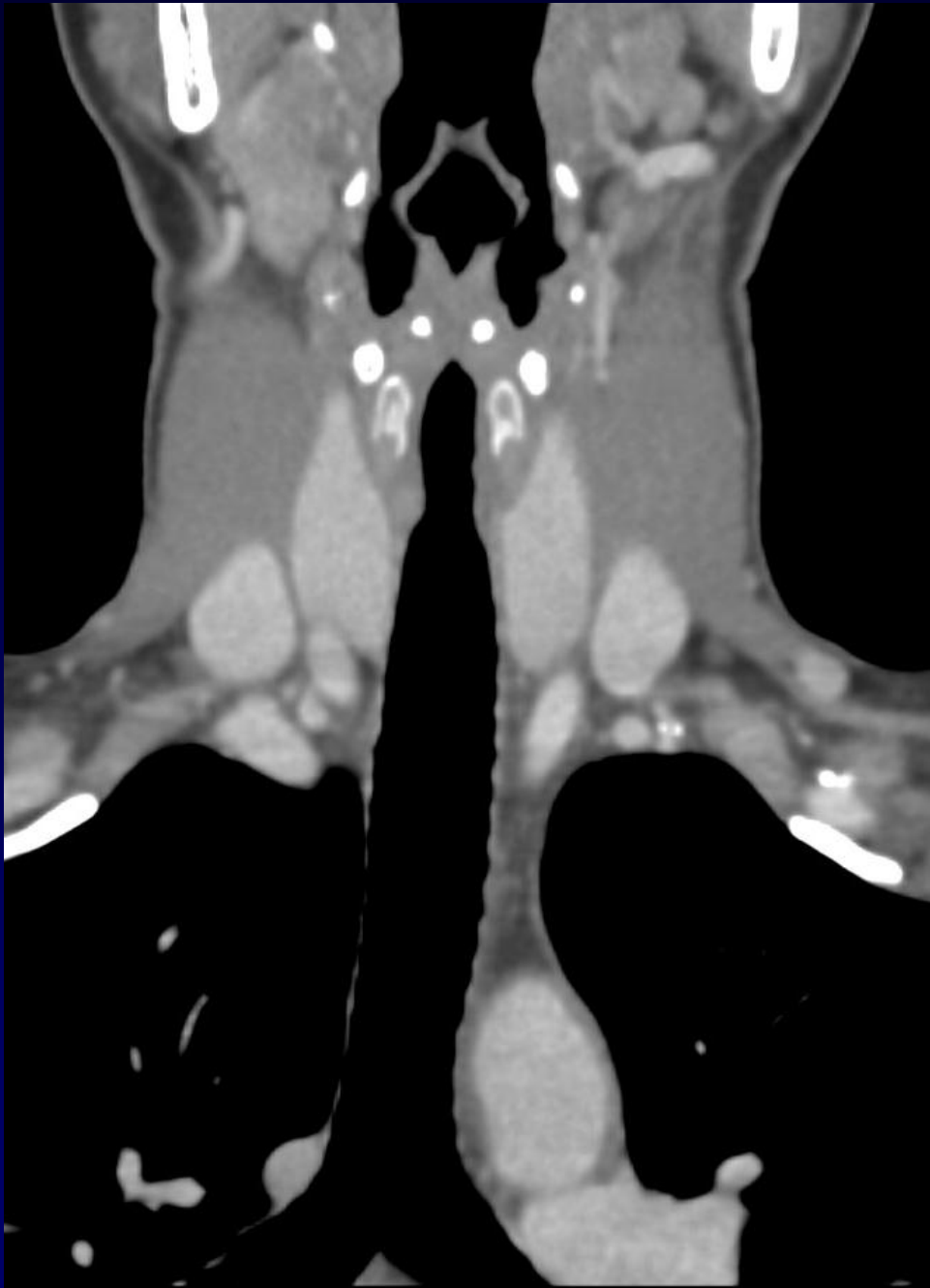
Femme de 34 ans

Dyspnée, stridor

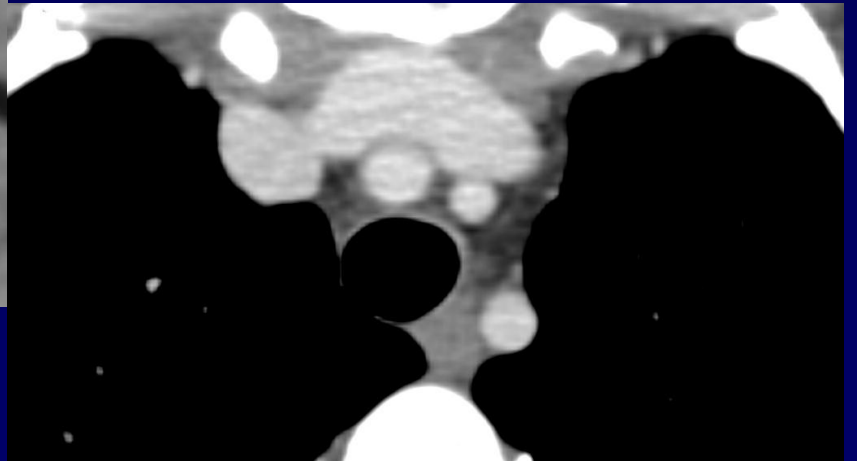
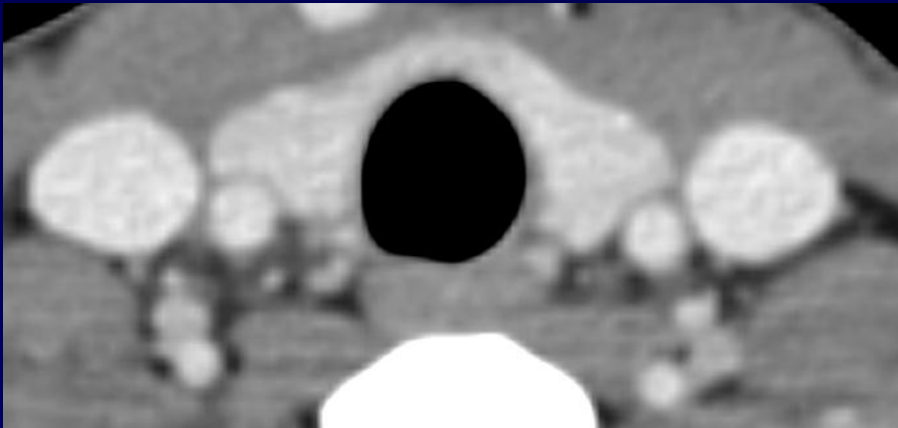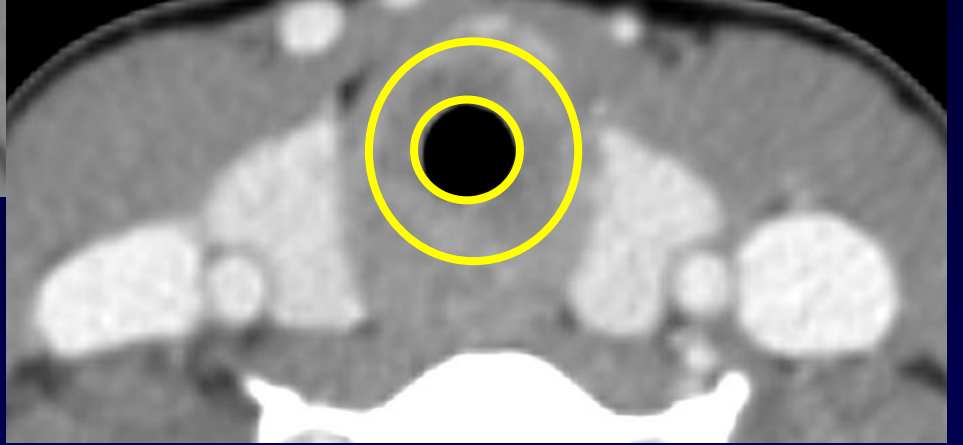
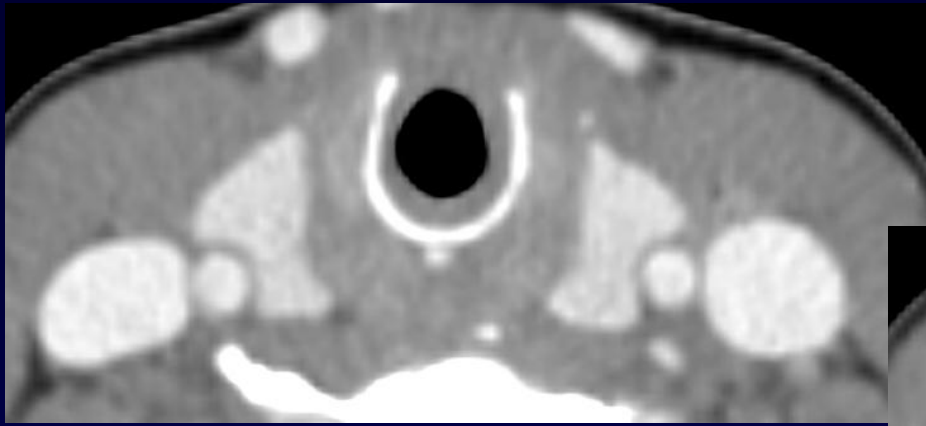
Vascularite sous traitement

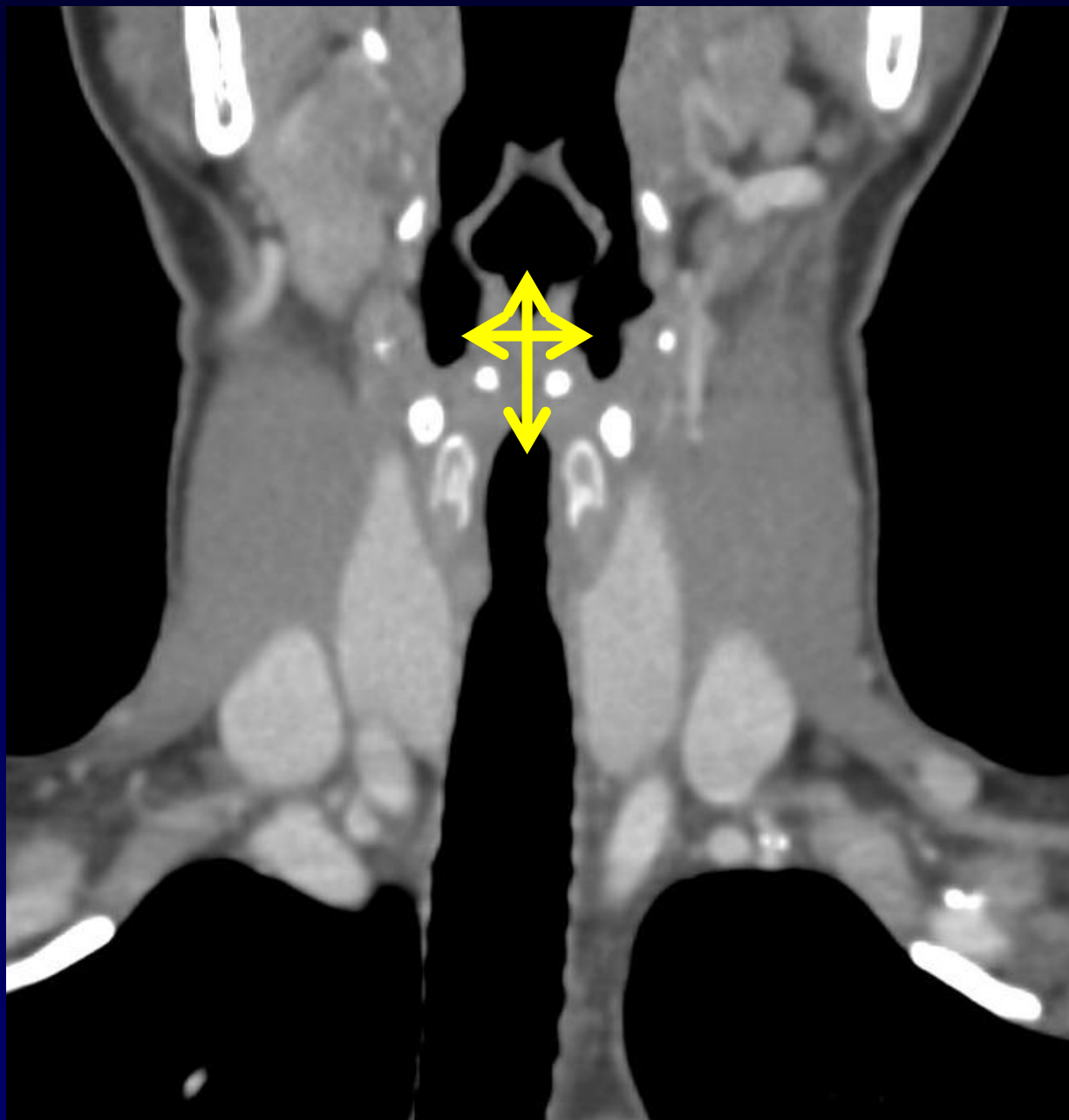
Aspect de plateau inspiratoire et expiratoire  
sur la courbe débit-volume





**Diagnostic ?**





# **Diagnostic**

**Sténose trachéale caractéristique  
d'une maladie de Wegener**